

ISSN 2559 - 723X
ISSN-L 2559 723X
e-ISSN 2601 - 1700

Surgery, Gastroenterology and Oncology

Volume 23, Supplement I, 2018

**Abstracts of Papers Submitted
to the IASGO World Congress**

September 9-12, 2018, Moscow, Russia



**Official Journal
of the International
Association of
Surgeons,
Gastroenterologists
and Oncologists**

CELSIUS PUBLISHING HOUSE

www.sgo-iasgo.com

Surgery, Gastroenterology and Oncology

official journal of the
International Association of Surgeons and Gastroenterologists and Oncologists

Honorary Editor-in-Chief

Masatoshi Makuuchi, *Tokyo, Japan*

Editor-in-Chief

Nuh N. Rahbari, *Mannheim, Germany*

Vice Editor-in-Chief

Irinel Popescu, *Bucharest, Romania*

Founding Editors

Dan G. Duda, *Boston, USA*

Kyoichi Takaori, *Kyoto, Japan*

Consultant Editor

Guido Torzilli, *Milan, Italy*

Associate Editors

Mustapha Adham, *Lyon, France*

Ho-Seong Han, *Seoul, Korea*

Vijay Khatri, *Elk Grove, USA*

Norihiro Kokudo, *Tokyo, Japan*

Masato Nagino, *Nagoya, Japan*

Marco Del Chiaro, *Stockholm, Sweden*

Calogero Iacono, *Verona, Italy*

Yasuhiro Kodera, *Nagoya, Japan*

Ming-Tsan Lin, *Taipei, Taiwan*

Sergey Voskanyan, *Moscow, Russia*

Editorial Board

Mohamed Abdel Wahab, *Mansoura, Egypt*

Sorin Alexandrescu, *Bucharest, Romania*

Toru Beppu, *Kumamoto, Japan*

Liliana G. Bordeianou, *Boston, USA*

Abdel-Hadi Al Breizat, *Amman, Jordan*

Thawatchai Akaraviputh, *Bangkok, Thailand*

Philippe Bachellier, *Strasbourg, France*

Mitesh J. Borad, *Phoenix, USA*

Florin Botea, *Bucharest, Romania*

Thomas Brunner, *Magdeburg, Germany*

Rawisak Chanwat, *Bangkok, Thailand*
Jeffrey W. Clark, *Boston, USA*

Simona Olimpia Dima, *Bucharest, Romania*
Ender Dulundu, *Istanbul, Turkey*
Susumu Eguchi, *Nagasaki, Japan*
Brian K. P. Goh, *Singapore, Singapore*
Doris Henne-Bruns, *Ulm, Germany*
Razvan Iacob, *Bucharest, Romania*
Aleksandar Karamarkovic, *Belgrade, Serbia*
Masayuki Kitano, *Wakayama, Japan*
Ser Yee Lee, *Singapore, Singapore*
Shugo Mizuno, *Mie, Japan*
Wojciech G. Polak, *Rotterdam, The Netherlands*
Alvin Silva, *Phoenix, USA*
Olivier Soubrane, *Paris, France*
Michiaki Unno, *Sendai, Japan*
Wenming Wu, *Beijing, China*
Hongwei Yao, *Beijing, China*
Zhongtao Zhang, *Beijing, China*

Tan-To Cheung, *Hong Kong*
Joaquim Costa Pereira, *Santa Maria da Feira, Portugal*
Renata Dobrila-Dintinjana, *Rijeka, Croatia*
Traian Dumitraşcu, *Bucharest, Romania*
Cristina R. Ferrone, *Boston, USA*
Yanzheng He, *Luzhou, China*
Taizo Hibi, *Kumamoto, Japan*
Speranța Iacob, *Bucharest, Romania*
Ahmed Kaseb, *Houston, USA*
Gregory Y. Lauwers, *Tampa, USA*
Jan Lerut, *Brussels, Belgium*
John T. Mullen, *Boston, USA*
Mitsuo Shimada, *Tokushima, Japan*
Si Young Song, *Seoul, Korea*
Dana Tomescu, *Bucharest, Romania*
Elena Usova, *Moscow, Russia*
Ching-Yao Yang, *Taipei, Taiwan*
Thomas C.C. Yau, *Hong Kong*
Andrew X. Zhu, *Boston, USA*

English Language Editor

Mihnea I. Ionescu, *Birmingham, UK*

Surgery, Gastroenterology and Oncology (*Journal of Translational Medicine and Research*)
is atested and indexed in Elsevier Bibliographic Databases: SCOPUS

CrossRef (DOI: 10.21614/sgo)

Surgery, Gastroenterology and Oncology = ISSN 2559 - 723X, ISSN-L 2559 723X

Celsius Publishing House

ABSTRACTS

Abstracts of Papers Submitted to the IASGO World Congress September 9-12, 2018, Moscow, Russia

001

COMPREHENSIVE ASSESSMENT OF USING OF EXTRACELLULAR BOVINE-DERIVED PERITONEUM MATRIX FOR ABDOMINAL WALL DEFECTS REPAIR

N. Abatov¹, R. Badyrov¹, M. Tussupbekova¹, K. Abugaliev², V. Ogay³

¹Karaganda State Medical University, Karaganda, Kazakhstan

²National Scientific Center for Oncology and Transplantation

³National Center for Biotechnology

Introduction. A new biological implant was developed – the extracellular bovine-derived peritoneum matrix, obtained by a detergent-enzymatic method of decellularization. For the first time an experimental study of extracellular bovine-derived peritoneum matrix as a new biological implant for repairing abdominal wall defects is leaded.

Aim. To assess the structural changes of the implantation area after using the extracellular bovine-derived peritoneum matrix, and evaluate the biomechanical properties of the new implant in the experiment.

Materials & Methods. Open abdominal wall defect repair was performed in 32 white non-linear rats. Extracellular bovine-derived peritoneum matrices were 1,5*1,5 cm per one animal. Observation periods: 7, 21, 30, 180 days (n=8 in each group). The technique of staining with H&E, Van Gieson's stain with pikro-fuchin. Microscopical criteria were performed by an inflammatory response, connective tissue maturation. Morphometric analysis included the counting of granulocytes, lymphocytes, plasmacytes, macrophagocytes, fibroblasts/fibrocytes, out of a suture line. The evaluation of biomechanical properties was leaded by studying the tensile strength and elongation. Statistical analysis was performed using Kruskal-Wallis test, P value<0.05.

Results. On the 7th day, lymphocytic infiltration with the formation of a young granulation tissue was observed. Cellular infiltrate showed a predominance of granulocyte cells (42.50±3.94), which characterized the exudative phase of the tissue reaction in response to implantation, surgical trauma. By 21 days, the predominance of mature connective tissue, the germination of collagen fibers, both in the material and in the muscular mass was noted. There was a statistically significant decrease in cells of the exudative and

productive phases with the predominance of stromal cells (65.54±7.25), which indicated that there was no any reactive and percussive inflammation in the forming scar. By the 30th day collagenization of the implantation area, its organization into mature connective tissue was registered. By 180 days there was a stable connective tissue contact between the biomaterial and anterior abdominal wall. Morphometric analysis showed the continuing tendency of increasing the proportion of fibrocytes in relation to other cellular elements - 85.7±2.3. The result of the tensile strength evaluation was 5.56 N/mm², the elongation at break was 110%, which together showed high mechanical strength, mainly due to the elasticity of the material.

Conclusion. Using the extracellular bovine-derived peritoneum matrix, a stage-specific change in tissue reactions observes that characterizes the normal wound process. Possessing high mechanical strength, this material demonstrates adequate biocompatibility with the macroorganism in the experiment, with the formation of stable contact with tissues of abdominal wall and minimal tissue inflammatory responses.

002

THE ROLE OF PROTEOLYTIC ENZYMES AND MEDIATOR OF INFLAMMATION (SEROTONIN) IN THE TIGHTNESS OF THE SURGICAL REGION

Z. Abdulatipova, O. Vasnev, O. Knyazev, Yu. Orlova, I. Trubitsyna

King Faisal Specialist Hospital and Research Centre Jeddah, Russia

Introduction. The doctrine of wounds is one of the most important theoretical foundations of surgery. Surgical sutured wounds of the hollow organs of the gastrointestinal tract in connection with the development of surgery and its new technologies is an urgent problem. Complications in the form of anastomosis and insolvency seams developed on average 30% of patients.

Purpose of research. In the experimental conditions to establish the features of healing of the surgical wound of the mucous membrane (CO) of the stomach and intestines.

Material and methods. Experimental investigations were

carried out on white rats line Wistar with the mass 180 – 220 g. Animals were maintained in accordance with international GLP regulations. For anesthesia used ether anesthesia. Atanasiu animals were performed under ether anesthesia on the 3rd and 10th day after surgery. Used 35 animals on 5 in each group. The level of proteolytic activity in mucosal extracts was determined on the day of sampling. Proteolytic activity of extracts of mucosal homogenate was determined by the Anson M. method, crystalline bovine hemoglobin was used as a substrate. Proteolytic activity was determined at pH 1.5 and 4.5. The concentration of serotonin was determined by the method Bassalik L. S.

Results and discussion. It was found that the mucous membrane of the gastrointestinal tract contains a large number of lysosomal enzymes having proteolytic activity at pH = 3,5-4,5. In the control group of animals low level of proteolytic activity at pH=4,5 is determined. On the 3rd day after surgery, it increases by 70% and decreases the inhibitory ability of intercellular fluid. In a separate series of studies, 15 animals used allogeneic stem cell transplantation in rats at a dose of 3.5 and 5 million cells in 1 ml of saline as an anti-inflammatory drug. Was administered intraperitoneally, once and twice. Allogeneic stem cells reduces the inflammation reaction and contributed to the quality of healing of the wound.

Conclusion. Lysosomal enzymes enter the intercellular space in case of tissue damage, as a result of which the area of damage in the area of the operating wound is increased and cell biomembranes are damaged.

Summary. In the area of damage, damaging factors were identified. 1. Extra-and intra-tissue proteolysis, providing damage to the surrounding tissue. 2. Violation of blood flow in the area of surgery, reduces the protective properties of the tissue. 3. Inflammation increases the concentration of serotonin inflammation mediator. 4. The use of stem cell transplantation is a promising direction in regenerative medicine.

003

TICKING TIME BOMBS - ABDOMINAL PSEUDOANEURYSMS, 5 YEAR. EXPERIENCE AT A GOVERNMENT GENERAL HOSPITAL

T. Aditya Chowdary, Ch. Madhusudhan, K. Prashanth, S. Kumar Sepuri, B. Jaganmohan Reddy, M. Prasanna, T. Ravi Mohan, W. Ali, R. Pratap Reddy
Government General Hospital, India

Background. Visceral artery pseudo aneurysms are uncommon, but commonly cause complications. The splenic artery is most commonly affected. They usually develop secondary to pancreatitis with abdominal trauma being the second most common cause. Our aim was to analyze all the abdominal visceral arterial pseudo aneurysms, analyze their clinic-

pathological features, management and outcome.

Methods. The study was conducted in the Surgical Gastroenterology Department of Osmania Medical College and Hospital. All patients who were diagnosed to have a splenic artery pseudo aneurysm from the January 2012 to July 2016 were included in the study.

Results. A total of 15 cases were identified, splenic artery was to origin in thirteen and gastroduodenal artery in two. All patients were male, pancreatitis accounted for 14 (93.33%) and trauma for 1 (6.66%). All patients were symptomatic with abdominal pain (80%), GI bleed (66.66%) and fall in hemoglobin (66.66%) being the common symptoms. CECT with vascular reconstruction was the best investigatory modality to identify them. Angio-embolization was used in two patients with good outcomes. Percutaneous thrombin was used in one patient but unsuccessful. Surgery was used in 13 patients (distal pancreaticosplenectomy – 8, trans-pseudocystic ligation – 3 and direct aneurysm ligation – 1).

Discussion. Visceral arterial pseudo aneurysms are not as rare as previously thought and the incidence is rising as our threshold for imaging is falling. Their management is multi-disciplinary and depends on the resources available. All of them are invariably symptomatic and require intervention of some sort for a permanent control. The threshold to offer surgery should be low as the morbidity (26.66%) and mortality (6.66%) are relatively low.

004

LIVER RESECTION IN THE CHILD WITH ATYPICAL GIANT FOCAL NODULAR HYPERPLASIA AND DILATED RIGHT HEPATIC VEIN

D. Akhaldze, N. Merkulov, N. Uskova, E. Andreev, N. Ivanova, G. Rabaev, N. Grachev

Dmitry Rogachev National Research Center of Pediatric Hematology, Oncology and Immunology, Russia

Actuality. Focal nodular hyperplasia (FNH) accounts for less than 2% of liver tumors in children. It has specific radiological semiotics, in most cases making possible to differentiate FNH from other liver lesions. Surgical treatment of FNH is indicated only in the case of the presence of clinical manifestations.

The purpose of the study. To present the diagnosis and treatment case of giant atypical right liver lobe FNH with sharply dilated right hepatic vein in a 2 years 7 months old boy with initial signs of biliary hypertension and rapid growth of the tumor. In available foreign literature we found no corresponding observations.

Materials and methods. In December 2017, abdominal ultrasound did not show any pathology. Large liver lesion was find in July 2017 when asymmetry of the abdomen was noticed. Radiology studies revealed non-encapsulated lesion with smooth lobular contours of 123x86x109 mm, originating from 5 and 6 liver segments. After the intra-

venous contrast administration, the intensified enhancement of entire mass during arterial phase was noted. On venous and delayed phases the lesion became isodense to healthy liver parenchyma. Besides, a lot of arterial vessels feeding the lesion were revealed. Absence of a central scar in the lesion was regarded as the sign of atypical FNH. According to CT-volumetry, the volume of the lesion exceeded the volume of the right lobe of the liver on 350 ml. This explains the right hepatic vein dilatation up to 17 mm in diameter.

Results. Atypical resection of involved segments 5.6 of the liver was performed without preliminary diagnosis verification. Fresh frozen histology confirmed the FNH. Postoperative course was uneventful. During postoperative period, there was a temporary sharp deterioration of dynamic characteristics of the blood flow through the right hepatic vein, which were not manifested by clinical symptoms and laboratory findings. The patient was discharged in 7 days after surgery.

Conclusion. The main treatment option for symptomatic giant FNH remains surgery. CT and gadolinium-enhanced MRI, as well as evaluation of the hemodynamics of the lesion in different contrast enhancement phases, are crucial for the FNH diagnosis and allow to avoid a non-informative biopsy which appears inconclusive in more than 60% of cases.

005

PRELIMINARY REPORT OF PEDIATRIC LIVER TUMORS SURGERY PROGRAM IN DMITRY ROGACHEV NATIONAL RESEARCH CENTER OF PEDIATRIC HEMATOLOGY, ONCOLOGY AND IMMUNOLOGY

D. Akhaladz, N. Uskov, E. Andree, N. Merkulov, N. Ivanov, G. Rabae, N. Grachev

Dmitry Rogachev National Research Center of Pediatric Hematology, Oncology and Immunology, Russia

Actuality. Curative resection remains the main treatment option for primary and secondary pediatric liver tumors. Increasing incidence of liver neoplasms stimulated to start a hepatic surgery in the center of pediatric oncology.

The purpose of the study. To analyze short-term results and to present initial experience in benign and primary/secondary malignant tumors surgery in children in Dmitry Rogachev National Research Center of Pediatric Hematology, Oncology and Immunology.

Materials and methods: From June 2017 to May 2018 15 children (8 boys, 7 girls) aged from 4 months to 17 years (mean 53,2 months) underwent surgery. Various anatomical liver resections, including segmentectomies, sectionectomies and major hepatectomies were carried out for: different spread (PRE/POSTTEXT I-III) hepatoblastomas (n = 10), hepatocellular carcinomas (n = 2), nephroblastoma liver metastases (n = 1), rhabdoid liver tumor (n = 1) and giant

focal nodular hyperplasia (n = 1). Open procedures applied in 14 cases. 1 patient underwent combined laparoscopic hepatectomy and thoracoscopic right lung resection.

Results. The median blood loss volume was 50 ml [Q1 = 30; Q3 = 300]. Median duration of Pringle maneuver - 0 min [Q1 = 0; Q3 = 9]. Median time of total vascular exclusion came to 0 min [Q1 = 0; Q3 = 1,25]. The median hospital stay in surgical unit did not exceed 7 days [Q1 = 6; Q3 = 12]. Curative resection was achieved in all patients. Dindo-Clavien grade IIIa and IIIb complications were met in 1 and 2 cases, respectively. In other patients no morbidity was noted. There were no mortality in entire cohort of patients. The median follow-up time came to 4,6 months [Q1 = 2,2; Q3 = 8,20].

Conclusion: Achieved satisfactory short-term results inspire to further development of pediatric liver surgery program.

006

EXTENDED TOTALLY EXTRAPERITONEAL REPAIR (ETEP) FOR VENTRAL HERNIAS: THE RESULTS FROM A SINGLE CENTER

A. Akhmetov, V. Kashchenko, A. Lodygin, A. Mitsinskaya I.M. Mitsinskii

Sokolov Hospital No 122 FMBA of Russia, Saint-Petersburg, Russia

Saint-Petersburg State University, Saint-Petersburg, Russia

Introduction: Totally extraperitoneal technique has been successfully using for laparoscopic inguinal hernia repair for many years. Recently totally extraperitoneal approach (eTEP) has been adopted for the repair of ventral and incisional hernias. In this article we present the initial experience of eTEP in our centre.

Materials and Methods: Eleven patients have been enrolled in the study. The mean age was 55.3 years, BMI - 34.6 and ASA classification - 2. Four patients had large umbilical or epigastrium hernia, 4 patients had umbilical hernia and diastasis recti abdominis and 3 patients had recurrent ventral hernia. All patients had preoperative examination with computer tomography for estimation of anterior abdominal wall. Two methods were used: "upper" technique (4 ports on top) - 6 patients and "lower" technique (3 ports at the bottom) - 5 patients. Special position was on the back with the lowered footboard. After entering to the retromuscular space (position of ports was chosen according to the technique), the dissection was performed with the help of the balloon, and then additional ports were set. Then we made total tissue dissection (Rives-Stoppa) from ensiform process to the pubis, with the excision of the hernia sac. Then we stitched up the white line of the abdominal cavity layer by layer (V-loc 1/0). The defects of the lower part of anterior abdominal wall were also tightly stitched (V-loc or Ethibond 2/0). Polypropylene mesh "medium weight" was used in 9 patients and "light

weight " - in 2 patients (384-540 cm²). It was fixed with two stitches in one case; there were no fixation in other cases. We drained the retromuscular space for 1 day.

Results. Two patients had seroma (type 1). There were no repeated surgery (during 30 days) and common complications. According to EuraHS QoL scale for assessment quality of life: there was chronic pain in one patient. There were no movement limitations during 6-month follow-up period. There were no readmissions at mean follow-up.

Conclusion. We conclude the eTEP technique can be successfully adapted in centres with advanced laparoscopic skills and after appropriate training. Careful patient selection is of paramount importance. Early and relatively long-term results of the eTEP technique are promising.

007

PANCREATIC LYMPHANGIOMA

A. Al Breizat

Consultant General & HPB Surgeon - Chief of Surgical Specialty at M.O.H, Director of Jordanian Centre of Organs Transplantation Directorate, Amman, Jordan

Introduction. Pancreatic cystic lymphangioma is a rare benign type of cystic pancreatic lesions, were they are extremely infrequent and accounted for less than 1% of all lymphangiomas (less than 100 cases described since its first report by Koch in 1913), more frequently found in females (ratio 2:1), affecting all age groups with the same incidence. The majority are localized in pancreatic body or tail, Tumor size is variable, with diameter ranging from 3 to 20 cm (average 12 cm) largest reported cyst size is 26*23*11 cm. Usually it is asymptomatic, being discovered incidentally in radiological exams.

Materials and methods. Depending on their size, they can become symptomatic: the most common complaints are abdominal pain and palpable abdominal mass, followed by nausea, and vomiting. Although rarely, it can manifest as acute abdomen due to complications such as cyst rupture, volvulus, infection or intracystic hemorrhage. Weight loss, fever or pancreatitis are NOT usually associated with these lesions. Traditionally, an accurate diagnosis before surgery was difficult since imaging studies were not sufficient to characterize the lesion. Its differential diagnosis includes (pancreatic pseudocysts, serous and mucinous cystadenomas, intraductal papillary mucinous neoplasm, congenital neoplasms, pancreatic ductal carcinoma with cystic degeneration and echinococcal cysts).

Results. They didn't have any specific or significant laboratory abnormalities that confirm the diagnosis of pancreatic lymphangioma. Imaging exams such as plain abdomen X-rays, ultrasonography (US), CT or MRI can be helpful in the workup, however they cannot establish a definite diagnosis of lymphangioma to detriment of the other diseases

previously cited EUS is the optimal exam to reveal internal details of pancreatic lesions, with the advantage of allowing FNA of the cyst fluid for diagnostic purpose. A chylous aspirated fluid, with a milky-white appearance and an elevated triglyceride level is diagnostic of pancreatic lymphangioma; the levels of amylase and CEA are low in these cysts. Pancreatic lymphangioma can be also diagnosed by histopathology and supported by immunohisto-chemically with endothelial cell showing reactivity to factor VIII-R antigen, and CD31, CD34, D2-40. CD20 (B cell Marker) , CD3 (T cell Marker), and an intermixed population of B and T cells was positive for some reported cases, leukocyte common antigen (LCA) positive lymphocyte can be seen between the cyst spaces.

008

SURGICAL TREATMENT OF THE COLORECTAL CANCER METASTASES TO THE LIVER

R. Alibegov^{1,2}, O. Sergeev^{1,2}, I. Zhvitiashvili², T. Prokhorenko²

¹Smolensk State Medical University

²OGBUZ "Clinical Hospital No.1", Smolensk, Russia

Actuality. At the time of the diagnosis of primary colorectal cancer (CRC) 24-27% of patients already have metastases to the liver. Surgical treatment of metastatic CRC (mCRC) is the most effective method of treatment. Some issues remain unresolved: the rate of postoperative complications; the determination of the remaining tumor volume; treatment of acute liver failure.

The aim. To improve immediate and long-term results of treatment of mCRC to the liver.

Materials and methods. Total of 64 patients with mCRC had liver resection; 27 male/37 female; aged 34-74 (53,2 ± 7,3). I group - patients with extended resection (n=52); II group - segmental resection (n=12). Amongst I group: right hemihepatectomy (HHE) (n=19); extended right HHE (n=14), left HHE (LHHE) (n=16), extended LHHE (n=3). Amongst II group: segmentectomy SVII-VIII (n=1), segmentectomy SII,III,IVB (n=1), left lateral sectionectomy (LLSE) (n=3), right lateral sectionectomy (n=1), segmentectomy SIII (n=2). Non-anatomic resections - removal 3 to 8 foci (n=13). Laparoscopic LLSE (n=2), laparoscopic resection SIII (n=1). Laparoscopic assisted LHHE (n=2). Bilobar lesion (n=29). Metachronic mCRP (n=36), synchronous (n=28). Surgeries included removal of the primary tumor (n=11): anterior rectum resection (ARR) with segmentectomy SVII-VIII (n=1); ARR + segmentectomy SII,III,IVB (n=1); right hemicolectomy + LHHE (n=1); right hemicolectomy + non-anatomical liver resections up to 8 foci (n=5), sigmoid colon resection + LLSE (n=2), left hemicolectomy + SIII (n=1). Surgeries for relapsing mCRC (n=5). Two patients were operated with "Liver First" technique.

Results. Complications were noted in 26 (40.6%) patients.

Reactive pleurisy - 12 (18,8%), bile leakage - 8 (12,5%), acute liver failure - 2 (3,1%), wound infection - 2 (3,1%), bleeding from the liver stump - 1 (1,6%), acute jejunal perforation - 1 (1,6%). Two latter complications required re-laparotomy - 2 (3,1%). Mortality - 1 (1,6%). Long-term results: three-year survival rate - 43%; five-year survival rate - 28%. Relapse-free survival rate - 19%.

Conclusion. 1) Liver resection is the most radical method of treatment for mCRC which allows to increase life expectancy and to improve its quality. 2) Single-staged surgical treatment is not associated with significant increase in the rate of post-operative complications and mortality. 3) Use of laparoscopic technologies leads to significant reduction of the surgical trauma at the same time achieving marked reduction in the pain syndrome after surgery and are is more compatible with ERAS protocols.

009

PANCREATICOJEJUNOSTOMY OR PANCREATICO-GASTROSTOMY - WHAT IS A BETTER OPTION FOR PANCREATICODUODENECTOMY?

R. Alibegov^{1,2}, S. Kasumyan, I. Zhvitiashvili², O. Sergeev¹, T. Prokhorenko²

¹Smolensk State Medical University,

²OGBUZ "Clinical Hospital No.1", Smolensk, Russia

Relevance. Failure of pancreaticodigestive anastomosis (PDA) remains the leading complication of pancreaticoduodenectomy (PDE) with the rate of 2.5-12.2%.

Objective. To reduce the incidence of postoperative complications and mortality after PDE by improving the formation of PDA.

Methods. PDE (n = 167) - Whipple's procedure n = 90; pyloric preservation PDR n = 77. Male 68.2%; female 31.8%. The median age 54.3 ± 9.3 years. 146 cases of periampullary cancer including: pancreatic cancer n = 92 (63.1%), ampullary cancer n = 31 (21.2%), distal common bile duct cancer of n = 16 (10.9%), duodenal cancer n = 7 (4.8%). Chronic pancreatitis n = 21. Standard PDE - n = 112; extended PDE - n = 49. Resection of the mesenteric part of the portal vein - n = 21 (12.6%): circular resection n = 14, lateral resection n = 4, resection with the prosthesis (PTFE) n = 3. Reconstruction of the superior mesenteric artery n = 1. We retrospectively analyzed the immediate results of various types of PDAs. Initially, we used three techniques of pancreaticojejunostomy (PJ) (n = 63): "end-to-end" n = 23, "end-to-side" n = 23, "duct-to-mucosa" n = 17. External pancreaticostomy n = 15. Later, the original pancreaticogastrostomy (PG) (n = 76)

was developed and successfully introduced: invagination n = 45, "duct-to-mucosa" n = 31. PJ by Blumgart was introduced in 2016 (n = 12). We studied risk factors for the development of pancreatic fistula (PF): nosological form, consistency of the pancreas, diameter of the main pancreatic duct (MPD), use of octreotide, type of PDA. Two cohorts of the patents were analyzed. Control cohort (n = 63) - patients with PJ, and the study cohort (n = 76) - patients with PG. Mono- and multivariate analyses were used with the p confidence interval (≤ 0.05).

Results. Postoperative complications happened in 70 patients (42%). PF - 15 (9.0%): st. A-4, st. B - 5, st. C - 6. PJ failure n = 14 (22.2%), PG failure n = 2 (2.6%). In the cohort of the patients with PJ - postoperative complications n = 47 (74.6%), mortality n = 9 (14.3%). in the cohort of the patients with PG - 22 (28.9%) and 2 (2.6%), respectively. There was no mortality in the last 69 PDE cases. Multivariate analysis showed that the diameter of the MPD (p = 0.035671) was inversely related with the rate PF formation, and the use of PG (p = 0.007339) significantly reduced the risk of PF formation. In the group of the patients with PJ by Blumgart (n = 12) one complication was noted - acute fluid collection.

Conclusion. PG is a reliable and safe method in the reconstructive stage of PDE. The rate of postoperative complications and mortality with PJ was reduced to 28.9% and 2.6%, respectively. We had encouraging results with the first experience of PJ by Blumgart. This technique requires further investigation.

010

HEPATIC ARTERY RECONSTRUCTION FOR HILAR CHOLANGIOCARCINOMA. DOES IT INCREASE RESECTABILITY?

R. Alikhanov, M. Efanov, I. Kazakov, S. Iskhagi, P. Kim, A. Vankovich, D. Achaladze, V. Tsvirkun
Russia

Aim. To review our experience with reconstruction of the hepatic artery during radical resection of hilar cholangiocarcinoma, and to assess the resectability significance of this challenging surgery.

Methods: From 2004 to 2017 in Moscow Clinical Scientific Center was radically managed 82 patients with hilar cholangiocarcinoma. We retrospectively reviewed clinical data of 9 patients with advanced hilar cholangiocarcinoma who underwent hepatectomy with resection and reconstruction of the right or propria hepatic artery with or without portal

vein reconstruction, focusing on the type of hepatic artery reconstruction and surgical outcome.

Results: Hepatic artery was reconstructed with end-to-end anastomosis (n=5), using the autologous greater saphenous vein graft interposition (n=1), the autologous common hepatic artery graft transposition (n=1), or the gastroduodenal artery (n=2). Postoperative pathology showed R0 resection in 8(88,8%) patients, Complication rates by Clavien-Dindo-III-IV-40%. There was one postoperative death because of cholangiogenic sepsis.

Conclusions: Reconstruction of the hepatic artery can improve the radical resection rate of advanced hilar cholangiocarcinoma and is safe and feasible in selected patients.

011

EARLY POSTOPERATIVE REHABILITATION (FAST TRACK) AFTER LAPARO-THORACOSCOPIC RESECTION OF THE PROXIMAL STOMACH AND THORACIC ESOPHAGUS ABOUT CARDIOESOPHAGEAL CANCER

A. Allakhverdyan, A. Anipchenko

Surgery Department, Moscow Regional Research and Clinical Institute ("MONIKI"), Moscow, Russia

Introduction. An obstacle to the use of minimally invasive video-endoscopic approaches for radical surgical operations for cardioesophageal cancer is the need of resection and lymphadenectomy in the two anatomical areas. The resolution of the problem of injuries surgical accesses actualizes the problem of optimal postoperative management of these patients.

Aims & Methods. In 2015-17, we performed 27 resection of the proximal stomach and lower esophagus with one-stage intrapleural esophagogastroplasty a combined laparoscopic and right thoracoscopic access. Prevailed patients in III stage of disease – 14 (51,9 %) patients. In 4 cases (14,8 %) cases were identified with stage IV. R0 resection was performed in 24 (88,9%) patients, R1 – 3 (11,1 %). Histological examination was studied on average 42±3 lymph node.

Results. The advantages of radical operations for cardioesophageal cancer a combined laparoscopic and right thoracoscopic approaches: the clarity of the visualization, good control of hemostasis, ease of mobilization of the stomach and esophagus, early activation of patients in the postoperative period (4 days), reduced length of hospital stay (7.3 days).

Conclusion. The use of early rehabilitation after surgery technology (ERAS or "fast-track") allows to reduce the duration of hospitalization, accelerate recovery and rehabilitation of patients.

012

LAPAROSCOPIC AND LAPARO-THORACOSCOPIC RESECTION AND EXTIRPATION OF THE ESOPHAGUS IN IN PATIENTS WITH ACHALASIA

A. Allakhverdyan, A. Anipchenko

Thoracic Surgery Department, Moscow Regional Research and Clinical Institute ("MONIKI"), Moscow, Russia

Introduction. Evaluation of results of laparoscopic and laparoscopy-thoracoscopic resections, and resection of the esophagus in patients with achalasia.

Aims & Methods. The aim of study is assessing the results of resection operations with single-stage plastic of the esophagus in the treatment of 55 patients with achalasia. In 2014-17 24 (43,6%) patients the operation was performed videoendoscopic: 9 patients underwent laparoscopic transhiatal access, esophagogastric-anastomosis in the neck; 3 patients resection of the lower esophagus laparoscopic transhiatal access, esophagogastric-anastomosis at the mediastinum on the level of proksimal border retropericardial segment of the esophagus; 12 patients underwent combined laparoscopic and right thoracoscopic access (by Lewis). In the period 2004-16 31 (56,4 %) patients underwent resection of the esophagus by open abdominomedial access with esophagogastric-anastomosis on the neck. In 2 cases the operation was performed in cases of suspected malignant transformation; 27 with recurrence of achalasia after cardiodilatation (15) or esophagocardiomyotomy (12); in 26 cases in connection with the futility of organ-preserving treatment.

Results. After plastic surgery of the esophagus in patients with achalasia mortality was not noted. The failure of the esophageal anastomosis sutures on the neck was noted in 2 patients (3,6%). In 1 case after laparoscopic transhiatal of esophagectomy were marked point necrosis of the gastric transplant, revealed on the 6th day after surgery and treated with drainage of the left pleural cavity. In 1 case, stenosis was revealed of esophagogastricostomy - bougienage was successful.

Conclusion. Video endoscopic extirpation/resection of the esophagus with single-stage plastic is the method of choice in the treatment stage 4 achalasia, its recurrence after organ-saving surgery and cardiodilatation and cases with a high risk of aspiration pneumonia.

013

SUBTOTAL RESECTION OF THE ESOPHAGUS WITH ESOPHAGOGASTROPLASTY BY COMBINED LAPAROTHORACOSCOPIC ACCESS (BY LEWIS) IN CANCER, PRELIMINARY EVALUATION

A. Allakhverdyan, S. Anipchenko, A. Anipchenko

Thoracic Surgery Department, Moscow Regional Research and Clinical Institute ("MONIKI"), Moscow, Russia

Introduction. Analysis of immediate and 2-year results after subtotal esophageal resections with single-stage esophagogastroplasty by combined laparo-thoracoscopic access (by Lewis) in cancer.

Aims & Methods. In 2015-17 were performed 33 subtotal resections of the esophagus by combined laparoscopic and right thoracoscopic access. In 6 cases, the operation was performed after previous abdominal interventions. In all cases, a "manual" esophageal-gastric anastomosis was formed.

Results. R0 resection was performed in 31 patients. In histological examination, an average of 36 ± 3 lymph nodes were studied. Postoperative complications were noted in 4 patients. Local failure of esophageal anastomosis occurred in 2 patients. In 1 patient, the healing of the fistula anastomosis was noted for 4 weeks after drainage. Postoperative mortality in one patient. The average duration of the operation was 8 hours 36 minutes. The average duration of stay in the intensive care unit was 16 hours. Enteral nutrition after surgery was started on 4-5 days. The average post-operative bed day in patients without anastomosis suture failure was 8 days. Two-year relapse-free survival in patients (stage II-III) operated on in 01.2015-04.2016 was 68.8% (11/16).

Conclusion. The advantages of laparoscopy thoracoscopic Subtotal resection of the esophagus: the clarity of the visualization, good control of hemostasis, ease of mobilization of the stomach and esophagus, early activation of patients in the postoperative period, reduction of hospitalization. The full value of resection and lymph node dissection is not inferior to those in "open" operations.

(M / F=159/206; mean age 55.9 years). In 164 (44,8%) patients, was revealed short esophagus. In 137 (36.4%) of patients had HH without axial shortening of the esophagus. In 43 (11,7%) cases were mixed HH and 21 (5,7%) patients had paraesophageal HH. All operations were performed by laparoscopic access. Circular types of fundoplication were performed mainly (95,9%): according to Nissen 49 (13,4%) patients, according to Nissen-Rosetti 7 (1,9%), long symmetrical fundoplication according to the original method - in 294 (80,5 %) cases. Incomplete fundoplication was performed in 15 patients (1 - Blunt (0,3 %), incomplete oblique posterior-lateral fundoplication - 14 (3,8%). In 166 (45,5 %) cases was performed posterior crurography, in 2 (0,5%) – anterior crurography, in 7 (1,9%) - a combination of the posterior and anterior crurography. In 127 (34,8%) cases, posterior tension-free alloplasty of oesophageal hiatus with "onlay" mesh "light-weight" polyester implants was performed. When shortening of the esophagus of the II degree fundoplication cuff is not fixed to the diaphragm. Laparoscopic antireflux operations were performed in 45 (12,3%) cases after previous abdominal interventions. In 16 (4,5%) cases, the cause of repeated laparoscopic surgery was the recurrence of a hiatal hernias or reflux esophagitis.

Results. Dysphagia after surgery was detected only in 4,1 % (2/49) patients after fundoplication by Nissen. Postoperative complications were in 7 (1,9%). Including 1 (0,27%) patient with acute gastric ulcer perforation and 1 (0,27%) patient with acute adhesive intestinal obstruction. Within 1 year after the operation, complications were revealed in 11 (3,01%) patients: recurrence of gpod in 10 (2,67%) cases, postoperative trocar hernia in 1 (0,27%) case. All cases of recurrence of HH were recorded in the group of patients who did not perform alloplasty of the oesophageal hiatus.

Conclusion. In cases with moderate diastasis of the oesophageal hiatus, a posterior or combined crurography in combination with circular fundoplication is preferable. In cases with significant diastasis (>5 cm), diaphragm prosthetics is associated with a lower number of recurrences and cases of dysphagia; postoperative pain in the long-term period is expressed slightly. Posterior non-tension alloplasty of significant hiatus diastases in the absence of contact of sawn timber with the esophagus does not cause bedsores of the esophagus and intraluminal migration of the prosthesis.

014

PREVENTION OF RECURRENCE OF HIATAL HERNIAS AFTER LAPAROSCOPIC SURGERY

A. Allakhverdyan, A. Anipchenko

Surgery Department, Moscow Regional Research and Clinical Institute ("MONIKI") Moscow, Russia

Introduction. Improvement of tactics and technical aspects of laparoscopic surgery for hiatal hernias (HH) in order to prevent their recurrence.

Aims & Methods. In 2010-17 were operated 365 patients.

015

THE DETECTING OF BACTERIAL TRANSLOCATION WITH GREEN-FLUORESCENT PROTEIN-EXPRESSING ESCHERICHIA COLI STRAINS BY THE EXPERIMENTAL INTESTINAL STRANGULATION

D. Amanova, A. Lavrinenko, P. Ivachyov, Ye. Turgunov

Karaganda State Medical University, Karaganda, Kazakhstan

Background. The strangulation of the intestine is one of the

most often types of bowel obstruction which correlates with dramatically and rapidly complications, e.g. peritonitis, system inflammation reaction syndrome or sepsis arises a breakdown of the intestinal barrier function under the influence of local conditions. The aim of this study was a detecting of bacterial translocation phenomenon by the experimental model of intestinal strangulation with and without reperfusion using the Green-fluorescent protein-expressing strains (GFP-expressing strains) of E.coli.

Materials and methods. 10 male Wistar rats weighing 250-280g were divided into 2 groups; 5 rats with SO-model in the each group. The general anesthesia was provided by the 0,15 mg/g ketamine injection The 1,0-1,5 ml in the standard 3.0 dilution by McFarland of GFP-producing E.coli was injected in the rat's intestine via the oroduodenal catheter. The model of SO was created by the application of plastic clamps onto the intestinal loop and feeding mesenteric vessel. In the 1st group we made the reperfusion after 1 hour since modelling – It was a simulating the surgical treatment. The reperfusion period continued during the 6 hours. In the 2nd group we didn't construct a reperfusion. The extraintestinal organ samples such as intestine, mesenteric lymphatic nodes and liver, and then it was cultivated on the Luria-Bertani agar.

Results. After the 6 hours of reperfusion in the 1st group the macroscopic picture presented the regeneration of the intestinal vitality such as appearance of mesenteric artery pulsation and repairing of nature color of intestine wall. Also the growth of GFP-expressing E.coli from the intestine, mesenteric nodes and liver samples were registered in the 80% (4 animals) of rats in the 1st group. In fact, in the 2nd group the inconvertible ischemia and thrombosis of mesenteric vessels were observed. In this case the generation of GFP-strains was not determined in all of the samples.

Conclusion. To sum up, GFP-expressing E.coli could be used for detecting of bacterial translocation by the experimental SO. The preventive therapy of SO should be provide, because the high risk of BT without resection of intestine makes a lot of irreversible complications.

016

ABDOMINAL ACTINOMYCOSIS (CLINICAL CASE)

O. Andreytseva, R. Terekhova, I. Kukeev

A.V. Vishnevsky National Medical Research Center of Surgery, Moscow, Russia

Introduction. Actinomycosis is a chronic purulent disease, with the formation of specific granulomas in soft tissues and bones, followed by the formation of abscesses and the possible recurrence of fistulas during further development [1].

Case report. Patient X, 30 years old. From 2010-2011 were performed a multiple drainages of liver abscesses. In April 2012 relapsed of liver abscess, abdomino-bronchial fistula.

The abscess was drained, appointed course of antibiotic therapy. In October 2012 - a relapse of the abscess of the right lobe of the liver with abdomino-pleural fistula. In December 2012 was performed the operation: cryodestruction of the tumor node. Histological material: chronic abscess of nonspecific etiology. Microorganisms from the cavity of abscess were not revealed. After 1 month there was a relapse of the abscess in the right lobe of the liver with a size of 74x24 mm. A puncture of abscess was performed. Microorganisms from the abscess cavity were not revealed again. In April 2013 were found multiple abscesses of the right lobe of the liver. Right hemihepatectomy was performed. Detected Streptococcus sp. In May 2013 revealed an abscess in the area of resection, draining in the right subdiaphragmatic space. Detected Actinomyces sp. in a pus. After antibacterial treatment with amoxiclav the cavity of abscess was decreased and fistula closed. In April 2014 - another relapse. Actinomyces sp. detected again. The patient was treated with Amoxiclav 325 mg x 2 times a day for two months with subsequent withdrawal of the drug. A month later on the background of the abolition of therapy was detected the abscess of the subdiaphragmatic space. Amoxiclav was appointed again and was recommended a constant reception. In December 2017 (25 months after discharge) there was not data for relapse of abscesses. Antibiotic therapy have been continuing.

Conclusions. Actinomycosis should be excluded when liver abscesses recurring. The treatment of the disease is complex: surgical treatment, long-term antibiotic therapy. The sensitivity of actinomycetes to antibiotic therapy with penicillin does not change with the time. The duration of antibiotic therapy of actinomycosis requires further study.

017

ENDOSCOPIC HAEMOSTASIS WITH FIBRIN GLUE IN CIRRHOTIC VARICEAL BLEEDING

Gh. Anghelici, I. Panici, S. Pisarenco, O. Crudu, T. Zugrav, G. Lupu, V. Roman

Laboratory of Liver Surgery, Surgery Department Nr. 2 "C. Țibîrnă" State Medical University "N. Testemițanu", Chișinău, Republic of Moldova

Relevance. The recovery of patients with liver cirrhosis (LC) and acute variceal bleeding (AVB) are directly related to the efficiency and the primary endoscopic haemostasis performing time. The aim of the study was to estimate the efficiency of the endoscopic haemostasis (EH) with fibrin glue (FG) in acute variceal bleeding (AVB), and to evaluate the mortality rate in cirrhotic patients in relation to hepatic functional supplies (HFS) and the EH performing time from hemorrhage onset.

Materials and methods. This study included 1096 patients with LC and AVB, treated over 2003-2018 (Child A/B/C-

165/724/207). EH was performed with intravariceal FG injection up to the complete eradication of all variceal cordons. The mortality rate was analyzed in relation to the EH performing time from the AVB onset, and divided into 2 groups: I-<12 hours (471 patients), II-> 12 hours (625 patients).

Results. The AVB control was achieved in 1079 cases (98.4 %). In 17 patients (1.6%), the bleeding from the bottom gastric varices couldn't be stopped. No statistically valid relation was established between HFS and the mortality of patients with AVH controlled in the first 12 hours from its onset. 39 patients (8.3 %) died in this group due to an irreversible hemorrhagic shock. Meanwhile, we established a direct correlation with the grade of the HFS for the patients who received an EH later than 12 hours, the mortality in this group rising up to 22.9 % of the cases (143 patients). According to FHS, the death rate in stages Child A/B/C/ mounted to 8/85/50 patients, or 7.4%/20.3%/51.0%, respectively, caused by hepatic failure.

Conclusions. The recovery of cirrhotic patients with AVB is directly related to the efficiency of the primary EH performing time. EH with FG is an efficient method to control AVH in LC. The results of EH in the first 12 hours from AVH onset did not depend on the HFS, but were determined by the severity of the hemorrhage. The mortality of patients with AVH stopped later than 12 hours significantly increases and correlates directly with the grade of disturbance of the hepatic function.

018

COMPLEX MINI-INVASIVE SURGICAL CORRECTION OF REFRACTORY ASCITES IN PATIENTS WITH LIVER CIRRHOSIS

Gh. Anghelici, S. Pisarenco, O. Crudu, M. Danu, T. Zugrav, G. Lupu, V. Roman

Laboratory of Liver Surgery, Surgery Department Nr. 2 "C. Țibîrnă", State Medical University "N. Testemițanu", Chișinău, Republic of Moldova

Introduction. The emergence of refractory ascites in a patient with liver cirrhosis aggravates the prognosis of the disease and presents considerable difficulties for treatment. Evolution of resistant ascites is closely interrelated with the processes of violations of peritoneal absorption and blockage of lymph circulation.

Objective. To determine the possibilities of surgical correction of refractory ascites in patients with decompensate liver cirrhosis by laparoscopic sanitation with postoperative fractional rinsing of the abdominal cavity, supplemented with simultaneous decompression of the thoracic lymphatic duct.

Materials and methods. Over the period from 2014 to 2018, 98 patients underwent surgery in the clinic (53 men (54.1%) and 45 women (45.9%), aged 29 to 71 years) for cirrhosis with massive refractory ascites Child C (9-10), without explicit signs of hepatic encephalopathy. The main etiological factors were,

as follows: viral hepatitis C -47pts (48.0%), B -29 pts (29.6%), B+D-17 pts (17.3%), and toxicity - 5 pts (5.1%). To prevent possible bleeding at the first stage, endoscopic filling of esophageal varices with fibrin glue was performed in 81 patients (82.7%). After controlling the effectiveness of varices filling, after 5-7 days the lap was used for laparoscopic sanitation of abdominal cavity with complete evacuation of ascites fluid, intra-operational rinsing and drainage of the abdominal cavity. Simultaneously, a decompression surgery of the thoracic lymphatic duct was performed to improve liver lymphatic drainage. Fractional post-operational rinsing was repeated for 3-5 days with the purpose of removing the edema of the peritoneum and improving its re-absorptive properties. Evaluation of results was performed 3, 6 and 12 months after surgical intervention.

Results. The post-operational lethality from the progression of liver failure mounted to 5.1% (5 patients). 7 other patients died over the following 3-6 months, due to the same cause. The annual survival rate was 87.6%. Complete regression of ascites over the following post-operational 3-12 months was noted in the majority of patients - 53 (55.8%), significant regression and stabilization in 25 (25.6%), moderate regression with the need for periodic decompressive laparocentesis in 8 cases. In all patients, the functional reserves of the liver and the quality of life were significantly improved.

Conclusions. The use of the developed technique of correction of refractory ascites in patients with depleted liver cirrhosis by laparoscopic sanitation with postoperative fractional rinsing of the abdominal cavity, supplemented with simultaneous decompression of the thoracic lymphatic duct, showed very high efficiency and deserves establishment as a clinical practice.

019

ACUTE SUPPURATIVE APPENDICITIS IN CHILDREN WITH MALIGNANT TUMORS OF THE CENTRAL NERVOUS SYSTEM DURING RADIATION TREATMENT (RT) WITH CHEMOTHERAPY

F. Antonenko, O. Scherbenko, O. Zheludkova, E. Slobina, A. Kryanev, E. Abbassova, R. Parkhomenko, N. Zelinskaya
Federal State Budgetary Institution "Russian Scientific Center of Roentgenology" of the Ministry of Health of Moscow, Russia

Relevance. In accessible domestic literature, we did not find a description of cases of purulent appendicitis development in children with malignant tumors of the central nervous system during the radiotherapy. At the same time, abdominal pain, constipation, intestinal paresis on the background of the chemotherapy they perform during this period of treatment is noted in 60-75% of cases.

Purpose. To draw the attention of the doctors of radiotherapists, pediatric oncologists and pediatric surgeons to

the fact that in children during radiation treatment (RT) there can be acute destructive appendicitis and acute intestinal obstruction, which require early diagnosis and patient's transfer to the surgical hospital.

Material and methods. More than 4000 children aged 2 to 18 years with malignant tumors of the central nervous system received radiotherapy in the children's radiotherapy department in the Federal State Medical Center "Russian Scientific Center of Roentgenoradiology" of the Ministry of Health of the Russian Federation for the last 20 years. Until 2013, the treatment was performed on the gamma-therapeutic apparatus "AGAT-P1" and on the linear accelerator "Phillips SL75. Since 2013, modern 3D conformal radiotherapy is being implemented using the latest generation of linear accelerators, such as Truebeam, Clinac 2100, Unique, including high-precision techniques (IMRT, VMAT, IGRT). In accordance with international protocols for combined treatment of patients, all our patients were admitted to radiation therapy after surgical interventions and after chemotherapy in specialized clinics of neurosurgery, onco surgery and onco-hematology.

Results. In 4 out of 4,000 patients, we observed a clinical picture of acute appendicitis, which was characterized by a constant, undeveloped abdominal pain that did not pass from antispasmodics, dubious symptoms of muscle tension in the anterior abdominal wall with deep palpation in the right ileal region. After 16-24 hours from the onset of the disease, the children were transferred to a specialized department of emergency pediatric surgery. Of the 4 patients, one after laparoscopy, acute appendicitis was excluded and appendectomy was not performed. Two days later he returned to RT. The second patient under laparoscopy was found secondary (catarrhal) appendicitis, which was removed. The patient did not return to radiotherapy. After the operation his condition worsened and he was transferred to the department of oncology, where he died on the background of chemotherapy. The following two children under laparoscopy were found destructive appendicitis with perforation of the appendix wall, which in one case was removed, and the other patient was partially removed, followed by drainage of the inflammatory infiltrate bed. In both of these patients, surgeons found stool stones that fell from the appendix into the free abdominal cavity. One of these patients did not return to RT, his condition worsened, he died on the 23rd day after the operation. In the second patient after antibacterial therapy, the appendicular infiltrate underwent a reverse development and he enrolled in RT 3 months after the operation.

Conclusions: In radiotherapy against a background of concomitant chemotherapy in children with malignant tumors of the central nervous system, in 0.4% of cases, acute appendicitis may develop, which requires early diagnosis and surgical intervention. Given that surgery on the abdominal organs critically increases the risk of recovery of such patients, it is advisable to apply diagnostic laparoscopy and, in cases of unconfirmed destructive appendicitis, appendectomy is not performed. The clinical

picture of acute purulent appendicitis in children with radiation therapy is not expressed, the symptoms of peritonitis are erased, the symptoms of tension in the muscles of the anterior abdominal wall are doubtful, there are no leukocytosis and neutrophilia in the blood tests, as the complication develops against the background of sharply reduced morphological reactions in view of ongoing chemotherapy, immunotherapy and hormone therapy. The only symptom and complaint remains constant pain in the abdomen. In this regard, the diagnosis should be based on clinical observation in the dynamics and mandatory ultrasound examination of the abdominal cavity, which allows verifying the topography and destruction of the appendix.

020

INTERDISCIPLINARY ASPECTS IN THE COMBINED TREATMENT OF BENIGN TUMORS OF THE BASE OF THE SKULL AND BRAIN IN CHILDREN IN RADIOLOGICAL CENTERS OF RUSSIA

F. Antonenko, O. Scherbenko, O. Zheludkova, E. Slobina, A. Kryanev, E. Abbassova, R. Parkhomenko, N. Zelinskaya, O. Regentova, K. Syroleva

Federal State Budgetary Institution "Russian Scientific Center of Roentgenology" of the Ministry of Health of Moscow, Russia

Relevance: According to literature data and our practical experience, the effectiveness of modern precision 3D conformal radiation therapy (IMRT, VMAT, IGRT), with recurring benign intracranial tumors and skull base tumors in children is unquestionable. At the same time, there is a problem of untimely sending such patients to radiotherapy in X-ray centers, which is due to the lack of consistency of the doctors involved in the combined treatment of such patients.

Purpose: to draw the attention of radiotherapists, radiologists, pediatric oncologists, endocrinologists, neurosurgeons to interdisciplinary problems in combined treatment of children with benign tumors of the skull and brain base (angiofibromas, craniopharyngiomas, hemangiomas) in Russia.

Material and methods: the optimal total dose for radiotherapy (RT) of benign head tumors in children was scientifically justified in the Federal State Budgetary Institution "Russian Scientific Center of Roentgenology" of the Ministry of Health of Russia, Moscow, for the first time in the beginning of the nineties. The studies were carried out on a gamma-therapeutic apparatus "AGAT-P1" and on a linear accelerator "Phillips SL75" with irradiation from 2 side fields (total dose 35-45 Gy). Over the 17 years from 1990 to 2007, 88 children with angiofibroma were treated, up to 80% of patients had a 5-year stable remission. The following were identified: a high risk of tumor recurrences after radiation therapy in children under 8 years of age, complications in 10% of patients in the coming years after RT and 100% reirradiated. During the last 5 years (2014-2018) we treated 27

patients aged 3 to 17 years with benign tumors of the base of the skull and brain (angiofibromas, craniopharyngiomas, hemangiomas) with precision modern 3D conformal radiotherapy (IMRT, IGRT) on linear accelerator "Truebeam", "Clinac 2100", "Unique". Fifteen of 27 patients were repeatedly operated in various domestic and foreign clinics and entered for the RT after reoperation and multiple selective angio-embolizations.

Results: in all 27 cases of RT in children, we observed a positive clinical effect - stopping bleeding from the nasopharynx after 1-3 sessions of 3D conformal radiation (dose per fraction 1.8 Gy, total dose 45-54 Gy), positive clinical symptoms under the supervision of otorhinolaryngologist, the effect of sclerosing and stopping the growth of tumors on MRI in 3 months, 6 months, 1 year. All patients were discharged in satisfactory condition, there were no complications of RT. At the same time, it is noteworthy that operations in patients with angiofibroma of the base of the skull have been performed mainly by neurosurgeons (88%) in the last 15 years, whereas in past years these operations were performed as a rule by head and neck surgeons. With late terms for radiotherapy after surgery, children with craniopharyngiomas in 50% were sent after surgery. They were observed independently by operating neurosurgeons and were not sent in time to pediatric oncologists. Of the 27 patients, 5 were given with a relapse of tumor growth after repeated neurosurgical interventions and selective angio-embolization in angioplasty centers. Unlike malignant tumors of the central nervous system in children, where there is continuity in multidisciplinary treatment among pediatricians, children's oncologists, neurosurgeons, radiotherapists, there is no such interdisciplinary approach among physicians in combination therapy in children with benign head tumors. Often such patients are not sent in time by neurosurgeons and head and neck surgeons to a pediatric oncologist and a radiotherapist, which causes their late admission to radiotherapy.

Conclusions: In modern conditions, 3D conformal remote radiation therapy on linear accelerators of the latest generation by the methods IMRT, VMAT, IGRT is an effective method of treating relapses of benign skull base tumors in children. The absence in Russia of a list of high-tech medical care for radiation treatment of benign head tumors in children limits the availability and timeliness of radiation therapy for these patients on a budgetary basis. Although the development of minimally invasive surgical technologies in the last 30 years has reduced the number of patients with benign skull base tumors sent for radiation therapy, but in 6-10% of patients there are relapses that can be prevented by timely radiation treatment.

021

COLLAGEN GEL DROPLET-EMBEDDED CULTURE DRUG SENSITIVITY TEST PREDICTS ADJUVANT CHEMOTHERAPY EFFICACY IN PANCREATIC CANCER

Kyohei Ariake, Fuyuhiko Motoi, Masamichi Mizuma, Hideo Ohtsuka, Hiroki Hayashi, Kei Nakagawa, Tatsuo Hata, Takeshi Naitoh, Michiaki Unno

Department of Surgery, Tohoku University Graduate School of Medicine

Background: Adjuvant chemotherapy was recommended after curative resection for pancreatic cancer (PC). However the efficacy of chemotherapy could not be estimated before treatment was started.

Purpose: We evaluated the clinical relevance of collagen gel droplet-embedded culture drug sensitivity tests (CD-DSTs) to predict the efficacy of adjuvant chemo-therapeutic treatments for PC.

Methods: We retrospectively reviewed the clinicopathological characteristics and prognoses of 88 PC patients who underwent CD-DST after pancreatectomies at Tohoku University between 2012 and 2016. Eligible patients had resectable or borderline resectable PC, were evaluated for 5-fluorouracil sensitivity successfully using CD-DST, and had received S-1 adjuvant chemotherapy.

Results: The successful evaluation rate for CD-DST was 52.3%. CD-DST was evaluated by T/C ratio which was calculated as the ratio of the number of cancer cells in the treatment group (T) to that of the control group (C). Receiver operating characteristic curve analysis revealed that the optimal T/C ratio of 5-fluorouracil should be 85% (area under the curve, 0.719) to predict recurrence of PC after adjuvant chemotherapy. The sensitive group (5-fluorouracil T/C ratio < 85%; n = 18) had a higher recurrence-free survival rate compared with the resistant group (5-fluorouracil T/C ratio ≥ 85%; n = 14) (P = 0.036) or non-adjuvant chemotherapy group (n=29) (P = 0.026). Sensitivity to 5-fluorouracil was an independent predictive risk factor for recurrence in multivariate analysis (hazard ratio: 3.05; 95.0% CI: 1.17-8.39; P = 0.022).

Conclusions: CD-DSTs could help predict PC recurrence after S-1 adjuvant chemotherapy.

022

THE ADVANTAGES OF LAPAROSCOPIC CYTOREDUCTIVE SURGERY FOR METASTATIC COLON CANCER

A. Atroshchenko, I. Khatkov, S. Pozdnyakov, M. Danilov, Z. Abdulatipova, G. Saakjan

"The Loginov's Moscow Clinical and Scientific Center", Colorectal surgery Department, Moscow, Russia

Background. Colon cancer (CC) one of the most common

oncological disease in World. Up to 30% patients in Russia have metastatic CC at first visiting to oncologist. The treatment results still controversial. Nowadays, minimally invasive laparoscopic precision technique allowed extending the indication for cytoreductive surgery even in patients with severe comorbidities

Purpose. To improve treatment results of metastatic colon cancer.

Materials and methods: 89 patients with colon cancer (T1-4a) and curable synchronous distant metastases include in study. All patients underwent cytoreductive surgery with primary tumor resection. In study group (44) we performed laparoscopic surgery, in main group (45)– open surgery procedure. The groups were similar by sex, age, tumor localization and histological structure, comorbidities.

Results. R0 resection performed 27% patients. The average number of lymph node removal was similar 13 and 12 respectively. Average operation time was significantly longer in study group 210 vs 120 min. In study group blood loss was lower: 300ml vs 1200ml. Postoperative patient recovery shorter after laparoscopic surgery ($p<0.05$): time to activation 2.2 vs 3.9 days; time to first peristalsis- 1.8 vs 4.5 days; first bowel movement- 3.4vs 4.8 days; first food taken- 2.9vs 3.9 days. Shorter time of analgesics intake- 2.3 vs 4.4 days, $p<0.05$. Hospital stay shorter: 9.3vs 13.4 days, $p=0.05$. Time to start chemotherapy reduced since 27.5 to 14.7 days, $p<0.05$. Postoperative complications lower in study group: 6.8 vs 17.8%, $p=0.05$. Kaplan-Meier 2-year overall survival were similar: 69.5% vs 61.6%, $p=0.96$.

Conclusion. Laparoscopic cytoreductive surgery for metastatic CC is safe, minimized surgical trauma and speed up patient recovery.

023

LAPAROSCOPIC CYTOREDUCTIVE SURGERY FOR METASTATIC COLON CANCER - HOW TO IMPROVE TREATMENT RESULTS

A. Atroshchenko, S. Pozdnyakov, M. Danilov, Z. Abdulatipova, G. Saakjan

Moscow Clinical and Scientific Center, Moscow, Russia

Background. Colon cancer (CC) one of the most common oncological disease in World. Up to 30% patients in Russia have metastatic CC at first visiting to oncologist. The treatment results still controversial. Nowadays, minimally invasive laparoscopic precision technique allowed extending the indication for cyto-reductive surgery even in patients with severe comorbidities.

Materials and methods. 89 patients with colon cancer (T1–4a) and curable synchronous distant metastases include in study. All patients underwent cytoreductive surgery with primary tumor resection. In study group (44) we performed laparoscopic surgery, in main group (45) - open surgery

procedure. The groups were similar by sex, age, tumor localization and histological structure, comorbidities.

Results. R0 resection performed 27% patients. The average number of lymph node removal was similar 13 and 12 respectively. Average operation time was significantly longer in study group 210 vs 120 min. In study group blood loss was lower: 300ml vs 1200ml. Postoperative patient recovery shorter after laparoscopic surgery ($p<0.05$): time to activation 2.2 vs 3.9 days; time to first peristalsis- 1.8 vs 4.5 days; first bowel movement- 3.4vs 4.8 days; first food taken- 2.9 vs 3.9 days. Shorter time of analgesics intake- 2.3 vs 4.4 days, $p<0.05$. Hospital stay shorter: 9.3vs 13.4 days, $p=0.05$. Time to start chemotherapy reduced since 27.5 to 14.7 days, $p<0.05$. Postoperative complications lower in study group: 6.8 vs 17.8%, $p=0.05$. Kaplan-Meier 2-year overall survival were similar: 69.5% vs 61.6%, $p=0.96$.

Conclusion. Laparoscopic cytoreductive surgery for metastatic CC is safe, minimized surgical trauma and speed up patient recovery.

024

THE FLUORESCENT ESCHERICHIA COLI AS MARKER OF BACTERIAL TRANSLOCATION BY EXPERIMENTAL MESENTERIC ISCHEMIA

I. Azizov¹, D. Amanova², A. Lavrinenko², Ye Turgunov²

¹Smolensk State Medical University, Smolensk, Russia

²Karaganda State Medical University, Karaganda, Kazakhstan

Actuality. Mesenteric ischemia (MI) is a surgical emergency caused by a transient reduction in blood perfusion to the bowel. Despite accounting for only 0.1% of hospital admissions its clinical expression often lead to high mortality rates. The important role in developing of ischemia complications belongs to bacterial translocation to the organs and system. **The aim.** We aimed to investigate the fact of microorganism's translocation by the experimental ischemia with following reperfusion using the fluorescent strains of E.coli (GFP-expressing E. coli) as a marker.

Materials and methods. The 10 male Wistar rats were divided into 2 groups; 5 rats in each group were anaesthetized using an intramuscular injection of ketamine (0, 15 mg/g). In the 1st "ischemia-reperfusion" group animals underwent 60 minutes of superior mesenteric artery (SMA) occlusion, followed by 6 hours of reperfusion, and in the 2nd one- the 5 rats with 2 hours-ischemia and following reperfusion for 6 hours. The model of MI was created by clamping of SMA under general anesthesia. The injection of GFP-strains was made by oroduodenal catheter in standard 3,0 dilution by McFarland in 1,0-1,5 ml dose. The straight fluorescent microscopy of homogenized extraintestinal organ samples (liver, intestine and mesenteric nodes) was provided. Also the homogenized organ samples such as intestine, mesenteric nodes and liver were cultured on

the Luria-Bertani agar media supplemented with ampicillin for detection of GFP-expressing *E. coli*.

Results. After 1 hour of ischemia and reperfusion we observed the reparative proceeding of blood-circulation in the intestinal wall and mesentery. Nevertheless, in the 2nd group after 2 hours of ischemia the irreversible macroscopy changes (total ischemia, thrombosis and necrosis of local parts of intestine) were examined. The straight bacterioscopy of homogenized samples didn't give the value results and GFP-expressing *E. coli* was not found in both of group. However, in 60% of the 1st group animals the colony of GFP-expressing *E. coli* was found in all of the experimental organ samples by the microbiological analysis. The rats with 2 hours of ischemia were presented no-colonization of GFP-producing strains. It relates with general thrombosis of mesenteric vessels and lacking of the bacterial translocation.

Conclusion. In conclusion this research demonstrates the efficiency of using GFP-producing *E. coli* for detection of bacterial translocation by the experimental model of MI. Besides, the cultivating of homogenized organ samples with subsequent microbiological analysis more preferred for detection of bacterial translocation by the mesenteric ischemia.

025

CONTACT NANO-ELECTROIMPULSE LITHOTRIPSY WITH TRANSFISTULAR CHOLEDOCHOSCOPY

A. Babak¹, E. Mozhaeva¹, D. Raskovalov¹, I. Andrienko¹, M. Prudkov²

¹*Sverdlovsk Regional Clinical Hospital No 1, Yekaterinburg, Russia*

²*General Surgery Department of Ural State Medical University Yekaterinburg, Russia*

Relevance. Transfistular cholelithotomy makes it possible to perform contact lithotripsy and removal of gallstones without destroying the sphincters of the major duodenal papilla (MDP). Electrohydraulic lithotripsy (EHL) is most often used. In 2003, Russian developers proposed a new method of crushing stones by electric impulses of nanosecond duration, which has several advantages over EHL. Nanoelectroimpulse lithotripsy (NEIL) uses a flexible probe containing 2 isolated coaxially electrodes. When the probe head contacts the stone, an electrical impulse is applied to the electrodes. With electrical impulses of nanosecond duration, a solid dielectric has a lower breakdown resistance than an aqueous medium. Therefore, at NEIL, in contrast to EHL, an electric breakdown, creating a shock wave, occurs not in the liquid, but in the thickness of the stone. For the destruction of stones with NEIL requires fewer impulses and a less total energy is released than with EHL. NEIL is already used to crush urinary stones. Data on the use of NEIL in the treatment of cholangiolithiasis in the sources available to us

are absent.

Object. The aim of the study was to evaluate the possibilities of NEIL with transfistular cholelithotomy in the treatment of cholangiolithiasis.

Materials and methods. 66 patients with bile duct stones were treated in our clinic from 2013 to 2016. All patients had previously performed cholecystectomy and drainage of the bile ducts. The age of the patients ranged from 30 to 89 years. 20 patients were men, 46 were women. We used an Olympus CHF T20 fibroscope with an outer diameter of 6 mm and an instrumental channel of 2.6 mm. A nanoelectroimpulse lithotripter "Urolit" with probes with a diameter of 1.2 mm, manufactured by Medline Ltd. (Tomsk, Russia), was used to break down the stones. The probe for NEIL was conducted through the instrumental channel of the cholelithotomy. The impulse power was 0.6-1 J. The number of impulses per 1 operation ranged from 5 to 25. Movable gallstones and their fragments after lithotripsy with a diameter of less than 6 mm were removed using metal baskets. Large and/or immobile stones were crushed to NEIL.

Results. The size of the stones was from 5 to 28 mm. Stones in 48 patients were crushed in 1 stage, in 14 patients – in 2 stages and in 4 patients – in 3 or more stages. Post-lithotripsy migration and wedging of fragments of stones in the ampulla of the MDP occurred in 4 cases. These patients were performed endoscopic biliary sphincterotomy (EBS) to move stones to the duodenum. 3 EBS were performed for papillary stenosis. There were three cases of failure. In 2 patients it was not possible to contact the lithotripter probe with the intrahepatic duct stone. In one case, fistula loss occurred. All 3 patients underwent cavity operations. Lithotripsy was successful in 63 patients (95.5%). Technical efficiency of lithotripsy was 100%.

Conclusions. Transfistular cholelithotomy with NEIL is a new highly effective and safe method of crushing gallstones.

026

TELECOMMUNICATION CONSULTING WITH MINIMAL FINANCIAL COSTS

K. Baburin

Far Eastern Telemedicine Center, Computing Center, Far East Division, Russian Academy Khabarovsk, Russia

Background. In the Far Eastern Telemedicine Center, established in 2000 as a structural subdivision of the Far Eastern State Medical University, more than 1,600 teleconsultations were conducted, mainly from the Far Eastern Federal District. Teleconsultations are performed in the off-line mode and only 6 videoconferences (on the equipment for the videoconferencing station in the FEMU IC). Until 2009, FECTM had a dial-up connection to the Internet. Until now, broadband coverage is only 60% of the entire territory of the Far Eastern Federal District. For example, in Koryakia of the

Kamchatka Territory (CRG of the village of Oszora and Palana) there is dial-up access with a speed of up to 10 kbit/s and not every day, in Magadan and high-speed Internet area is still unavailable for many MO, in the Chukotka Autonomous Okrug in the District Hospital to 100 kbps. Nevertheless, only outpatient clinics, FAPs and some district hospitals of the DFO regions are not covered by the Internet.

Material and methods. Even with a minimal set of equipment and any available communication channels, it is possible to conduct asynchronous consultations, which in 60-80% of cases is sufficient to meet the goals of subscribers, and if you still use video telephony, then the percentage of need for VCS is much lower. Now in telemedicine of Russia there are two main problems: 1. Limited funding 2. Lack of legal framework. The first problem is completely solved. PCs of low power for office purposes (and accordingly low cost) with a standard set of office programs, including freely distributed via the Internet (even a viewer for dicom format images can be downloaded free of charge!) - it is quite suitable for telemedicine purposes. In many FEFD MOs (and not necessarily rural, even in Khabarovsk), the only PC with access to the Internet is in the reception of the head physician, in the bookkeeping or office, i.e. on it perform different office work, and not just teleconsultations, which dramatically reduces the cost of teleconsultations for this MO. The flatbed scanner for office needs also exists in almost all MO. If the scanner does not have a slide adapter, then an inexpensive digital camera (4.0 thousand rubles) or a mobile phone with a good resolution and a negatoscope for digitizing film carriers and for receiving photos is also not a problem. And if there are simple audio speakers (350 rubles) and a microphone (90 rubles) with a video camera (600 rubles), then video telephony is possible (for example, Skype, in which half of the consultants have accounts).

Results. We carried out all consultations free of charge. The consultants were the staff of the Far East State Medical University, the staff of the research institutes, the National Center of Higher Education, universities and clinics of the central regions of the country, participants in medical Russian and international Internet forums, practitioners of health care, consultants from near and far abroad. We advise without contracts, i.e. only with those MOs who provide services for free. Foreign consultations we organize in some forums (eg Orthoforum Ural NIITO), when applying to the MO and the Foundation for Developing Countries (Swinfen Telemedicine Network, Dene House, Wingham, Nr Canterbury, Kent CT3 1NU, United Kingdom, <http://www.swinfencharitabletrust.org/>). In this fund, experts with world names consult (Great Britain, New Zealand, USA, Germany, Australia, etc.); answer, as a rule, within 1-2 days. A strict condition for registration in the fund - consultations should be free for subscribers. When registering, basic data about your organization and 2-3 subscribers (in our case, DFO hospitals) are indicated. The only problem is that the extracts must be translated into English, we use a computer translation (not very high quality), so we tried to send an extract with a minimum of text to the fund, for example. on

traumatology-orthopedics, dermatology. It is curious that Russian organizations registered in the fund only 1-2 (from the Volga Federal District).

027

SCLEROSIS AND ATROPHY OF THE GALL BLADDER AS RISK FACTOR IN PATIENTS WITH CHRONICAL CALCULOUS CHOLECYSTITIS

E. Baichorov¹, V. Greyasov^{1,2}, N. Sivokon², M. Agapov²

¹Stavropol State Medical University, Chair of surgery and endosurgery, Stavropol, Russia

²Public Clinical Hospital of the city of Essentuki, Essentuki, Russia

Relevance. Prolonged a-functional state of the gall bladder (GB) leads in certain cases to sclerosis of the hepato-duodenal ligament that complicates cholecystectomy in patient with chronic calculous cholecystitis. The impact of morphological alterations in the sclerotic and atrophic GB on the complexity of cholecystectomy has not been studied deep enough.

Goal. Study of the impact of gall bladder sclerosis and atrophy (GBSA) on the frequency and character of complications after elective laparoscopic cholecystectomy.

Material and methods. A retrospective analysis was made of the results of the examination and treatment of 14764 patients with chronic calculous cholecystitis who had undergone laparoscopic cholecystectomy in the Essentuki Public Clinical Hospital. The causes of intraoperative and postoperative complications were studied and certain were selected: e.g. injuries of the extrahepatic bile ducts and bleeding within the boundaries of surgical invasion. Factors having the most impact on the number of such complications were determined. A special group of patients with GBSA was selected in accordance with the results of ultrasonic survey (diminishing size less than 4x3 cm, sclerosis or thickening of the wall in excess of 0.3 cm, lack of gall and filling of the bladder with concrements) confirmed by the cytological examination of the deleted GB. There were 607 (4.1%) of such cases. From 2010 all patients with GBSA symptoms after US testing would undergo MRI with hepatic duct contrasting or retrograde cholangiography to confirm the diagnosis and rule out pathology in the extrahepatic bile ducts.

Results. Complications after elective LCE were observed in 46 (0.31%) patients, with 37 (80.4 %) cases among those who had BGSA. Injuries of extrahepatic bile ducts with symptoms of bile leakage were found in 38 (0.25%) patients. In 17 (44.7%) patients from that group bile leakage was observed during the separation of the sclerotic GB from liver tissues. Hematoma in the retrohepatic space in the postoperative period was observed in 9 cases (0.06%), out of which 7 (77.7%) were patients with GBSA. In 8 (0.05%) patients we

revealed complete dissection of the common bile duct. In 6 of those LCE was performed with GBSA symptoms present. In 4 cases we observed GBSA combined with Mirizzi syndrome type 2-3 according to Csendes which had not been diagnosed before the operation.

Conclusions. GBSA should be considered as a risk factor for LCE complications in cases of chronic calculous cholecystitis. Among the iatrogenic injuries of the extrahepatic bile ducts in patients with GBSA cases of complete mechanical dissection of the common bile duct prevail. This fact should be accounted for by the deformation of the hepato-duodenal ligament structures which increases the risk of faulty interpretation of its elements. This is why it would be relevant to place patients with GBSA symptoms in the separate risk group. A separate guideline should be developed to deal with this group to eliminate iatrogenic complications in elective cholecystectomy.

abscess was ruptured during the operation. In 4 cases, because of Mirizzi syndrome, the partial reconstruction of CBD with external drainage performed. Conversion to open surgery was performed in 1 case. Recurrent choledocholithiasis observed in 2 cases (group I). In group II, frequency of complications of ERCP/S was 4.7% (3 cases), as acute pancreatitis (2 cases) and severe papillary bleeding (1 case). These complications were treated conservatively, bleeding was stopped using endoscopic electrocoagulation. No mortality were observed.

Conclusion. Our study shows that two-step method of treatment (ERCP/S and LC/LCBDE) is preferable. This approach significantly reduces the time spent by the patient in hospital. We propose the following strategy for patients with choledocholithiasis with obstructive jaundice: ultrasound and MRSP for diagnostics and ERCP/S with LC/LCBDE in 2-3 days for treatment.

028

THE MANAGEMENT OF PATIENTS WITH CHOLEDOCHOLITHIASIS USING TWO-STAGE APPROACH

A. Baimakhanov, A. Smagulov, A. Raimkhanov, N. Sadykov, Ye. Abdrashev, D. Jumataev, G. Nurzhankyzy
Asphendiyarov Kazakh National Medical University, Almaty, Republic of Kazakhstan

Actuality. Endoscopic retrograde cholangiopancreatography with sphincterotomy (ERCP/S) has traditionally been performed prior to laparoscopic cholecystectomy (LC) in patients with suspected choledocholithiasis. More recently, one-stage techniques – combination LC and laparoscopic common bile duct exploration (LC/LCBDE) – have been developed to treat these patients.

Aim. To evaluate the safety and efficacy of managing common bile duct (CBD) stones using a two-stage approach.

Materials and methods. The study based on the results of treatment of 63 patients with choledocholithiasis. All patients were divided into 2 groups. Group I included 38 patients who underwent ERCP/S, followed by delayed laparoscopic cholecystectomy (in 2-3 months). Group II included 25 patients with LC/LCBDE 1-3 days after ERCP/S. Elderly patients were present in group I for 30.2%, in group II for 37.1%. The duration of the disease before hospitalization of patients in both groups averaged 6.3 days, respectively. The level of bilirubinemia in the blood ranged from 25,2 to 277,5 mmol/L. Elimination of choledocholithiasis using ERCP/S in both groups succeeded in all 63 (100%) patients.

Results. The average duration of inpatient treatment in group I was 12.8 ± 3.5 days. In group II, the average duration of treatment in the hospital was 7.5 ± 1.5 days, this is due to the fact that the 2nd stage of treatment was carried out on the 2nd, 3rd day after ERCP/S. In group I, during LC/LCBDE, perivesical infiltrate was more significant. In several cases, a perivesical

029

FAILURES AND COMPLICATIONS OF SURGICAL TREATMENT OF CHOLELITHIASIS AND ITS CORRECTION

A. Balalykin, H. Mutsurov, P. Barbado, T. Burmatova, G. Orazaliev, E. Shpak, V. Gvozdik
Russia

Introduction. Complications of traditional and laparoscopic surgery of cholelithiasis despite of years of clinical practice. Aim of survey to evaluate approaches in correction of complications of surgical treatment in patients with cholelithiasis

Materials and methods. We introduced transpapillary operations in 1974, laparoscopic operations in 1991. Several thousands of operations performed in this period

Results. As failures of laparoscopic and traditional operations we consider wrong draining of bile ducts, complications, residual cholelithiasis, rejection of simultaneous operations on gallbladder and bile ducts, incomplete cholecistectomy. Mistakes of external draining are: wrong treatment of tubes, wrong positioning of drains in CBD, mistakes of fixation. In group of 37 patients, obstructions of bile ducts registered in 5.4%, drains dislocation in 2.7%, CBD leak in 22%, CBD injury while drain extracted in 5.4%, peritonitis in 5.4%, cholangitis – 13.5%, biliary fistula – 2.7%, strictures of CBD – 8.1%, cholelithiasis – 63%. Correction via laparotomy performed in 5 patients, death occurred in 1 case; laparoscopy performed in 1 case, 31 patient cured by transpapillary operations. Thus, endoscopy can be mentioned as main way of correction of draining complications. 87 patients had complications of cholecystectomy. Injury of CBD was in 7 patients, CBD leak in 4, leakage of cystic duct stump in 17 patients, biliary fistula – 1, 7 strictures of CBD, cholangiolithiasis in 27 patients, incomplete cholecystectomy in 1 case. 76% of patients treated by transpapillary operations, including lithotripsy, lithoextraction, stenting in biliary leakage, cholangiolithiasis. Laparoscopy used

in cystic duct leak (3/17), in cholelithiasis (2). Traditional treatment used in strictures (4/7) huge lesions of CBD (3/6). Recurrent cholelithiasis most commonly is missed during cholecystectomy or transpapillary operation. 29.8% of patients with cholangiolithiasis underwent traditional operations, 70.2% - transpapillary operations.

Conclusion. Thus, transpapillary operations are main approach in treatment of complicated cholelithiasis.

030

HISTORICAL ROLE OF ENDOSCOPY IN DIAGNOSTICS AND TREATMENT FOR DIAGNOSTICS AND TREATMENT OF EARLY CANCER OF GASTROINTESTINAL TRACT

A. Balalykin, A. Verbovsky, P. Barbado
Russia

Introduction. Successes of surgical treatment of cancer defined by operations on early stages, provided by endoscopic diagnostics and resection of neoplastic lesions, that was an historical event in science and clinical practice. Opportunities of endoscopy in diagnostics and treatment of early cancer widened with introduction of EMR. Aim is to give overview of historical aspects of EMR and ESD.

Materials and methods. First EMR performed in Japan in 1970, in USSR in 1972 by AS Balalykin. In 5 years more than 500 EMR performed by team of VS Savelyev. Experience show that EMR indicated in prominent and flat lesions, easy and safe, when technical principles are followed.

Results. Value of EMR is hard to overestimate – histological survey of whole lesion, solution of diagnostical and tactical tasks was present. Clinical efficacy of EMR in early cancer is proved. 54 laparotomies after EMR, metastasis found in 12%. This limited use of EMR in cancer, localized in gastric outlet. EMR was new approach in oncology and refused by surgeons and oncologist for a long period. Limitations for EMR in ulcerous and big (more than 20 mm) lesions, when high risk of complication indicated. Expanding of opportunities of endoscopic surgery in this situations associated with ESD. Little self experience in 9 patients indicates of good diagnostical and therapeutical potential.

Conclusions. EMR and ESD have good perspectives in widening diagnostical therapeutical abilities of endoscopy in oncological practice.

031

3D MODELING OF THE LIVER BASED ON COMPUTED TOMOGRAPHY DATA IN THE PLANNING OF SURGICAL INTERVENTION

A. Bashkov¹, Zh. Sheikh², S. Voskanyan¹, A. Dunaev³, M. Popov¹, E. Naidenov¹, M. Shabalin¹, A. Safonov¹

¹State Research Center Burnazyan Federal Medical Biophysical Center of Federal Medical Biological Agency of Russia

²State budgetary institution «City clinical hospital named after S. P. Botkin» of the Department of health of Moscow

³State budgetary institution «Moscow City clinical hospital No 62» of the Department of health of Moscow

Introduction. Multidetector computed tomography with three dimensional (3D) reconstructions allows to determine vascular anatomic variants of the liver, relationship between lesion and magistral vessels, the best hepatectomy plane and help identify patients in whom additional surgical steps will be required.

Purpose. To study application of 3D modeling technique based on computed tomography (CT) data in planning of liver surgery, performed in the State research center Burnazyan federal medical biophysical center in the period from 2012 to 2018 years.

Methods. Medical records of 372 patients were retrospectively analyzed. The number of cases of applying 3D reconstructions technique based on CT data in the planning of liver surgery depending on its type and nosology was calculated. CT was performed on multislice computed tomography scanner Toshiba Aquilion 64 with bolus intravenous injection of 100 ml Ultravist.

Results. 3D reconstruction technique was applied in 100% of cases of living liver donor transplantation, in 89% of cases of alveolar echinococcosis, in 21% of cases of hepatocellular carcinoma, in 52% of cholangiocarcinoma, 18% of metastatic tumor. 3D images were required in 100% of cases when anatomical resection of the liver was associated with involvement of hepatocaval region and vascular reconstruction was planned, as well as in cases of extended hepatectomy in order to measure the volume of remnant liver and to evaluate the preservation of its supplying and draining vessels.

Conclusion. Application of 3D reconstruction technique is one of the crucial point in planning of living donor liver transplantation due to high responsibility for successful operation. 3D images alleviate surgeons to plan liver resection if it is associated with resection and reconstruction of magistral vessel(s) or with risk of compromising future liver remnant.

032

MULTIMODAL ADJUVANT THERAPY WITH CONCURRENT CHEMORADIATION WITH CAPECITABINE IN GASTRIC CANCER: A REGIONAL CANCER CENTER EXPERIENCE

M. Behera¹, K. Mittal², F. Ansari³, S. Dutta⁴

¹*Clinical Fellow, Clinical Radiation Oncology, AHRCC, India*

²*Assistant Professor, Radiotherapy, UP, India*

³*Associate Consultant, Radiotherapy, Delhi, India*

⁴*Assistant Professor, Radiotherapy, Siligudi, India*

Background. Gastric cancer remains one of the most common malignancies worldwide. Despite the significant advances in surgical treatment and multimodality strategies, prognosis has modestly improved over the last two decades. The prognosis of advanced GC remains poor, even after radical surgical treatment, with a 5-year overall survival of 20- 30% for T3-T4/N+ patients. There is a high risk of locoregional and distant recurrence, and this requires multidisciplinary management in order to improve outcomes. Locoregional relapse remains one of the main issues and the combined chemoradiation treatment seems to be one of the preferred approaches. This study aims to evaluate the efficacy and toxicity of adjuvant concurrent chemoradiation with capecitabine.

Patients and method. The study included 70 patients having histologically proven adenocarcinoma of the stomach or GE junction; stage Ib–IV post gastrectomy with D2 lymph node dissection. All the patients received radiotherapy by IGRT or IMRT technique with dose of 45-50.4 Gy in 25-28 fractions concurrently with capecitabine 825-1000 mg/m² BID. Emphasis was laid on documenting the toxicity of the treatment & nutritional status of the patients during treatment.

Results. The median follow-up period was 30 months, the 2-year disease free and overall survivals were 60.2% and 70%, respectively. 15 patients relapsed during the follow up period. 10 patients presented with loco-regional recurrences. 5 patients had distant metastases in lung or liver or brain. Ten patients could not complete the entire chemoradiation treatment due to gr III toxicity or due to the progressive disease. 10 patients presented with gr III toxicities; low hemoglobin in 5, vomiting in 2 patients and neutropenia in 3. GI toxicity was the most common toxicity encountered. There was no gr III/IV diarrhea or skin lesions.

Conclusion. Oral capecitabine concurrently with radiation therapy is effective and safe with acceptable toxicity. Encouragement for the development of multicenter randomized trials will address the optimal sequence and timing of CT, RT in respect to surgery.

033

COMPLICATIONS AFTER LAPAROSCOPIC AND CONVENTIONAL LIVER RESECTIONS FOR METASTATIC COLORECTAL CANCER

N. Belev^{1,2}, R. Penkov¹, Hr. Kolarov¹, I. Petleshkov¹, G. Djarov¹

¹*University Multiprofyl Hospital for Active Treatment - "Eurohospital" Plovdiv, Bulgaria*

²*Medical University - Plovdiv, Medical Simulation and Training Center, Bulgaria*

Introduction. Safety of planned liver surgery is continuously improving over the last 30 years. While in 1970s mortality after liver surgery reached 13% nowadays results today are more optimistic – 0% to 4% mortality and complications in 19.6% to 35%. These better postoperative results are due to liver surgery refinement in specialized centers, better patient selection regarding liver function and accompanying diseases, the advancement of surgical technique and better understanding of liver segmental anatomy as well as new instruments of parenchymal transection. Furthermore anesthesiology and intensive care in liver surgery have seen drastic improvement, for example low central venous pressure during parenchymal transection alone has great importance.

Aim. Comparison of complications and ways to reduce them after laparoscopic and conventional liver resection for metastatic colorectal cancer.

Materials and methods. For the period of 01.03.2012 until 31.12.2017 we have analyzed retrospectively the immediate results and complications of 156 liver resections for metastatic colorectal cancer. 88(56%) of them are simultaneous liver and colorectal resections (34-39% laparoscopic and 54-61% conventional) and 68(43%) liver resections for metachronous metastasis (20 laparoscopic and 48 (29%) conventional). We evaluated patients performance status as 0,1,2 according to the European Oncology Study Group, liver function according to MELD criteria, ASA score for anesthesiology risk assessment. Morbidity is classified according to the Clavien-Dindo classification.

Results. Registered mortality is 1.4%. Complications are 23% (36 patients) – 19% (30 patients) had operation related complications and 4% (6 patients) had general complications. According to the Clavien-Dindo classification complication were distributed the following way – laparoscopic surgery patients had 19.6% complications classified as mainly Grade A and B according to the Dindo classification. Mean blood loss in laparoscopic surgery was 80ml while 150ml was registered in open surgery. Mean hospital stay is 6.5 days in the laparoscopic group and 9.5 days in the open surgery group.

Conclusion. Laparoscopic liver surgery generates better postoperative results (less blood loss, less haemotransfusion requirement, shorter hospital stay. According to our study laparoscopic liver surgery results in lower percent of postoperative morbidity with more complications registered as low grade according to the Clavien-Dindo classification.

034**LAPAROSCOPIC SURGERY IN ADVANCED GASTRIC CANCER (PT2-4A, N1-3B, M0) COMBINED WITH HIGH PRESSURE AEROSOL CHEMOTHERAPY FOR PERITONEAL CARCINOMATOSIS(PC) PROPHYLAXIS AND TREATMENT****N. Belev^{1,2}, P. Rusev¹, P. Krastev¹, R. Penkov¹, B. Atanasov¹, Sh. Popov¹, I. Petleshkov¹, D. Cvetkov¹, G. Djarov¹**¹UMHAT-Eurohospital Plovdiv, Bulgaria²Medical University-Plovdiv, Medical Simulation Training Center, Bulgaria**Aim.** Our aim is to established the effectiveness of combined radical laparoscopic gastric surgery with PIPAC in advanced gastric cancer for the prevention and treatment of PC.**Object.** Gastric cancer is the second most common cause for cancer dead. Open gastrectomy is associated with, high morbidity (9.1%-46%) and longer hospital stay. Laparoscopic gastrectomy show better postoperative results in comparison to open surgery while having the same oncologic results. Peritoneal spread in gastric cancer is generally observed in 40 to 50% of the patients. When PC is diagnosed all patients die. Gastrectomy with peritonectomy and Hyperthermic intraperitoneal chemotherapy (HIPEC) in series by Sugarbaker and Yonemura show a possibility for the treatment of this group. Pressurized intraperitoneal aeorosol chemotherapy (PIPAC) is based on breaking up chemotherapy agents into particles of 10-15 microns and delivering them in a concentration of 10% of the systemic dose under pressure of 15mmHg for 30 minutes. Prevention and therapy of PC is the main indication for PIPAC which have promising initial reults.**Material and methods.** Patients with resectable gastric cancer (T3-4a, N1-3b, M0, M1, P1, positive cytology), high risk of PC are candidates for this study. In prospective 12 patients had laparoscopic gastrectomy (7 total and 5 subtotal) with D2 lymph node dissection . After finishing the reconstructive stage we applied PIPAC for 30 minutes. This procedure was repeated after 30 days for a total of 3 times. We analyzed retrospectively 14 laparoscopic gastrectomies due to gastric cancer for a past period of 1 year (poorly differentiated, diffuse type) actively searching for PC.**Results.** Two postoperative complications (16.6%) were established in the laparoscopic surgery group with PIPAC (internal pancreatic fistula, oesophago-jejuno anastomotic leak) and 3 complications (21,4%) in the retrospective group (internal pancreatic fistula, duodenal stump leak, oesophago-jejuno anastomotic leak, all Clavien-Dindo-II). In 8(57%) of the retrospective patients PC, was established at the end of the first year after surgery. Three of the patients in the aerosol group have reached the end of the first year with no data

supporting PC, the others remain to be analyzed.

Conclusion. Even this early in its studies it is posible to say that PIPAC has better pharmacological capabilities compared to HIPEC and systemic chemotherapy for the treatment of PC as in vitro and animal studies and clinical data support this statement. RCT are needed for complete and exact validation of this method.**035****C-REACTIVE PROTEIN MEASUREMENT IS NOT ASSOCIATED WITH AN IMPROVED MANAGEMENT OF ACUTE CHOLECYSTITIS: A PLIÉ FOR A CHANGE****A. Beliaev, M. Booth***Auckland City Hospital, Auckland, New Zealand***Background.** The diagnosis of acute cholecystitis (AC) is challenging and may result in a delay in surgical treatment and increased mortality. The 2007 and 2013 Tokyo Guidelines for AC proposed to use C-reactive protein (CRP) as an additional bench mark of AC. The aim of this study was to evaluate whether CRP measurement influences management of patients with AC.**Methods.** For more than a period of 5 years (May 2004 to June 2009), 1959 patients were identified from the audit of cholecystectomies in North Shore, Waitakere and Southern Cross hospitals at Waitemata District Health Board, Auckland, New Zealand. The exclusion criteria were elective and private patients, patients without AC on histologic examination of gallbladders, and patients with acute acalculous cholecystitis.**Results.** A total of 414 patients met eligibility criteria. Compared with the non-CRP group, patients who had CRP measured had a longer time to operation theater and a greater proportion of acute gangrenous cholecystitis on histologic examination of excised gallbladders, but similar postoperative complication rate, index, and total hospital stay. Time to operation theater was not associated with development of acute gangrenous cholecystitis (odds ratio, 1.0; 95% confidence interval, 0.996-1.01; P = 0.797), but correlated with the index hospital admission length (correlation coefficient, 0.6092; P < 0.001).**Conclusions.** CRP measurement does not influence management of patients with AC. To improve quality of care and to minimize health care provider costs physiologically fit patients with more advanced forms of AC and higher values of CRP should have their operation performed earlier than patients with mild AC and a lower concentration of CRP.

036

C-REACTIVE PROTEIN IS THE GOLD STANDARD DIAGNOSTIC BIOMARKER OF ACUTE CHOLANGITIS IN LIVER TRANSPLANT RECIPIENTS

A. Beliaev, A. Bartlett, C. Bergin

Auckland City Hospital, Auckland, New Zealand

Background. Bacterial infections including acute cholangitis (AC) after liver transplantation (LTx) remain a significant cause of patient morbidity, re-transplantation and mortality. The 2018 Tokyo guidelines (TG18) for AC do not provide diagnostic criteria for liver transplant (LT) recipients. The aims of this study were to evaluate the discriminative powers of common inflammatory markers used for diagnosing AC in LT recipients and to determine their diagnostic cutoff levels.

Methods: This was a retrospective case-control study. Over 4 years 182 patients who underwent endoscopic biliary decompression were identified from a Hospital Radiology Department database. Ten LT recipients who were diagnosed with AC were included in the study. The control group was randomly drawn from the Hospital LT Registry in a 1:1 ratio to the number of cases. Two pediatric LT recipients were excluded from the study because of age matching. Eligibility criteria were met by 10 LT recipients with AC who had 29 hospital admissions for AC treatment and 10 LT recipients without AC who were seen as outpatients.

Results: Among commonly used inflammatory markers C-reactive protein (CRP) had the highest discriminative power for diagnosing AC and for monitoring the response to treatment in LT recipients. The area under the receiver operating characteristics curve of CRP was 99% (95% CI: 97-100%). A cut-off value of CRP for diagnosing AC was equal to or above 5 mg/L. CRP had a weak positive linear relationship with neutrophil count ($r = 0.261$; $p = 0.03$).

Conclusion: CRP should be used as the "gold standard" for the diagnosis and monitoring of treatment response in LT recipients with AC.

values are yet undetermined.

Aim. The aims of this study were to evaluate the discriminative powers of common inflammatory markers compared with WCC for diagnosing AC and to determine their diagnostic cutoff levels.

Methods. This was a retrospective cohort study. Over two years 96 patients who underwent endoscopic biliary decompression were identified from the Auckland City Hospital Radiology Department database. Only patients with a confirmed diagnosis of AC were included in the study. Thirty-four patients with AC and 18 controls met eligibility criteria.

Results. Comparing areas under the receiver operating characteristic curves, it was the lymphocyte count, neutrophil to lymphocyte ratio (NLR) and C-reactive protein (CRP) that had the highest discriminative powers in diagnosing AC. Values of WCC for diagnosing AC were equal to or above $9.6 \times 10^9/L$, neutrophil count equal to or exceeding $4.9 \times 10^9/L$, lymphocyte count equal to or below $1.3 \times 10^9/L$, NLR 5.3 and above, albumin equal to or below 30.5 g/L and CRP concentration 23.5 mg/L or above.

Conclusions. Lymphocyte count, NLR and CRP have superior discriminative powers to WCC, albumin and neutrophil count and can be useful in the diagnosis of AC.

038

EVALUATION OF NEUTROPHIL-TO-LYMPHOCYTE RATIO AS A POTENTIAL BIOMARKER FOR ACUTE CHOLECYSTITIS

A. Beliaev, N. Angelo, M. Booth, C. Bergin

Auckland City Hospital, New Zealand

Background. The diagnosis of acute cholecystitis (AC) is frequently associated with an increase in white cell count (WCC) and C-reactive protein (CRP). However, one or both of these inflammatory biomarkers can be normal in AC.

Aim. The aim of this study was to evaluate and compare the discriminative powers of the neutrophil-to-lymphocyte ratio (NLR) with WCC and CRP in diagnosing AC.

Methods. This was a retrospective cohort study. Over a 5 year period 1959 patients were identified from the cholecystectomy Registry. Laparoscopic cholecystectomy patients with histological evidence of AC were included if they also had pre-operative WCC and CRP measurements. Eligibility criteria were met by 177 patients. These patients were compared with 45 controls who had normal gallbladder histology.

Results. One unit of NLR increase was associated with a 2.5 times increase in the odds of AC (Odds ratio = 2.48, 95% CI, 1.5 – 4.1, $p < 0.0005$). NLR cutoff values of 4.1 (95% CI, 3.42 – 4.79), 3.25 (95% CI, 1.95 – 4.54) and 4.17 (95% CI, 3.76 – 4.58) were diagnostic for the overall AC, mild and moderate-severe AC, respectively. The NLR areas under the receiver operating characteristic curve (AUC) in AC, mild and moderate-severe AC were 94% (95% CI, 91–97%), 87% (95% CI, 81 – 93%)

037

DIAGNOSTIC INFLAMMATORY MARKERS IN ACUTE CHOLANGITIS

A. Beliaev, M. Booth, D. Rowbotham, C. Bergin

Auckland City Hospital, New Zealand

Background. The 2018 Tokyo guidelines (TG18) for acute cholangitis (AC) use white cell count (WCC) as one of the diagnostic criteria. However, the TG18 grading does not provide guidance for AC patients with normal WCC. In this situation, other inflammatory biomarkers also can be used to diagnose AC and grade severity, but their diagnostic

and 98% (95% CI, 96 – 100%), respectively. The discriminative power of NLR was superior to that of WCC and similar to CRP for diagnosing AC and different grades of severity.

Conclusions. NLR can be considered as a potential inflammatory biomarker for AC.

039

HISTOLOGY-BASED CLASSIFICATION OF ACUTE CHOLECYSTITIS SEVERITY: CLINICAL AND CURGICAL IMPLICATIONS

A. Beliaev, N. Angelo, M. Booth, C. Bergin

Auckland City Hospital, Auckland, New Zealand

Background. Acute cholecystitis (AC) severity influences patient management. The 2018 Tokyo Guidelines (TG18) assigned severity grades to AC and proposed corresponding different management regimens. However, TG18 guidelines do not relate severity of AC to histologic features of gallbladder inflammation.

Aim. The aims of our study were to assess the relationship between histologic gallbladder inflammation, risk of conversion of laparoscopic cholecystectomy to open surgery (CTO) and severity of peri-operative complications, and to propose a histology-based clinical classification for AC severity.

Methods. This was a retrospective cohort study of 1762 patients who had laparoscopic cholecystectomy (LC), 472 of whom had AC confirmed on histological examination.

Results. Patients with active chronic cholecystitis and those with acute edematous cholecystitis had more than a five-fold increase in odds of CTO compared with patients with normal gallbladders and those with chronic cholecystitis, (OR = 5.1; 95% CI, 3.5 – 7.6; $p < 0.00005$). Patients with acute necrotizing cholecystitis had a ten-fold increase in CTO odds (OR = 10.9; 95% CI, 6.1 – 19.1; $p < 0.00005$). Patients with acute gangrenous and suppurative cholecystitis had more than 11-fold increase in CTO odds (OR = 11.9; 95% CI, 6.8 – 20.5; $p < 0.00005$) and those with pericholecystic abscess or gallbladder perforation had 25 times higher odds of CTO (OR = 25.2; 95% CI, 5.2 – 129.2; $p < 0.00005$). Patients with acute edematous cholecystitis and those with active chronic cholecystitis were classified as mild AC and the remainder as moderate-severe. Patients with moderate-severe AC have twice the risk of CTO that patients in the mild group have (OR=2.0; 95% CI: 1.3-3.1; $p = 0.003$), longer durations of surgery and higher rates and severity of perioperative complications.

Conclusions. Increasing severity of histologic gallbladder inflammation corresponds with greater risk of CTO, higher rates and severity of perioperative complications. Patients with active chronic cholecystitis and acute edematous cholecystitis correspond with clinically mild AC and those with acute necrotizing, gangrenous, suppurative cholecystitis,

pericholecystic abscess and AC with gallbladder perforation comprise clinically severe AC.

040

C-REACTIVE PROTEIN HAS A BETTER DISCRIMINATIVE POWER THAN WHITE CELL COUNT IN THE DIAGNOSIS OF ACUTE CHOLECYSTITIS

A. Beliaev, R. Marshall, M. Booth

Auckland City Hospital, Auckland, New Zealand

Background. The diagnosis of acute cholecystitis (AC) is challenging and may result in a delay in surgery, hospital discharge, and increased mortality. To improve its diagnosis, C-reactive protein (CRP) has been proposed as a benchmark. The aim of this study was to evaluate discriminative power of CRP against white cell count (WCC) in AC.

Methods. This was a retrospective cohort study. Over a 5-y period, 1959 patients were identified from the audit of cholecystectomies. The exclusion criteria were coexisting acute surgical conditions, absence of blood tests within 3 d before hospital admission for elective surgery, and private patients.

Results. The eligibility criteria were met by 1843 patients. Comparison of the area under receiver operating characteristic (AUC) curve of CRP and WCC in acute on chronic, edematous, necrotic, suppurative, and gangrenous AC showed a better discriminative power of CRP. Both tests performed equally well in patients with pericholecystic abscess and gallbladder perforation. CRP was superior than WCC in mild AC, AUC = 0.93 (95% confidence interval [CI], 0.9-0.95) and 0.79 (95% CI, 0.74-0.84), $P < 0.00005$, in moderate and severe AC, AUC = 0.99 (95% CI, 0.97-1.0) and 0.92 (95% CI, 0.88-0.97), $P = 0.009$, and in all forms of AC combined, AUC = 0.94; (95% CI, 0.92-0.97) and 0.83 (95% CI, 0.79-0.87), respectively, $P < 0.005$.

Conclusions. CRP has a better discriminative power than WCC in most forms of AC and is a useful diagnostic marker of AC.

041

DENVER SCREENING PROTOCOL FOR BLUNT CEREBROVASCULAR INJURY REDUCES THE USE OF MULTI-DETECTOR COMPUTED TOMOGRAPHY ANGIOGRAPHY

A. Beliaev, P. Barber, R. Marshall, I. Civil

Auckland City Hospital, Auckland, New Zealand

Background. Blunt cerebrovascular injury (BCVI) occurs in 0.2-2.7% of blunt trauma patients and has up to 30% mortality. Conventional screening does not recognize up to 20% of BCVI patients. To improve diagnosis of BCVI, both an expanded

battery of screening criteria and a multi-detector computed tomography angiography (CTA) have been suggested. The aim of this study is to investigate whether the use of CTA restricted to the Denver protocol screen-positive patients would reduce the unnecessary use of CTA as a pre-emptive screening tool.

Methods. This is a registry-based study of blunt trauma patients admitted to Auckland City Hospital from 1998 to 2012. The diagnosis of BCI was confirmed or excluded with CTA, magnetic resonance angiography and, if these imaging were non-conclusive, four-vessel digital subtraction angiography.

Results. Thirty (61%) BCI and 19 (39%) non-BCI patients met eligibility criteria. The Denver protocol applied to our cohort of patients had a sensitivity of 97% (95% confidence interval (CI): 83-100%) and a specificity of 42% (95% CI: 20-67%). With a prevalence of BCI in blunt trauma patients of 0.2% and 2.7%, post-test odds of a screen-positive test were 0.03 (95% CI: 0.002-0.005) and 0.046 (95% CI: 0.0314-0.068), respectively.

Conclusions. Application of the CTA to the Denver protocol screen-positive trauma patients can decrease the use of CTA as a pre-emptive screening tool by 95-97% and reduces its hazards.

042

LATE TWO-STAGE LAPAROSCOPIC CHOLECYSTECTOMY IS ASSOCIATED WITH AN INCREASED RISK OF MAJOR BILE DUCT INJURY

AM Beliaev, M Booth

Auckland City Hospital, Auckland, New Zealand

Background. Late laparoscopic cholecystectomy (LC) after endoscopic retrograde cholangiopancreatography (ERCP) and sphincterotomy (ES) for common bile duct (CBD) stone clearance, two-stage LC (TSLC), is associated with difficult surgical dissection and an increased rate of conversion to open procedure. The purpose of the study was to evaluate whether the interval between ERCP/ES and LC is associated with major bile duct injury (BDI) and determine an optimal period for TSLC.

Methods. This was a retrospective cohort study of adult patients who underwent LC. The exclusion criteria were absence of CBD stones on imaging or ERCP, surgical treatment of choledocholithiasis, post-operative endoscopic CBD stone clearance and open cholecystectomy.

Results. The eligibility criteria were met by 183 patients. There were six major BDIs (3%). Comparisons of the early and late TSLC showed statistically significant difference in major BDI at 16-week cut-offs. Binomial regression analysis demonstrated that late (≥ 16 weeks) TSLC was associated with 10-fold increase in major BDI (95% confidence interval: 1.1-95.7, $P = 0.043$). Survival analysis comparing early (< 16 weeks) with late (≥ 16 weeks) TSLC demonstrated that both groups had similar survival time (log-rank test: 0.317).

Conclusions. General surgeons should be aware of the

increasing risk of major BDI with delaying TSLC and perform interval LC before week 16.

043

NEUTROPHIL-TO-LYMPHOCYTE RATIO AS A POTENTIAL BIOMARKER FOR ACUTE CHOLECYSTITIS

A. Beliaev, N. Angelo, M. Booth, C. Bergin

Auckland City Hospital, Auckland, New Zealand

Background. The diagnosis of acute cholecystitis (AC) is frequently associated with an increase in white cell count (WCC) and C-reactive protein (CRP). However, one or both of these inflammatory biomarkers can be normal in AC. The aim of this study was to evaluate and compare the discriminative powers of the neutrophil-to-lymphocyte ratio (NLR) with WCC and CRP in diagnosing AC.

Methods. This was a retrospective cohort study. Over a 5 year period 1959 patients were identified from the cholecystectomy Registry. Laparoscopic cholecystectomy patients with histological evidence of AC were included if they also had pre-operative WCC and CRP measurements. Eligibility criteria were met by 177 patients. These patients were compared with 45 controls who had normal gallbladder histology.

Results. One unit of NLR increase was associated with a 2.5 times increase in the odds of AC (Odds ratio = 2.48, 95% CI, 1.5 – 4.1, $p < 0.0005$). NLR cutoff values of 4.1 (95% CI, 3.42 – 4.79), 3.25 (95% CI, 1.95 – 4.54) and 4.17 (95% CI, 3.76 – 4.58) were diagnostic for the overall AC, mild and moderate-severe AC, respectively. The NLR areas under the receiver operating characteristic curve (AUC) in AC, mild and moderate-severe AC were 94% (95% CI, 91–97%), 87% (95% CI, 81 – 93%) and 98% (95% CI, 96 – 100%), respectively. The discriminative power of NLR was superior to that of WCC and similar to CRP for diagnosing AC and different grades of severity.

Conclusion. NLR can be considered as a potential inflammatory biomarker for AC.

044

SOCIO-ECONOMIC DEPRIVATION IS NOT ASSOCIATED WITH REDUCED SURVIVAL OF LUNG TRANSPLANT RECIPIENTS

A. Beliaev, P. Alison, D. Reddy, M. O'Carroll, C. Lewis, T. McWilliams

Auckland City Hospital, Auckland, New Zealand

Background. Important risk factors for long-term survival of lung transplant (LT) recipients are infection, acute graft rejection (AR) and chronic lung allograft dysfunction (CLAD). Socio-economic deprivation (SED) is associated with increased

graft failure rate after heart and kidney transplantation, but has not been investigated in LT recipients.

Aim. The aim of this study was to evaluate an association between LT recipients' SED status and development of AR, CLAD and long-term survival.

Methods. This was a retrospective cohort study. Over a 23 year period 233 patients were identified from the Auckland City Hospital Lung Transplant Registry, Auckland, New Zealand. All patients were divided into two groups according to the 2013 New Zealand Deprivation Index Score.

Results. The incidence of AR in the higher SED group was 34.0/100 person-years (95% CI: 24.7-46.7/100 person-years) and in the lower SED group 40.2/100 person-years (95% CI: 33.5-48.3/100 person-years) ($p=0.373$). The incidence of CLAD in the higher SED group was 10.7/100 person-years (95% CI: 6.2-18.4/100 person-years) and 9.3 (6.9-12.5/100 person-years) in the lower SED group ($p=0.645$). Mortality in the higher SED group was 12.9/100 person-years (95% CI: 9.2-17.9/100 person-years) and 12.4/100 person-years (95% CI: 10.0-15.3/100 person-years) in the lower SED group ($p=0.834$).

Conclusion. SED status of LT recipients in New Zealand has no negative effect on development of AR, CLAD and patients' survival.

045

USE OF THE 2018 TOKYO GUIDELINES IN SCREENING FOR ACUTE BACTEREMIC CHOLANGITIS

A. Beliaev, S. Zyu'korneeva, C. Bergin

Auckland City Hospital, Auckland, New Zealand

Background. Acute bacteremic cholangitis (ABC) complicated by septic shock is associated with up to 40% mortality. Early diagnosis, initiation of antimicrobial therapy and urgent biliary decompression improves survival of patients with ABC. The predictive power of the 2018 Tokyo guidelines (TG18) criteria for moderate acute cholangitis (AC) in diagnosing ABC is unknown. The aim of this study was to investigate the predictive power of TG18 diagnostic criteria for moderate AC in screening patients for ABC.

Methods. This was a retrospective cohort study in which patients with a confirmed diagnosis of ABC were compared with those without biliary bacteremia (the non-ABC group). Results. Forty seven ABC patients with a total 67 biliary bacteremic episodes and 53 non-ABC patients with 67 hospital admissions met eligibility criteria. The TG18 diagnostic criteria for moderate AC used in screening for ABC had a sensitivity of 62.7% (42/67) (95% confidence interval (CI): 50-74.2%), specificity of 71.6% (48/67) (95% CI: 59.3-82%), correctly classified in 67.2% of patients, an area under receiver operating characteristic curve of 0.67 (95% CI: 0.59-0.75). With a prevalence of biliary bacteremia of 23%, the positive predictive value for TG18 criteria was 39.8% (95% CI: 30.2-50.2%),

negative predictive value 86.5% (95% CI: 82-90.1%).

Conclusion. TG18 criteria for moderate AC have low sensitivity, specificity and positive predictive values for diagnosing ABC. Development of diagnostic criteria for ABC is urgently required.

046

COMPLEX CORRECTION OF ENTERIC INSUFFICIENCY SYNDROME IN PREVENTION OF POSTOPERATIVE INFECTIOUS COMPLICATIONS FOR COMMON PURULENT PERITONITIS AND ABDOMINAL SEPSIS

B. Belik¹, D. Mareev², V. Suyarko², S. Efanov¹, M. Oskanian¹, G. Chirkinyan¹, A. Maslov¹

¹*FSBEE HE «Rostov State Medical University» of Ministry of Health of the Russian Federation*

²*Surgical Department Municipal Budgetary Institution of Health Care «Municipal hospital No 1 of Rostov-on-Don named after N.A. Semashko»*

Relevance. Enteric insufficiency syndrome (EIS) plays a key role in the pathogenesis of common purulent peritonitis (CPP) and it's main trigger of abdominal sepsis (AS) progression. In this case, EIS correction directed to elimination of microorganisms translocation from intestinal and prevention of reinfection of abdominal cavity may be one of the ways of prevention of postoperative abdominal infectious complications (PPAIC) in patients with heavy forms of CPP.

Objective. To determine the clinical significance of complex correction of EIS in prevention of PPAIC in patients with heavy forms of CPP and AS.

Material and methods. The clinical material consisted of 78 patients with CPP who had signs of AS. AS diagnostics in patients was based on of the following criteria: verified source of intra-abdominal infection; EIS in the form of persistent intestinal paresis within 48-72 hours or more; dysfunction of at least one or more of the three organ systems of extraabdominal localization (cardiovascular, renal, respiratory) for 24-48 hours or more, evaluated on the SOFA scale >2 points. During the operation, the source of peritonitis was eliminated, nasointestinal intubation and transumbilical catheterization of the portal vein were performed. In the postoperative period probe small intestinal decompression, intestinal lavage, enterosorption, intra-portal infusion therapy using ozone-saturated solutions and prolonged epidural blockade were performed. The diagnostic program included: evaluation the severity of the patients on the APACHE II scale, calculation of relaparotomy prognostic index (RPI) according to the method of J.F.Pisajo, measurement of the intra abdominal pressure (IAP), determination of serum procalcitonin (PCT) level and endotoxin concentration in peritoneal exudate and systemic blood.

Results. In the 1st day after surgery during EIS and endotoxosis the severity of the patients evaluated on the APACHE II scale

was $28,9 \pm 2,6$ points. At the same time there were observed the raising IAP level to $18,9 \pm 1,7$ mm Hg, the increase of serum PCT ($15,5 \pm 0,6$ $\mu\text{g/ml}$) and endotoxin concentration in peritoneal exudate in 8.4 time and systemic blood – in 1.4 time than reference levels. The use complex correction of EIS at 92.2% cases led to the restoration of intestinal motility by 3-4 days after surgery. In the same term, at patients the decrease of IAP, taxinomia elimination, the decrease of serum PCT ($4,6 \pm 0,3$ $\mu\text{g/ml}$) and endotoxin concentration in peritoneal exudate in 3.5 time than initial levels was noted. At the same time, the severity of the patients on the APACHE II scale decreased to $11,8 \pm 0,2$ points, and RPI did not exceed $8,1 \pm 1,2$ points. From 78 patients only 3 (3.8%) had the need to perform relaparotomy on demand. It allowed for patients with CPP and AS to reduce the number of relaparotomies to 8.9% and reduce postoperative mortality from 43.7% to 34.6%, that is, by 9.1%.

Conclusion. One of the ways of prevention of PPAIC in patients with CPP and AS is complex correction of EIS, which contributes to the early restoration of functional activity of the intestine, elimination of translocation of microorganisms and reinfection of the abdominal cavity, elimination of bacteremia and toxinemia, regression of intra-abdominal hypertension and organ dysfunction, which reduces the number of relaparotomy "on demand" and reduce postoperative mortality.

047

THE ROLE OF ABDOMINAL COMPARTMENT SYNDROME AND ENTERIC INSUFFICIENCY SYNDROME REGARDING OF PROGRESSION OF INFECTIOUS COMPLICATIONS HEAVY FORMS OF ACUTE PANCREATITIS

B. Belik¹, G. Chirkinyan¹, D. Mareev², R. Tenchurin², M. Oskanian¹, A. Dadayan²

¹FSBEE HE «Rostov State Medical University» of Ministry of Health of the Russian Federation

²Surgical Department Municipal Budgetary Institution of Health Care «Municipal hospital No 1 of Rostov-on-Don named after N.A. Semashko»

Relevance. The leading pathogenetic mechanisms complicating heavy forms of acute pancreatitis (AP) are intra-abdominal hypertension (IAH) and enteric insufficiency syndrome (EIS), which accompanied by microorganisms translocation from intestinal tract to the portal system of veins and lymphatic system. In this regard, it seems to be interesting assessment factors of IAH and EIS in the infectious complication progression for heavy forms of acute pancreatitis

Objective: to determine the role of IAH and EIS on the frequency of progression of infectious complications and lethality rate in patients with severe AP.

Material and methods. The analysis of treatment results of 92 patients with severe AP. On 79 patients (85,9%) from

their number sanitary laparoscopy has been carried out. In patients were evaluated the severity on the APACHE II scale, performed measurement of the intra abdominal pressure (IAP) according to the method of I.L.Kron and blood serotonin concentration was studied as the main neurotransmitter activating smooth muscle contraction. IAH degree determined in accordance with the gradation M.L. Malbrain. Depending on the severity of the IAH all the patients were divided into 2 groups. On 66 (71,7%) patients 1-2nd degree IAH is noted (the 1st group), on 26 (28,3%) patients 3-4th degree IAH is noted (the 2nd group).

Results. The IAP indexes of patients in the 1st group on admission was $15,3 \pm 0,9$ mm Hg, in patients of the 2nd group - $21,1 \pm 1,2$ mm Hg. At the same time during EIS manifestations in patients of the 2nd group blood serotonin concentration was significant lower than patients of the 1st group (respectively $54,7 \pm 2,4$ and $89,3 \pm 4,2$ $\mu\text{g/ml}$) and significant lower than reference level ($132,4 \pm 5,9$ $\mu\text{g/ml}$). After sanitary laparoscopy performing in patients of the 1st group normalization IAP was observed in $3,2 \pm 2,7$ days. At the same time during EIS elimination increase blood serotonin concentration ($129,6 \pm 3,7$ $\mu\text{g/ml}$) and regress of indexes of a scale of APACHE II from $11,2 \pm 1,3$ to $8,7 \pm 0,6$ points were noted. After sanitary laparoscopy performing in patients of the 2nd group transitory blood serotonin concentration increasing was observed, which by the 5th – 7th day replaced by its sharp deficiency ($49,8 \pm 2,1$ $\mu\text{g/ml}$), that manifested at the clinical level by the development of persistent intestinal paresis and increase IAH (IAP - $23,8 \pm 1,9$ $\mu\text{g/ml}$). At the same time increase of indexes of a scale of APACHE II was noted from $19,6 \pm 1,7$ to $26,3 \pm 1,3$ points. Further, it was required 4 patients to perform decompression laparotomy and nasointestinal intubation. From 92 patients with severe AP the infectious complications was noted at 14 (15,2%). In the 1st group infectious complications took place at 2 (3,0%) patients, in the 2nd group – at 12 (46,1%) patients. In the 1st group from 66 patients died 3 (4,5%). In the 2nd group from 26 patients died 15 (57,7%). Total lethality was 19,6% (18 patients died).

Conclusion. There is a direct correlative communication between the severity of the IAH and EIS on one side and the frequency of infectious complications and lethality rate the other side in patients with severe AP.

048

PATIENT-RELATED RISK FACTORS FOR RECURRENCE AFTER INGUINAL HERNIA REPAIR

A. Belousov, O. Vasnev, M. Nigmatov

The Loginov Moscow Clinical Scientific Center is State Institution funded by Moscow Health Department (The Loginov MCSC MHD)

Actuality. Recurrence after inguinal hernia surgery is a considerable clinical problem, and several risk factors of

recurrence such as surgical technique, re-recurrence, and family history have been identified. Non-technical patient related factors that influence the risk of recurrence after inguinal hernia surgery are sparsely studied.

Aim. The purpose of the study was to investigate the patient related risk factors leading to recurrence after inguinal hernia surgery.

Materials and methods. 552 patients with primary inguinal hernia were operated in Moscow Clinical Scientific Center between January 2013 and December 2017. The average age of patients was 55.7 ± 3.8 years. There were 505 men, 47 women. Smokers 313 (56,7%), non-smokers 239 (43,3%). Patients with bilateral hernia: 109 (19.7 %), right-side hernia 239 (43,2%), left-side hernia 204 (37.1 %). Depending on the method of surgery, we identified two groups. Group I, patients underwent TAPP (430 patients). In group II patients underwent inguinal hernia repair by Lichtenstein (122 patients).

Results. The results of treatment of 486 patients (88% of the total number of patients) were studied. 463 men, 23 women. The average follow-up period was 32.46 ± 5.2 months (minimum 3 months, maximum 62 months). Recurrence was diagnosed in 39 patients (8% of the total number of followed-up patients). There are 24 patients in group I and 15 patients in group II. In the analysis of the results, we identified the 5 most common patient-related risk factors for recurrence: BMI > 25 kg/m², direct inguinal hernia, hernia size > 3 cm, smoking, family history of hernia formation, concomitant pathology (chronic bronchitis or diabetes). The combination of more than 3 risk factors was observed in 18 of 24 patients with recurrent inguinal hernia in group I, in group II - in 9 of 15.

Conclusion. Data showed that non-technical patient-related risk factors have great impact on the risk of recurrence after inguinal hernia surgery. The reason to why inguinal hernias recur is most likely multifactorial and lies in the span of technical and non-technical patient-related risk factors. This knowledge should be implemented into clinical practice in order to reduce the risk of recurrence and in future research design examining recurrence after inguinal hernia surgery as outcome.

049

LAPAROSCOPIC MESH HERNIOPLASTY OF INGUINAL HERNIA AND SIMULTANEOUS RADICAL PROSTATECTOMY, MULTICENTER RETROSPECTIVE STUDY

R. Biktimirov^{1,2}, A. Martov^{1,2}, A. Kaputovskij¹, T. Biktimirov^{1,2}, A. Kochkin³, I. Orlov⁴

¹Federal clinical center of high medical technology of FMBA of Russia. Khimki, Moscow region, Russia

²Department of Urology and Andrology, IPPE of A.I. Burnazyan SSC FMBC of FMBA of Russia. Moscow, Russia

³Urological Center of Russian Railways Hospital. Nizhny

Novgorod, Russia

⁴*St. Luke's Clinical Hospital. St. Petersburg, Russia*

Introduction. The correlation between inguinal hernia and low urinary tract symptoms (LUTS) is known. The prostate cancer is one of the reason of LUTS. Laparoscopic prostatectomy (LP) may be method of choice for radical treatment.

Results. The data of 25 patients, who underwent simultaneous procedures from 2011 to 2017 in our clinical centers, were analyzed retrospectively. Seven cases of bilateral mesh hernioplasty and other unilateral. The same surgical approach was used for both conditions. The mean age of patients was 65.2 years, mean blood loss was 175 ml, mean operation time was 191.5 min. The postoperative complications rate was 12%. All three cases were Clavien I-II grade.

Conclusion. Current study has demonstrated suitable results of laparoscopic mesh hernioplasty of inguinal hernia and simultaneous LP. It should be considered for routine use.

050

LAPAROSCOPIC MESH HERNIOPLASTY OF INGUINAL HERNIA AND SIMULTANEOUS MINIMAL INVASIVE SIMPLE PROSTATECTOMY FOR BENIGN PROSTATIC HYPERPLASIA, IS IT SAVE?

R. Biktimirov^{1,2}, A. Martov², A. Kaputovskij¹, T. Biktimirov^{1,2}

¹Federal clinical center of high medical technology of FMBA of Russia Novogors district, Khimki, Moscow region, 141435, Russia

²Department of Urology and Andrology, IPPE of A.I. Burnazyan SSC FMBC of FMBA of Russia. 23 Marshala Novikova St., Moscow, 123098, Russia

Introduction. The correlation between inguinal hernia and BPH is well known. Minimal invasive simple prostatectomy may be method of choice for surgical treatment of BPH.

Results. The data of 79 patients, who underwent MISP from 2011 to 2016, were analyzed retrospectively. The two study group were formed. The group I: only MISP (n=34). The group II: MISP plus simultaneous inguinal hernia repair (n=17), three bilateral and other unilateral. Three patients in group II underwent simultaneous cystolithotomy additionally. The same surgical approach was used for both groups. The Fisher's exact test was used for statistical analysis. No statistically significant differences (p>0.005) were found in mean age of patients (68 vs 71 years), mean blood loss (416 vs 238 ml), mean operation time (190 vs 221 min) and complications rate (11.7% vs 5.8%) between two study groups. The mean prostate volume was 128 cm³ in both group.

Conclusion. Laparoscopic hernioplasty of inguinal hernia and simultaneous MISP for BPH is save procedure and may be smart option for surgical treatment discussed conditions.

051

SURGICAL TREATMENT OF GASTROESOPHAGEAL REFLUX DISEASE

T. Bitarov, A. Shestakov, A. Tskhovrebov, O. Rykov, I. Selivanova, M. Shakbanov, A. Yurasov, M. Voronov
Petrovskiy National Research Centre of Surgery, Moscow, Russia

Relevance. The incidence of gastroesophageal reflux disease reaches 50-60% and increases every year. The unsatisfactory results of medical treatment, as well as the absence of a standard unified surgical approach, determine a significant interest in this problem. Significant complications after various "modifications" fundoplication require constant search for the most effective, safe and technically simple antireflux surgery.

Object. The aim of this study was to evaluate the effectiveness of the laparoscopic self-modification of fundoplication and compared it with the same open procedure.

Materials and methods. In Petrovsky National Research Center of Surgery modified fundoplication has been performing since 1979. In January of 2008 first laparoscopic similar procedure was performed, and since 2012 it became the antireflux procedure of choice for the treatment of GERB. We had analyzed the clinical records of total 265 patients with reflux-esophagitis, who underwent this procedure in our clinic. The common indications for the surgery were (1) reflux-esophagitis with hiatal hernia and unsuccessful conservative medical therapy (1); Barrett's metaplastic changes in the mucosa (without dysplasia) or peptic stricture formation in the low part of the esophagus (2); shortened esophagus (3); extraesophageal manifestations of GERB (4). The laparoscopic modification includes gastric wrap formation from the top using continuous suture with a tightly bridging of anterior and posterior edges of the gastric fundus by the first upper bite. This operation technique allows creating a symmetrical circular tension-free 360-degrees gastric wrap, preventing vagal nerves trunks injury, torsion and deformation of the stomach, migration and slipping off the gastric wrap. The open procedure is identical to the laparoscopic except that the gastric wrap is formed in an upward direction.

Results. According to the operation technique total 265 patient were divided into two groups: laparoscopic (n = 113) and open (n = 152) fundoplication. The average operation time of the laparoscopic procedure was 74 minutes, post-operative length of stay- 3,5 days. Clinical and instrumental postoperative check-up showed satisfactory immediate results: both 93% of patients after laparoscopic and 94% of patients after open procedure became symptom-free or noted excellent control of GERB symptoms.

Conclusions. Analysis of the results testifies that the Petrovsky National Research Center of Surgery modified fundoplication shows excellent clinical effectiveness in the treatment of the patients with GERD and hiatal hernia regardless of the surgical approach. The mentioned advantages and clinical results make

it possible to recommend RSSC modified fundoplication for the more extensive application.

052

NUTRITIONAL SUPPORT AS A BASIC THERAPY IN A CRONKHITE-CANADA SYNDROME – A CASE REPORT

N. Blazevic¹, A. Biscanin¹, Z. Dorosulic¹, M. Zivkovic¹, I. Pavic², M. Nikolic¹, D. Hrabar¹

¹*Department of Gastroenterology and Hepatology, Clinical Hospital Center Sestre milosrdnice, University of Zagreb, School of Medicine and Dental Medicine, Zagreb, Croatia*

²*University Department of Pathology, Clinical Hospital Center Sestre milosrdnice, University of Zagreb, School of Medicine and Dental Medicine, Zagreb, Croatia*

Introduction. Cronkhite-Canada syndrome is a rare, non-familial gastrointestinal polyposis syndrome, characterized by weight, gustatory and hair loss, diarrhea, ectodermal dysplasia, skin hyperpigmentation and nail atrophy. The pathogenesis of syndrome is unknown, with possible importance of immune abnormalities, infection and allergies. Additionally, mental stress may be important triggering factor. The main goals of treatment include amelioration of diarrhea and weight loss, and improvement of ectodermal lesions. Current literature suggests a combination therapy based on nutritional support and steroids.

Case report. We report a case of a Croatian male who was diagnosed with Cronkhite-Canada Syndrome at 60 years of age, 3 years after his initial symptoms started. The patient initially presented with dyspepsia and gastric hyperplastic polyps, including normal laboratory findings. After initial pantoprasole therapy, complete regression of symptoms occurred. Three years later he was admitted again to Clinical Hospital Center Sestre milosrdnice, presenting with symptoms of hypogeusia, anorexia, weight loss, malaise, chronic diarrhea, hematochezia, hair loss, nail changes and hyperpigmentation of palms. Endoscopic procedures (upper GI endoscopy, anterograde double balloon enteroscopy and colonoscopy) revealed multiple polyps in the stomach (predominantly antrum), duodenum and several polyps in proximal jejunum, distal ileum, ascending and descending colon. Pathohistological examination in duodenum showed infiltration with mononuclear cells and edema of lamina propria, somewhere with dysplasia. In colon, findings suited with diagnosis of non-specific colitis and pseudopolyposis of colon. From February 2012 until November 2013 our patient was hospitalised nine times because of short courses of worsening of the symptoms, presenting with significant diarrhea, gastrointestinal bleeding, electrolyte disbalance and dehydration. Worsening of symptoms almost exclusively was a consequence of serious stressful events in private life or at work. The patient was satisfyingly treated with combination

of parenteral and enteral nutrition. Nutritional support was combined with adequate hydration, electrolyte and albumine infusion. Clinical remission was maintained by enteral nutrition, mesalazine (2-3g daily in two or three divided doses) and pantoprasole. During last two hospitalisations progression of clinical symptoms with significant worsening of hypo-proteinemia with hypoalbuminemia and anemia were present. After short response to steroid therapy, rapid irreversible deterioration of patient's condition occurred, resulting with pulmonary oedema. Patient died 6 years after his initial symptoms appeared.

Conclusion. Our experience supports beneficial effect of nutritional support in treatment of Cronkhite-Canada Syndrome. According to our case, emotional stress can be triggering factor in worsening of the symptoms. Despite all efforts for treatment improvement, the long-term prognosis is poor.

053

ADVANTAGES OF LIVER METASTASES RESECTION COMBINED WITH RADIOFREQUENCY ABLATION FOR PATIENTS WITH COLORECTAL CANCER

M. Bobrakov

Russia

Introduction. Practically in 50% of patients with colorectal cancer (CRC) develops isolated metastatic liver damage. The surgical method is the main one in the combined treatment of colorectal cancer metastases (mCRC) in the liver. Radical liver resections can be performed by almost 20% of patients and reach a 5-year survival rate of 30-40%.

Purpose. Analyze advantages of liver resection combined with radiofrequency ablation (RFA) for the patients with colorectal cancer metastases in the liver.

Materials and methods. In the clinic of Hospital surgery n.a. V.A. Opiel from 2005 to 2017 were treated 93 patients for mCRC liver, 33 of them with the use of RFA. All RFA are performed using the Radionics Cool-Tip Ablation System.

Results of the study. Patients are divided into three groups according to the type of surgical intervention. The first group consisted of 17 patients who underwent RFA of the liver with metastatic sites. The second group consisted of 60 patients who underwent liver metastases resection. The third group consisted of 16 patients with resection and RFA of liver metastases. In the first group 7 cases (41.17%) of simultaneous primary colon tumor removal and operative intervention, in the second group 17 (28.3%), in the third group 3 (18.75%). Bilobar lesions had 5 (29.41%) patients from the first group, 6 (10%) from the second and 14 (87.5%) from the third. Five or more metastases were detected in 3 (17.65%) cases in the first group, 1 (1.67%) in the second group, and 11 (68.75%) in the third. The duration of surgical intervention and the average volume of blood loss depend-

ed on the method of surgical treatment. In the first group, 100.71 minutes; 58.57 ml. In the second group, 198.81 minutes; 736.95 ml. In the third group, 173.24 minutes; 344.12 ml. Early postoperative mortality was 10 patients (16.67%) and was noted only in the second control group. The annual survival was 16 (94.12%), 50 (83.3%), and 14 (87.5%) patients; three-year 11 (64.71%), 46 (76.7%), 12 (75%) patients; five-year 6 (35.29%), 28 (46.7%), 7 (43.75%) patients, respectively, in three groups.

Conclusion. The combination of resection and liver RFA allows to expand indications for surgical treatment of mCRC in the liver in the following cases: with bilobar liver damage, if it is impossible to perform removal of all mCRR by resection methods only, due to small remaining volume and functional insufficiency of liver parenchyma, with liver resection performed earlier; allows to reduce the duration of surgical intervention and intraoperative volume of blood loss in comparison with resection of metastatic liver damage; significantly reduces the risk of early postoperative lethality; demonstrates good survival rates. Simultaneous operations did not statistically significantly affect duration, volume of intraoperative blood loss, and overall survival in groups.

054

THE ROLE OF ORGANIZATIONAL TECHNOLOGIES OF SECONDARY PREVENTION OF FEMALE GENITAL ORGANS CANCER AT THE TERRITORY OF THE CHELYABINSK OBLAST (AS ILLUSTRATED BY EXAMINATION ROOMS)

A. Bochkova², A. Domozhirova^{1,2}, I. Aksenova^{1,2}, M. Zaykova³

¹*Clinical Center of Oncology and Nuclear Medicine of Chelyabinsk Region, Chelyabinsk City, Russia*

²*South Ural State Medical University, Chelyabinsk City*

³*State Budgetary Healthcare Institution 'Municipal Hospital No. 2', Miass City, Russia*

Topicality. The reproductive system cancer is diagnosed in two of five (39 %) cases of malignant neoplasm (MN) in women, of them tumors of female genital organs are found in 18 % of the cases. In the majority of MN cases, a tumor can be revealed upon visual examination, thus, the efficacy of the early MN diagnostics relies upon the primary healthcare setting – examination rooms (ER).

Objective. To evaluate the efficacy of women's ERs within the Chelyabinsk Oblast (ChO) in improving the cumulative adjusted survival rates (CASR) in female patients with MN of genital organs for the period from 2005 to 2015.

Materials and methods. For the period from 2005 to 2015, the cumulative CASR calculations in patients with cervical MN (424), uterine body MN (421), and ovarian MN (203) revealed due to energetic efforts of ERs within the ChO (main group) and in patients with cervical MN (3702),

uterine body MN (5558), and ovarian MN (3679) diagnosed in other settings (during periodic health examination, upon self-referral, by a maternity healthcare center staff, etc.) (control group) were made based on the data of the Population-Based Cancer Registries (PbCR) of the ChO taking into consideration the age of the patients and disease grade. The calculated survival rates were obtained using population-based classical methods of data analysis.

Results. Each year, more than 450,000 women aged 18 years and older (72 % of the initially referred patients) attend examination rooms. In the main group, patients with localized tumor process prevailed: the total percentage of patients with diagnosed cervical MN (I to II grade) was 50.6 % versus 42.3 % in the control group, with uterine body MN - 86.9 % versus 80.2 %, respectively. As for ovarian MN, no significant differences were detected: in more than 60 % of all the cases, ovarian cancer was diagnosed at III to IV grade (61.8 % in the main group and 65.4 % in the control group). No significant differences were revealed during the statistical data analysis with respect to the age-related time periods for both study groups. The highest number of patients with detected cervical MN in the main group and control group were aged between 40 years and 59 years (50 % and 47 % of cases, respectively), i.e., within pre-menopausal and menopausal age. For cases of the uterine body MN and ovarian MN, the age group was 10 years older with age range of 50 years to 69 years (in more than 60 % of cases).

Conclusions. The conducted analysis of the data from PbCR of the ChO showed that the 5-years CASR in patients of all age groups with cervical and uterine body MN of II to III grade detected due to energetic efforts of ER within the ChO improved during the period of 10 years compared to the control group: 78.2 % and 45.1 % versus 70.6 % and 39.9 %, respectively, in patients with cervical MN; 84 % and 53 % versus 66.8 and 42.3 %, respectively, in patient with uterine body MN. As for ovarian cancer cases, no significant differences in the 5-year survival rate were detected (67.3 % and 28.8 % versus 64.6 % and 31.2 %, respectively).

055

REASONS OF UNSUCCESSFUL SURGICAL TREATMENT OF PATIENTS WITH ACUTE BOWEL OBSTRUCTION, CAUSED BY A MALIGNANT TUMOR.

M. Bokarev¹, A. Mamikin¹, E. Muntyanu¹, A. Vodoleev², D. Kryazhev², V. Gogichashvili², A. Markarov²

¹*I.M. Sechenov First Moscow State Medical University*

²*Moscow hospital of A.K. Eramishantcev, Russia*

Introduction. It is well known that surgical treatment of patients with acute bowel obstruction, caused by a malignant tumor (ABOMT), often accompanies with life threatening postoperative complications. These complications prolong hospital staying of patients and make prognosis very uncertain. In some

clinics the lethality rates of these patients exceeds 30%. The division of hospital surgery of the I.M. Sechenov First Moscow State Medical University and the department of surgery of Moscow hospital of A.K. Eramishantcev conducted a retrospective study of the results of surgical treatment of patients with ABOMT through the period of 2005 – 2017.

Aim. The aim of the study was to investigate the main reasons of unsuccessful surgical treatment of patients with ABOMT.

Results. During the period 280 patients were operated on in an open manner. There were 130 (46,4%) males, 150 (53,6%) females. The middle age of the group was 67,1±8 years. An obstruction of the right colon was diagnosed in 74 (26,4%) cases, an obstruction of the left colon and rectum had 206 (73,6%) patients. The duration of obstruction was 3,7 ± 1,6 days. A complicated postoperative course was documented in 185 (66,1%) cases, 65 (23,2%) patients died. To find the reasons of unsuccessful surgical treatment, serious postoperative complications were explored. For better understanding of clinical situation, all complications were divided in medical and surgical (intraabdominal and wound). It was found out that dangerous medical complications had 18 (65%) patients, serious surgical complications demonstrated 36 (12,9%) patients. The analysis of medical complications identify that the most frequent complication was pneumonia – 125 (68,6%) patients. Acute vascular accident (myocardial infarction, stroke, pulmonary emboli) was diagnosed in 22 (7,8%) cases. Multiple organ failure was present in 21 (7,5%) patients. Acute renal insufficiency was found 3 (1,6%) times. Distribution of serious surgical complications has shown that 31 (11,1%) patients had total wound suppuration with visceral eventration. Diffuse or local peritonitis was found in 12 (4,3%) cases. 7(2,5%) patients had necrosis of stoma with its interposition to the abdomen. There were 3(1,1%) small intestinal obstructions and 3 (1,1%) intraabdominal bleedings. In 33 (91,7%) cases surgical complications were in close connection with medical complications.

Conclusion. This study allows us to make some very important conclusions, that move surgeons for further investigations: ABOMT is still a grave disease with high morbidity and high mortality; Surgical treatment is a real danger for development of life threatening complications. Medical complications should be the most important reason for unsuccessful surgical treatment of patients with ABOMT.

056

COMPARATIVE ANALYSIS OF SURGICAL TREATMENT OF THE COMPUTED NON-TUMOR PATHOLOGY OF ANAL CHANNEL AND RECTUM

A. Borota, A. Kukhto, N. Baziyan-Kukhto

National Medical University. M. Gorky Donetsk People's Republic, Donetsk

Relevance. Until now, the diagnosis, differential diagnosis

and surgical treatment of combined non-tumor proctologic diseases is a complex and completely unresolved problem.

Purpose of the study. Conduct a comparative analysis of the results of one-stage surgical treatment of patients with combined non-tumorous pathology of the anal canal (AC) and rectum on the basis of methods of operative treatment developed in the clinic.

Material and methods of investigation. The results of surgical treatment of 1012 patients who were operated at the General Surgery Clinic # 1 on the basis of the proctology department of the Donetsk Clinical Territorial Medical Association for the non-tumor pathology of the anal canal and rectum for the period from 2014 to 2017 are analyzed. Of this group of patients, the combination of hemorrhoids and other pathologies of AC and rectum occurred in 232 (22.7%). These patients made up the study group (SG). Control group 1 (KG-1) comprised 544 (52.1%) patients, operated in the clinic for the same period for hemorrhoids and had only hemorrhoidectomy, control group 2 (KG-2) were 286 (25.2%), patients who were operated in the clinic for acute or chronic paraproctitis and who underwent paraproctectal dissection or excision of the rectal fistula.

Results. The main indication for combined operations with acute paraproctitis, pararectal fistula and chronic anal fissure is the presence of chronic hemorrhoids 2-4 stages. The slight increase in the duration of the operation, the intensity of the postoperative pain syndrome at various times after the operation, the number of complications in the early and late postoperative period, as well as the average bed-day and the periods of rehabilitation are not significant in the study group. After a comparative analysis of the surgical treatment of this category of patients, it was proved that opening the acute paraproctitis with the cutting set in the presence of an extrasfincitorial arrangement of the internal fistula aperture has many advantages over the traditional methods of surgical treatment of paraproctitis, since it is a radical, effective one-stage method of surgical treatment that allows reducing the number of postoperative complications, relapses. The implementation of one-stage surgical intervention in combined non-tumor pathology of the anal canal and rectum does not worsen the immediate and functional results of treatment, relieves the patient from the need for repeated surgical intervention and possible complications.

057

MULTIVISCERAL RESECTIONS WITH COLORECTAL CANCER

A. Borota, A. Kukhto, N. Baziyan-Kukhto

*National Medical University. M. Gorky
Donetsk People's Republic*

Relevance. There is a tendency to increase the primary

incidence of colorectal cancer (CRC) in young and middle-aged people. To increase the radicalism of surgical treatment, multivisceral resection (MVR) are increasingly being used.

Purpose of the study. Based on the neural network model, the Expert System for the Projection of Operational Risk (ESPOR) developed in the clinic, the correction of possible intra- and postoperative complications in the performance of MVR is possible due to the increase in the duration of the intervention, the operating injury and the unplanned volume.

Materials and methods. In the clinic of general surgery on the basis of proctology department Donetsk Regional Clinical Territorial Medical Association for the period from 2012 to 2017 years. About 834 patients were operated on with CRC, 150 (17.9%) patients were operated with MVR. For the correction of possible intra- and postoperative complications in the implementation of MVR in CRC due to the increase in the duration of the intervention, operational injury and unplanned volume, as well as to determine the degree of risk and evaluate the effectiveness of the MVR performance, ESPOR was used.

Results. Despite the duration, the scope of the operative intervention, we believe that the implementation of MVR in CRC is optimal and justified, since the number of complications and the functional results of treatment of patients in this group are not significantly different from the group of patients with standard surgical interventions. To determine the indications for carrying out the MVR, it is necessary to have a clear idea of the location of the tumor, its size, prevalence, histological structure, the degree of germination in neighboring organs and other structures, as well as the presence or absence of distant metastases.

Conclusions. Elaboration of ESPOR intra- and postoperative complications may serve as criteria for determining the risk of surgical intervention, as well as for predicting the evaluation of the effectiveness of the implementation of MVR in patients with CRC in real time. ESPOR intra- and postoperative complications provides a full and effective correction of concomitant pathology in the preoperative period, prevention of intra- and postoperative complications, as well as effective targeted intensive therapy in this category of patients, which in all cases allowed to reduce complications with preserved one-stage surgical radicalism.

058

THE RECONSTRUCTIVE SURGERY STAGING OF COMPLICATED ULCERATIVE COLITIS

A. Borota, A. Kuhto, N. Baziyan-Kuhto

M. Gorky Donetsk National Medical University, Donetsk

Relevance. The problem of timing and staging of complicated ulcerative colitis surgical treatment still doesn't have standartized approach. The decision on surgical intervention

type is always taken individually by the surgeon depending on pathological process severity, patient's general condition the and many other factors. Thus, the question of surgery stages amount for complicated ulcerative colitis patients remains very relevant.

Purpose of the study. The aim was to compare the functional results of complicated ulcerative colitis patients depending on surgical stages amount.

Material and methods of investigation. From 2012 to June, 2018 in Coloproctological Department of Donetsk Clinical Territorial Medical Association (the base of M. Gorky Donetsk National Medical University) 68 patients with complicated ulcerative colitis recieved surgical treatment. The one stage reconstructive surgery (colproctectomy with J-pouch-rectal anastomosis and protective ileostomy) was provided in 38 cases. In 2 of those colproctectomy was laparoscopically assisted. In 24 cases as a first stage the subtotal colectomy with ileo- and sigmectomy was provided. 9 of those later had sigmoproctectomy with J-pouch-rectal anastomosis and protective ileostomy. So, in 47 cases we had reconstructive surgery. 38 – in one stage, 9 – in two stages. In 6 cases the other typrs of surgery were performed, such as colproctectomy, abdomino-pelvineal resection, proctectomy. In follow-up all the patients underwent endoscopy with rectul cuff and J-pouch biopsy, pouchography, MRI, CT with virtual recto-pouchography, QoL questionnaire.

Results. There were no difference between the number and structure of postoperative complications depending on the surgery stages amount. The functional results in a one stage surgery did not differ from those in several stages. The functional results also did not differ in laparoscopically assisted from traditional surgery.

Conclusions. In case of complicated ulcerative colitis the surgery in one or several stages can be performed. Laparoscopically assited colproctectomy is possible.

059

EXPRESSION OF PCA3 GENE IN URINE EXOSOMES AS A NON-INVASIVE MARKER OF THE RISK OF RECURRENT LOCALIZED PROSTATE CANCER

F. Bova

Federal State Budget-Funded Institution "Rostov Research Institute of Oncology" at the Ministry of Health of Russia, Rostov-on-Don, Russia

Relevance. Integration of genetic studies of prostate tumour tissue into clinical practice is constrained by a number of circumstances. The evaluation of gene expression in the tumour tissue is duplicated by the study of other biological media and cellular elements. In this context, identification of informative methods of non-invasive diagnostics allowing to give a description of the underlying disease with due regard

to the tumour microenvironment and the peritumoral zone state, is relevant and practically significant.

Objective. To study PCA3 gene expression in the urine sediment and exosomes in patients with localized prostate cancer (PCa), depending on the histomorphological changes in the peritumoral zone and the presence of biochemical recurrence (BR).

Methods. PCA3 gene expression was determined in samples of the post-massage portion of the urine of 148 patients with localized PCa using RT-PCR method. At the same time, the values of Ct threshold cycles of the studied gene and the reference one were compared. As a reference gene, the KLK3 gene characterized by prostate-specific expression, was considered. The resulting portion of urine was divided into 2 parts: 20 ml of urine was centrifuged to obtain urine sediment (15 min at 3000 rpm) and 50 ml for exosomes (3 hours at 100,000 rpm) and then washed. Depending on the results of the morphological study of the surgical material, patients were divided into the main group (n=96) - combination of the prostate adenocarcinoma and high-grade prostatic intraepithelial neoplasia (PIN-2) in the peritumoral zone, and the comparison group (n=52) - the prostate adenocarcinoma not changed in the peritumoral zone.

Results. The values of median and interquartile range of Δ Ct of PCA3 gene were not significantly different as compared to KLK3 in the urine sediment in the groups studied (-0.02 vs. -0.49; p=0.89). The values of the median of Δ Ct of the gene studied in relation to the reference gene were negative; this fact indicated a higher level of expression of the first gene as compared to the second one. Meanwhile, as a result of subsequent frequency analysis and the cross-tabulation method, it was found that in patients with simultaneous presence of adenocarcinoma and PIN-2 in the peritumoral zone, the decrease of Δ Ct PCA3-KLK3 in the urine sediment was below 1.86 (the differential separation point for PCa as compared to benign prostatic hyperplasia) was more common (40% versus 59%, p=0.04). In urine exosomes in the main group, a higher level of mRNA of PCA3 gene was determined as compared to the comparison group (p=0.04). Δ Ct PCA3-KLK3 median in urine exosomes in the main group was -2.57, and -1.13 - in the comparison group. The retrospective analysis with due account for the 2-year data on the biochemical recurrence of Pca showed that the base level of PCA3 gene expression in urine exosomes of the main group patients was higher (Δ Ct PCA3-KLK3 median -3.17 vs. -1.14, p=0, 02) with subsequent BR as compared to the favourable disease course. In the comparison group, PCA3 gene expression in urine exosomes did not depend on BR presence or absence (p=0.32).

Conclusion. The evaluation of PCA3 gene expression in urine exosomes is informative for determining the risk of the tumour disease recurrence with concomitant changes in the peritumoral zone (PIN-2), and in the urine sediment, in addition, when Δ Ct PCA3-KLK3 decrease is less than 1.86.

060**MOLECULAR FEATURES OF TISSUE EXPRESSION OF HYPOXIA-INDUCIBLE FACTOR AS A PREDICTOR FOR BIOCHEMICAL RECURRENCE OF PROSTATE CANCER****F. Bova, O. Kit, A. Maksimov***Federal State Budget-Funded Institution "Rostov Research Institute of Oncology" at the Ministry of Health of Russia, Rostov-on-Don, Russia*

Relevance. It has been recently revealed that hypoxia-inducible factor-1 α (HIF-1 α) is involved in the activation of transcription mechanisms that affect the proliferation of cancer cells.

Objective. To study the expression of hypoxia-inducible factor of tumour cells in patients with localized prostate cancer (PCa) with biochemical recurrence (BR) after radical prostatectomy (RPE).

Methods. The expression of HIF-1 α protein was evaluated in the tumour tissue samples of 116 patients with localized PCa after RPE using IHC method. The main group (n=56) - biochemical recurrence (BR) was detected within two years after RPE. The comparison group (n=60) - patients with PCa without BR detected. The control group (n=55) - biopsy tissue of benign prostatic hyperplasia. HIF-1 α expression by the number of positive cells (per 1000 cells) and the type of staining in the cell (cytoplasmic, nuclear, mixed) were evaluated. RT-PCR was used to evaluate HIF-1 α gene tissue expression.

Results. When analyzing the contingency between the disease recurring and HIF-1 α protein expression in the tumour tissue of patients with localized PCa, only a tendency (p=0.06) to increase the number of cells with pronounced expression and decrease of the number of cells with poor expression of HIF-1 α factor in the main group as compared to the comparison group was revealed. In the compared groups, HIF-1 α localization in tumour cells was different. In PCa patients with BR, the number of cells with nuclear HIF-1 α localization (73.2%) increased (p=0.04) as compared to the comparison group (53.3%). With the increased risk of PCa recurrence, HIF-1 α expression in tumour tissue and HIF-1 α localization in the tumour cell nuclei significantly increased (p<0.0001). A statistically significant increase in HIF-1 α gene expression by 4.9 times (p<0.001) in the main group and less pronounced increase by 1.8 times (p<0.05) in the comparison group as compared to the control group were determined.

Conclusion. In the primary tumour tissue, nuclear HIF-1 α protein localization coupled with a pronounced increase in the encoding gene expression are predictively significant factors of the early recurrent localized PCa.

061**PD-L1 EXPRESSION IN PATIENTS WITH RETROPERITONEAL LEIOMYOSARCOMAS****V. Bugaev, M. Nikulin, V. Safronova, N. Kokosadze, L. Lubchenko, I. Stilidi***N.N. Blokhin National Medical Research Center of Oncology, Russia*

Background: Leiomyosarcoma is one of the most common type of soft tissue sarcoma. Radical surgical resection and doxorubicin-based adjuvant chemotherapy provide the best chance for achieving cure. Immunotherapy which is based on the blockage of PD-L1 or its receptor PD1 is considered as promising treatment option. Level of PD-L1 expression is thought to be prognostic and predictive marker of disease natural history and effectiveness of immunotherapy.

Purpose: to define rate of positive PD-L1 expression in patients with retroperitoneal leiomyosarcomas and its correlation with clinic-morphological features.

Materials and methods: 21 patients with retroperitoneal leiomyosarcomas which have underwent surgical or combined treatment at N.N. Blokhin National Medical Research Center of Cancer since 2014 to 2017 were retrospectively reviewed. Data recorded included clinic-demographic characteristics, morphological features of tumor and results of surgical resection. Degree of PD-L1 expression in primary tumor were evaluated in 15 patients (4 men and 11 women). Immunohistochemical analysis of tumor paraffin blocks were performed on automatic immunohistostainer BenchMark GX Ventana, Roche with the use Anti-PD-L1 [28-8] ab205921 antibodies in 1:300 proportion according to manufacturer's recommendations. Positive tissue control was performed at every stage of staining. PD-L1 expression were considered to be positive in cases when more than 5% of tissue were stained.

Results. 13 women and 8 men were included in the study. Median age was 57.5 years. 24% of patients (n=5) had G2 leiomyosarcoma, and 76% of patients (n=16) had G3 leiomyosarcoma. With the median follow-up period of 12 months median disease-free survival after radical surgical resection was 13 months, 2-year overall survival – 82%. Radical (R0) surgical resection was performed in 95% of patients, median tumor size was 10 cm. In half of cases combined surgical resection was performed. Positive PD-L1 expression was identified in 20% of patients with the level of expression 5%, 10% and 15% among every single patient. Patients with positive PD-L1 expression had G3 leiomyosarcoma with high Ki-67 index (65-70%). Distant metastases were diagnosed in one patient 18 months after radical surgical resection, while two other patients remain disease-free.

Conclusions: In our retrospective case-study the rate of positive PD-L1 expression was 20%, what can be considered as possible basis for immunotherapy in patients with retroperitoneal leiomyosarcomas.

062

10-YEARS EXPERIENCE OF CELIAC PLEXUS BLOCK WITH SUBSEQUENT NEUROLYSIS IN PATIENTS WITH CHRONIC ABDOMINAL PAIN SYNDROME

M. Burdyukov^{1,2}, A. Nechipay², M. Isakova¹, I. Yurichev¹, O. Malihova¹

¹*N.N. Blokhin National Medical Research Center*

²*FSBEI FPE RMACPE MOH Russia*

Chronic abdominal pain syndrome is present in most oncology diseases of abdomen as well as in chronic pancreatitis after chemotherapy. Despite on development of new drugs and surgical methods of pain management there is still a dilemma as each of the methods has its own complications and deficiencies. One of the methods of pain management is neurolysis under endoscopic ultrasound control (EUS-CPN). The method is very useful and safe. We performed a study to access pain syndrome dynamics after EUS-CPN and reveal the most common pain responses.

Purpose: to analyze the dynamics of pain syndrome after EUS-CPN and reveal most common response pattern to the method.

Design: we enrolled 75 cases from 2006 to 2016 in the study with chronic abdominal pain who suffered from different oncological diseases of abdomen. Before intervention and the day after, as well as at time points at 1,2,4,8 weeks after intervention, questionnaire with visual-analog scale were assessed. Statistical analysis of the date along with most common response patterns to the intervention was performed.

Results: Analysis of difference between baseline pain syndrome level and pain level immediately and during the time of observation after the procedure revealed significantly decrease of pain intensity ($p < 0,05$). Decrease of pain syndrome ranged between 5 and 90 scores, with mean decrease of 55 scores, median 60 scores. In quarter patients' pain decrease ranged between 5 and 40 scores with range of decrease between 70 and 90 scores in other quarter. Based on that, we concluded that EUS-CPN decrease the pain that makes that the procedure is effective method of pain management; median magnitude of pain syndrome decrease was 60 scores that prove significance of the effect on pain syndrome. The most common side-effects were immediately escalation of severity of pain (12%), transitory arterial hypotension (45%), transitory diarrhea (2,6%). No mortality and morbidity were noted.

Conclusion: Results of the study reveals that pain syndrome statistically significantly decrease in comparison with the baseline throughout the observation. There is a tendency to gradual increase in pain syndrome without reaching statistical significance at the end of observation. We recommend EUS-CPN as an additional tool of pain management in oncological patient and chronic pancreatitis after chemotherapy in cases of chronic abdominal pain.

063

RESULTS OF LAPAROSCOPIC HIATUS HERNIA REPAIR WITH NON-TENSION CUFF

M. Burikov, I. Skazkin, O. Shulgin, A. Kinyakin

Rostov-on-Don Clinical Hospital of South District

Medical Center of Federal Medical Biological Agency,

Rostov-on-Don, Russia

At present, the quality of a patient's life after surgery is of an increasing importance to effectively evaluate the surgical treatment. This topic is of particular significance in the assesment of the quality of the postoperative period in the hiatal hernia repair. In order to improve the assessment of the quality of life of patients with hiatus hernia a modification of Neissen fundoplication operation with the formation of a non-tension cuff was proposed (RF patent No. 2529415 of 27.09.2014). To assess the effectiveness of the technique used, the results of treatment of 159 patients with hiatus hernia were scrutinized during a 1 to 5 year post-surgical follow-up. 86 of them were operated on via a non-tension cuff technique, 73 underwent the standard procedure for the Nissen fundoplication. Gerd-Q, GSRS and SF-36 questionnaires were used to evaluate the results, as well as data from instrumental and laboratory studies. In patients with an non-tension cuff, the phenomenon of telescope syndrome was less frequent (2.3%, versus 8.2% in the standard group), reflux disease- 4.5% vs. 9.6%, and cuff hyperfunction 5.8% against 10.9%. This testifies better functional results of applying the technique non-tension cuff formation. There were no recurrences in any group of patients. According to the Gerd-Q questionnaire, with a comparable initial data in the long-term postoperative period, the reflux syndrome is less prevalent in non-tension cuff group of patients (3.36 vs. 4.33). According to the GSRS questionnaire, there are marked differences in the "abdominal pain", "reflux syndrome" and "dyspeptic syndrome" scales, which in our opinion are directly related to the method of cuff formation. In assessing the quality of life, based on the SF-36 questionnaire, it can be concluded that, on all scales, in both groups in the postoperative period there is an improvement in indices, compared to preoperative values. At the same time in the non-tension cuff group of patients, the indicators are somewhat higher. With a total evaluation of the results of standard group a good result of treatment was recognized in 91.8% of cases, satisfactory treatment in 7.69%, unsatisfactory in 2.7%. In the non-tension cuff group, a good result was noted in 94.2%, satisfactory in 5.8%, unsatisfactory results were not noted. As a result, it can be concluded that the proposed method of forming an non-tension cuff demonstrates better results than the traditional method and can be recommended for use in everyday practice.

064**TREATMENT OF GASTRIC GASTROINTESTINAL STROMAL TUMORS****M. Cernat¹, I. Mishin², L. Antochi¹, M. Voizan²**¹*Department of gastric surgery, Oncological Institute from Moldova, Chisinau, Moldova*²*First Department of Surgery "N.Anestiadi" and Laboratory of Hepato-Pancreato-Biliary Surgery, State University of Medicine and Pharmacy "N.Testemitsanu", Institute of Emergency Medicine, Chisinau, Moldova*

Introduction: Gastrointestinal stromal tumors (GIST) are rare malignancies but the most common mesenchymal tumors of the digestive tract. Stomach is the most frequent primary site.

Aim: To analyze the clinicopathologic features, histopathologic and immunohistochemical phenotype and treatment results of gastric GIST.

Material and methods: A retrospective study was done of the database of 73 patients with (c-kit(CD117)(+) GIST treated between 2007–2015.

Results: The study group consisted of 43 patients with gastric GIST, M:F=1:2.3, mean age – 58.07±1.91 (95% CI: 54.21–61.92) years. Main symptom – abdominal pain in 40 patients (93%). Upper gastrointestinal bleeding was the first presenting symptom in 11 cases (27.5%) from which: intraabdominal – 1 case (9.1%), intraluminal – 10 (90.9%). Surgical options: excision of gastric tumor – 6 (13.9%) cases, gastrotomy with tumor excision – 5 (11.6%), gastric wedge resection – 11 (25.6%), partial gastrectomy – 17 (39.5%), total gastrectomy 4 (9.3%). Mean diameter of tumors – 10.2±1.1 (95%CI: 7.93-12.42) cm, proportion of GIST>20cm – 16.3% (n=7). Size of GIST with low risk vs. intermediar/high risk – 5.1±0.38 (95%CI: 4.29-5.88) vs. 14.21±1.53 (95%CI: 11.04-17.38) (p<0.05). Immunohistochemical phenotype of tumors: CD117(c-kit)(+)–43(100%), CD34(+)-39(90.7%), desmin(+)-4(9.3%), vimentin(+)-40(93%), S-100(+)-11(25.6%), SMA(+)-22(51.2%), NSE-6(13.9%). Median number of mitoses in the low risk group – 3.04±0.18 (95%CI: 2.67-3.41), in the high risk group – 25.19±5.57 (95%CI: 13.32-37.05) (p<0.05). Metastases at first presentation were recorded in 6.9% (n=3) cases. Disease progression was recorded in 16.3% (n=7) cases. Complex treatment – surgical and target therapy with imatinib mesylate was performed in 15 (34.9%) patients.

Conclusions: First symptom of gastric GIST can be a complication. Diagnosis is not specific. Surgery remains the main treatment option. Target therapy induces stable disease in the majority of cases.

065**THE ROLE AND MECHANISM OF HUMAN MESENCHYMAL STEM CELLS IN HEPATOCELLULAR CARCINOMA****Chen Jiang, Wu Di, Ji Tong, Jiang Shi, Lin Hui, Xiujun Cai***Department of General Surgery, Sir Run Run Shaw Hospital, School of Medicine, Zhejiang University, Hangzhou, Zhejiang, China*

Human mesenchymal stem cells (MSCs) seems to be a potential vehicle for anticancer drugs due to their strong tumor tropism ability. However, the interactions between MSCs and hepatocellular carcinoma (HCC) are quite controversial and the underlying mechanisms are ambiguous. In this study, we investigated the effect of MSCs on tumor proliferation and motility in 7407 and LM3 HCC cells. The expression level of tumor-associated macrophages (TAM) related markers CD45 and F4/80 as well as IL-6, TNF α , phospho-ERK, phospho-histone3 were also evaluated. Co-culture of HCC with MSC significantly enhanced in vivo tumor proliferation and in vitro metastatic potential. Whole transcriptome analysis of MSC treated HCC cells and controls revealed overexpression of Integrin α 5 (ITGA5) in MSC treated HCC cells. ITGA5 siRNA blocked the MSC-induced invasive and metastasis of HCC. These findings suggest that MSCs play vital role in HCC proliferation and metastasis and could be identified as a putative therapeutic target in HCC.

066**HEPATOCELLULAR CARCINOMA DICTATES SURVIVAL IN PATIENTS WITH DOUBLE CANCERS OF THE STOMACH AND LIVER****Chen Po-Da, Tseng Shang-Ming, Huang Chiun-Sheng, Chen Chiung-Nien, Lin Ming-Tsan***Department of Surgery, National Taiwan University Hospital, Taiwan*

Relevance. Double primary cancer is gaining increasing attention, and recent studies are focused on attaining prolonged cancer survival and employing improved protocols for early diagnosis. Gastric cancer and hepatocellular carcinoma (HCC) are the most-common malignancies in Asia and have been individually studied. However, the clinical features of the combination of these primary cancers remain unclear.

Materials and Methods. In this retrospective study, we accessed our hospital registry and reviewed the medical records of all patients with gastric cancer.

Results. From 1984 to 2016, 6198 patients with gastric cancer were documented in the registry, including 63 patients with HCC. Excluding 6 cases with missing data, we included 21 cases of synchronous cancers, 11 cases of first

metachronous gastric cancer, and 25 cases of first metachronous HCC. A higher proportion of patients with first metachronous gastric cancer tended to have early stage HCC and better survival than those with synchronous double cancers (55 vs. 16.8 months, respectively, $p < 0.05$)

Conclusions. Gastric cancer and HCC are common in Taiwan, and 1% of the population is affected by double primary gastric cancer and HCC. Early Barcelona-Clinic Liver Cancer stage is a good prognostic factor in patients with double primary gastric cancer and HCC.

067

THE ADOPTION OF ROBOTIC HEPATECTOMY FOR HEPATOCELLULAR CARCINOMA

Po-Da Chen, Chao-Ying Wu, Yao-Ming Wu, Ming-Tsan Lin

Department of Surgery, National Taiwan University Hospital, Taiwan

Object. Robotic hepatectomy is a new treatment modality for hepatocellular carcinoma (HCC). However, the perioperative outcomes and oncological results of this approach remain unclear. Herein, we review the current evidence regarding robotic hepatectomy for HCC, and analyze the reported surgical and oncologic outcomes.

Material and methods. A literature review was performed in PubMed, with specific search phrases. The operative characteristics, perioperative outcomes, and oncological results of published robotic hepatectomy case series with HCC cases were extracted and analyzed.

Results. Eighteen series with 726 cases were reviewed, including 351 HCC cases. The overall ratio of major hepatectomy was 33%, and mainly involved right hepatectomy. No series reported perioperative mortality, and the conversion and complication rates were 3.9% and 11.9%, respectively. The most common reason for conversion was intractable bleeding, and most common complications were wound infection and biloma. The mean operative time was longer in the robotic group compared to that in laparoscopic and open groups, while the intra-operative blood loss was comparable. The length of the hospital stay was less for robotic hepatectomy than for open procedures (5-11.7 vs. 10.1 days), and was similar to that for laparoscopic procedures (5-9.5 days). Robotic hepatectomy had comparable 5-year disease-free and overall survival rates to that with open surgery (64.7 vs. 36.9% and 84.3 vs. 77.1%, respectively) and laparoscopic hepatectomy (42 vs. 38% and 65 vs. 48%, respectively).

Conclusions. Robotic hepatectomy for HCC is safe and feasible when performed by experienced surgeons, and achieves comparable oncological outcomes as that with conventional approaches. The adoption of robotic hepatectomy for HCC suggests that more patients in need of major hepatectomy could benefit from this minimally invasive approach. More

experience should be collected to clarify the oncological benefits and cost-effectiveness of robotic hepatectomy for HCC.

068

PROVISION EFFICIENCY OF SURGICAL TREATMENT OF PATIENTS WITH COMPLICATED FORMS OF HIATAL HERNIA

M. Cherkasov, D. Cherkasov, Y. Starcev, S. Melikova, K. Galashokyan

The Rostov State Medical University, Rostov-on-Don, Russia

Relevance: For more than 200 years, the hiatal hernia has attracted the attention of researchers, and despite the undoubted successes in the diagnosis and treatment of this disease, there are many unclear and controversial problems that require further study.

Aim. Improvement of the results of video endoscopic treatment of patients with complicated forms of hiatal hernia.

Materials and methods. We present the experience of 149 video endoscopic interventions for complicated forms of hiatal hernia. Axial hernias were detected in 118 patients, parasophageal hernias in 31 cases. According to the classification of Granderath et al. (2007), among the axial hernias small were found in 35.6% patients, large - in 56.8%, giant - in 7.6% cases, among paraesophageal - in 64.5% patients there were large hernias, 35.5% had giant hernias. All 149 patients had GERD, erosion - in 12.1%, Barrett's esophagus - in 14.1%, stenosis was detected in 3.3% and infringement - in 0.7% of the patient. In 19 patients with Barrett's esophagus in the postoperative period, courses of argon-plasma coagulation were performed.

Results. All 149 patients underwent a Nissen or Nissen-Rosetti operation from laparoscopic access. During the operation, after mobilization of the diaphragmatic legs, the hiatal surface area (HSA) was identified by the formula of Granderath et al. (2007). In case of HSA was more than 15 cm², combined plastic was produced according to the original technique. The mesh implant was fixed in the posterior mediastinum, then posterior crural closure was performed, so as to completely eliminate the contact of the mesh implant with the organs of the abdominal cavity. Intraoperative bleeding was noted in 13 (8.8%) patients, in this case, in 6 patients a conversion was performed, in 2 patients the cause of conversion was a pronounced adhesion process. In the early postoperative period, no complications were noted, also there were no complications associated with the use of mesh implants. Postoperative bed-day in patients with hiatal hernia, operated from laparoscopic access, was 5.2±0.6. In the long-term period, in 2 patients (1.3%) the phenomenon of "cuff sliding" was diagnosed, they underwent second surgical operation from laparotomy access. In the long-term period relapses of hiatal hernia was not noted. Long-term results were evaluated

in 127 patients on the GERD-HRQL scale as good in 87.4%, satisfactory in 11.0%, unsatisfactory in 1.6% cases.

Conclusions. Treatment of patients with complicated forms of hiatal hernia should have a complex approach: medical treatment, antireflux surgery, if Barrett's esophagus is diagnosed - courses of argon-plasma coagulation. Video endosurgical interventions are the operations of choice in the treatment of patients with complicated forms of hiatal hernia. The most optimal variant of plastics the large and giant hiatal hernias is combined plastic with the use of a mesh implant.

069

SCREENING AND EARLY DIAGNOSTICS OF BREAST CANCER (BC)

I. Chernichenko¹, E. Khadzhieva², Y. Gerashchenko¹

¹Medical institution "White Rose"

²NIII named after Almazov, St. Petersburg, Russia

Materials and methods: retrospectively analyzed medical cards (MC) for more than 164,000 women examined in MI "White Rose" for the period from 2012 to 2018. All patients are divided into three age groups 18-40 years, 41-60 years and over 60 years. Electronic data logging and statistical analysis of the indicators were conducted in the "System of Automation of Medical and Insurance Services for Population" CPS "Samson", version 2.5 (Samson Group LLC). The survey interval is 1 year. The statistical data are presented as the arithmetic mean ± standard error of the mean. Methods of examination: anamnestic, examination, palpation, colposcopy, sampling of CM from the nipple (according to indications), ultrasound examination of the MG, x-ray mammography (MMG) from 2 sides in 2 projections. From 2017 it is executed from 35 years 1 time in 2 years and from 50 years annually. The criteria for assessing the presence and absence of MG pathology was based on standard X-ray, ultrasound (US), palpation data on thickness, density, size and ratio of organs and tissues for different age groups, BI-RADS classification, and laboratory indicators.

Results: Over the period from 2012 to 2017, more than 164,000 women were examined in total (11,931 in 2012, 16,866 in 2013, 22,416 in 2014, 26,101 in 2015 43,526 - in 2016, 43,487 in 2017) (an average of 27,388 ± 4,102 per year). 962 cases of breast cancer were diagnosed: 210 (1.76%) in 2012, 118 (0.69%) in 2013, 241 (1.07%) - in 2014, 130 (0.49%) - in 2015, 136 (0.31%) - in 2016, 127 (0.29%) in 2017. (160 ± 21 per year). Analysis of the incidence of BC in 2017: of the central part of MG-9, BC of the upper-inner quadrant MG-8, BC of the lower-inner quadrant MG-11, BC of the upper-bound quadrant MG-63, BC of the lower-lying quadrant MG-7, MG lesions that go beyond the above-mentioned locations -9, MG, unspecified part-18, total-127. According to the results of the comprehensive examination,

patients with formations that require verification and suspicion of breast cancer are referred to specialized centers. In the city oncological dispensary: in 2015-887, in 2016-1806, in 2017. 2084 (1529 ± 361) women. In the advisory scientific and practical center (oncological): in 2015-158, in 2016-89, in 2017. 58 (101 ± 29) women. To the Leningrad Regional Oncology Center: in 2015-2, in 2016-52, in 2017. 42 (26 ± 15) women. In the mammological center St. Petersburg State Medical University named after Pavlov: in 2017. 280 women. Patients with MG diseases that do not require surgical treatment for further diagnosis, dynamic control and treatment are directed to the specialized center "House of Health". For conducting fine-needle aspiration biopsy, ultrasound control, selection of etiotropic therapy: in 2015-321, in 2016-335, in 2017. 336 (330 ± 4) women.

Conclusion: Using the experience of the MI "White Rose" (St. Petersburg) in standardizing the MG survey and routing patients, can improve the early detection, incidence of breast cancer, affect the quality and life expectancy of women, and serve as a starting point for planning regional screening programs.

070

ROBOTIC HILAR CHOLANGIOMYOCARCINOMA RADICAL RESECTION LONG-TERM CASE SERIES REPORT WITH SHORT-TERM COMPARE WITH LAPAROTOMY RADICAL RESECTION

Sai Chou, Zhengyao Chang, Rong Liu, Guodong Zhao

The Department of hepatopancreaticobiliary surgical oncology, Chinese PLA general hospital, Beijing, China

Background: Performing robotic resection for the treatment of hilar cholangiocarcinoma (HCC) is not universally accepted as an alternative approach to open surgery, and only a limited number of such procedures have been reported due to the difficulty of radical resection and the lack of consensus regarding the adequacy of this approach. We aimed to describe our experience with robotic HCC radical resection with long-term outcome and to compared its short-term outcome with those of open HCC radical resection in HCC patients.

Method: We retrospective reviewed medical records of 45 patients who underwent robotic approach (n=16) or open approach (n=29) between January 1st 2016 and December 31st 2016 at the department of HPB oncology surgery in Chinese PLA general hospital. All cases were confirmed by pathology histological.

Result: The retrospective study contains 15 females and 30 males, with mean age was 62.5±9.3. Most common Chief complaint was jaundice (71%) and overall R0 rate was 71.1%. With 23 months follow-up, the median overall survival was 18.75 VS months and 1-year overall survival rate was 57%. Compared with robotic resection group with open

resection group (ORG), there was no statistically significant difference in age, tumor size, resection margin, 30-days mortality and short-term complication including DGE, massive hemorrhage and surgical related infection. However, the robotic resection group show longer operating time ($P < 0.01$), less estimated intraoperative blood loss ($p=0.025$), less fasting days ($P=0.03$), shorter hospital stay ($P=0.03$) and higher hospitalization costs ($P < 0.01$).

Conclusion: Robotic procedures have greatly expanded the applications of liver resection, lymphadenectomy and vascular reconstruction in hilar cholangiocarcinoma. Compared with laparotomy, robotic HCC radical resection could concluded as an equivalence or non-inferiority approach with acceptable long-term outcome.

071

MEAN PLATELET VOLUME (MPV) AS A PREDICTOR OF VENOUS THROMBOEMBOLISM (VTE) IN COLORECTAL CANCER

Wilasrusmee Chumpon¹, Poprom Napaphat¹, Horsirimanont Suthas¹, Supsamutchai Chairat¹, Jirasiritham Jakrapan¹, Siribumrungwong Boonying²

¹Department of Surgery, Faculty of Medicine Ramathibodi Hospital, Bangkok, Thailand

²Department of Surgery, Faculty of Medicine Thammasat University Hospital, Pathumthani, Thailand

Introduction: Platelet activity is a major devilish in atherothrombotic events and cancer. Mean platelet volume (MPV), which is widely available as a routine parameter of the complete blood count, is a potentially useful biomarker of platelet activity in the setting of venous thrombosis. Recent studies showed that high-MPV levels associated with a increase VTE risk in cancer patients.

Aim. To investigate the role of MPV in VTE and colorectal cancer.

Materials & Methods: A retrospective study was performed to analyze differences of MPV between patients with VTE, VTE and colorectal-cancer, and control. Two reviewers independently extracted data for meta-analysis. Differences in MPV were expressed as unstandardized mean difference.

Results: Among 170 patients, 58-control, 54-VTE, and 58-VTE with colorectal-cancer, MPV was significantly higher in VTE groups. From 403 articles, 10 studies (5 cohorts and 5 case-controls) comprising 2,265 patients. MPV was significantly higher in those with VTE (mean difference 0.61 fL, 95%CI 0.34-0.88, $P < 0.001$). Elevated MPV increased the relative risk of VTE (RR 1.319, 1.061- 1.641, $I^2=82.5\%$).

Conclusion: Our evidence suggests that elevated MPV is associated with VTE and VTE with colorectal-cancer. A mechanistic study and RCT are required in order to use antiplatelet therapy.

072

PERSPECTIVES OF CRYOSURGERY IN ABDOMINAL ONCOLOGY

A. Chzhao, D. Ionkin

A.V. Vishnevsky National Medical Research Center of Surgery, Russia

Relevance. The need for a comprehensive study of the prospects of cryosurgery in abdominal oncology.

Aim. To examine the possible development prospects cryotechnology in modern oncology.

Materials and methods. Based on the literature data and personal experience determined the immediate prospects for the development of abdominal cryosurgery. It is necessary to fully develop fundamentally new cryoequipment for their use minimally invasive accesses. Further basic research in the field of cryomedicine.

Results. Experience with different thermal destruction techniques suggests that we should do everything possible to introduce different combinations of local destruction methods. Early studies suggest stimulation of the immune response of the whole organism. Offers significant prospects for a more rational use of chemotherapy in the optimum time after a thermal effect on the tumor.

Conclusion. The cryosurgical method of influencing the tumor, taken as an addition to the standard surgical procedure, allows resection to be more economical and significantly expand the list of suitable patients. A multidisciplinary approach to treatment is key to the treatment of such patients. Cryodestruction must take its rightful place in the treatment of malignant tumors of the pancreas, primary and metastatic liver cancer and considered as a reasonable alternative to existing surgical methods or as a component of combination treatment.

073

CLINICAL OUTCOMES OF ENDOSCOPIC RESECTION FOR COLORECTAL LATERALLY SPREADING TUMORS WITH ADVANCED HISTOLOGY

Ik-Joo Chung, Young-Eun Joo

Department of Internal Medicine, Chonnam National University Medical School, Gwangju, South Korea

Object: Colorectal laterally spreading tumors (LSTs) are large, flat neoplasms that are usually treated using different endoscopic techniques based on their morphology, size, and histology. The aim of this study was to evaluate the clinical outcomes of LSTs with advanced histology treated by endoscopic resection.

Materials and Methods: A total of 246 LSTs with advanced histology (i.e. high-grade dysplasia [HGD] and adenocarcino-

ma [AC]) treated by endoscopic resection (i.e. endoscopic mucosal resection [EMR], EMR-precutting [EMR-P], and endoscopic submucosal dissection [ESD]) were enrolled. Clinicopathological characteristics were collected by review of patient's medical records.

Results: The en bloc resection and R0 resection rates were 75.6% and 85.0%, respectively. The bleeding and perforation rates were 10.2% and 2.4%, respectively. The frequency of cancerous pit pattern and bleeding was significantly higher in LSTs with AC than in LSTs with HGD. The R0 resection rate in LSTs with HGD was significantly higher than that in LSTs with AC. The frequency of comorbidity and cancerous pit patterns in LST cases with submucosal AC were significantly higher than those with intramucosal AC. The mean size of the LST lesion was significantly larger in ESD group than in EMR or EMR-P groups. The frequencies of nodular mixed subtype, cancerous pit patterns, and en bloc resection rates were significantly higher in the ESD group than in the EMR or EMR-P groups. However, the frequency of perforation was significantly higher in EMR-P group than in EMR or ESD groups.

Conclusions: These results indicate that ESD is a more acceptable treatment approach for resection of colorectal LSTs of larger size, with nodular mixed subtype, having a cancerous pit pattern or AC, using either en bloc or curative resection methods, compared to EMR or EMR-P procedures.

074

CRYOSURGICAL EQUIPMENT FOR TREATMENT OF CANCER LESIONS

M. Danichenko¹, D. Ionkin²

¹*Elatomsky Instrument Plant JSC, Ryazan, Russia*

²*A.V. Vishnevsky Institute of Surgery, Moscow, Russia*

Modern cryomedicine allows solving many clinical problems, effectively using different values of extra low temperatures. At the heart of cryosurgical methods of treatment lies the controlled destruction of pathological tissues by freezing them. These methods are used in those cases when traditional surgery is ineffective or causes a significant risk, and when it is necessary to avoid undesirable cosmetic consequences. In order to expand the use of cryomethods in everyday medical practice, especially for areas where cold treatment has already been recognized and disseminated medical procedures for the use of low temperatures, the Elatomsky Instrument Plant JSC team developed the universal cryoapparatus KRIO-01 ELAMED, which allows for local cryosurgery and cryotherapy. As a cryogen is used liquid nitrogen, which ensures a guaranteed freezing or cooling of biological tissue. And although the cryoapparatus belongs to the systems of the expendable type, a wide range of cryogenic influences allows to use the functionality of the product efficiently and comprehensively in medical

institutions of any level, including in performing cavitory operations and in ambulatory practice. The cryoapparatus makes it possible to realize the most popular types of cryotherapy for biological tissue: - contact (applicator) cryodestruction; - penetration (invasive) cryodestruction; - cryospraying - irrigation with a vapor-liquid jet of nitrogen with the purpose of destruction of external pathological formations or obtaining therapeutic effect; - contact cryotherapy (hypothermia); - cryotherapeutic (non-invasive) action by a continuous or pulsed gas jet. The device provides the task and control of temperature, cooling and warm-up speed at the workplace. The size of the iceball is determined using the ultrasound method. The cryoapparatus is a mobile rack and can be equipped with the following specialized cryoinstruments: - general surgical with a working part length of 165 mm and a diameter of 14 mm and a set of replaceable tips for the operating and ambulatory conditions; - for gynecology with a working part length of 245 mm and a diameter of 14 mm and a set of tips; - for laparoscopy with a working part length of 245 mm and a diameter of 11 mm and a set of tips; - for otolaryngology with a working part length of 165 mm and a diameter of 6 mm and a set of tips. All cryoinstruments and replaceable tips can be sterilized. The cryoapparatus contains methodological support, which includes sections on the treatment of neoplasms, application in gynecology, urology, dermatology, cryotherapy. In the framework of joint work with the leading specialists of the "A.V. Vishnevsky Institute of Surgery" the methodical recommendations are prepared: 1) Application of cryoapparatus KRIO-01 ELAMED for primary and metastatic liver cancer (2016); 2) Application of cryoapparatus KRIO-01 ELAMED in pancreatic cancer (2016).

075

LONG-TERM RESULTS OF THE CYLINDRICAL (EXTRALEVATOR) ABDOMINO-PERINEAL RESECTIONS FOR LOW RECTAL CANCER

M. Danilov, A. Atroshchenko, S. Pozdnyakov, G. Saakyan
*Moscow Clinical Scientific Center named after A.S. Loginov
Department of Colorectal Surgery, Russia*

Introduction. Abdomino-perineal resection (APR) is the "gold" standard for surgical treatment of low rectal cancer at present, despite the fact that the rate of sphincter-preserving surgeries increases every year and the role of combined cancer treatment for this localization increases. "Conventional" procedure suggested of K.Miles has a important disadvantages – high rate of positive circumferential resection margin (CRM). These disappointing results led to the search for ways to improve them, and T. Holm proposed a modification of the "traditional" operation and introduced the practice of "extralevator" or "cylindrical" APR. The essence of this procedure is a wide transection of the levator muscles near the sites of their

attachment to the pelvic walls, thus creating an additional layer of tissues, which significantly reduces the frequency of +CRM and local recurrence.

Propose. To assess the long-term results of surgical treatment of patients with low rectal cancer.

Materials and methods. In the period from 2011 to 2014 were performed 72 "cylindrical" APR, the comparison group consisted of 40 patients who underwent "conventional" operation in the period from 2009 to 2011. The tumor stage (pT2-4bN0-3M0) in the groups did not differ, and patients with synchronous distant metastases were excluded from the study. The groups also did not differ in severity of somatic (ASA), oncological status (ECOG) and demographic characteristics. Postoperative mortality in the groups was not recorded. Some parts of patients from both groups underwent neoadjuvant treatment (CT/CRT) - 50% in the tAPR group and 61% in the cAPR group, $p=0.4$. In the tAPR group, the rate of +CRM was 20%, in the cAPR group -2.7%, $p=0.001$. All patients were observed and examined according to the protocol for monitoring CRC. The median follow-up was 52+3 months, the number controlled patients was 98.2% (110 patients out of 112).

Results. In the long term, the rate of local recurrences, 3-year overall, 3-year disease-free, and cancer-specific survival were assessed. In the tAPR group, the frequency of local recurrence was 25% (10 patients), in cAPR - 1.4% (1 patient), $p=0.002$. Nine patients underwent repeated interventions (relapse removal), 2 patients underwent adjuvant treatment. Only one patient developed a local recurrence after CRT. The 3-year overall survival rate in the groups did not differ and amounted to 80% in the tAPR group and 86% in the cAPR group, $p=0.4$. Three-year disease-free survival in the tAPR was - 65%, in the cAPR - 83,3%, $p=0.03$. Three-year cancer specific survival in the tAPR group was 70%, in cAPR - 84,7%, $p=0.03$.

Conclusions. "Cylindrical" APR actually becoming the standard for surgical treatment of low rectal cancer, improving both the immediate (reducing the rate of the positive CRM) and the long-term oncologic outcomes (cancer-specific and disease-free survival). Chemoradiation execution before surgery is a factor in a favorable prognosis.

076

VIDEO FILM ABOUT LAPAROSCOPIC SURGERY FOR LIVER HYDATID CYST

Salam Daradkeh

Jordan University Hospital, Amman, Jordan

Actuality. Common disease in our area with serious complications and lack of efficient medical therapy

The aim. Parasitic disease affecting humans accidentally, with common localization in the liver

Materials and methods. All patients with liver hydatid cysts

are given Albendazole at a dose of 15mg/kg for at least two weeks prior to surgery, then subjected to laparoscopic deroofing following aspiration and injection of Savlon as scolicial agent.

Results. Since 2011, 45 patients underwent surgery, 68 cysts managed by laparoscopy. this technique proved to be safe, efficient and with low recurrence rate on the short follow-up.

Conclusion. Feasible technique, safe , with good results

077

OESTROGEN RECEPTORS: A POTENTIAL THERAPEUTIC PATHWAY IN OESOPHAGEAL CANCER

De Rosa Antonella¹, Al-Khyatt Waleed², Tufarelli Cristina³, Khan Raheela, Iftikhar Syed^{1,2}

¹*Faculty of Medicine & Health Sciences
University of Nottingham, Nottingham, UK*

²*Derby Hospitals NHS Foundation Trust, Derby, UK*

³*Leicester Department of Genetics and Genome Biology,
Leicester Cancer Research Centre
University of Leicester, Leicester, UK*

Introduction: Oestrogen and its receptors play a pivotal role in the development of many cancers, such as breast cancer, where oestrogen receptor (ER) expression has both prognostic and therapeutic implications. Oesophageal cancer is a male dominant disease, with a male: female ratio of 5:1 to 10:1. We hypothesise that ERs are expressed in oesophageal cancer cells and may contribute to the gender bias.

Methods: The expression of ER α and ER β at the mRNA and protein level was determined in female (OE33) and male (OE19) oesophageal AC cell lines using Reverse transcription polymerase chain reaction and western blotting, respectively. The breast cancer cell line, MCF7, was a positive control. ER α and ER β expression in oesophageal cancer biopsy tissue obtained at gastroscopy was determined by immunohistochemistry.

Results: The mean ER α mRNA expression in MCF7, OE19 and OE33 was 24.2(SD \pm 1.0), 4.9(SD \pm 2.4) and 7.1(SD \pm 0.6), respectively, and the mean ER β mRNA expression in MCF7, OE19 and OE33 cell lines was 3.7(SD \pm 0.9), 0.7(SD \pm 0.3), and 4.2(SD \pm 0.3), respectively. The ER α and ER β mRNA expression was significantly different between cell lines ($p<0.0001$). The mean ER α protein density in MCF7, OE19 and OE33 cell lines was 1.2(SD \pm 0.2), 0.1(SD \pm 0.01), and 0.3(SD \pm 0.2), respectively, and the mean ER β protein expression was 0.4(SD \pm 0.2), 0.1(SD \pm 0.03), and 1.0(SD \pm 0.2), respectively. The mean ER β Allred score was 6.8 (SD \pm 1.3) in oesophageal cancer biopsies (n=18). None of the oesophageal cancer biopsy specimens demonstrated ER α protein expression at immunohistochemistry.

Conclusions: ER β is the dominant ER subtype expressed in oesophageal cancer cell lines and human cancer tissue.

Further studies to define the role of the ER β subtype in oesophageal cancer are needed.

078

TAMOXIFEN: A NOVEL TREATMENT OPTION IN OESOPHAGEAL CANCER

De Rosa Antonella¹, Al-Khyatt Waleed², Tufarelli Cristina³, Khan Raheela¹, Iftikhar Syed^{1,2}

¹*Faculty of Medicine & Health Sciences, University of Nottingham, Nottingham, UK*

²*Derby Teaching Hospitals NHS Foundation Trust, Derby, UK*

³*Leicester Department of Genetics and Genome Biology, Leicester Cancer Research Centre, University of Leicester, Leicester, UK*

Introduction: Tamoxifen has been the gold-standard treatment for oestrogen receptor (ER) positive breast cancer for over 30 years. Tamoxifen works via ERs and has either agonist or antagonistic effects dependant on the target tissue. Oesophageal cancer cell lines and oesophageal cancer tissue express ERs and we hypothesise that tamoxifen inhibits oesophageal cancer cell growth in-vitro.

Methods: The expression of ER α and ER β at the mRNA and protein level was demonstrated in OE33, oesophageal AC cell lines using reverse transcription polymerase chain reaction and western blotting, respectively. The effect of tamoxifen at five different concentrations (1 – 10,000nM) on cell proliferation was assessed using 5-bromo-2'-deoxyuridine (colorimetric) assay. In an attempt to support changes in proliferation changes in the expression of the following proliferation-associated proteins with tamoxifen treatment were investigated by western blotting: Ki67, PCNA, Cyclin D and E-cadherin.

Results: Tamoxifen significantly inhibited OE33 proliferation in a dose-dependent manner. Importantly, a tamoxifen dose of 100nM, the concentration achievable in-vivo in humans with standard dose tamoxifen administration, significantly inhibited OE33 cell proliferation ($p < 0.0001$). There was no significant change in the expression of Ki67, PCNA, Cyclin D or E-cadherin with tamoxifen treatment.

Conclusion: This in-vitro study on oesophageal cancer cell lines demonstrates tamoxifen inhibits cell growth in a dose dependent manner. The mechanism of action of tamoxifen in oesophageal cancer is still undetermined and warrants further investigation, as does the effect of tamoxifen on oesophageal cancer growth in-vivo.

079

THE INFLUENCE OF THE DIFFERENT FORMS OF APPENDIX BASE CLOSURE ON PATIENT OUTCOME IN LAPAROSCOPIC APPENDECTOMY. A RANDOMIZED TRIAL

Samir Delibegović, Zlatan Mehmedovic

Department of Surgery, University Clinic Center Tuzla, Bosnia and Herzegovina

Objective. The aim of this study was to compare the clinical outcomes of various forms of securing the base of the appendix, in order to find the most suitable method.

Background. During laparoscopic appendectomy (LA), the base of the appendix is usually secured by an Endoloop ligature or stapler. A non-absorbable plastic Hem-o-lok clip and titanium DS clip have been shown as alternative techniques.

Patients and Methods. The study included 120 patients with acute appendicitis, randomly divided into four groups, with 30 patients in each. In the first group the base of the appendix was secured using an Endoloop ligature, in the second group using a 45-mm stapler, in the third group using non-absorbable XL Hem-o-lok clip, and in the fourth group using a titanium DS clip. The primary outcome was taken to be overall morbidity following securing the base of the appendix. Secondary outcomes were time of application, time of operative procedure, total length of stay and surgical outcome.

Results. No morbidity was recorded in any group. The time of application was statistically significantly longer in the Endoloop group than in the Stapler ($P < 0.0001$), Hem-o-lok ($P < 0.0001$) and DS clips ($P < 0.0001$) groups. The time of application in the Stapler group was statistically significantly shorter than in the Hem-o-lok ($P < 0.0001$) and the DS clips ($P < 0.0001$) groups. The time of the surgical procedure was statistically significantly longer in the Endoloop than in the Stapler group ($P < 0.0001$). The time of the surgical procedure in the Stapler group was statistically significantly shorter than in the DS clips group ($P < 0.0001$) but did not differ statistically significantly from the Hem-o-lok group ($P = 0.199$), which was statistically significantly shorter than in the DS clips group ($P = 0.044$). However, the price of one PDS Endoloop is 38.10 EUR, Vycril 36.99 EUR, for the stapler the price is 167.7 EUR, for one Hem-o-lok clip 7.5 EUR, and for a DS clip 20 EUR.

Conclusion. All forms of closure of the appendix base are acceptable, but plastic and titanium clips have the best potential for further development, and will probably become the method of choice in securing the base of the appendix.

080

ENDOSCOPY-ASSISTED LAPAROSCOPIC TRANSGASTRIC RESECTION OF A GASTRIC GASTROINTESTINAL STROMAL TUMOR (GIST) LOCATED IN THE CARDIA NEAR THE GASTROESOPHAGEAL JUNCTION: FIRST INSTITUTIONAL EXPERIENCE

Delos Santos-Belen, Krista Angeli Parayno, Mendoza Miguel C, Atazan Judy Carissa M.

Asian Hospital and Medical Center, Filinvest Corporate City, Alabang, Muntinlupa, Philippines

Actuality. Cooperative laparoscopic and endoscopic surgery for the management of gastric gastrointestinal stromal tumors (GIST) have been developed in the past years and of which different variations have been conducted by institutions abroad with promising results. In the Philippines, minimally invasive surgical approach to gastric tumors have yet to be accepted by gastroenterologists and surgeons alike. **Aim.** This report aims to describe our institution's first experience in performing an endoscopy-assisted laparoscopic transgastric resection of GIST, with the goal of integrating the intraluminal and extraluminal approach to be able to identify precise lesion location, achieve negative surgical oncologic margins, and perform reconstruction with good functional outcome.

Materials and methods. This is a case of a 33 year old female, diagnosed with gastric GIST, who presented with epigastric pain, melena, and anemia. Preoperative evaluation consisted of endoscopy with ultrasonography and abdominal CT scan, which showed a 3.3x1.9 cm submucosal mass located just below the gastroesophageal junction (GEJ) in the posterior wall of the cardia, with no evidence of nodal or distant organ metastasis. Due to the proximity of the tumor to the GEJ, an endoscopy-assisted laparoscopic transgastric resection was performed.

Results. Standard position and port placement for laparoscopic gastric surgery was done. The key steps for this technique are as follows: 1) Liver retraction for adequate exposure of the proximal stomach, 2) Mobilization of the greater curvature of the stomach, 3) Endoscopic localization of the tumor, 4) Laparoscopic longitudinal gastrotomy in the anterior wall overlying the tumor upon transillumination using the gastroscope, 5) Eversion of the tumor thru the gastrotomy then stapled resection along the submucosal-muscularis layer with 1-cm margins, while the gastroscope is inserted to ensure patency of the GEJ lumen, 6) Stapled closure of the gastrotomy with reinforcement using absorbable continuous sutures, 7) Endoscopy after closure of the defect to check for completion of resection, patency of the GEJ lumen, bleeding, and leakage upon air insufflation. 8) Use of specimen bag for extraction to prevent tumor rupture or spillage. Short term outcomes evaluated during the immediate postoperative course, on 1-week and on 1-month followup included: postoperative bleeding, anastomotic leakage, and surgical site infection, none of which

were reported. Final histopathology report revealed a 3x3x2 cm mass consistent with GIST, with negative margins, and mitotic rate 15/50hpf. Adjuvant imatinib therapy was recommended based on predicted intermediate risk for malignant potential and recurrence.

Conclusion. This technique is specifically advantageous for lesions located in the posterior wall and near the GEJ, where preserving the lumen is crucial, while also adhering to standard oncologic principles. The safety and efficacy of this combined approach depends on the expertise and coordination of the gastroenterologists and laparoscopic surgeons.

081

LAPAROSCOPIC SURGERY IS A NECESSARY STANDARD FOR THE TREATMENT OF LIVER ECHINOCOCCOSIS

Demin DB, Funygin MS, Sobolev Yu.A., Solodov Yu.Yu.
Orenburg State Medical University, Russia

Echinococcosis of the liver is a frequent pathology, and the surgery for this condition has traditionally remained laparotomic. As supporters of minimally invasive methods, we perform laparoscopic surgeries for for this disease.

Objective: to evaluate the effectiveness of laparoscopic surgery in patients with liver echinococcosis.

Material and methods. In 2014-2018 in the University Clinic of Surgery on the basis of the Pirogov Hospital, Orenburg, we performed laparoscopic interventions for liver echinococcosis in 30 patients. Liver resection was performed in 19 patients, and echinococcectomy in 11 cases. Methods of resection intervention: in 10 cases atypical segmental resections, in 7 cases resection of the left lateral sector, in 2 cases - resection of the right lateral sector.

Results. The lesion's size varied from 4 to 12 cm in diameter. With frontal and lateral cysts, the patient's operating position is in supine decubitus. When the formations are found in S VII-VIII, we operate patient lying on the left side, which allows, after crossing the right triangular ligament and dissection of the area nuda, to obtain the necessary access to the posterior segments. In two cases there were paired cysts with a diameter of 10 cm in S VI-VII and S V-VIII in the shape of the sandglass, in others - the cysts were simple. In one case, liver resection was performed for recurrent echinococcus S IV, which was already operated twice in another clinic by laparotomy. During our interventions, ultrasonic energy and a bipolar coagulator were used. If necessary, additional hemostasis was performed with a monopolar ball electrode, using local hemostatic agents (tachocomb, surgicel). When visualizing resected tubular structures along the line, they were additionally stitched with nodal sutures. By default, preference was given to resection techniques. The choice of echinococcectomy was taken due to the intimacy of the main tubular structures of the liver revealed by computed tomography. The method of

laparoscopic echinococectomy was similar to laparotomic interventions, in addition, we excised the most of the fibrous capsule with adjacent areas of the liver to minimize the size of the residual cavity. We didn't fill the remaining cavity with any material (no capitonnage technique). There were no conversions, complications or fatal events. In one observation after the resection, a slight biliary leakage through the insurance drainage was observed, it stopped spontaneously in 5 days. Drainage tubes were removed in 3-5 days. There was an obligatory ultrasound control before discharge. There weren't any residual cavities visualised. All patients were discharged on the 7-8th day after the surgery, and during our follow-up period, the recurrence of echinococcosis has not yet been revealed. Thus, according to our results, laparoscopic surgery of liver echinococcosis is safe and effective, which may mean that an extensive generalization of this intervention technique is needed in this condition because preference should be given to resection techniques that reduce the risk of residual cavity formation and relapse of the disease.

082

THE EFFECT OF WOUND PROTECTOR TO DECREASE THE SURGICAL SITE INFECTION IN OPEN ABDOMINAL SURGERY, DOUBLE-BLIND PROSPECTIVE RANDOMIZED CONTROLLED TRIAL

A. Deeprasertvit, Ph. Tuntivararut, W. Jiramarit
Department of Surgery, Police General Hospital, Bangkok, Thailand

Background. Surgical site infection (SSI) is the most common cause of postoperative morbidity after the laparotomy. Many independent factors shows to increase risk of SSI. Prevention of SSI is very important especially intraoperative period.

Methods. Patients undergoing a standard midline laparotomy were prospectively randomized to use or not use a wound protector between September 2016 and January 2018. The 128 patients were eligible for the study. All demographic data and surgical variability of the 2 groups are no significantly difference. Preoperative and perioperative data, those can be risk factors for SSI, were collected for analysis.

Results. Wound protector was used in 64 patients (WP group) and not used in 64 patients (Non-WP group). One patient in non-WP group dead from non-SSI related condition. Three patients (1 patient from non-WP and 2 patients from WP group) undergone re-operation before 30 days without any wound complication. Surgical site infection was occurred in 30 patients (24%), with significantly higher incidence in Non-WP group than WP group (17.7% vs 6.5%, P-value 0.006). Multivariate analysis revealed that placement of a wound protector could decrease the incidence of SSI (odds ratios [OR] 0.269, 95% confidence interval [CI] 0.109-0.667). Many specific conditions that wound protector could prevent the

SSI were found.

Conclusion. Intraoperative wound protector placement is effective for decreasing the incidence of surgical site infection in the major laparotomy operation.

Keywords: intra-abdominal operation; Laparotomy; Surgical site infection; Wound protector; Wound retractor.

083

MINIMALLY INVASIVE TREATMENT OF PARASITIC LIVER ABSCESS

A. Detochkin, V. Zurnadzhyants, E. Kchibekov
Astrakhan State Medical University, Russia

Actuality. Treatment of liver abscesses remains one of the important problems of modern surgery. Practically all abscesses of the liver require surgical treatment. Unfavorable results can be from 16.9 to 55.0% [6, 12]. The percentage of diagnostic errors in liver abscesses reaches high figures - 45.5%, and the use of ultrasound and CT can reduce it to 7.8% [2]. The main principles of surgical treatment of abscesses are opening of the purulent focus, its sanitation and drainage of the existing cavity [4, 10, 15]. Traditional methods of operative interventions often lead to various complications [3, 14, 18] and high postoperative lethality, which, according to some authors, is 15.2 to 54% for subdiaphragmatic abscesses and 16.9 to 55% for abscesses liver. For today the most common methods of treatment of abscesses of liver are percutaneous puncture and drainage.

The purpose of the study. Improve the results of treatment of patients with liver abscesses by using low - invasion interventions under the supervision of ultrasound.

Materials and methods: The analysis resulted in the treatment results of 489 patients with liver abscesses from 2007 to 2013, while working in the Republic of Angola, where the authors were on a business trip. There were 272 women, 217 men, and 15 of them children under 14 years old. The age of patients ranged from 3 to 87 years. Single abscesses were in 278 (56.8%) patients. Multiple abscesses (2 abscesses and more) - in 211 (43.2%) patients. Abscesses in the initial stage - 116 (23.7%) patients. Purulent abscesses - 373 (76.3%) patients. Percutaneous drainage of liver abscesses was performed on the day of receipt under ultrasound control, trocars with a diameter of 4 to 8 mm from Kendall Argyle (USA). The operation was performed under local anesthesia with 10-20 ml of a 1% lidocaine solution. In the presence of a pig-capsule, the operation resulted in active drainage (57 patients (11.6%)). Active aspiration was carried out by vacuum systems with a volume of 250 ml produced by JSC Medpolimer, Russia. All patients underwent antibacterial and antiparasitic therapy with ceftriaxone and metronidazole in medial dosages corresponding to the mass of patients and their age. Sanitation of the abscess cavity was carried out with a solution of metrogil 10-50 ml

once a day for 3-4 days. With multiple abscesses, the largest cavities (from 2 to 4) were drained, with simultaneous puncture of cavities up to 35 mm in diameter. If necessary, after 2-4 days, the remaining purulent cavities were drained through existing punctures or through additional punctures. Uzi control was performed daily to correct the position of drainage in the cavity of the abscess.

Results. As a result of the treatment, the results of treatment of patients with this pathology were significantly improved, the duration of inpatient treatment was reduced, and mortality decreased dramatically. Long-term results were studied in 352 (71.9%) patients. Relapses were noted in 3 (0.6%) in terms of 3 to 9 months. Lethality was 0.4% (2) of patients.

Conclusion: The use of minimally invasive interventions under the supervision of ultrasound research allows to achieve good results in the treatment of this pathology.

084

OPEN SURGICAL CONVERSION FOR DIFFICULT LAPAROSCOPIC CHOLECYSTITIS. STILL VALID OPTION?

Isidoro Di Carlo

Department of Surgical Sciences and Advanced Technologies, University of Catania, Italy

In case of acute cholecystitis, laparoscopic approach can be today considered the standard of treatment. Open surgery, anyway, or as the result of a conversion, or as the first approach in the most difficult cases, still remains a safe procedure both for the patient and for the surgeon. A certain number of previous publication analyzed the anatomic situation that most of all can lead to a conversion (buried gallbladder, impacted stones in the infundibulum, bad visualization of the critical view of safety etc.) but no paper except for a survey to Japanese, Taiwanese and Korean surgeons speak about the importance of the duration of the surgery in the decision process leading to conversion. The Tokyo Guidelines published in the early months of 2018 describe the so called "bail-out" procedures: the techniques for subtotal cholecystectomy. Fenestrating cholecystectomy and Reconstituting cholecystectomy are the techniques described for go on a subtotal cholecystectomy. We think that the reconstituting technique can guarantee the best results if the distance of 1 cm from the infundilum is respected when the remnant of gallbladder is sutured. The perception that the rate of compliances is superior in open surgery is invalid because the patients treated with open surgery are the ones in the worst conditions (general conditions and anatomical conditions). Surgeons have to use the technique that better know, but subtotal cholecistectomy represents the technique that better preserve the patients from complications. Some surgeons experienced the conversion as a failure in their activity but thinking in terms of long term results this can be a succes for both surgeon and patient.

085

SEVERE PANCREATITIS PRESENTED AS HEMORRHAGIC SHOCK TREATED BY DAMAGE CONTROL SURGERY

Doklešić Krstina¹, Lončar Zlatibor¹, Vasin Dragan²

¹Clinic for Emergency Surgery, Clinical Center of Serbia, Belgrade, Serbia and University of Belgrade, Faculty of Medicine, Belgrade, Serbia

²Department of Radiology, Clinical Center of Serbia, Belgrade, Serbia

Introduction. We report a rare case of pancreatitis that presented as uncontrolled bleeding and hemorrhagic shock. Presentation OF CASE A 58 year-old male was admitted to the Emergency Surgery from a regional hospital with diagnosis of ruptured abdominal aneurysm with severe bleeding. In the patient's medical records was found that in the past he had upper abdominal pain with elevated levels of serum amylase and lipase, but he was not treated for pancreatitis. On admission he was presented with organ failure and hemorrhagic shock, hypotension (<70 mmHg), acidosis (pH < 7.25), coagulopathy (INR ≥ 1.7) and he received massive (>7 RBC) blood transfusion. Massive active abdominal bleeding and retroperitoneal hematoma was detected with a contrast-enhanced computed tomography (CT), with abdominal aortic aneurysm without dissection, source of abdominal bleeding could not be precisely located. Due to uncontrolled bleeding patient underwent emergency laparotomy. Major intraoperative findings were hemoperitoneum, huge retroperitoneal hematoma and pancreas destruction. Damage control surgery (DCS) was performed with rapid control of bleeding, abdominal packing and temporary wound closure. Reassessment of the vital parameters started immediately, continued with restoration and physiological stabilization in the intensive care unit (ICU). After 48h in ICU patient was stabilized and we approached to re-exploration, surgical repair with removal of the dead pancreas tissue (necrosectomy), peritoneal lavage and we performed jejunostomy tube feeding. Postoperative patient was intensively treated according to protocols for severe pancreatitis. Control CT detected residual pancreas inflammation with infected pancreas necrosis and without further bleeding. After 3 weeks patient underwent second re-laparotomy and necrosectomy of focal areas of nonviable pancreatic parenchyma. Hospital stay was 34 days and he was discharged in good condition. Patient underwent follow-up intensively over the next 15 months with pancreatic contrast-enhanced ultrasound and CT, he has an incisional abdominal wall hernia as only complication.

Conclusion. Hemorrhagic shock is a rare life-threatening complication of pancreatitis. It is important to be aware of pancreatitis-related bleeding that can be potentially lethal if not recognized and emergency treated. DCS can be lifesaving in critically ill patients with pancreatitis-related bleeding.

086

CYANOACRYLATE CLOSURE OF INCOMPETENT SUPERFICIAL VENOUS TRUNKS

S. Drobyazgo¹, A. Manaev¹, D. Chechetka²

¹*Crede Experto Clinic, Moscow, Russian Federation*

²*Far-Eastern State Medical University, Khabarovsk, Russian Federation*

Introduction: VenaSealTM is the only approved method in Russian Federation of non-thermal and non-tumescent vein ablation. It has been proven as effective as open surgery or thermal ablation. The procedure is safe without any potential serious adverse events and may be performed as a single treatment option without miniphlebectomy. Postoperative compression stockings are also not required. However, per available data it has been observed that in 14-24% of patients post-procedure recovery is temporarily accompanied by thrombophlebitis.

Purpose: to report results of VenaSeal procedures in selective cases achieved by removing large tributaries with lower incidence of superficial phlebitis.

Materials and methods: since July 2017, total 36 patients (mean age 51 ± 12 , 75% of women), with 54 incompetent vein trunks (39 GSVs, 7 SSVs and 8 accessory saphenous veins) were treated. In 15 patients (42%) concomitant miniphlebectomy was also performed. Only most prominent, contouring under the skin varices were removed. In such cases, patients were prescribed compression socks for 3-5 days to reduce bruising. Local anaesthesia was used and no sedation was required. Patients were examined post-operatively on Numerical pain rating scale, Venous Clinical Severity Score (rVCSS) and Aberdeen Varicose Vein Questionnaire. Subsequently a post-procedural follow-up examination was performed with ultrasound on day 3 and after 1, 3, 6, 12 months.

Results: the follow-up period was 5,5 (1-12) months. The average diameter of the trunks was 7,8 mm (from 5,6 to 19 mm). Treated veins were completely closed after 1 month. Partially recanalized segment up to 5 cm in length was detected in 1 trunk after 6 months of follow-up. Mean pain rating after procedure was 1.5 of 10. All patients showed significant improvement in rVCSS and Aberdeen Varicose Vein Questionnaire postoperatively ($p < 0.001$). Serious complications were not registered. Two (5,5%) of 36 patients developed phlebitis. One patient had a hyperemic skin reaction in the site of the glued vein. The other one had tributary phlebitis below knee. Both patients fully recovered in 3-5 days with the topical anti-inflammatory agents.

Conclusion: VenaSealTM closure system is safe and effective treatment for the ablation of incompetent venous trunks. The frequency of postoperative phlebitis can be reduced by removing large varicose branches. Additional studies are required to confirm this hypothesis.

087

USE OF ULTRASOUND ELASTOGRAPHY IN DIFFERENTIAL DIAGNOSIS OF PANCREATIC CYSTIC LESIONS

E. Drozdov¹, A. Koshelev², T. Dibina³

¹*Tomsk regional oncology hospital, Tomsk, Russian Federation*

²*City clinical hospital No 3 of B.I. Alperovich, Tomsk, Russian Federation*

³*Medical centre G.K Zherlov, Seversk, Russian Federation*

Relevance. Increases in the quality as well as utilization of cross-sectional imaging have led to rising diagnosis of pancreatic cystic lesions (PCL). The differential diagnosis of PCL is an increasingly common clinical challenge.

Object. The aim of this study was to evaluate the effectiveness of ultrasound elastography in the differentiation of PCL. **Materials and methods.** From May 2016 to October 2017, 70 consecutive patients (31 men, 39 women) with PCL were enrolled for this study. Gray-scale conventional B-mode US and shear wave elastography (SWE) were performed for all patients using the same US machine (Aplio – 500, Toshiba, Japan) equipped with a convex ultrasound transducer. SWE was performed after B-mode examinations. The lesions were placed in the middle of the field of view, and the probe was stabilized under the lesions. After 4–6 s, steady elasticity images were recorded for each lesion. The parameters assessed using SWE were: mean elasticity within the entire lesion (ME, kPa), standard deviation (SD, kPa) and SWE-ratio (SR) between target and referent zones

Results. Based on the results of the studies, the following data were obtained. SWE parameters for pancreatic pseudocyst: ME - 16, SD - $\pm 2,27$, SR - $2,4 \pm 0,72$; for serous cystadenoma ME - 30, SD - $\pm 7,4$, SR - $1,3 \pm 0,86$; for mucinous cystadenoma ME - 78,5, SD - $\pm 11,6$, SR - $3,2 \pm 0,55$; for mucinous cystadenocarcinoma ME - 100, SD - $\pm 10,6$, SR - $8 \pm 1,9$. The area under the ROC curve for the SWE model was 0,93 ($p = 0.028$) (Fig 1). Thus, with a SR < 5 units, the presence of a benign process is most likely; in the case when the SR more than 5 units - presence of malignant process is more likely. The sensitivity, specificity, accuracy, positive predictive value, and negative predictive value of the elastography in the differential diagnosis of PCL were 97%, 75%, 84%, 97% and 84%, respectively ($p = 0.0001$).

Conclusions. The results of our study suggest that ultrasound elastography is a promising technique that is easy and rapid to perform and can help in the differential diagnosis of benign and malignant PCL.

088

JEJUNAL PANCREATIC HETEROTOPIA MIMICKING METASTATIC DISEASE IN A PATIENT WITH RENAL CELL CARCINOMA: A CASE REPORT

B. Dudyemi¹, Y. Ashie¹, N. Titiloye¹, R. Azorliade², A. Boateng¹, A. Yifieyeh², B. Petershie²

¹Department of Pathology, Kwame Nkrumah University of Science and Technology, Kumasi, Ghana

²Department of Surgery, Komfo Anokye Teaching Hospital, Kumasi, Ghana

Introduction: Ectopic pancreas is defined as a pancreatic tissue without any vascular or ductal communication with the orthopic pancreas. It is a congenital anomaly that is thought to arise from a separation of pancreatic tissue from the pancreatic buds during their embryological rotation and fusion or a persistence of a duodenal evagination involved in the normal development of the pancreas and this remnant can migrate with the developing gastrointestinal tract accounting for its various locations. A third theory suggests pancreatic metaplasia of the endodermal tissue in the gastric mucosa. It is a relatively rare disorder (2-15%) usually an incidental finding in patient suffering from other diseases that require laparotomy or during post mortem examinations. The most common site of occurrence is the gastric antrum (25 to 38%) followed closely by the duodenum and the jejunum. Other rare locations include the ileum, colon, splenic hilum, liver, gall bladder, biliary tract, mesentery, mediastinum and fallopian tubes. We present a case of pancreatic heterotopia in the jejunum of a 46 year old male with renal cell carcinoma thought to be a metastatic disease.

Methodology: This was a rare picked incidentally from routine reporting of histopathology slides of a patient who had nephrectomy for renal cell carcinoma whose left kidney was sent with nodular tissue found in the jejunum.

Result: The left kidney showed renal cell carcinoma (clear cell variant) while the jejunum showed normal pancreatic tissue including ducts, acini and islet cells within the sub-mucosa and the muscular layer (Type 1 pancreatic heterotopia according to Heinrich's classification).

Conclusion: Jejunum is a possible site of ectopic pancreas although it is rare compared to the stomach and duodenum.

089

USE OF SPECIAL STAINS IN THE DETECTION OF VASCULAR INVASION IN HISTOLOGICALLY CONFIRMED COLORECTAL CANCER

B. Dudyemi¹, E. Adankwah², N. Titiloye¹, D. Andoh², D. Agyemang², A. Yifieyeh²

Departments of ¹Pathology and ²Medical Laboratory Science, Kwame Nkrumah University of Science and Technology, Kumasi, Ghana

³Department of Surgery, Komfo Anokye Teaching Hospital, Kumasi, Ghana

Background: Venous Invasion (VI) is a well-established independent prognostic factor in colorectal cancer (CRC) associated with haematogenous spread and high risk of mortality. Its accurate detection is, however, essential in identifying a high risk group of patients who may benefit from adjuvant therapy and also to detect the risk of disease recurrence. Our study sought to determine the value of an elastic tissue stain in assessing vascular invasion in colorectal cancer.

Methodology: Formalin fixed paraffin-embedded (FFPE) colonic tissue blocks were retrieved from the archives of the histopathology department of the Komfo Anokye Teaching Hospital. Duplicate sections were made from each block and divided into two with one part of the sections being stained with Haematoxylin and Eosin (H&E). The other part of the sections was stained with Vierhoeff Van Gieson (VVG) stain. Both H&E and VVG stained sections were assessed for the incidence of vascular invasion. Findings were put in tables and charts.

Result: 41 cases were used for our study comprising 40 adenocarcinomas (6 well differentiated, 26 moderately differentiated and 8 poorly differentiated); and 1 high grade NHL. The mean age of our patient was 55 years with a M:F ratio of 1:1.4. Of the 41 sections stained with H&E, venous invasion was detected in 14 cases representing 34% while VVG detected venous invasion in 18 cases constituting 44%. VVG was found to increase the detection rate of venous invasion.

Conclusion: The application of the VVG elastic tissue stain enhanced the sensitivity of detecting venous invasion as compared to the use of H&E alone and thus recommendations should be made to include elastic tissue stains in colorectal cancer pathology reporting.

090

MULTI-CHAMBER LIVER ECHINOCOCCOSIS PERCUTANEOUS TREATMENT IN HUMANS

V. Durlshter¹, Y. Kirtanasov^{2,3}, A. Andreev⁴

¹Surgery Department No 3 FPK and PPS FGBOU VO KubGMU, Ministry of Health of Russia, Krasnodar, Russia

²Ultrasonic Diagnostics Department FPK and PPS FGBOU VO RostGMU, Ministry of Health of Russia, Rostov-on-Don, Russia

³X-ray Surgical Diagnosis and Treatment Department GBU RO OKBNo.2, Rostov-on-Don, Russia

⁴Surgery Department No 2 FPK and PPS FGBOU VO KubGMU Ministry of Health of Russia Krasnodar, Russia

Applicability: Liver echinococcosis percutaneous treatment methods under X-ray control are characterized by low traumatism, high efficiency rate (95%), low postoperative lethality rate (0.19%), low serious complications development

rate (2.7%) and low relapse rate (0.9%). However, despite the low traumaticity and high efficiency they are used only for single-compartment echinococcal cysts of I and II type (according to Gharbi ultrasonic classification).

Investigational target: To study the clinical effectiveness of percutaneous interventions for liver multi-compartment echinococcal cysts treatment in humans.

Material and methods: Results of percutaneous treatment under ultrasound and X-ray control of 28 patients with liver multi-compartment echinococcal cysts were analyzed. 16 females (57.1%), and 12 males (43.9%) were included in target group. Multi-compartment cysts were diagnosed in 13 (46.4%) subjects. Age range was 17 - 72 years. Complicated cysts were revealed in 4 (14.2%) subjects, 1 subject had cyst empyema in multi-compartment echinococcal cysts, 3 subjects had bile ducts compression followed by obstructive jaundice progression. The maximum number of cysts in one patient with multi-compartment cysts was 3. The maximum size of the multi-compartment cyst was 216 mm. Echinococcal cysts larger than 10 cm were revealed in 20 (71.4%) subjects. Total number of cysts in all 28 subjects was 43. Percutaneous drainage was performed under ultrasound and X-ray control by the special device for draining cavities (UDPO). Radiocontrast polyethylene drainage of 12F diameter, fixed by suture, was used for drainage. The percutaneous puncture was performed with a 18G needle under ultrasound and X-ray control. 1% sodium hypochlorite water solution was used as an agent with anti-scolex activity (RF patent No.2355436 and RF patent No.2478345). In 28 subjects were performed the following: 41 percutaneous intervention, 36 drainage procedures, 5 punctures.

Results. Percutaneous treatment was successful in 26 (92.8%) subjects. No lethal cases were registered. Intraoperative complications (urticaria allergic reaction) were revealed in 2 (7.1%) subjects. Postoperative complications were registered in 14 (50%) subjects: 11 (39.2%) cases of biliary fistula, 3 (10.7%) cases of residual cavity bacterial contamination during outpatient stage of treatment. In two cases of bile flow rate more than 600 ml per day endoscopic papillosphincterotomy was performed to close the biliary fistula. In 2 (7.1%) cases the residual cavity persists throughout the year, so repeated percutaneous drainage and sclerotherapy was performed. The average hospitalization duration was 18.2 inpatient days. The average duration of echinococcal cyst (free from bile fistula) drainage was 38 days. The average duration of complicated by bile fistula echinococcal cyst drainage was 98.3 days.

Summary: Our investigation had shown that liver multi-compartment echinococcal cysts percutaneous treatment may be used as an alternative method of surgical treatment.

091

TREATMENT EXPERIENCE OF PREGNANT WOMEN WITH COMPLICATIONS OF CHOLELITHIASIS IN URGENT SURGERY

V. Durlshter, E. Babenko, K. Antinyan

State budgetary educational health care institution "Region clinic hospital Nr 2" of the Ministry of health care of Krasnodar region, Krasnikh partisan st. 6/2, Krasnodar, Russia

Currency. Prevalence of cholelithiasis during gestation is 0.05 – 8.00%. Acute cholecystitis occur in 1 to 1600-10000. Gallstones are presented in 3 – 10% of pregnant. Gestation is a provocative factor for acute cholecystitis development because of dyskinesia and impediment of bile outflow as a result of hyperestrogenism.

Aim. Improvement of treatment results of pregnant with complications of cholelithiasis by means of low-invasive technologies.

Materials and methods. 77 pregnant women admitted to surgical departments of SBIHC RCH Nr 2, Krasnodar in 2008 - 2017 years with complications of cholelithiasis were treated and the results were analyzed. Mean age of the patients was 25.1 – 4.5, from 18 till 42 years old. Period of gestation was from 6 till 38 weeks.

Results. 46 patients with acute cholecystitis were hospitalized. 22 (47.8%) patients underwent conservative therapy. As a result, an attack of the disease was checked. It was recommended them treating in postnatal period. 24 (52.2%) patients underwent some types of low-invasive surgery. In the I gestation term laparoscopy cholecystectomy (LCE) was carried out in 4 (57.1%) of patients, 7 (28.6%) had conservative therapy, and 1 underwent transcutaneous thanshepatic cholecystostomy (TTCS). In the II gestation term LCE was carried out in 13 (56.5%) from 23 patients, 6 (26.1%) had conservative therapy, 3 (13.0%) – TTCS. 1 (4.4%) underwent diagnostic video laparoscopy. The obvious infiltrate in the part of gastro-duodenal junction was revealed perioperationally. To minimize a surgical aggression and conversion to laparotomy the TTCS was performed. In the III gestation term the TTCS was performed in 2 (12.5%) patients and in 14 (87.5%) cases the conservative therapy was successfully used. There were no surgical and obstetric complications after LCE and cholecystostomy (CS) under sonography control. All patients were discharged with progressive pregnancy. A separate group consisted of 31 patients with cholelithiasis complicated with obstructive jaundice (OJ). In all cases endoscopy retrograde cholangiopancreatography (RCPG) with endoscopy papillosphincterotomy (PST) and lythoextraction (LE) were performed. The intervention was carried out under anesthesia. 2 patients in the II gestation term underwent laparoscopy cholecystectomy after RCPG+PST+LE without discharging from the hospital. The surgical complication was an acute RCPG-induced pancreatitis that was checked by conservative therapy.

Conclusions. Sonography of pancreatic-duodenal part allowed determining the grade of gallbladder destruction and inflammatory alterations. Laparoscopy cholecystectomy is recommended mainly in I and II gestation terms when a para-vesical infiltrate in hepatic-duodenal junction is absent. TTCS under sonography control is indicated to pregnant women when obvious destructive lesions are revealed. We recommend them routine low-invasive surgery in postnatal period. Endoscopy retrograde cholangiopancreatography (RCPG) with endoscopy papillosphincterotomy (PST) and lithoextraction (LE) under obligatory anesthesia are indicated in cholelithiasis complicated by obstructive jaundice. When acute cholecystitis is diagnosed laparoscopic cholecystectomy or TTCS is indicated.

092

USAGE OF LOW-INVASIVE SURGICAL INTERVENTIONS IN TREATMENT OF SHARP DESTRUCTIVE PANCREATITIS

V. Durlshter^{1,2}, A. Andreev², Y. Kuznetsov^{1,2}, Yu. Pushkar¹, V. Pykhteev¹, S. Shuplak²

¹*Surgery Department No. 3 Faculty of Professional Development and Professional Retraining Kuban State Medical University, Russia, 350063, Krasnodar, Sedina St., 4*
²*State-funded Health Institution "Regional Clinical Hospital No 2" Krasnodar Medical and Diagnostic Association, Russia*

Sharp pancreatitis is one of the most difficult diseases in surgical gastroenterology. In this article we would like to share the practical experience of low-invasive intervention usage as a main surgical method for treatment of patients with sharp pancreatitis of heavy degree.

Research Objective: the purpose of our research was treatment result improvement of patients with heavy degree sharp pancreatitis on the basis of widespread introduction of low-invasive surgical interventions.

Material and methods. The basis of the research is the analysis of treatment results of 482 patients with sharp pancreatitis of heavy severity hospitalized to State-funded Health Institution "Regional Clinical Hospital № of Krasnodar Krai from 2007 to 2017. Sick male 66% (318) prevailed among patients. The age of patients balanced from 27 to 72. 58% (280) of patients had a sterile pankreonekroz (SP), 42% (202) had the infected pankreonekroz (IP), 30% (147) of patients are the share for subtotal, total, and 70% (335) – for a focal pankreonekroz. In our clinic we use low-invasive technologies as the main and final method of purulent complications of destructive pancreatitis treatment: EPT (endoscopic papillotomiya), percutaneous punctures of liquid congestions, drainage of limited purulent cavities and retroperitoneal phlegmons, transvesical videoscopic sequestrectomy.

Results and discussion. The average grade point of patient's severity condition in the studied group on a scale of APACHE II has made 9 points, by the Ranson system – 5 points. About 21% (112) of patients with sharp pancreatitis arrived in heavy and critical condition. Values on the APACHE II system for these patients were from 10 to 16 points, and lethality reached 25%. All patients with sharp destructive pancreatitis arrived to intensive care unit. In case of diagnosing the patients with pankreonekrozy liquid parapancreatic, paracolic formations and for determination infection purpose and severity of destructive processes the puncture is carried out. It is carried out 1112 percutaneous interventions under control of radioterapia and video endoscopic methods: Seldinger drainage – 778 (70%), one-stage drainage – 333 (30%). The percutaneous decompression of bilious ways is carried out for 42 patients. The percutaneous transfusion interventions were carried out for 74 patients, 30 (40%) from 74 patients. For 14 patients have been carried out more than two percutaneous transfusion interventions. The treatment of purulent - necrotic retroperitoneal phlegmons by the combined low-invasive methods was effective for 89% (178) patients. The sequelae connected to the low-invasive methods of treatment usage have developed in 2,6% (21) of cases, and only eight patients needed a laparotomy.

Conclusion. Treatment of patients with sharp pancreatitis of heavy degree with usage of low-invasive surgical interventions allows reducing lethality to 15%.

093

ANTIMICROBIAL PHOTODYNAMIC THERAPY IN THE TREATMENT OF BACTERIAL LIVER ABSCESSSES

I. Dzidzava, B. Kotiv, A. Apollonov, E. Sivolodsky, A. Smorodsky, A. Slobodyanik, O. Fedun, S. Soldatov
Federal State Budgetary Educational Institution of Higher Professional Education
S. M. Kirov Military Medical Academy, Saint Petersburg

Relevance. Diagnosing and treating liver abscesses (LA) is one of the most urgent problems of surgical hepatology. At present, the number of multidrug-resistant strains of microorganisms and insufficient effectiveness of antibiotic therapy persist, which leads to search for alternative treatments.

Purpose. Improvement of the minimally invasive treatment methods for LA.

Materials and methods. The study consists of experimental and clinical parts. Four groups were studied in the experiment. The first group includes microorganism cultures not exposed to photosensitizers (PS) and laser radiation (LR). The second consists of microorganism cultures exposed to PS. The third group of bacteria underwent isolated LR. The fourth group includes microorganisms exposed to LR after Radachlorin

treatment. The strains exposed to treatment were the reference strains of *Klebsiella pneumoniae*, *Pseudomonas aeruginosa*, *Enterococcus faecalis*, *Escherichia coli*, *Staphylococcus aureus*, *Candida albicans* in a working concentration of 1×10^6 CFU. The results of treatment of 43 patients with liver abscesses were analyzed. 16 of them were in the main group LA patients treated with antimicrobial photodynamic therapy (APDT) after undergoing minimally invasive drainage. The control group included 27 LA patients who underwent percutaneous drainage without LR. 0.35% Radachlorin (Russia) at a concentration of 0.1 mg/kg was used as a photosensitizer. Exposure to the drug in the abscess cavity lasted 30 minutes. Abscess was exposed to trans-drainage radiation for 20 minutes using an endoscopic fiber optic catheter, with LR wavelength of 662 Nm and at 1.00 W. The laser radiation device used is Lakhta-MILON (Russia).

Results. Experimental data showed no antimicrobial effect of PS on the growth of microorganisms in the second group. No bactericidal effect of LR was found in the third group. The fourth group showed that under the specified regime of LR and PS treatment *Pseudomonas aeruginosa*, *Enterococcus faecalis*, *Escherichia coli*, *Candida albicans* and *Klebsiella pneumoniae* microorganisms were completely destroyed. The clinical part of the study showed that antibiotic therapy in the control group lasted 12.6 ± 0.7 days; in the main group, it lasted 3.5 days less (treatment period 9.1 ± 0.4 days) ($p < 0.001$). The LA drainage period in the control group was 15.6 ± 1.6 days, while in the main group drainage was removed 7.7 days earlier (draining period 7.9 ± 0.5 days) ($p < 0.001$). The length of stay in the control group was 24.7 ± 3.0 days. In the main group, it decreased by more than 2 times (11.6 ± 0.5 days) ($p < 0.001$).

Conclusion. PDT has a high antimicrobial effect against the most relevant LA pathogens and is justified for patients undergoing complex LA treatment with the use of minimally invasive drainage access.

094

ANTEGRADED ENDOBILIARY STENTITIES IN TREATMENT OF HIGH STRICTURES OF BILE DUCTS WITH TUMOR GENESIS

I. Dzidzava, B. Kotiv, O. Fedun, A. Rzaeva
Military Medical Academy, St. Petersburg, Russia

Relevance. The proximal level of obstruction of the biliary tract is the most unfavorable and technically difficult in resolving biliary hypertension. Asymptomatic flow often leads to a wide spread of the tumor process, down to the level of segmental and subsegmental.

Purpose of the study: to estimate the efficiency of the antegrade bilateral endobiliar stenting using self-expanding endoprotheses for the tumor-bearing liver portal treatment. Materials and methods of research. The study included 9

patients with extensive tumor lesion gates of the liver: 5 - Klatskin type IV tumor (according to Bismuth-Corlett), 2 - metastatic lesion of the liver gates, 2 gallbladder tumors. All patients with the first stage were performed with a semiotic or segmental external drainage. The number of drains required for adequate decompression of the bile ducts was from 2 to 4. The following stenting options were performed: two uncovered stents, type "7" - 4; two uncoated stents X-shaped intrahepatically with the installation of a third partially covered in hepaticoholedoch (modified by the type of the number "7") - 2 and Y-stenting with two uncovered stents - 3. In all cases self-expanding nitinol stents "SMART" (Cordis, USA) and "HANAROSTENT" (MI Tech, Korea).

Research results. Adequate drainage of the bile ducts is achieved in all cases. In one case, with stenting by the type "7", on the second day after stenting, there was a migration of proximal edge of the stent in the distal direction due to a reduction in its length during expansion, which required the installation of an additional uncovered stent - "stent in the stent". In the following we managed to exclude the evolution of this complication by performing predilatation of the stricture area. The installation of the distal part of the stents in the hepaticoholedochus suprapapillary allowed to avoid the phenomena of reflux-cholangitis in all patients. The terms of observation of patients were from 3 to 18 months. No evidence of recurrence of jaundice was observed in either case. Four patients died: 3 from the progression of the disease, 1 patient from the cardiovascular pathology. 5 patients are alive and receive palliative XT.

Conclusion. Complex antegrade endobiliary stenting of bile ducts by self-expanding metal stents is a technically difficult but highly effective method of palliative care for patients with malignant neoplasms of the gates of the liver, accompanied by fewer complications and significantly improving the quality of life of patients.

095

VOLUMETRIC AND FUNCTIONAL CHARACTERISTICS AS A RISK FACTORS FOR HEPATOCELLULAR INSUFFICIENCY WITH EXTENSIVE LIVER RESECTIONS

I. Dzidzava, A. Slobodyanik, B. Kotiv, A. Kudryavtseva, S. Alentev, S. Soldatov, A. Smorodsky
Russia

Relevance. Preoperative assessment of the remaining volume of the liver and its functional state allows to predict the course of the postoperative period after extensive liver resections.

Objective: to study the diagnostic value of CT-volumetry and clearance of indocyanine green, as predictors of post-resection liver failure.

Material and methods. The results of 179 liver resections are analyzed: 128 different hemihepatectomies and 51 sectionectomy. In 24 cases, preoperative embolization of

the portal vein was used. To quantify the liver function, a clearance test with indocyanine green (ICG) was performed. The plasma disappearance rate (PDR) and the residual concentration for 15 min (R15) was determined. To calculate the future liver remnant (FLR) used the technique of CT-volumetry scan. The severity of post-resection liver failure was assessed in accordance with the recommendations of the International Research Group for Liver Surgery (IRGLS) and with the criteria "50-50".

Results. The frequency of post-resectional hepatic insufficiency (PHI) with extensive resections was 42,5%: grade A – 38,7%; degree B – 41,9%, grade C – 19,4%. The planned post-resection volume as a predictor of postoperative hepatic insufficiency was characterized by moderate prognostic force (c-statistic=0,710, $p = 0,04$) with sensitivity and specificity of 84,6% and 61%, respectively. The indocyanin green elimination indices were significantly worse in patients with chronic liver disease or after repeated courses of polychemotherapy (PDR 15,6%/min vs 18,6%/min, $p=0,004$, OR15 – 19,6% vs 6,1%, $p=0,003$). The clearance test with indocyanine green was characterized by high sensitivity (92.3%) and specificity (71.4%) in determining the functional potential of the liver and excellent prognostic strength (c-statistic=0.82, $p=0.0001$) in the predetermination of FLR. Risk factors for the development of postoperative hepatic failure in performing extensive resections are $FLR < 372 \text{ cm}^3/\text{m}^2$ and $PDR < 10\%/\text{min}$. Indications for preoperative embolization of the portal vein are $FLR < 372 \text{ cm}^3/\text{m}^2$ with $PDR > 15\%/\text{min}$ or $10\%/\text{min} < PDR < 15\%/\text{min}$ at $FLR > 550 \text{ cm}^3/\text{m}^2$. The rate of plasma elimination ICG less than 10%/min is recognized as a contraindication to performing extensive liver resections. Application of these criteria allowed to reduce the incidence of post-resection hepatic insufficiency (25.6%) and to exclude the development of its severe forms.

Conclusion. The planned post-resection volume of the liver according to CT-volumetry scans and parameters of the clearance test with indocyanine green are highly sensitive methods for predicting postoperative hepatocellular insufficiency. Application of the developed medical diagnostic algorithm with specified indications for preoperative embolization of the portal vein allows to reduce the frequency of post-resection hepatic insufficiency.

096

SHORT-TERM RESULTS OF MINIMALLY INVASIVE LIVER RESECTION FOR BENIGN TUMORS

M. Efanov, R. Alikhanov, A. Vankovich, I. Kazakov, P. Kim, A. Koroleva, N. Elizarova, E. Zamanov, K. Grendal
The Loginov Moscow Clinical Scientific Center, Moscow, Russia

Relevance. Benign tumors of the liver are increasingly diagnosed and continue represent a management challenge.

Laparoscopic liver resection has considerably altered the management paradigm favoring invasive therapy.

The aim of the study was to evaluate the short-term results of minimally invasive liver resections for benign tumors.

Materials and methods. Data were accumulated since 2014. Benign liver tumors were the indication for liver resection in 66 patients: in 55 (83%) women and 11 (17%) men, aged from 23 to 76 years. Minimally invasive procedures were performed in 60 (91%), including 48 lap and 12 robotic resections. Six patients underwent operation through open approach. The benign lesions were presented by hemangioma (35), adenoma (13), FNH (11) and cystadenoma (7). Indications for liver resection were giant (>10 cm) growing lesions with clinical signs (abdominal pain on physical activity) and suspicion for malignancy (especially in cystadenomas).

Results. Major hepatectomy was performed in 9 (13,6%) patients for hemangiomas (6), adenoma (1), cystadenoma (2). Partial resection of postero-superior segments and caudate lobe was performed in 21 (31,8%) patients. Robotic system was used in 7 of them. Major morbidity after minimally invasive liver resection was observed in one (1,9%) patient (IIIA, Clavien-Dindo): hematoma, requiring additional drainage after lap S6,7 resection. There was no mortality. After 6 open liver resections bile leakage took place in 3 patients and required additional drainage (IIIA). Mean operation time of minimally invasive and open liver resection was comparable: 305 (80-605) min and 321 (260-395) min, respectively. The mean blood loss for minimally invasive and open procedures was 385 ml and 1425 ml, respectively. The mean postoperative hospital stay after minimally invasive and open resection was $7 \pm 2,8$ and $12 \pm 5,6$ days, respectively.

Conclusion. Minimally invasive liver resection is the safe option for treatment of giant symptomatic benign tumors and may be considered as the first choice approach if surgery is indicated. Difficult-to-reach liver segments lesions is not a contraindication for experienced centers with high volume of minimally invasive liver surgery.

097

COMMUNICATING PATHWAYS BETWEEN MAJOR HEPATIC ARTERIES. MYTH OR REALITY?

V. Egorov^{1,2}, R. Petrov, N. Chernaya^{1,2}

¹FSBEI HE Kazan State Medical University, Kazan, Russia

²Tatarstan Regional Clinical Cancer Center, Kazan, Russia

Background. The resources of anastomoses between major hepatic arteries are underestimated and do not used by HPB surgeons. It is supposed that this is only theoretical knowledge.

Aim. To show the importance of this knowledge to practical purposes.

Method. Analysis of 10 cases of liver survival due to commu-

nicating interlobar artery after major pancreatic and gastric resections and hepatic artery embolization, accompanied by dearterialization of one of the liver lobes. Monitoring of liver arterial supply intraoperatively was carried out by US Doppler of liver parenchyma, and after surgery - by CT angiography(CTA) and angiography.

Results. Distal pancreatectomy with celiac (CA) and gastroduodenal artery resection (Michels IV), total duodenopancreatectomy with CA resection (Michels III), pancreaticoduodenectomy with common hepatic artery resection (Michels IX), total gastrectomy with resection of right hepatic artery originated from the CA (Michels I), total duodenopancreatectomy with resection of the left hepatic and embolization of the right hepatic artery and embolysatioembolization of the right hepatic arteries for multiple gunshot injuries (Michels I) and for huge hepatocellular carcinoma (Michels I) were performed without vascular reconstructions and ischemic sequelae within short- and long- term postoperative period. Postsurgical CTAs have shown that arterial supply to the liver lobes lacking their main arteries is provided through the anastomoses between major hepatic arteries.

Conclusion. The knowledge about the capability of anastomoses between major hepatic arteries allows to resect or embolise the main feeding lobar hepatic artery without reconstruction. In so doing intraoperative monitoring of blood supply must be used, which depending on circumstances can be ultrasound Doppler or angiography.

098

RESULTS OF PANCREAS-PRESERVING DUODENECTOMY FOR DUODENAL DYSTROPHY. WHY, WHEN AND HOW? EXPERIENCE OF 80 CASES OF DUODENAL DYSTROPHY TREATMENT

V. Egorov, R. Petrov

Bakhrushin Brothers Moscow City Hospital, Russia

Background: Terms “paraduodenal pancreatitis“(PP), duodenal dystrophy,DD, paraduodenal cyst and groove pancreatitis are in use by reasoning that these conditions mimic pancreatic head tumors and share certain histological evidences. Treatment modalities of the disease and reasons for amalgamation of these terms are unclear.

Objective: To assess the results of pancreas–prese-rving surgery for DD treatment.

Method: 1.Prospective analysis of 80 cases of DD (2004-2017), comparing 80 pretreatment and 59 histopathological findings; 2.Assessment of clinical presentation and the results of DD treatment.

Results: Preoperative diagnosis was correct in all the cases except one, when cystic tumor of the pancreatic head was suspected (1,8%). Patients were presented with abdominal pain (100%), weight loss (76%), vomiting (30%) and jaundice

(18%). CT, MRI and endoUS were the most useful diagnostic modalities. Twelve patients were treated conservatively, 35 underwent pancreaticoduodenectomies(PD), pancreatico- and cystoenterostomies (8), Nakao procedures (4), duodenum-preserving pancreatic head (DPPH) resections(5), and 15 pancreas-preserving duodenal resections(PPDR). No mortality. Full pain control was achieved after PPRDs in 93%, PDs in 83%, and after PPPH resections and draining procedures in 18% of cases. New diabetes mellitus(3) and exocrine insufficiency(3) developed after PD. Weight gain after 1 year was much more significant after PD and PPDR.

Conclusions: The diagnosis of DD can be confidently determined preoperatively; Early diagnosis of DD saves pancreas; Late diagnosis converts DD in PP and leaves patient only PD; The efficacy of PPDR proves that DD is an entity of duodenal, but not paraduodenal origin.

099

RESULTS OF VEIN RESECTIONS IN PANCREATIC SURGERY FOR TUMORS. EXPERIENCE OF 112 CASES

V. Egorov, R. Petrov, D. Utkin, M. Grigorievsky

Bakhrushin Brothers Moscow City Hospital, Russia

Background. Vein resection (VR) associated with pancreatectomy for has become a routine procedure for oncological surgery. However, results of these procedures are still the subject for discussion.

Aim. To assess short-and long-term results of pancreatectomies with VR for oncological reasons (2009- 2018).

Method. Retrospective comparative analysis of 523 pancreatectomies, including 112 procedures with VR and 11 WATSA. Edge VR and VRs without reconstructions were excluded.

Results. VR were performed in 21% of pancreatectomies: 86 (27%) pancreatoduodenectomies (PDs), 3(3,5%) distal resections (DP), 12(20%) total DPs (TDPs) and 10(38%) mAppleby. R0 resection level was 64% with VR and 73% without. The true vein wall involvement was revealed in 76 (68%) cases. Chemotherapy for pancreatic ductal adenocarcinoma (PDAC) was received by 77% of operated on patients, neoajuvant chemotherapy was delivered to 11% and a quarter of patients with VR received neoajuvant. Mortality after PDs without VR vs PDs with VR was 5,73% vs 4,7% , fistulas B/C – 6,4% vs 3,5% complication rates class III-IV by Dindo-Clavien were 7% vs 4,7% (p>0.2). Median survival for PDAC without VR and with VR was 24 vs 18 months (p<0,05).

Conclusion: VR during pancreatectomy is a safe procedure in specialized department. Survival after primary resections for PDAC is significantly lower when VR is performed. We have no enough data for the assessment of long-term results of pancreatectomies with VR after neoajuvant therapy.

100**SPLEEN-PRESERVING DISTAL PANCREATECTOMY WITH SPLENIC VESSELS RESECTION. WHICH ARTERIES CAN WE RELY ON?**

V. Egorov, R. Petrov, K. Dmitrieva, N. Starostina
Bakhrushin Brothers Moscow City Hospital, Russia

Background. The knowledge of spleen collaterals is important as for distal spleen-preserving pancreatectomy with splenic vessels resection (DSPPSVR), so as for possible upper GI surgery for these patients.

Objective. To clarify the sources of spleen blood supply after DSPPSVR.

Methods. Perfusion of the cadaveric left gastric artery with a colouring agent after the occlusion of all arteries except for the short gastrics (n= 10); Intraoperative Doppler ultrasound (IDU) for the evaluation of the splenic blood flow during distal pancreatectomy (n=18) after the splenic artery clamping, following the clamping of the splenic and the left gastro-epiploic arteries (LGEA) and after the clamping of the splenic and the short gastric arteries (SGA); CT-angiography (CTA) of gastric and splenic vessels before and after DSPPSVR (n=39).

Results. The perfusion of cadaveric arteries after the occlusion of all the arteries except for the SGA never only once revealed a dyestuff in the spleen (through the accessory left gastric artery); IDU never detected any blood flow in the splenic hilum after the clamping of the splenic and the LGEAs; CTA after DSPPSVR never delineated SGA supplying the spleen. Postoperative CT revealed three types of splenic blood supply after DSPPSVR: with gastro-epiploic arcade (GEA) as a main collateral artery (n29,74,3%), with the SGAs as a main collateral (n3,7,7%) and intermediate type (n7,18%)

Conclusion. Experimental, intra- and postoperative CT have revealed GEA as a main source of arterial blood supply of the spleen after DSPPSVR. The R GEA and LGEA are the "main players" after DSPPSVR and must be carefully preserved. SGAs serves as a main collateral in very rare cases.

101**COLORECTAL ANASTOMOTIC LEAKAGE AND FORMATION OF A CHRONIC PRESACRAL SINUS AS THE OUTCOME OF TOTAL MESORECTUMECTOMY**

V. Egorov^{1,2}, F. Ahmetzyanov^{1,2}

¹*FSBEI HE Kazan State Medical University, Kazan, Russia*

²*Tatarstan Regional Clinical Cancer Center, Kazan, Russia*

Total mesorectumectomy is a risk factor for the develop-

ment of the colorectal anastomotic leakage and the formation of pathological presacral sinuses. As a result of resection of the rectum with total mesorectumectomy, a volumetric cavity is formed in the pelvis, bounded by bone structures. This "dead space" predisposes to the accumulation of fluid and blood in it, which increases the risk of infection and the formation of presacral abscesses. Chronic presacral sinus is formed in 5% of patients after total mesorectumectomy.

Aim. Improve the results of surgical treatment of patients with rectal cancer after total mesorectumectomy.

Materials and methods. Data have been analyzed for 499 patients with rectal cancer who underwent surgical treatment between 2011 and 2017. A total mesorectumectomy was performed in 324 patients with the formation of low, ultra-low colorectal anastomoses and coloanal anastomoses. In order to prevent purulent-septic complications from the pelvic organs and the formation of the presacral sinus, the original technique of aspiration was used. The original method of conservative treatment of this pathology was used for the treatment of the colorectal anastomotic leakage. The effectiveness of the EndoVac, fibrin glue, surgical excisions in the formation of chronic presacral sinus has been studied. There has been carried on the factors of the development of the colorectal anastomotic leakage.

Results. Out of 499 patients, the colorectal anastomotic leakage was developed in 56 (11.2%) patients. After total mesorectumectomy, the colorectal anastomotic leakage was revealed in 46 (14.2%) patients. In 38 (82.6%) patients the colorectal anastomotic leakage was managed conservatively with the use of the original technique of aspiration drainage of the pelvic cavity. In seven patients (15.2%) required diversion colostomy and in one (2.2%) patient underwent disconnection of the anastomosis. The following factors that statistically significantly influence the development of the colorectal anastomotic leakage are established - the height of the tumor location, the height of the anastomosis location, the total mesorectumectomy, the body mass index. The average time of treatment of the chronic presacral sinus after the application of different treatment methods was 8 months.

Conclusion. Total mesorectumectomy is a statistically significant factor in the development of the colorectal anastomotic leakage and the formation of a chronic presacral sinus. The use of the original aspiration drainage technique with a sufficiently high efficiency makes it possible to prevent the development of abscesses and phlegmon of the small pelvis and prevent the formation of a chronic presacral sinus. Various tissue sealants and the EndoVac system are effective agents in the case of the development of the chronic presacral sinus.

102

LIVER AND STOMACH COLLATERAL BLOOD SUPPLY AFTER DISTAL PANCREATECTOMY WITH CELIAC ARTERY RESECTION. IO US AND ICG GASTROSCOPY ARE MORE USEFUL TOOLS THAN PREOP COMMON HEPATIC ARTERY OCCLUSION: EXPERIENCE OF 115 CHA CLAMPINGS AND 26 DP CARS

V. Egorov, R. Petrov, Ju. Zhurina, M. Grigorievsky
Bakhrushin Brothers Moscow City Hospital, Russia

Aim. To study stomach and liver collateral arterial supply after common hepatic (CHA) and celiac artery (CA) temporary occlusion.

Background. Distal pancreatectomy with celiac artery resection (DPCAR) is in use for borderline-resectable pancreatic cancer. It is believed that considerable reduction of the liver arterial supply after DPCAR may cause severe liver ischemia. Decision to reconstruct CHA or left gastric has to be justified. Patients and methods: Arterial anatomy, diameters of CHA, proper hepatic, gastroduodenal and pancreatoduodenal arcades(PDA) were registered before surgery in 115 consecutive patients with pancreatic body/tail cancer (n36), gastric cancer with pancreatic involvement (n30) and liver tumors (n45) by CT. For DPCAR(n26) patients ICG gastroscopy or CT were performed during or after surgery. Arterial blood flow in the liver and mean systolic velocity in hepatic arteries before and after clamping were measured intraoperatively by US.

Results: Classical arterial anatomy was identified in 67%. Pulse disappeared in 9(8%) cases after clamping of CHA, RGEA and aLHA/rLPA. Arterial blood flow in the liver parenchyma was preserved in all cases. DPCAR led to increase of GDA, PDA and RGEA blood flow in 1-12 times; PDA were detected only once before DPCAR. Gastric ischemia was revealed in four and liver ischemia in 0 cases.

Conclusion: 1. IOUS is a reliable modality for intraoperative assessment of liver arterial blood supply during DPCAR; 2. Gastric ischemia is much more frequent event than liver ischemia after CA occlusion. IO ICG gastroscopy can be the option for the reconstruction of left gastric artery. 3. CHA occlusion before DPCAR is unnecessary procedure.

103

INVASIVE METASTATIC AND NONMETASTATIC INTRADUCTAL TUBULO-PAPILLARY CARCINOMA. NATURAL HISTORY AND APPROPRIATE TACTICS BY THE EXAMPLE OF THREE CASES OF THE RAREST EXOCRINE PANCREATIC TUMOR

V. Egorov, R. Petrov, N. Ratnikova, D. Kalinin
Bakhrushin Brothers Moscow City Hospital, Moscow, Russia

Introduction. Intraductal tubulo-papillary neoplasm (ITPN) is the rarest pancreatic tumor. Invasive ITPC is even more rare and its biology is unknown.

Aim. To discuss biology of invasive metastatic and non-metastatic ITPC and appropriate tactics by the example of three cases.

Patients and results. 1. A 36-year old woman with jaundice and anemia after profuse GI bleeding was operated on 5 day for the pancreatic tumor invading the whole pancreas. Uneventful postoperative period. ITPC was diagnosed at pathology and genetic examination. Four years later there is no relapse, ECOG -0, well monitoring of diabetes mellitus, fully functional. Six months ago she has given to the healthy child and both do well by the moment. 2. In 2015, April in 29-year old lady the mass was found in the pancreas which was observed as a cyst. In 2016, March tumor was found in the pancreatic head and body and two focuses in the right liver. CNB – adenocarcinoma. DS-Ductal adenocarcinoma, T3NoM1, 6 courses of gemcitabine + 2 LACE. Multiple consultations of multiple byopsies in different institutions and countries: adenocarcinoma of unknown origin in the liver and pancreas. Four courses of FOLFIRINOX were followed by quick tumor progression. After intensive discussion 26 months after the disease beginning total pancreatectomy and right trisegmentectomy was performed for 32- year old lady. Complicated postoperative period followed by stabilization but sudden death a day before discharge because of acute liver failure. 3. A 72-year old woman with abdominal pain and 4-cm tumor in the pancreatic head was treated by Whipple procedure and completion pancreatectomy for sentinel bleeding and discharged uneventfully. Pathology has found ITPC in the pancreatic head and focus of the ITPN in the pancreatic body without nodal involvement.

Conclusion. Natural history, efficacy of surgery and conventional chemotherapy for Invasive, especially, metastatic ITPC is unknown and has to be investigated.

104

ORGAN-PRESERVING AND EXTENSIVE PANCREATIC SURGERY FOR VON HIPPEL-LINDAU DISEASE SIX CASES OF 45 PATIENTS UNDER SURVEILLANCE

V. Egorov, R. Petrov, D. Beltsevich
Bakhrushin Brothers Moscow City Hospital, Moscow, Russia

Background. Pancreas is involved in 15% of patient with von Hippel-Lindau disease (VHL). Pancreatic surgery for VHL is recommended for pNENs>2 or>3 cm.

Aim. To assess results of pancreatic surgery for VHL NENs.

Methods. Retrospective analysis of 6 pancreatic resections from 42 VHL patients under surveillance (2013-18).

Results: First case: total duodenopancreatectomy for head and tail pNENs on the background of total pancreatic involvement by serous cystadenomas of different size was performed to the 54-year old woman, who 6 years ago was treated by right-sided nephrectomy performed for clear-cell cancer. 8 months later she had died due to dissemination of renal cancer. A 45-year old woman with multiple cerebellar and spine hemangioblastomas, pNENs in the head and body and tail, 5 years after right adrenalectomy for pheo, centre-preserving pancreatectomy and left adrenalectomy for pheo. A 47-year old man with multiple spine hemangioblastomas, large (5-6 cm) pNENs in the head and 10 years after bilateral adrenalectomy for pheo was successfully treated by pancreaticoduodenectomy. One case of distal pancreatectomy (DP) for NENs combined with bilateral adrenalectomy and left renal resection and another case of DP combined with left adrenalectomy, triple left kidney and double right kidney resection after cranial hemanangioblastoma removal. All the patients were discharged and at the moment they are functional, working and fully compensated. After right adrenalectomy, left nephrectomy and repeated brain surgery, total pancreatic head resection was performed to a 32-year old man for rapidly growing 21-mm NEN, followed by Grade C fistula, completion pancreatectomy, recurrent hemorrhage and death.

Conclusion: Timely and possibly parenchyma-sparing pancreatic resections are the operations of choice for pNENs on the background of VHL. Indications for surgery must be thoroughly weighted.

105

SHOT-TERM RESULTS ANALYSIS OF ROBOTIC PANCREATICODUODENECTOMY

N. Elizarova, M. Efanov, R. Alikhanov, V. Tsvirkun, I. Kazakov, A. Vankovich, P. Kim
Russia

Background: The recent studies have documented the feasibility and safety of minimally invasive pancreaticoduodenectomy (PD) in comparison to open PD. There was showed that robotic approach was associated with a lower rate of conversion to open surgery compared to laparoscopy. Minimally invasive PD is included among the options in the latest NCCN Guidelines. The use of robotic surgery for PD is limited due to the complexity of the operation, need for special training of surgeons, and the high capital cost. Since it is expected that the cost of the robotic platform will decrease in the future and that there will be more training programs for it, the use of robotic surgery for PD is expected to increase.

The aim of the study was to analyze the accumulated over the year experience of robot-assisted PD in patients with tumors of the pancreas head and distal cholangiocarcinoma.

Materials and methods. Program of robotic PD started in April 2017. Twelve patients underwent robot-assisted PD for malignant (n = 11) and benign (n = 1) tumors of the pancreatic head and common bile duct (n = 1). In all cases we performed a standard Whipple procedure (with antrectomy) and used a Blumgart's technique for pancreatojejunostomy.

Results. The mean age of the patients was $63 \pm 6,1$ years (from 54 to 75 years). There were 10 women and 3 men. In cases of malignant tumors the prevalence size of the primary tumor was "T3" (75%), in 25% of cases it was T2. In 53% of cases the patients had a laparotomy in the anamnesis. Mean operation time was 685 ± 84 min, it was decrease in 1.5 times as experience is accumulated. Mean blood loss was 200 ± 60 ml, blood transfusion was not required. There was one (8,3%) conversion for pancreatic outflow reconstruction throw the upper middle laparotomy. Four (33%) cases of major (>Grade II, Clavien-Dindo) morbidity were observed. In one case it was an infected fluid cluster in the operation area, in one case - a bile leakage. Overall, there were two (16,6%) clinically significant (Grade B) pancreatic fistulas. These occurred in patients with «soft» pancreas. In all cases, complications were corrected by the percutaneous drainage. There was no 30-day/in-hospital mortalities. The median post-operative stay was 14 ± 6 days and there were one (8,3%) 30-day readmissions. Mean lymph node harvest was 12 ± 5 and margin negative resection was observed of 92%.

Conclusion: Improvement of technology robotic-assisted PD and accumulation of experience allow to reduce the number of complications and post-operative hospital stay, as well as to improve their quality of life and early initiation of adjuvant chemotherapy in the case of malignant disease.

106

MINIMALLY INVASIVE APPROACHES FOR RADICAL PROCEDURES IN THE SURGICAL TREATMENT OF LIVER ALVEOLAR AND HYDATID ECHINOCOCCOSIS

N. Elizarova, R. Alikhanov, V. Tsvirkun, I. Kazakov, A. Vankovich, P. Kim, M. Efanov
The Loginov Moscow Clinical Scientific Center, Moscow, Russian Federation

Background: Despite the improvement of drug therapy and percutaneous methods, the only radical treatment of liver echinococcosis remains surgery. There is considerable disagreement about the surgical technique to be adopted. With the development of liver surgery, radical methods including liver resection have become safer.

The aim of the study was to evaluate the early outcomes of open and laparoscopic radical surgery for hydatid cysts.

Materials and methods: We reviewed our series of patients underwent radical treatment for liver echinococcosis over a period of 5 years from 2013 through 2018.

Echinococectomy with total or subtotal pericystectomy was performed for hydatid cysts and liver resection for alveolar echinococcosis.

Results: Totally 40 patients underwent radical surgery. In 9 patients (22.5% of cases) who presented with residual and complicated liver hydatid cysts, including 5 cases of alveolar echinococcosis in P3 profile we performed open surgery. In 65 % of cases (26 patients), we used a laparoscopic approach, and 5 patients (12.5% of cases) were operated by robotic assisted approach. Among minimally invasive operated patients, there were 26 patients with liver echinococcosis and 5 patients with alveolar echinococcosis. The mean age of the patients was 43 ± 15 years. The ratio of men and women was 3:2. Mean size of cysts was 80 ± 36 mm. Among the hydatid cysts, type CE3 cysts predominated (61.5%) in comparison with types CE1 (19.2%), CE2 (15.4%), CE4 (3.8%). The PNM stage of alveolar echinococcosis was P1 (3) and P2 (2). In 11 (42%) cases a total pericystectomy was performed. In six patients (23%) a cystobiliary fistula was found, which was closed by the search and the intersection of the Glisson's pedicle bearing the fistula. The mean operation time was 330 ± 152 . The average blood loss was 200 ml (range 10 to 1500), blood transfusions were needed in one case. In 61,3% of patients cysts were located in in the posterosuperior segments (1,7,8). Severe complications (G>2, Clavien-Dindo) were observed in 5 (13%) patients: III (3), IV(1), V(1). One patient died on 90 day due to severe postoperative pancreatitis. Mean hospital stay was 7 (3–23) days.

Conclusion: Minimally invasive approach (laparoscopic and robotic) is safe and feasible for radical treatment of hydatid and alveolar echinococcosis, including difficult cyst location and complicated cysts.

107

**CAN GASTRIC SPECIMEN MEASUREMENTS
DEFINES THE LAPAROSCOPIC SLEEVE GASTRECTOMY
OUTCOME?**

Muhammer Ergenc, Tevfik Kivılcım Uprak, Ömer Günal
*University of Marmara, School of Medicine,
Department of General Surgery, Turkey*

Introduction: The success of weight loss surgery is defined by the rate of excess weight loss(EWL). Parameters which affect the excess weight loss percent is the subject of research1. We therefore intent to investigate the relationship between variety of gastric measurements and excess weight loss percent.

Methods: We have retrospectively screened the data of sleeve gastrectomy patients (LSG) which were operated since 2014. All patients were followed up according to our clinics criteria by the time this abstract has been written. In our study we have taken in to account anatomic measurements of resected gastric specimen. The lengths of stapler

(resection site) line(LRL), greater curvature(LGC), width of fundus (WF) and antrum (WA), tissue thickness (double-wall thicknesses) of fundus (TF) and antrum (TA) were all measured before and after the gastric specimen insufflation with CO2 through the hole at the pyloric site of the stomach. The CO2 volume insufflated by 10 mmHg assumed as the gastric volume. We infused %0.09 NaCl into the resected stomach until the specimen overflowed when it is hung in the vertical position. The relationship between gastric measurements and EWL percents at postoperative third, sixth and twelfth months was investigated. The correlation between the 3rd, 6th, 12th months EWL% and gastric volume, LRL, LGC, WF, WA, TF, TA expansion rates were also analyzed with correlation analysis (Pearson's and Spearman's correlation tests) .

Results: A total of 327 obesity surgery patients were screened which were operated by one surgeon. 220 Patients have undergone sleeve gastrectomy. 64 Laparoscopic sleeve gastrectomy patients which have gastric specimen measurements were included the study. Male/Female ratio was 15/49. The mean age was 41.5 ± 1.4 years (range, 21–62 yr). Third, sixth and twelve month EWL percents were $39.4 \pm 1.5\%$, $59.2 \pm 2\%$, $74.6 \pm 3\%$ respectively. Body mass indexes (BMI) were $40,8 \pm 1$, $36,2 \pm$, $31 \pm 1 \text{kg/m}^2$ at the same time intervals. Male/Female mean gastric specimen volumes (GSV) were 970 ± 91.5 ml/ 748.9 ± 36.5 ml. ($p=0.0001$). The overall group mean GSV was 803.28 ± 37.2 ml. The mean LRL, LGC, WF and WA, TF and TA expansion rates were $17.2 \pm 1.3 \%$, $35 \pm 2.2 \%$, $110,3 \pm 6.9 \%$, $80.9 \pm 3.7 \%$, $493.4 \pm 21.2 \%$ and $330.6 \pm 15.9 \%$ respectively. We have found a correlation between the 12th month EWL % and LRL expansion rates (Spearman's correlation coefficient $r=0.504$, $p=0.017$).

Conclusion: Male specimen volumes are significantly greater than females'. LRL expansion rate seem to be an indicator of good 12 month EWL. Gastric specimen measurements can be a useful harbinger of future weight loss.

108

**SURGICAL TREATMENT OF HEPATOBLASTOMA:
10-YEARS EXPERIENCE**

**Filin A.V., Metelin A.V., Dimova O.V., Burmistrov D.S,
Galjan T.N., Kamalov Y. R., Babajan A. A. and Kim E.F.**
*Petrovskiy National Research Centre of Surgery, Moscow,
Russia*

Relevance. Increasing the incidence of hepatoblastoma (HB), the most frequent form of malignant liver tumors in children, requires searching the ways for radical treatment by expanding the criteria of tumor resectability and the patient's operability.

Aim. To analyze the results of treatment of HB in the Petrovskiy National Research Centre of Surgery.

Materials and methods. From April 2008 to April 2018 132

pediatric patients with a variety of focal liver lesions underwent surgery at Petrovsky National Research Centre of Surgery. More frequent liver lesions were presented by hepatoblastoma (HB) (n = 88; 66,7%), focal nodular hyperplasia (n = 10; 8 %), hepatocellular carcinoma (n = 6; 5%), mesenchymal hamartoma (n = 6; 5 %). More recent liver masses were undifferentiated (embryonal) sarcoma, malignant rhabdoid tumor, rhabdomyosarcoma, hepatocellular adenoma, infantile hemangioendothelioma, benign teratoma, hemangioma, inflammatory myofibroblastic tumor. Two patients had a parasitic liver disease: cystic and alveolar echinococcosis. The incidence of malignant neoplasm was 78,4 %. The median age of children with HB was 21 months (with range from 2 months to 17 years). In 90 % of cases the age did not exceed 4 years old. Lung spreads were identified in 21 % of cases. Neoadjuvant chemotherapy was performed in 96,6 % patients. Patients staged by PRETEXT system: I - 6% (n = 5), II - 41 % (n = 36), III - 28 % (n = 25), IV - 25 % (n = 22). Surgical options were present with lobectomy and trisectionectomy in 70 (79%), living-donor liver transplantations in 13 (15%), left lateral sectionectomy in 4 (5%) and mesohepatectomy in 1 (1%) cases. Trisectionectomy were the most frequent surgical option. Pringle maneuver were performed only in one patient.

Results. There were no deaths in group of benign and parasitic diseases. The median follow-up for HB patients was 34 months. The actuarial survival rate (total/event free) for patients with hepatoblastoma was, respectively: 1-year 90,47 ± 3,21/80,69 ± 4,35, 5-year 80,70 ± 6,20/77,62 ± 4,70, 10-year 80,70 ± 6,20/77,62 ± 4,70.

Conclusion. The correctly built strategy of the surgical treatment of HB provides high survival rates. Long-term results demonstrate broad opportunities both resection and liver transplantation in cases of selection of optimal surgery plan and chemotherapy protocols. All patients with PRETEXT III and IV stage should be consulted in transplant units for the optimal future surgical planning.

109

THE EFFECTIVENESS OF COMPREHENSIVE REHABILITATION PROGRAM IN LOW ANTERIOR RESECTION SYNDROME TREATMENT

O. Fomenko¹, Y. Shelygin¹, I. Kalashnikova¹, D. Aleshin¹, V. Kozlov², S. Belousova¹, D. Egorova¹

¹State Scientific Centre of Coloproctology, Moscow, Russia

²National Research University Higher School of Economics Institute of Demography

Relevance. Currently, low anterior resection of the rectum with different types of colonic reservoirs is performed in 75-90% of rectal cancer. However 30-50% of these patients have evacuation problems and anal incontinence in consequence, what is named the "low anterior resection

syndrome" (LARS). The reasons for LARS: bowel dysfunction, loss of rectoanal inhibitory reflex, intraoperative external sphincter damage, resection or removal of the internal sphincter with a receptor zone and hemorrhoidal "cushion". Aim. To estimate the effectiveness of short course of biofeedback retraining and tibial neuromodulation (TNM) in LARS treatment.

Materials and methods. The study included 29 patients with LARS. Women - 12(41.4%), mean age 61.2±7.8 years. Men - 17(58.6%), 61.5±9.5 years old. Before and after treatment all the patients were tested with Wexner incontinence scale. Pressure in the anal canal at rest and during volitional contraction was assessed by anorectal manometry. The rehabilitation program included biofeedback and TNM for 10 procedures.

Results. Before treatment rest tone and maximal squeezing pressure of anal sphincters in women were 26.2±6.2 and 91.2±30.0 mmHg, Wexner scale was 12.8±3.9 points. In men, the same parameters were 23.5±7.0, 103.9±46.6 mmHg, and 13.0±3.5 points. After treatment in women there was a positive trend, the increase in parameters was an average of 15.3% and 17.3%, that is, the average rest tone and squeezing pressure were 30.2±7.9 and 107.0±36.3 mmHg, respectively. In men, the increase was on average 14.9% and 18.1% (27.0± 8.5/122.7±49.9mmHg). Mann-Whitney test showed that the difference between rest tone is not significant at 5% level, but significant at 10% (p=0.07), while for men p=0.23 and for women p=0.12. The increasing of squeezing pressure after treatment was already significant (p=0.047) for all patients, but was not significant for individual sexes - male p=0.11, female p=0.24. There also was improving of Wexner score after treatment: 11.0±4.6 points in women and 10.5±4.7 in men. However, the difference was not statistically significant according to Mann-Whitney test: p=0.05 (including for both sexes separately - p=0.155 for men and p=0.42 for women).

Conclusion. Short course of biofeedback retraining and tibial neuromodulation failed to achieve the significant improving of anal sphincter function in patients with LARS, except voluntary contraction parameters.

110

EXTRACELLULAR NUCLEIC ACIDS IN THE BLOOD OF WOMEN WITH CERVICAL CANCER AFTER CHEMORADIOTHERAPY

Y. Fomenko, L. Muravlyova, V. Sirotka, A. Shushanova
Karaganda State Medical University, Karaganda, Kazakhstan

Introduction. Currently, the role of extracellular nucleic acids (exNA) in the mechanisms of development and progression of cancer of various localization is discussed, as well as potential diagnostic, prognostic and predictive

biomarkers of cancer.

The aim of the present study is to evaluate the concentration of exNA and acid-soluble nucleic acid precursors in the blood plasma of women with cervical cancer before and after chemoradiotherapy.

Materials and Methods. 18 women (average 48.0±1.9 years old) with cervical cancer (stage IIB, IIIA, IIIB according to FIGO 2009) were included in this research. These patients were divided into 2 groups. The first group (8 persons) received radiation therapy, the second (35 person) - radiation therapy in combination with cisplatin. Control group consisted of 19 same age volunteers, who were without signs of any inflammation. All patients underwent radiation therapy as follow: External beam radiotherapy (devices "Rokus AM" and "Clinac 600 C") to the cervix, parametrium and regional lymph nodes the single focal dose (SFD) 3 Gy, the total focal dose (TFD) 50 Gy. 2. Brachytherapy (apparatus "Agat VU") SFD 5 Gy, TFD 30-35 Gy. Dosimetric support was carried out individually for each patient at the planning station "Gamma-plan 1". Chemoradiotherapy was performed in combination with cisplatin (40 mg/m² every 7 days throughout the course of radiotherapy). Blood was collected from the cubital vein (3 ml/sample) and was drawn into vacutainer tubes. Investigations of blood plasma were done within 1-2 hours after its collection. The level of extracellular RNA, DNA and acid-soluble nucleic acid precursors in the blood plasma was determined by the method of LI Markusheva et al. (2000).

Results. A significant increase in acid-soluble fractions (3-5 times) and extracellular RNA (10-12 times) in the blood plasma of patients before treatment was revealed in comparison with those of control. After the end of the course of radiotherapy, the level of acid-soluble fractions and extracellular RNA was comparable with that before treatment. After the end of the course of radiotherapy with cisplatin, there was a tendency to decrease the content of acid-soluble fractions, but the level of extracellular RNA did not differ significantly from that before treatment. There were no significant changes in extracellular DNA in the blood plasma of patients of both groups under various treatment regimes.

Conclusion. The results showed that in patients with cervical cancer the level of acid-soluble fractions and extracellular RNA in blood plasma increases. The radiation regimen with cisplatin helps to reduce the content of acid-soluble fractions, which correlated with a decrease in the volume of tumors, which can be regarded as a prognostic marker.

Emad Hamdy Gad¹, Hazem Zakaria¹, Yasmin Kamel², Talat Zakaria³, Mohamed Abbasy³, Ali Nada³, Mohamed Al-sayed abd-elsamee⁴

¹Hepatobiliary Surgery, National Liver Institute, Menoufiya university, Shebein Elkoum, Egypt

²Anaesthesia, National Liver Institute, Menoufiya university, Shebein Elkoum, Egypt.

³Hepatology and endoscopy, National Liver Institute, Menoufiya university, Shebein Elkoum, Egypt

⁴Radiology, National Liver Institute, Menoufiya university, Shebein Elkoum, Egypt

Objectives: For complicated large difficult CBD stones that cannot be extracted by ERCP, patients can be managed safely by open or laparoscopic CBD exploration. The aim of this study was to assess these surgical procedures of CBDE after endoscopic failure.

Methods: We retrospectively reviewed and analyzed 85 patients underwent surgical management of large difficult CBD stones after ERCP failure, in the period from beginning of 2013 to beginning of 2018. The overall male/female ratio was 27/58. Results: Sixty seven (78.8%) and 18(21.2%) of our patients underwent single and multiple ERCP sessions respectively with significant correlation between number of ERCP sessions and post ERCP complications (P=0.009). Impacted large stone was the most frequent cause of ERCP failure (60%). LCBDE, OCBDE and the converted cases were 24.7% (n=21), 70.6% (n=60), and 4.7% (n= 4) respectively. Stone clearance rate post LCBDE and OCBDE reached 95.2% and 95% respectively (P< 0.05), Eleven (12.9%) of our patients had post operative complications (14.3% post LCBDE and 11.7% post OCBDE, P<0.05) without mortality. By comparing LCBDE and OCBDE groups; there was significant association between the former and younger age, shorter referral time, more frequent choledochoscopy, and longer operative time with independent correlation regarding age and operative time. On comparing, T-tube and 1ry CBD closure in LCBDE group, there was significant longer operative time, and hospital stay in the former. However, on comparing them in OCBDE group, there was significant correlation between 1ry CBD closure and smaller diameter of CBD, single stone, choledochoscopy, shorter operative times and hospital stays. Furthermore, in OCBDE group, choledococopy had independent direction to 1ry CBD repair and significant association with shorter operative time, hospital stay, and higher stone clearance rate.

Conclusion: Large difficult CBD stones can be managed either by open surgery or laparoscopically with acceptable comparable outcomes with no need for multiple ERCP sessions due to their related morbidities; furthermore, Open choledococopy has a good impact on stone clearance rate with direction towards doing primary repair that is better than T-tube regarding operative time and hospital stay.

111

SURGICAL (OPEN AND LAPAROSCOPIC) MANAGEMENT OF LARGE DIFFICULT CBD STONES AFTER DIFFERENT SESSIONS OF ENDOSCOPIC FAILURE

112

OUTCOME OF SURGICAL MANAGEMENT OF LAPAROSCOPIC CHOLECYSTECTOMY (LC)-RELATED MAJOR BILE DUCT INJURIES

Emad Hamdy Gad¹, Eslam Ayoup¹, Yasmin Kamel², Talat Zakaria³, Mohamed Abbasy³, Ali Nada³, Mohamed Alsayed abdelsamee⁴

¹Hepatobiliary Surgery, National Liver Institute, Menoufiya University, Shebein Elkoum, Egypt

²Anaesthesia, National Liver Institute, Menoufiya University, Shebein Elkoum, Egypt

³Hepatology and endoscopy, National Liver Institute, Menoufiya University, Shebein Elkoum, Egypt

⁴Radiology, National Liver Institute, Menoufiya University, Shebein Elkoum, Egypt

Objectives: Laparoscopic cholecystectomy (LC) - associated bile duct injury (BDI) is a clinical problem with poor outcome. The study aimed to analyze the outcome of surgical management of these injuries.

Patients and methods: We retrospectively analyzed 69 patients underwent surgical management of LC related major BDIs (MBDIs), in the period from the beginning of 2013 to beginning of 2018.

Results: Regarding injury type; the Leaking, Obstructing, leaking + obstructing, leaking + vascular, and obstructing + vascular injuries were 43.5%, 27.5%, 18.8%, 2.9%, and 7.2% respectively. However, the Strasberg classification of injury was as follow: E1=25, E2=32, E3=8, and E4=4. The definitive procedures were as follow: End to end biliary anastomosis with stent, hepaticojejunostomy (HJ) with or without stenting, and RT hepatectomy plus biliary reconstruction with stenting in 4.3%, 87%, and 8.7% of patients respectively. According to time of definitive procedure from injury; the immediate (before 72 h), intermediate (between 72 h and 1.5 months), and late (after 1.5 months) management were 13 %, 14.5 %, and 72.5 % respectively. The hospital and 1month (early) morbidity after definitive treatment was 21.7 %, while, late biliary morbidity was 17.4 % and the overall mortality was 2.9%, on the other hand, late biliary morbidity free survival was 79.7%. On univariate analysis, the following factors were significant predictors of early morbidity; Sepsis at referral, higher Strasberg grade, associated vascular injury, RT hepatectomy with biliary reconstruction as a definitive procedure, intra-operative bleeding with blood transfusion, liver cirrhosis and longer operative times and hospital stays. However, the following factors were significantly associated with late biliary morbidity: Sepsis at referral, end to end anastomosis with stenting, Reconstruction without stenting, liver cirrhosis, operative bleeding and early morbidity.

Conclusion: Sepsis at referral, liver cirrhosis and operative bleeding were significantly associated with both early and late morbidities after definitive management of LC related MBDIs, so it is crucial to avoid these catastrophes when doing those major procedures.

113

RESULTS OF PERORAL ENDOSCOPIC MYOTOMY IN PATIENTS WITH ACHALASIA CARDIA. FIRST EXPERIENCE

S. Gabriel, A. Guchetl, V. Durlshter, V. Dynko, R. Tlekhuray, A. Mamishev, M. Bespechniy
Regional Clinical Hospital No. 2 Krasnodar, Russia

Relevance: In connection with the emergence of high-tech equipment and tools greatly enhanced the possibility of flexible endoscopy in recent years. The idea of creating a hydraulic cushion in the submucosal layer and access to the submucosal layer led to a fundamentally new level of endoscopic surgery in the treatment of achalasia cardia. High-tech surgical intervention - endoscopic peroral myotomy (POEM) appeared due to this.

Object: The aim was to analyze the effectiveness of the first POEM operations in the conditions of the state budgetary health care institution «Regional Clinical Hospital No. 2» (SBHI «RCH No. 2»).

Materials and methods: POEM is performed in SBHI «RCH No. 2» from 2017. As the equipment used: endoscopy column «Olympus» Evis Exera III (GIF HQ-190), CO2 insufflation system «Olympus» UCR, electrosurgical unit «ERBE» VIO 200S, electrosurgical knife «Finemedix» CleaCut-knife (Q-type), «Olympus» Dual-knife. To create a hydraulic cushion, use a solution of Gelofusin, tinted with indigo carmine. After creating the hydraulic cushion by 12-14 cm proximal to the cardia and entering the submucosal layer, a tunnel was formed along the posterior wall to the subcardial section. Myotomy was performed full-length with dissection of longitudinal and circular muscle fibers for 6-7 cm proximal to the cardia. The initiating incision was clipped by the endoclips «Olympus». During this period, 13 patients were treated successfully by POEM, with a median operation time of 57 min. Of these: 6 men, 7 women aged 38 to 73 years (mean age +53.6 years).

Results: By severity achalasia patients was as follows: stock II degree - 6 patients, with III degree - 6 patients, with IV degree - 1 patient. The average history of the disease was 3-4 years. The intraoperative complications that affected the change in treatment tactics were not revealed. The average length of hospitalization was 8,2 days. In the postoperative period, patients clinically noted the absence of dysphagia, absence of night cough and pain behind the sternum. In postoperative period all the patients took antisecretory and enveloping drugs. Positive dynamics was observed with X-ray control, contrast substance freely passed through the cardia.

Conclusions: POEM is a new, relatively safe, minimally invasive method for treating patients with achalasia cardia, which allows to shorten the period of hospitalization and has a wonderful cosmetic effect. However, the final conclusions on the effectiveness and safety of this operation can be done after a deeper analysis of a larger group of patients and a longer period of observation.

114**DIAGNOSIS AND CHOICE OF A METHOD OF TREATMENT OF INTRAABDOMINAL HYPERTENSION AND ABDOMINAL COMPARTMENT SYNDROME****R. Gafarova***Russia*

In the past three decades studies have shown the important role of redundant, especially acute, rapid increase in intra-abdominal pressure (IAP), clinically significant pathological effects which are called syndrome of abdominal hypertension (IAH) and abdominal compartment syndrome (ACS). Due to various etiological factors, leading to an increase in IAD (inflammatory, destructive processes, trauma, sepsis, postoperative complications, etc.) negative effects of increased IAP on the function of the gastrointestinal, respiratory, cardiovascular system, kidneys, Central nervous system, often as AHI clinically not recognized, although IAH (IAP>12 mm Hg.art.) occurs in 25-30% of therapeutic and more than 40% of emergency surgical patients [6.11.12], and mortality can reach from 10% to 68% and above [6.17]. In 2013, significant amendments were made to the Recommendations of the world society for abdominal compartment syndrome (VOAX) 2006,2007 and 2009. Now the important role is given to the results of clinical trials and confirmation of the proposed recommendations by clinical experience [8]. In General, the therapeutic tactics in IAG/ACS appear to be less "aggressive" and more conservative, open surgical decompression is used when the entire Arsenal of known methods of conservative, medicamentous treatment is exhausted [5]. Clinical symptoms are also the exact productora high IBP, and IBP regular measurements allow to identify patients with risk of development of IAD/ACS [4.15]. The algorithm of recommendations of VOAX is based on three principles [8]. Firstly, regular measurement of IAP is necessary for the diagnosis of IAH/ACS. Second, when IAD increases, medical treatment should be carried out as soon as possible to reduce IAD and prevent the development of ACS. Thirdly, targeted optimization of systemic hemodynamics is important for maintaining organ function during surgical decompression of the abdominal cavity, when the previously mentioned measures are unsuccessful.

115**IMAGING AFTER CRYOABLATION OF PANCREATIC TUMORS****Y. Galchina, N. Karelskaya, V. Vdovenko, G. Karmazanovsky, D. Ionkin, A. Chzhao***«A.V. Vishnevsky NMSC of surgery», Moscow, Russia*

Relevance: Malignant pancreatic tumors are often occurring. Up to 80% of patients have a locally advanced cancer at the time of diagnosis and it is unresectable. The only treatment until 1990 was chemo-radiotherapy. Nowadays, a promising method of palliative treatment of pancreas locally advanced cancer is cryoablation.

Purpose: to evaluate the imaging methods of the completeness of cryoablation (CA) in patients with pancreatic tumors. **Methods:** For the period 2012-2018 69 patients underwent the CA of the pancreatic tumors. 19 patients underwent dynamic postoperative monitoring by imaging methods. Duplex ultrasound, CT and MRI were performed before and after operation: in 1st day, 3 months, 6 months, 12 months. **CT criteria of the fullness of CA in pancreas tumors:** a change in contrast enhancement on the tumor, the of tumor size, local prevalence, the severity of pancreatic hypertension. **MRI criteria of the fullness completeness of CA in pancreas tumors:** decrease of the diffusion coefficient. **Duplex ultrasound criteria of the fullness completeness of CA in pancreas tumors:** blood flow in the tumor.

Results: Duplex ultrasound showed a decrease of blood flow in the tumor. MRI in the first day after ablation of pancreas tumors is poorly informative due to the postoperative perifocal changes. MRI in 3 and 6 months showed a decrease of diffusion restriction in the tumor. Contrast enhanced CT showed that the intensity of contrast agent accumulation by the pancreas tumors in terms of 3 and 6 months was less than before CA. A gradual narrowing of the lumen of the vessels was noted. The size of the CA zone did not change in terms of 3 and 6 months, but in term of 12 months increased moderately.

Conclusions: 1. MRI in the first day after cryoablation in pancreas tumors is poorly informative due to postoperative changes. In the subsequent periods of monitoring, a decrease in the diffusion coefficient was noted. 2. Duplex ultrasound showed a significant decrease in the intensity of blood flow in pancreas tumors. There contrast agent accumulation by the pancreas tumors in terms of 3 and 6 months was less than before CA. 3. These criteria can be used to assess the fullness of the tumor cryoablation.

116

ENDOVIDEOSURGICAL RADICAL NEPHRECTOMY WITH THROMBECTOMY OF IVC

E. Galliamov¹, R. Biktimirov², V. Sergeev³, A. Sanzharov⁴, E. Gallyamov⁴

¹Federal State Autonomous Educational Institution of Higher Education I.M. Sechenov First Moscow State Medical University of the Ministry of Health of the Russian Federation (Sechenov University), Moscow, Russia

²Federal State Institution "Federal Clinical Center of High Medical Technologies of the Federal Medical and Biological Agency", Moscow, Russia

³Federal State Institution «State Research Center of Russian Federation - the Federal Medical Biophysical Center named A.I. Burnazyan» FMBA of Russia, Moscow, Russia

⁴Federal State Institution «Federal Scientific and Clinical Center for Specialized Methods of Medical Care and Medical Technologies» - the Federal Medical Biological Agency, Moscow, Russia

Aims. Endovideosurgical radical nephrectomy is a routine operation, but not in the case of tumor thrombus of inferior vena cava (IVC). Surgery complexity is associated with the need to exclude the flow of blood into IVC and its opening.

Material and methods. In 2016–2017, 3 endovideosurgical nephrectomies with subsequent thrombectomy of the IVC were performed. The first 60-years-old patient was diagnosed with right kidney tumor (T3bN0M0) and a blood clot in IVC 1 cm above hepatic veins. The second 80-year-old patient was diagnosed with cancer of the left kidney (T3bN2M0), a thrombus up to the level of the caudate lobe of the liver, and enlarged lymph node below the renal vein. The third 69-year-old patient was diagnosed with cancer of the left kidney (cT3bNxM0) (laparoscopic nephrectomy for right kidney cancer (pT1aN0M0G2) in 2016) and tumor thrombus in the renal vein protruding into IVC lumen.

Technical for operation. The operation included endovascular placement of thrombo extractor and above it placement of a balloon catheter in the vena cava at the level of the hepatic veins; mobilizing the kidney affected by tumor; separation and intersection of gonadal vein and ureter; separation of anterior wall of the IVC (with portacaval lymphodissection in 2nd and 3d patients); separation of renal hilum and artery intersection; excision of affected kidney; separation of hepato-duodenal ligament (HDL) with the portal vein; mobilization of the renal vein of the healthy kidney (in 1st and 2nd patients); extensive mobilization of vena cava and intersection of lumbar veins; clamping tributaries (bulldog clamp on renal vein of the healthy kidney, tightening HDL with tourniquet; applying Satinsky Vena Cava Clamp to the lower edge of IVC); cavotomy; thrombectomy with resection of IVC; repairing IVC defect; reestablishing blood flow; hemostasis testing.

Results. Operation time was 320 minutes, duration of vena cava clamping - 18 min., blood loss – 2100 ml., resuscitation duration - two days, hospital stay - 10 days.

Conclusion. Endovideosurgical radical nephrectomy and thrombectomy is a labor-intensive operation that requires vast experience and coordination of the surgical team. This approach is less traumatic, with easier postoperative period is essential for patients with high comorbidity index.

117

EXPERIENCE OF ENDOVIDEOSURGERY PELVIC EXENTERATION

E. Galliamov¹, V. Sergeev², A. Sanzharov³, E. Gallyamov³, G. Gololobov¹

¹Federal State Autonomous Educational Institution of Higher Education I.M. Sechenov First Moscow State Medical University of the Ministry of Health of the Russian Federation (Sechenov University), Moscow, Russia

²Federal State Institution «State Research Center of Russian Federation - the Federal Medical Biophysical Center named A.I. Burnazyan» FMBA of Russia, Moscow, Russia

³Federal State Institution «Federal Scientific and Clinical Center for Specialized Methods of Medical Care and Medical Technologies» - the Federal Medical Biological Agency, Moscow, Russia

Treatment of patients with primary and recurrent locally advanced pelvic tumors represents an extremely complex problem of surgical oncology.

Aim. Evaluate perioperative and long-term postoperative results of laparoscopic pelvic exenteration technique.

Material and methods. In the period 2011 to 2018, 21 pelvic exenteration was performed with laparoscopic access, (mean age 59.79±8.5), sex distribution: 17 women and 4 men. Nosology distribution: in 6 patients cervical cancer was verified, 7 patients had bladder cancer, 4 patients had rectal cancer, 1 patient had vaginal cancer, 2 patients had recurrence of vaginal cancers after previous uterine extirpation and 1 patient with ovarian neoplasm. The most common complaints were blood in stool, constipation, pelvic pains, weakness, and sharp weight loss. Most patients had anemia, agranulocytosis and lymphocytosis. When lower urinary tract was involved in the tumor process, urea and creatinine levels increased. The volume of the exenteration was as follows: 9 total, 7 anterior and 5 posterior. The duration of the operation, the volume of blood loss, the frequency and nature of intra- and postoperative (Clavien-Dindo) complications were evaluated.

Results. Surgery duration was 227.3±70 minutes, intra-operative blood loss was 363.8±117 ml, postoperative stay was 10±3. Major postoperative complications (grade 3/5) were observed in 3 patients (14.3 %). In all cases, it was possible to achieve a negative margin of resection line (R0). Follow-up period was 6–28 days. In the postoperative period, all patients received chemotherapy and/or chemoradiotherapy. 12 months after the operation, two patients

with no relapses underwent reconstructive laparoscopic colostomy reversal.

Discussion. As a comparison group, we used patients after open exenteration. Given the absence of our own database of such patients, data on patients after open operations were taken from literature sources. Using of laparoscopic access is accompanied by a smaller amount of blood loss, decrease of frequency of early postoperative complications, contributes to more comfortable postoperative period with early activation, less severe pain syndrome and leads to a reduction in the duration of inpatient treatment.

Conclusion. The pilot results testify to the safety of the laparoscopic technique of exenteration of the pelvis and allow it to be recommended in specialized hospitals, which has extensive experience in performing laparoscopic interventions.

118

LAPAROSCOPIC CORRECTION OF RECURRENCE OF GASTROESOPHAGEAL REFLUX DISEASE AND HERNIA OF THE ESOPHAGEAL APERTURE OF THE DIAPHRAGM

E. Galliamov¹, S. Erin², Yu. Busirev¹, K. Presnov³, G. Starkov⁴

¹Federal State Autonomous Educational Institution of Higher Education I.M. Sechenov First Moscow State Medical University of the Ministry of Health of the Russian Federation (Sechenov University), Moscow, Russia

²City Clinical Hospital named S.I. Spasokukockogo, Moscow, Russia

³Diversified Medical Center of Bank of Russia, Moscow, Russia; ⁴Federal State Institution "Central Hospital of Civil Aviation", Moscow, Russia

Introduction. Laparoscopic antireflux surgery are becoming more frequent tool in the treatment of gastroesophageal reflux disease (GERD). In this case, according to the literature, symptoms of dysphagia in the postoperative period arise again in 3-30% of patients, which leads to the fact that 3-6% of them are operated repeatedly. The purpose of research - assessment mechanisms for recurrence of GERD and the ability to perform adequate surgical correction after primary antireflux surgery.

Aims. Fundoplication for gastroesophageal reflux disease (GERD) and hernia of the esophageal opening of the diaphragm (GVPD) often do not lead to desired effect.

Materials and methods. The team of authors during the period from 1993 to 2018 operated on 2,678 patients for GERD and hernia of the esophageal aperture of the diaphragm (GVAP). 127 (4.74%) patients underwent surgery for recurrent form of the disease, 46 from their initial operation is performed in other clinics.

Results. Surgery for recurrent hernia included restoration of abdominal esophagus position, and posterior 'cruroraphy' in

42 (33%) patients; posterior and anterior 'cruroraphy' in 8 (6.30%) patients; mesh implants plasty of diaphragmatic 'crura' 'diastasis' was performed in 8 (6.30%) patients. Surgery for Slippage syndrome included the revision of the original wrap, its unfolding, formation of a new wrap: Nissen fundoplication in 16 (12.60%) patients, Toupet fundoplication in 6 (4.72%) patients. 8 (6.30%) patients underwent posterior 'cruroraphy'. Surgery for wrap failure included the revision of the deformed wrap and its conversion to a short loose wrap in 22 (17.3%) patients (Nissen 'fundoplication'). When needed, posterior 'cruroraphy' was performed in 7 patients and proximal gastropexy in 8 patients. With stenosis in the wrap area, adhesions were observed in upper abdominal cavity with cicatricial periprocess – 7 patients (5,51). These patients underwent revision of wraps; circular wraps were converted into partial (Toupet 'fundoplication'). Surgical approach for GERD recurrence was determined by clinical picture: in 5 (3.94%) patients with flatulence and 2 (1.57%) with dysphagia a tight long circular wrap was converted to softer shorter circular wrap; in 3 (2.37%) patients with recurrent GERD, partial wraps were converted to circular wraps. The median follow-up of re-operated patients was 63 months (12 to 139 months). A satisfactory functional result was achieved in 76.4% of the reopened patients.

Conclusion. Relapses after first fundoplication were probably caused by insufficient experience of the operating team, mechanical errors during surgery, wrong modifications of 'anti-reflux surgery' for particular patients.

119

LAPAROSCOPIC HYSTERECTOMIES: EXPERIENCE OF IMPLEMENTATION, ANALYSIS OF RESULTS

E. Galliamov¹, L. Aminova², V. Alimov², A. Myrzin¹, E. Kryukova¹

¹Federal State Autonomous Educational Institution of Higher Education I.M. Sechenov First Moscow State Medical University of the Ministry of Health of the Russian Federation (Sechenov University), Moscow, Russia; ²GC "MEDSI", Moscow, Russia

The widespread introduction of laparoscopic technologies in the daily practice of a gynecological hospital leads to the fact that more and more hysterectomies are performed by this method.

The aim of our study was to analyze the results of laparoscopic hysterectomies carried out in our clinic in the period from 2013 to 2017, to find the best ways to perform these surgical procedures.

Materials and methods. In our clinic was performed 937 laparoscopic hysterectomy. Indications for the operation were: uterine myoma, adenomyosis, atypical endometrial hyperplasia in the perimenopausal period, recurrent pathology of the endometrium in postmenopausal, cancer of the uterus

and appendages. Depending on the type of pathology conducted the following types of operations: laparoscopic supravaginal amputation of the uterus (from 32 patients), laparoscopic hysterectomy with fallopian tubes (458 patients), laparoscopic hysterectomy with appendages (407 patients), laparoscopic extirpate of the uterus with pelvic lymph node dissection/resection of the greater omentum (40 patients). The average age of patients who underwent laparoscopic hysterectomy was 52±4.8 years. The size of the uterus varied from 6 to 32 weeks of gestation. The average time of operations, time of hospital treatment, number of postoperative complications were estimated.

Results. The average time for laparoscopic hysterectomies was 82±28,7 min. In the cases of performing pelvic lymphadenectomy or resection of the greater omentum for cancer average operation time was lengthened to 165±23,6 min. The average duration of hospitalization during laparoscopic hysterectomy was 4 ±1.2 days. Complications during laparoscopic hysterectomy occurred in 8 patients (0.85%): 4 cases of bleeding from the vaginal stump (after sexual intercourse due to non-compliance by patients with the terms of the protective regime); 2 cases of pericultitis; 2 cases of bleeding from a trocar wound. Intraoperative lesions of the ureters and other pelvic organs, as well as vaginal stump after surgery for the study period were not observed.

Conclusion. Analyzing our own operational experience, we have identified three key points in this type of intervention: 1. Strict adherence to the sequence of hysterectomy stages to adequately perform this kind of intervention even with large uterine size (more than 15 weeks); reduces the risk of intraoperative damage to the ureter and improves the safety of this operation. 2. Implementation of colorectal by McCauley is a reliable prevention of the loss of the stump and it can be recommended as an alternative to the supravaginal amputation of the uterus with the extent of the operation.

120

LAPAROSCOPIC LATERAL SECTIONECTOMY FOR LIVING LIVER DONATION

E. Galliamov¹, A. Monahov², E. Zagaynov³, Yu. Busirev¹, G. Gololobov¹

¹Federal State Autonomous Educational Institution of Higher Education I.M. Sechenov First Moscow State Medical University of the Ministry of Health of the Russian Federation (Sechenov University), Moscow, Russia

²Federal State Budgetary Institution «National Medical Research Center of Transplantation, Moscow, Russia

³The Loginov Moscow Clinical Scientific Center is State Institution funded by Moscow, Moscow, Russia

Introduction. Transplantation of liver fragments of an adult related donor to children demonstrates good short-term

and long-term survival. Laparoscopic liver resection in a living donor is a surgical innovation aimed at accelerated rehabilitation of the donor and achieving a better cosmetic effect.

Aims. Analyze the experience of the Federal Research Center of Transplantology and Artificial Organs named V.I. Shumakov and compare it with the experience of leading foreign centers.

Materials and methods. From 2016 to 2017, 33 completely laparoscopic resections of liver fragments for transplantation to children were performed in our Center. In 31 cases, resection of the left lateral sector was carried out and in 2 cases leftsided hepatectomy was performed.

Results. The average age of donors was 29.64 (± 4.78) years. The average blood loss was 93.41±60 ml. The duration of operations was 290±40 min. The period of hospital stay was 4±1.4 days. Surgical complications according to the Clavien-Dindo 'classification' above Grade II were not observed.

Conclusion. The program of laparoscopic resection of liver fragments of an adult donor for transplantation to children demonstrates efficiency. The perioperative characteristics of the presented innovation correspond to the experience of the world's leading clinics.

121

THE METHODS OF INTRAOPERATIVE BLOOD LOSS REDUCTION DURING LAPAROSCOPIC MYOMECTOMY

E. Galliamov¹, L. Aminova², V. Alimov², A. Myrzina², A. Garina¹

¹Federal State Autonomous Educational Institution of Higher Education I.M. Sechenov First Moscow State Medical University of the Ministry of Health of the Russian Federation (Sechenov University), Moscow, Russia
GC «MEDSI», Moscow, Russia

Laparoscopic myomectomy is the operation of choice for women who plan pregnancies and have myomas. If large myoma size, numerous myomas and difficult locations take place myomectomy is accompanied by critical blood loss, so surgeons have to find methods to prevent it. Intraoperative blood loss reduction is also an urgent problem for patients with symptomatic myomas, excessive or prolonged menstrual bleeding, intermenstrual bleeding that result in initially low hemoglobin before surgery. The objective of our study was to find ways to reduct intraoperative blood loss during laparoscopic myomectomy using modern medical technics.

Materials and methods. Over the period 2013 to 2017, 268 laparoscopic myomectomies were performed at the gynecology department of the Hospital №2, JSC, GC «MEDSI». In order to prevent blood loss, 82 of 268 surgeries were performed using temporary internal iliac artery clipping.

Results and Discussions. The indications were: numerous myomas, large myomas, difficult location of myoma (cervical

region, posterior uterine wall or deep location). In these cases uterine size was 10-28 pregnancy weeks, number of myomas was 1-18. The average blood loss was $193 \pm 47,5$ ml. Besides temporary clipping, in 4 cases vessels clamps were applied to utero-ovarian ligaments. In 186 cases we used ultrasonic scissors HARMONIC; it caused reduction of operation duration and thus blood loss. Accurate sealing of myoma bed is necessary for good hemostasis and prevention uterine rupture during pregnancy. Using suture material V-LOC relieves from the necessity to make knots and so let stitch up the myoma bed faster, reduce blood loss. Unidirectional notches on sutures prevent suture line disruption. Suture material V-LOC was used in 193 cases, in other cases we used Vicryl (submucosal myomas, one-row suture on the external side of myometrium and serous tunic). Over the period besides above-mentioned methods, during 7 laparoscopic myomectomies we used intraoperative blood reinfusion by instrument CellSaver. In all 7 cases patient had initially moderate/medium anemia because of intermenstrual bleeding. Uterine size was 10-28 pregnancy weeks. 4 patients had numerous myomas of various sizes, 3 patients had 1 large interstitial myoma. Blood loss was 500-1000 ml. The volume of rein fusion and washed erythrocytes was 200-350 ml. So, using modern laparoscopic instruments, suture material V-LOC let reduce blood loss during laparoscopic myomectomies. In complicated cases (numerous myomas, large myomas, anemia, difficult myoma) it is effective to use intraoperative temporary internal iliac artery clipping and blood reinfusion by instrument CellSaver.

122

URGENT LAPAROSCOPIC SURGERY

E. Galliamov¹, O. Lutsevich², M. Agapov³, Yu. Busyrev¹, A. Kirillin¹

¹Federal State Autonomous Educational Institution of Higher Education I.M. Sechenov First Moscow State Medical University of the Ministry of Health of the Russian Federation (Sechenov University), Moscow, Russia

²A.I. Yevdokimov Moscow State University of Medicine and Dentistry, Moscow, Russia; ³University clinic Lomonosov Moscow State University, Moscow, Russia

Objective. The determination of possibilities of endoscopic surgical technologies in the treatment of urgent pathology of the abdominal cavity.

Materials and methods. More than 8100 emergency operative endovideosurgical interventions were conducted in the case of acute diseases of the abdominal cavity from 1993 to 2016 in the hospitals presented by the authors. They included 2705 laparoscopic appendectomies in acute appendicitis, 4557 laparoscopic cholecystectomies in acute cholecystitis, 171 laparoscopic sanitations and drainage of the abdominal cavity and stuffing bags in acute pancreatitis, enzymatic

peritonitis, 191 laparoscopic suturings of perforated gastroduodenal ulcers, 153 laparoscopic resolutions of intestinal obstruction in acute adhesive small bowel obstruction, 46 emergency laparoscopic colon resections, 91 laparoscopic hernioplasties of strangulated inguinal hernias, 186 staged sanitations of the abdominal cavity in the peritonitis of different etiology.

Results. Acute intestinal obstruction was due to a single adhesion in 58 % cases and due to massive adhesions in 42% cases. The basic principle of operation at acute intestinal obstruction is work with cold scissors, atraumatic intestinal clamps. The movement of the optical trocar in different points of the abdominal wall is based on the principle of "the triangle". 14 laparoscopic operations in Hartmann's type with the removal of colostomy were conducted in acute colonic obstruction caused by occlusive tumors, then patients underwent a laparoscopic reconstruction. The resection of the transverse colon was made in 1 case. The laparoscopic right hemicolectomy with an open decompression and primary anastomosis was carried out in 16 cases. 15 laparoscopic resections of the sigmoid colon with the removal of colostomy were conducted in diverticulitis and perforation of the diverticulum with diffuse peritonitis. 171 manual-assisted and laparoscopic necrosectomies, the sanitation and drainage of the abdominal cavity with the next staged sanitations and necrosectomies were made in the case of total and subtotal pancreatic necrosis. The operations ended with the final sanitation and drainage of the abdominal cavity. The prevention of adhesive disease of the abdominal cavity have been carried out in intra- and postoperative periods: the use of anti-adhesive barriers Intercoat, Interceed, the early activation of the patient in the first day of the operation, the early stimulation of the bowel.

Conclusions. Any emergency surgery for acute surgical pathology of the abdominal cavity organs and retroperitoneal space in the absence of general contraindications must begin with the diagnostic laparoscopy. Endovideosurgical interventions in the emergency case must be conducted by high-qualified professionals who have experience and skills in traditional and laparoscopic operations of various complexity.

123

DIAGNOSIS AND SURGICAL TREATMENT OF DEEP INFILTRATIVE ENDOMETRIOSIS

E. Galliamov¹, L. Aminova², V. Alimov², A. Myrzina², E. Golubenko¹

¹Federal State Autonomous Educational Institution of Higher Education I.M. Sechenov First Moscow State Medical University of the Ministry of Health of the Russian Federation (Sechenov University), Moscow, Russia
GC "MEDSI", Moscow, Russia

Endometriosis is a common gynecological disease. Deep infil-

trative endometriosis (DIE) of the intestine is the most difficult problem for diagnosis and treatment. The most common symptoms of this disease include dyspareunia, chronic pelvic pain (CPP), pain during defecation and intestinal symptoms. Due to the high technical complexity of DIE surgery, difficulties in diagnosis at the preoperative stage a differentiated approach is required for patients with this disease.

Aims. Assessment of the compliance of data on the distribution of endometriosis, received at the preoperative and intraoperative stage; assessment of life quality of patients at pre- and postoperative stages.

Materials and methods: retrospective analysis of 616 cases of surgical treatment for endometriosis from 2013 to 2018 on the base of the gynecological department of clinical hospital №2 MEDSI was carried out. Of these, 142 surgery (23%) were performed for intestinal DIE: shewing the rectum (122 cases), excision of the endometriosis infiltrate to submucosal layer (12 cases), discoid (5 cases) and circular (3 cases) bowel resection. Before the operation patients have rectovaginal examination, ultrasound and MRI of the pelvic organs, colonoscopy. Subjective assessment of the pain syndrome with dyspareunia, CPP, pain during defecation was carried out for 35 patients with intestinal DIE.

Results: Of the 142 operated patients with DIE, involvement in endometrial infiltration of the rectum was installed for 92 patients (64.8%) during the preoperative stage. There were cases of intraoperative detection of intestinal GIE due to due to underestimation of the degree of endometriosis at the preoperative diagnosis. In 7 cases (4.9%), the final capacity of the surgical treatment (bowel resection) was performed by the second stage after the post-examination. Results of treatment of 35 patients were examined by questionnaire 3 months after the operation. 22 patients were carried out shewing the rectum, 7 - excision of the focus to the mucous layer of the intestine, 4-discoid and 2-circular intestinal resection. In all patient groups the pain level was reduced by an average of two times.

Conclusion: 1. Radical treatment of intestinal DIE leads to a significant reduction in the severity of pain during coition, defecation, decrease in severity of CPP and as a consequence to improvement in the quality of patients life. 2. Despite the multiplicity methods of preoperative examination of the patient, laparoscopy remains the "gold standard" for the diagnosis of intestinal DIE. In cases of lack of necessary skills and inadequate preparation of the patient, it is advisable to divide the operation into two stages: the first step is to restore as much as possible the anatomy of the pelvic organs, the second stage is to perform a radical surgery to resection the focus of endometriosis, including intestinal resection.

124

COMPARATIVE ANALYSIS OF THE CHARACTERISTICS OF LAPAROSCOPIC AND ROBOT-ASSISTED LAPAROSCOPIC FUNDOPLICATION WITH HERNIA HIATAL

E. Galliamov¹, S. Erin², M. Dibirov², I. Semenyakin², K. Chukitu¹

¹*Federal State Autonomous Educational Institution of Higher Education I.M. Sechenov First Moscow State Medical University of the Ministry of Health of the Russian Federation (Sechenov University), Moscow, Russia*

²*City Clinical Hospital named S.I. Spasokukockogo, Moscow, Russia*

Hiatal hernia (HH), and as the main manifestation of HH - gastroesophageal reflux disease (GERD) is a very common and disease. This disease accounts for up to 75 % of all pathologies related to the esophagus and stomach. Ten percent of the adult population of the Russian Federation suffer from such a disorder as heartburn (the main symptom of GERD) daily and up to 40 % - at least once a month. Therapeutic treatment of this disease has traditionally been focused on the suppression of gastric secretion and improve the tone of the esophagus and stomach, and is usually long. When canceling therapy, almost 90% of patients experience relapse of symptoms. Long-term use of proton pump inhibitors (PPI) in turn leads to the development of a whole list of complications. In recent years, due to the widespread laparoscopic surgery, indications for surgery have increased significantly. The most widely operation of open procedures, to modify Flopi. The questions of indications for surgical treatment in HH and GERD are well covered in the literature. Materials and Methods. During 2015-2017, 55 patients were operated in our clinic using the da - Vinci robotic system, laparoscopic robot-assisted fundoplication and 238 traditional laparoscopic fundoplication were performed. The group of robot-assisted operations included 55 patients: 34 women and 21 men, the average age was 47±7 years, the average body mass index was 27±4, the risk on the ASA scale was 2.4±1.3. Axial cardiophorinae hernia in 34%, paraesophageal hernia 56% and mixed hernia 10%.

Result. The mean duration of operation in the period of development of the technique amounted to 130-140 After 10 minutes of operation the duration of 80-100 minutes. All operations were performed without blood loss. Postoperative bed-day 1.8±2 d. For comparison, we have identified several characteristics: the number of ports (accesses), visualization, surgery time, comfort of the surgeon and assistant, learning curve. We conducted this review to predict the future of robot-assisted laparoscopic fundoplication (RALF), namely, looking at this new technology from different angles, compared to conventional laparoscopic fundoplication (CLF), in terms of operative complications and postoperative results, the training aspect RALF, applications in complex cases and challenging tasks.

Conclusion. We are of the opinion that there is a promising

future for RALF, despite the increased costs and longer operation times. It has been found that RALF can function better in smaller spaces and is more capable of thinner dissection and has a shorter and steeper learning curve. It is expected to reduce time and money costs with further development and modernization of robotic surgery, as well as increase the experience of surgeons in RALF. Thus, we believe that this Ralf trend refers to the future of anti-reflux surgery.

125

LAPAROSCOPIC SUBTRIGONAL BLADDER AUGMENTATION: SEGMENTARY OR SPHERICAL DOME?

E. Galliamov, T. Mikhaylikov, A. Kovalenko, A. Sanzharov, V. Sergeev, K. Prohorenko
Russia

Introduction: Bladder pain syndrome is the state which despite being benign anyway significantly decreases life quality. After the fall of antibacterial therapy the first line of treatment are hydrodistension and introduction botulin toxin A into detrusor. However in case of their inefficiency surgical removal of scarred tissues should be considered. According to EAU recommendations the best results are for subtrigonal cystectomy with bladder augmentation with intestinal segment. We present 2 type of such operations: with segment-shaped and spherical shaped domes

Aim: To define optimal technique of bladder augmentation

Materials: 4 patients with bladder pain syndrome (confirmed by histological examination) after many courses of antibacterial and at least 1 attempt of hydrodistension progressed in sclerotic bladder patients. All of them survived laparoscopic subtrigonal cystectomy with bladder augmentation with intestinal segment: 2 patient with segment-shaped (group 1) and 2 patients with spherical shaped domes (group 2) The highest bladder capacity in group 1 was 112,2 ml, in group 2 115,3 ml. One patient of group 2 had bilateral ureteral stricture because of what he had additionally transposition of both ureters in the newly formed dome.

Results: Intervention time in group 1 was 212.5 min, in group 2 - 181.5 min. Blood loss in both groups was up to 200 ml. For 10 days all the patients had bilateral external ureteral stents while the drainage of the augmented bladder was removed in 12 days 20, no urinary leaks was met. All the patients had self urination with abdominal support, desire of urination was saved, full continence. Urination volume in group 1 during the day 1 and day 2 amounted to 46.5 ml, in group 2 - 48.2 ml. In 10 days it changed to 120.3 ml and 124.2 ml, accordingly. In 3 months - 205.4 ml and 201.6 ml, accordingly.

Conclusion: Also, based on the data we suppose there is no difference in functional outcomes in segment-shaped and spherical-shaped domes while bladder augmentation but the first technique looks to be faster and more simple. Following investigations are needed.

126

LAPAROSCOPIC RESECTION OF THE KIDNEY IN TUMORS OF R. E. N. A. L. ≥ 10

E. Galliamov¹, A. Kochkin², V. Sergeev³, A. Sanzharov⁴, E. Gallyamov⁴

¹Federal State Autonomous Educational Institution of Higher Education I.M. Sechenov First Moscow State Medical

University of the Ministry of Health of the Russian Federation (Sechenov University), Moscow, Russia

²Private Healthcare Institution "Road Clinical Hospital at the Nizhny Novgorod Station of the Open Joint Stock Company" Russian Railways", Nizhny Novgorod, Russia

³Federal State Institution «State Research Center of Russian Federation - the Federal Medical Biophysical Center named A.I. Burnazyan» FMBA of Russia, Moscow, Russia

⁴Federal State Institution «Federal Scientific and Clinical Center for Specialized Methods of Medical Care and Medical Technologies» - the Federal Medical Biological Agency, Moscow, Russia

Introduction. The introduction of laparoscopy in urology changed the approach to the selection of patients for organ-preserving surgical treatment of renal parenchyma tumors. In particular, the criteria of resectability are determined by the so-called nephrometry scales, such as "R. E. N. A. L." (A. Kutikov, Uzzo R., 2009). According to this scale, if the index value is more than 10, the probability of successful resection drops significantly. This circumstance mainly determines the volume and the option of surgery, preferably nephrectomy.

Material and methods. The work is based on the results of a retrospective analysis of the treatment results of 226 patients (mean age 56 years, body mass index 30.1 kg/m²) with kidney tumors, evaluated on the above scale values of more than 10 points, to whom laparoscopic resection was performed. Both intra - and postoperative complications, duration of operation and inpatient treatment were taken into account.

Results. Mortality and conversion rates were not. All operations performed transabdominal; 10 - transtentorial; in 23 cases, without clamping renal artery. The average warm ischemia time was 18±2 min, Average blood loss volume and operation time reached 220 ml and 215 minutes, respectively. The number of postoperative complications (Clavien \geq III) is 4.42%. In 6 cases, the pelvis was stented and in 3 case the formation of an arteriovenous fistula with a urinary tract tamponade occurred-superselective embolization of the segmental renal artery was performed. The average duration of hospital treatment was 7±0.91 bed days.

Conclusion. The results of the study demonstrate the possibility of effective implementation of laparoscopic resection of the kidney in tumors "R. E. N. A. L. ≥ 10 " with the tactics of organ-preserving intervention. Nephrometry scale are important as a tool to objectively assess clinical situations, but cannot be considered as an immutable guide to action.

127

LAPAROSCOPIC TREATMENT OF CANCER AND GASTROINTESTINAL STROMAL TUMORS OF THE STOMACH

E. Galliamov¹, Yu. Busirev¹, K. Presnov², E. Gallyamov³, E. Mekhdiev¹

¹Federal State Autonomous Educational Institution of Higher Education I.M. Sechenov First Moscow State Medical University of the Ministry of Health of the Russian Federation (Sechenov University), Moscow, Russia

²Diversified Medical Center of Bank of Russia, Moscow, Russia

³Federal State Institution «Federal Scientific and Clinical Center for Specialized Methods of Medical Care and Medical Technologies» - the Federal Medical Biological Agency, Moscow, Russia

Introduction. The cancer of the stomach continues to account for almost a third of all deaths from malignant tumors all over the world. The surgical method remains the main method in the treatment of locally advanced gastric cancer. Gastrointestinal stromal tumors (GIST) are most often localized in the stomach. In patients with tumors greater than 10 cm, the 5-year survival was only 20%

Materials and Methods. From 2000 to 2018, 132 patients with various forms of oncological diseases of the stomach were operated. Of these, 84 (64%) men and 48 (36%) women. The age of patients ranged from 32 to 85 years. The scope of the lesion was established on the basis of X-ray examination, endoscopic examination, ultrasound data, computed tomography (CT). Evaluation of the lesion of the stomach was also evaluated according to biopsy data. The stage of the process in the preoperative and postoperative period was assessed according to the classification of the International Cancer Union.

Results and Discussions. A team of authors performed 132 laparoscopic interventions, 85 of them for stomach cancer, 47 for gastric GIST. In 46 cases was performed gastrectomy, in 39 cases was performed subtotal resection of the stomach. In 47 patients with GIST in 39 cases was performed laparoscopic sectoral resection of the stomach and in 8 cases laparoscopic proximal resection of the stomach was performed. All patients with gastric cancer underwent standard D-2 lymphodissection. These surgical interventions were performed using standard sets for endovideosurgical interventions, using HARMONIC ultrasound scissors, LIGASURE bipolar coagulation apparatus, EnSeal, a set of linear endoscopic staplers (Eshelon, ATB-45, Flex, EndoGIA-30, Endouaniversal) for manual assisting LAP-DISK, DEXTRUS. The resected organ was paralyzed and evacuated from the abdominal cavity in an airtight container, observing the principles of ablatics. The average time of surgical interventions was 180 min, the average blood loss was 300 ml, the average bed-day was 8 days. Complications after surgery arose in 9 (6.9%) cases in the form of an anastomosis. In 1 (0.8%) case, a patient with developed anastomosis has a self-expanding uncovered

nitinol stent (removed after 2 months).

Conclusions. Using endovideosurgical technologies in the treatment of malignant formations of the stomach makes it possible to ensure the observance of oncological principles of treatment of malignant diseases and adequate radical intervention in case of small / minimal invasiveness. A small percentage of complications (6.9%) allows us to compare endovideosurgical methods of treatment with traditional ones, however, in view of the small number of observations, it is premature to systematize remote oncological results.

128

LAPAROSCOPY IN SEVERE ACUTE PANCREATITIS

E. Gallyamov¹, O. Lutsevich², M. Agapov³, A. Shaligin¹, I. Gorbacova¹

¹Federal State Autonomous Educational Institution of Higher Education I.M. Sechenov First Moscow State Medical University of the Ministry of Health of the Russian Federation (Sechenov University), Moscow, Russia

²A.I. Yevdokimov Moscow State University of Medicine and Dentistry, Moscow, Russia; ³University clinic Lomonosov Moscow State University, Moscow, Russia

Objective. To examine the effectiveness of laparoscopic and manual assisted videoendoscopic surgical benefits in the treatment of severe acute pancreatitis (SAP).

Materials and methods. From 2004 to 2017 171 patients with SAP were operated using laparoscopy. The age of the patients ranged from 28 to 77 years. The volume and prevalence of destruction of the pancreas and surrounding tissues were determined on the scale of Balthazar (1985). The patents were stratified on the scale of Balthazar: with degree D (3 points) - 39 patients, with degree E (4 points) - 32 patients. The fact of the infection was established with bacteriological study of the intraoperatively collected material. The severity of the patients' condition was estimated on the scale APACHE II 9,4±0,9.

Results. The conduct of the primary surgical necrectomy was the first stage in the treatment of pateints with SAP. In that case the pancreatic infection was not the only indication for surgery. Laparoscopic manual assisted (hybrid) access and laparoscopic access were used in the SAP treatment, parapancreatic flegmons and paracolic fiber were used in the treatment of pancreatogenic peritonitis. From the first day after the initial rehabilitation the irrigation of parapancreatic space was started through multiple drainage structures using large quantities of sterile saline (up to 10 l per day). Staged rehabilitations were conducted through laparoscopic access or extraperitoneal endoscopic ecess depending on the dynamics of the clinical picture and the data of computer tomography. The inability to ensure adequate single-step rehabilitation was the indication for re-operations in the programmable mode. In case of wound channels after removal of the tampons and

drainage of Penrose-Mekulich staged rehabilitations were conducted through median and/or lumbotomy accesses. The patients underwent from 1 to 15 endoscopic rehabilitations with an interval of 3-7 days. Most of the patients were on prolonged ventilation from 7 days up to 4 months. The mortality rate was 9,9% (17 patients died in the postoperative period from increasing multiorgan failure).

Conclusions. Patients with infected pancreatic necrosis are still a group at high risk among patients with SAP for whom surgery remains a preferred method of treatment. The first results of the research turned out to be optimistic but reliable statistical analysis requires a larger number of clinical observations. The establishment of standards and algorithms of the treatment of SAP and its complications using high-tech endoscopic surgical technologies requires further Randomized controlled trial.

129

NEW APPROACHES TO DIAGNOSIS AND TREATMENT OF ACUTE NECROTIC PANCREATITIS

E. Galperin, T. Dyuzheva, A. Shefer

The First Moscow Medical Sechenov University, Moscow, Russia

In 1990, Balthazar concluded that there is no correlation between the volume of pancreatic necrosis and the disease severity, length of hospital stay and the rate of complications in patients with acute pancreatitis (AP). He also stated that CT diagnosis of pancreatic necrosis can be performed only on the 6-7th day after the onset of AP. These conclusions lead to form an opinion that defining the volume of pancreatic necrosis doesn't have any advantage in the estimation of the severity and lethality of AP comparing with clinical presentation of the disease. The results of our study have showed (TG Dyuzheva) that a contrast enhanced CT discovers the volume and location of the pancreatic necrosis in the first 2-4 days after the onset of AP. Furthermore, our data revealed that identifying the degree and location of the necrotic damage of the main pancreatic duct (MPD) plays an actual role in estimation of the severity of AP unlike the approach of defining the volume of the pancreatic necrosis. Injury of MPD can be defined as pancreatic cross necrosis involving more than 50% depth of the gland. It is very important to know if the pancreatic functional parenchyma (FP) is located distal or proximal to the necrosis (configuration). If the FP is located distal to the cross necrosis involving more than 50% depth of the gland (configuration type 1 by Dyuzheva) then we can assume the disconnection of MPD with formation of the internal pancreatic fistula and the wide spread parapancreatitis (WSPP) 2-3 days after the onset of AP. The recommendations of JAP/APA arbitrarily postulates the time of intervention in these patients once there is «disconnected duct

syndrome with necrosis without signs of infection more than 8 weeks after onset of AP». Our opinion: the earlier the intervention (MPD cannulation with stenting, aspiration of fluid collections or minimal invasive surgery) in configuration type 1 patients is performed the less infection and mortality is observed. Our data will be presented in the lecture.

130

LAPAROSCOPIC APPROACH FOR LEFT-SIDE HEPATECTOMY IN LIVING LIVER DONORS: A SINGLE CENTER EXPERIENCE

S. Gautier^{1,2}, A. Monakhov¹, E. Gallyamov³, O. Tsurulnikova^{1,2}, K. Semash¹, E. Zagaynov⁴, T. Dzhambekov⁴, K. Khizroev⁴, D. Oleshkevich¹, E. Cheklecova¹

¹Federal State Budgetary Institution Academician V.I. Shumakov Federal Research Center of Transplantology and Artificial Organs, Moscow, Russian Federation

²Federal State Autonomous Educational Institution of Higher Education I.M. Sechenov First Moscow State Medical University of the Ministry of Health of the Russian Federation, Moscow, Russian Federation

³A.I. Yevdokimov Moscow State University of Medicine and Dentistry

⁴The Loginov Moscow Clinical Scientific Center is State Institution funded by Moscow Health Department

Relevance. Resection of left lateral section of the liver and left hepatectomy are the most frequent operations in living donors for transplantation liver fragments to pediatric patients. At the same time, for the enhanced rehabilitation of donors and the best cosmetic effect, in world practice laparoscopic performance of these operations are used.

Aim: to analyze own experience in left-side grafts procurement in living liver donors and to evaluate effectiveness and safety of this approach.

Materials and methods: since May 2016 to May 2018 our center performed 50 laparoscopic resections of liver fragments for transplantation to pediatric patients. Resection of the left lateral sector was performed in 47 cases, and in 3 cases left-sided hemihepatectomy was performed.

Results. The average age of donors was 29 (\pm 6.27) years. Mean intraoperative hemorrhage was 96 (\pm 49,7) ml. The duration of the operation was 298 (\pm 42) min. The period of the hospital stay was 4 (\pm 1.3) days. There was only one complication in grade IIIb (Clavien-Dindo classification).

Conclusion. Laparoscopic liver resection in live liver donors demonstrates excellent results for the faster rehabilitation of donors and the good cosmetic effect and could be performed as preferable procedure. Careful selection of donors is required for laparoscopic left hepatectomy.

131**THE PROBLEM OF TREATMENT OF VENOUS TROPHIC ULCERS AND THE WAYS OF ITS SOLUTION****A. Glukhov, M. Aralova***Voronezh State Medical University. N.N. Burdenko, Voronezh, Russia*

Varicose disease of the lower extremities is the most common pathology of peripheral vessels, affecting up to 50% of the adult population. Decompensated forms of chronic venous insufficiency contribute to the formation of long-term non-healing venous trophic ulcers, the treatment of which is a medical, social, economic problem. This dictates the need to develop and use the optimal set of the most effective modern methods of treatment. The aim of the work is to study the effectiveness of the complex personalized technology of regional treatment of patients with trophic ulcers of venous etiology.

Materials and methods. A personalized technology for regional treatment of patients with trophic ulcers of the lower limbs has been developed. The technology includes the developed method of debridement of the wound surface from pathological tissues, fibrin, necrotic tissues based on the use of contact controlled cryodestruction of pathologically altered tissues on the wound surface, and a method of stimulating regenerative processes in wounds using a combination of collagen preparations and concentrated platelet suspension. To study the effectiveness of the developed methods, a prospective analysis of the results of treatment of 302 patients (263 women and 39 men) with open trophic ulcers was carried out. The average age of patients was 65.7 years, the time interval during which the ulcer had never closed averaged 2.4 years. It should be noted that in 115 (38%) cases the area of trophic ulcers exceeded 20 cm². Patients with concomitant lesions of peripheral arteries were excluded from the study.

Results. The developed method of debridement of the wound surface, in contrast to the classical surgical treatment, for 5 days can significantly reduce pain, reduce exudation and flushing. Strengthening of the edema is associated with the peculiarities of the technique. In 90% of cases, microbial contamination decreases from 106 to 102 CFU/g. In 96% of cases, the wound surface by 5 days corresponds to the 2nd phase of the wound process. As a result of using the method of stimulation of regenerative processes in wounds using a combination of collagen preparations and concentrated suspension of platelets in cases with 136 patients with wounds up to 20 cm², the wound area due to marginal epithelialization decreased significantly faster: 71% in a month, compared with three control groups (33%, 65% and 55%). When using a combination of donor thromboconcentrate and collagen preparations before autodermoplasty with a split skin flap, the best viability of the transplant was noted in the main group a week after the operation. By the end of the first month, 89% of the patients had a full engraftment of the skin flap.

Conclusion. Contact controlled cryodestruction quickly and practically painlessly allows you to transfer the wound into the II phase of the wound process and prepare the surface of an extensive trophic ulcer for various types of skin plasty. The use of donor thrombocyte concentrate and collagen preparations statistically significantly accelerates the epithelization of the wound surface and improves the results of skin transplantation.

132**MINIMALLY INVASIVE SURGERY IN THE TREATMENT OF GASTROINTESTINAL STROMAL TUMORS****Gluzman M.I., Kashchenko V.A., Orlova R.V.***¹The L.G. Sokolov' Memorial Hospital No122, Saint-Petersburg
²Saint-Petersburg University, Medical Department, Saint-Petersburg*

Background. The relatively low incidence of gastrointestinal stromal tumors (GISTs) and the unique biological characteristics make the surgical management and outcomes of this kind of tumor still under debate. Unlike other types of malignant tumors requiring a sufficient distance to the incisional margin and performance of lymphadenectomy, GISTs only require the achievement of R0 resection, and preserving of pseudocapsula. Therefore, minimally invasive surgery (MIS) seems to be more applicable than open resections (OR) for patients with GISTs. This study aimed to explore the optimal surgical strategy for GISTs of various sites and size.

Methods. In total, 149 consecutive patients undergoing MIS or OR for pathologically confirmed GISTs from 2007 to 2017 were enrolled in this retrospective study. The demographic, clinicopathologic, and survival data of all patients were collected. The intraoperative, postoperative, and long-term oncologic outcomes were compared between the MIS and OR groups. Data were processed using IBM SPSS Statistics software.

Results. There were 55 male (36,9%) and 94 female (63,1%). The mean age was 61±1,8 (range, 27-84) years, and 63,8% of patients were ≤70 years old. Stomach was the most common site (n=109, 73,2%), followed by intestines (n=34, 22,8%), colon and rectum (n=3, 2%) and retroperitoneum (n=3, 2%). The mean tumor size was 5,7±0,7 (range, 0,4-40) cm. Eighty five (57%) patients received MIS and 64 (43%) patients received OR. R0 resection was performed for the 98.7% of the patients. There were only 2 patients that underwent R1 or R2 resection. Subgroup analysis revealed that in the case of gastric GIST ≤5 cm in diameter MIS was significantly superior to the OR group with respect to the operative time, intraoperative blood loss, perioperative blood transfusion, postoperative length of hospital stay and incidence of postoperative complications (p<0,05). In the case of extragastric localization and size of tumor >5 cm MIS had significantly more postoperative complications rate

than OR group ($p=0.005$). The median follow-up time was 34 (range, 4-330) months. There were no significant differences between the MIS and OR groups in the recurrence-free survival ($p=0.09$).

Conclusions. MIS for gastric GISTs ≤ 5 cm in diameter is superior to OR with respect to intraoperative parameters and postoperative outcomes without compromising long-term oncological outcomes.

133

DISTAL RESECTION OF PANCREAS WITH D2 GASTRECTOMY IN PATIENTS WITH LOCALLY ADVANCED STOMACH CANCER

P. Gordiichuk^{1,2}, **K. Koschel**², **M. Gordiichuk**¹, **S. Merencev**²

¹National Medical Academy of Postgraduate Education, Department of Oncology

²Kyiv City Clinical Cancer Centre, Kyiv, Ukraine

Relevance. Surgical treatment of stomach cancer still is the main radical method of treatment. With the development of advanced surgical techniques and modern anesthesiological support, it is possible to perform advanced, combined and combined surgical interventions.

Object. Determine the expediency of distal resection of the pancreas in patients with germination of the tumor in the spleen artery without invasion of the pancreas.

Materials and methods. During the period from 2007 to 2017, in the abdominal department of the Kyiv City Clinical Cancer Center, 927 radical surgical interventions were performed in patients with locally advanced gastric cancer (T2-4N0-3M0), among which: in 526 (56.74%) performed D2 gastrectomy, and 401 (43.26%) - distal subtotal resection of the stomach. The average age of operated patients was 54.3 ± 4.7 years with the male superiority over the female. Neoadjuvant chemotherapy was performed to 193 (20.82%) patients, and 57% received a clinical effect. D2 + gastrectomy was performed in 87 (9.38%) cases, only on the basis of positive results of an express biopsy for a therapeutic purpose. Combined surgical interventions were performed in 406 (43.79%) patients, the intervention in 2 neighboring organs was performed at 37.11%, at 3 and more - 15.32%. Splenectomy was not considered as a combined intervention, if the tumor affected the proximal part of the stomach, large curvature, the back wall of the stomach. After the performed combined interventions, the general direct results are as follows: - Postoperative surgical complications made up - 5.91% with mortality - 3.2%. The overall one-year survival rate was 69.45%, 3rd-year-olds-37.93%, and 5-year-olds-23.15%.

Results. Combined D2 or D2+ gastrectomy with resection of the pancreas deserves special attention, since it has poor long-term results of treatment. For this period, we have performed

168 (18,12%) combined operations with pancreatic resection in different volumes in patients with locally advanced stomach cancer. The results obtained showed that the immediate results had no statistical difference with the above, but separated, especially 5-year survival was statistically worse and was 16.07%, while in the case of sub-total resection of the pancreas - 0%. In our opinion, special attention was paid to the acceptance of surgical tactics in 12 patients with intraoperative invasion of the tumor in the spleen artery, which required its removal from the mouth, but without invasion of the tumor in the pancreas tissue. In 5 patients, the invasion is caused directly by the tumor of the stomach, and in 7 cases, the invasion from the metastatic lymph nodes (groups 9, 11). In 7 patients, the distal resection of the pancreatic hall was performed, as the situation was judged to be a clear violation of trophic tissue in the gland, and in 5 patients it was not performed. The postoperative period was identical. Postoperative complications in the form of left-sided sub-diaphragmatic abscess and reactive pleurisy occurred in 1 patient with resection and in two patients without resection of the gland. Complications starts at 12-18 days of the postoperative period, had a latent course, were eliminated by surgical manipulations, there was no postoperative lethality.

Conclusions. Execution of distal resection of the pancreas during invasion of the tumor in the spleen artery and without germination into the pancreas is discursive and requires further study.

134

PROCTECTOMY IN COMPLEX TREATMENT FOR THE LOWER-AMPULAR RECTAL CANCER

P. Gordiichuk, M. Gordiichuk

National Medical Academy of Postgraduate Education, Department of Oncology. Kyiv City Clinical Cancer Centre, Kyiv, Ukraine

Relevance. Interest in the problem of patients treatment with cancer of the lower ampullary part of the rectum is always increasing, which is due to an increase in morbidity all developed countries of the world, Ukraine is not an exception. The surgical method is a leader in complex treatment for patients with rectal cancer, as this method is determinant in the obtained direct and long-term results.

Object. Justification of the choice of surgical interventions, which will ensure, without violating oncological principles, optimal rehabilitation and will prevent the patient's vital disability.

Materials and methods. During the period from 2007 to 2017, 3678 patients with rectal cancer were operated in the abdominal department of the Kyiv City Clinical Cancer Center, 577 (15.69%) patients had a tumor located in the lower ampullum of the rectum. Patients performed a complex of protocol examination with the mandatory imple-

mentation of SCT and MRI, and if PET-CT will be necessary. Insignificant prevalence of male patients over women was determined, the average age of patients was 56.8 years, the youngest patient was 29 years, the oldest was 84 years. Morphologically 546 (94.63%) patients had a verified adenocarcinoma of varying degrees of differentiation (G1-2 - 68.49%, G3-4 - 31.51%), in 18 (3.12%) patients - squamous cell carcinoma and 6 (1.04%) - melanoma. The distance from the lower pole of the tumor to the toothed line was: 22.87% around 40 mm; in 43.84% from 20 to 40 mm; and 33.29% less than 20 mm. By the stage of the disease: I st - 2.08%; II st - 58.23%; III st -25.65% and IV st. in 14.04% of patients. At the first stage of complex treatment 473 (81.97%) patients were treated with chemoradiotherapy, radiotherapy by classical technique with a single dose of 1.8 to 2.2 Gy to a total of 44.6 - 55.0 Gy with the appointment of fluorouracil or oral capecitabine followed by surgical treatment after 6 weeks.

Results. At the second stage, the following surgical interventions were performed: - low front resection - was performed at localization of the lower pole of the tumor at 40 mm above the dentate line, with total mesorectal excision and anastomosis formation above the dentate line at 10-20 mm; each fifth operation was performed in a combined volume; - abdominal-supraanal resection - performed at the localization of the lower pole between 20-40mm to the toothed line, with the formation of primary or delayed extracorporeal anastomosis, about 45% in the combined or simulant volumes; - Proctectomy was performed in 156 (27,03%) patients, with localization of the tumor closer to 20 mm to the dentate line, in the absence of invasion of the muscle tumor of the diaphragm of the pelvis and of the elements of the external anal sphincter-Abdominalperitoneal resection performed in 69 (11,95 %) of patients in whom on the basis of MRI revealed signs of invasion of the tumor in the pelvis diaphragm and elements of the external anal sphincter. According to the structure of performed surgical interventions in patients with cancer of the lower ampullum part of the rectum, the sphincter-saving operations amounted to 84.04%, in comparison with the previous decade, the number of executed rectal extirpations decreased and the number of executed extracts increased by almost five times made by proctectomy. The technique of its implementation, namely: high separate ligation of the lower erythema artery and veins with apical lymphatic dissection; execution of complete mesorectumectomy without breaking the fascia and with maximum preservation of hypogastric nerves; if necessary, to perform a one-sided or two-side lateral lymph node dissection, a conical resection of a deep portion of the external anal sphincter, pubic-rectus muscle or rectum levator; formation of the primary or delayed circle-anodermal anastomosis. Proctectomy does not in any way violate the oncological principles as evidenced by the immediate and long-term results of sphincter-preserving interventions: - postoperative complications amounted to 13.69%; - post-

operative lethality in 2.94%; - 3-year survival rate - 79,20%; - 3-year-old without recurrence of survival - 72.62%.

Conclusions. Execution of proctectomy does not lead to deterioration of immediate and distant results, but provides social rehabilitation of patients and their quality of life.

135

TRANSCATHETER ARTERIAL CHEMOEMBOLIZATION (TACE) IN PATIENTS WITH HEPATOCELLULAR CARCINOMA (HCC) ON THE WAITING LIST FOR ORTHOTOPIC LIVER TRANSPLANTATION (OLT)

D. Granov, A. Polehin, P. Tarazov, A. Polikarpov
Russian Scientific Center of Radiology and Surgical Technologies, Saint Petersburg, Russia

Aim: to evaluate the results of TACE treatment in HCC patients who are on the waiting list for OLT.

Materials and methods. Between 1998 and 2018, 200 OLT were performed in 183 patients including 15 (8%) with HCC on cirrhosis. Of them, 5 received OLT without neoadjuvant therapy. 12 patients on the waiting list received TACE, and 10 of them were transplanted. 12 patients completed 38 courses of TACE to prevent tumor progression and therefore extend the organ transplant waiting time. We performed superselective TACE of tumor-feeding arteries using 30-60 mg Doxorubicin in 5-10 ml Lipiodol and Gelfoam or drug-eluting beads. The effectiveness of the procedure was assessed by CT. TACE was performed one time in 5, twice in 3, three times in 3, and five times in 2 patients.

Results. The technical success was 100%. There was no complication. Two patients with small multiple supplying arteries additionally received percutaneous radiofrequency ablation (RFA) and laparoscopic resection of extrahepatic metastasis. Partial response to treatment in all 12 patients was seen. OLT was performed in 10 (83%) patients in the period from 1 to 26 mo after TACE. The histological study showed 90-95% tumor necrosis in the removed organs. Six patients (60%) are alive with no relapse and tumor spread in the period from 7 to 128 mo. One patient receives targeted therapy due to lungs metastasis, the period of observation is 29 mo. Three patients died in 11 and 52 mo of HCC progression and in 8 mo of multiple organ failure. Two patients were drop-offed from the waiting list: 1) long-term complete metabolic response of HCC after TACE (68 mo) with exceeding of age limits; 2) refusal to OLT.

Conclusion. TACE slows down the growth of HCC. In most cases, TACE extends the liver transplant waiting time and hence the curability of patients with HCC on cirrhosis.

136

LIVER TRANSPLANT PROGRAM IN RUSSIAN SCIENTIFIC CENTER RADIOLOGY AND SURGICAL TECHNOLOGY, 20-YEAR EXPERIENCE

D. Granov, D. Maystrenko, V. Borovik, A. Polikarpov
Russia

Relevance. Liver transplantation (LT) is still become only curative option of treatment the patients with end-stage liver disease and as well as for selected malignancies.

Aim. To submit the results of liver transplantation for 20 years in Single-Center.

Materials and methods. From June 1998 to June 2018 205 liver transplantations in 191 patients were performed in Russian Scientific Center Radiology and Surgical Technology. The main part of LT was made in cases of post-hepatitis (C-30%, B-10.5%) and undetermined (27%) cirrhosis. About 11% of recipients (n=21) had hepatocellular carcinoma (absolute majority in the outcome of viral hepatitis –81%). To achieve local tumor control at patients in waiting list performed the transarterial chemoembolization and transcuteaneous radiofrequency ablation. In order to prevent repeated bleeding from varicose veins and treatment of refractory ascites was put in a transjugular intrahepatic portosystemic shunt (n=11). The rate of repeated LT amounted to 6.8%.

Results. The cumulative (Caplan-Meier) survival was 91% at 1year, 82 % at 5 year for patient respectively. In five cases developed a significant stenosis of the retrohepatic vena cava, which required stenting. Pathological changes in the portal vein (thromboses, recanalization) of the recipient noted in 13 cases and were removed intraoperatively. Relative insufficiency of arterial blood supply to the liver after revascularization encountered in 22 recipients identified and eliminated intraoperatively (revision of a Fogarty catheter, remove blood clot and heparinization the arterial system, ligation of the gastroduodenal and splenic artery, decompression of the celiac trunk, the reconstruction of the anastomosis). In three cases thrombosis was detected in the postoperative period, which required repeated surgery. Biliary complication registered in 46 cases (24%), late non-anastomotic strictures requiring endobiliary correction and re-transplantation prevailed. Out of 21 recipients with hepatocellular carcinoma (HCC) 8 patient had accidental tumor; 7 alive in terms of 2 to 112 months, one died of sepsis after 2 weeks after LT. Seven patients out of 13 treated with neoadjuvant therapy alive up 17 to 112 months after LT.

Conclusion. The obtained long-term results are comparable with the published data of Russian and foreign centers. A significant factor in the development of the program LT is to overcome the relative shortage of donor organs.

137

EXPERIENCE IN SURGICAL TREATMENT OF GIANT POSTOPERATIVE VENTRAL HERNIAS WITH THE USE OF SEPARATION TECHNIQUES IN COMBINATION WITH ABDOMINOPLASTY

Y. Grebtsov, A. Lugovoy

North-Western state medical University N.A. I. I. Mechnikov, Saint-Petersburg, Russia

Actuality. Modern surgery of ventral hernias should be aimed at the most reliable and most physiological surgery. It is necessary that after the operation the patient receives not only mechanical removal of hernia, restoration of function, but also aesthetic satisfaction. The vast majority of patients, given the presence of a significant hernial defect with "domain loss", there is a fairly pronounced excess of stretched skin and subcutaneous fat, which, according to various authors, are the causes of gray.

The aim. To evaluate the possibility and appropriateness of combinations of simultaneously performing separation of hernioplasty and abdominoplasty.

Materials and methods. For the period from 2015 to 2018, plastic surgery of postoperative ventral hernias using TAR technique and Carbonell was performed in 19 patients in the surgical Department of THE municipal hospital of Pokrovskaya in St. Petersburg. Age from 25 to 73 years. The width of the defect in all patients was more than 10 cm (W3). All patients were measured intraoperatively, as well as every 6 hours after surgery, intra-abdominal pressure by indirect method through the urethral catheter. Pressure of no more than 15 mm Hg was considered sufficient for the final closure of the anterior abdominal wall. In order to prevent the formation of the so-called "dead space" in the subcutaneous fat, in the clinic since 2016, the removal of giant hernias is performed using separation techniques with additional excision of the excess skin flap: in the presence of a vertical scar, vertical abdominoplasty, transverse scar, or its absence – classic abdominoplasty. According to the method of access to the muscular-aponeurotic layer, patients were divided into 2 groups: in the first group of 10 patients (52.6%), classical access was performed - median laparotomy with excision of the old postoperative scar. In the second group of 9 patients (47.4%), depending on the location of the scar, vertical or classical abdominoplasty was performed.

Results. Laparotomy was performed after mobilization of the skin grafts marked before the operation. Further, adhesion in the abdominal cavity was performed, and the components of the abdominal wall were separated: in 11 cases of TAR and in 8 cases of Carbonell plastic by conventional methods. In the first group, 50% (5 patients) in the postoperative period showed the formation of sera, which were successfully treated with a puncture method. In one case, there was a marginal necrosis of the skin with suppuration of the postoperative wound. Successfully treated with the use of VAC system. In the second group, the formation

of seromas was noted in 22% (2 patients) also treated with a puncture method. The average bed day was 9.8 ± 1.7 days. There was no postoperative mortality. During the follow-up period of 4 to 40 months, no recurrence was observed.

Conclusion. TAR technique and Carbonell are effective methods of treatment of giant ventral hernias with "domain loss" and can significantly increase the volume of the abdominal cavity. This makes it possible to produce plastic large hernial defects of the abdominal wall without tension. The addition of these methods with abdominoplasty allows not only to reduce the number of gray and wound complications, but also to obtain a good aesthetic effect.

138

COMPARATIVE ANALYSIS OF ISOLATED AND SIMULTANEOUS LAPAROSCOPIC HEPATIC RESECTIONS

E. Grebyonkin, U. Stanoevich, S. Goncharov, V. Ragimov, R. Kolesnikov, A. Abramov, V. Chkhikvadze, G. Akhaladze
FGBU "Russian Scientific Center of Rentgenoradiology" (Director: acad. V.A. Solodkiy) of the ministry of Healthcare, Russia

Background: 15 - 25% of colorectal cancer patients have synchronous liver metastasis on the moment of the diagnosis. The strategy of simultaneous removal of colorectal cancer and liver metastasis seems to be favorable recently. Development of modern abdominal and hepatopancreatobiliary laparoscopic surgery completely allows to fulfill this objective simultaneously.

Aim: Comparative analysis of simultaneous and isolated laparoscopic liver resections provided in the Russian Scientific center of Rentgenoradiology during 2013-2018yy. **Methods:** Comparative analysis is carried out in 2 groups of patients: 14 patients, after simultaneous laparoscopic procedures for the primary tumor resection and laparoscopic liver resection for metastasis and 15 patients after isolated laparoscopic liver resection for metastatic lesion.

Results: Blood loss in simultaneous procedures group came to 469 ± 176 ml, and in isolated liver resection group - 408 ± 124 ml ($p=0.2$). Surgery duration for simultaneous procedures lasted 296 ± 107 min and 204 ± 82 min ($p=0.01$) isolated resections. Conversion rate in simultaneous resection group came to 14%, and 26% in isolated resection group. This difference is associated with learning curve peculiarities in the beginning of the laparoscopic liver surgery. All liver resections in both groups were carried out in R0 mode. Mortality rate came to 0.

Conclusion: Our study proves principle ability and safety of simultaneous laparoscopic procedures including in cases of difficult localization of primary tumor and liver metastasis.

Key words: laparoscopis liver resection, simultaneous procedures

139

THE SOCIAL SIGNIFICANCE OF TRANSPLANTATION OF PANCREATIC BETA-CELL CULTURES IN DIABETES MELLITUS

A. Grintsov, V. Ahrameev, N. Nesterov, A. Shestopalova
State Educational Institution of Higher Professional Education "M.Gorky Donetsk National Medical University", Donetsk, Ukraine (DNR)

The relevance of the topic and the effectiveness of beta-cell transplantation is confirmed by modern reports from a number of leading institutions in Russia and Belarus. It has been established that in cultures of islet cells of 16-24-week-old human fetuses there should be B cells that are at different stages of morphological and physiological differentiation, and a certain part is formed by cells secreting insulin but not yet reached antigenic maturity and not yet recognized by the recipient's lymphocytes.

Purpose: analysis of the immediate and long-term results of transplantation of pancreatic beta-cell cultures in diabetes mellitus. The material for transplantation was flotation organ-specific cultures of pancreatic tissue of human fetuses by the method of V. Blumkin et al. (1984). Techniques for growing the culture and immunological control were described earlier by O. Slyusarev. and O. Raksha-Slyusareva. All 73 patients (16 to 35 years) are divided into 2 groups. The first group (n=56) who underwent primary transplantation of pancreatic tissue cultures. The second group (n=17) - transplantation 1.5-2.5 years later. In the postoperative period, starting from the first day, complex therapy of diabetes mellitus was carried out. Transplantation of tissue cultures was carried out according to one's own method. Immediate and long-term results were studied within 14 days, 1,3,6,9 months, 1 year, 15 months, 2,3,4,5,10,15 and 20 years. Results from one month to two years were studied in 71 patients. After 3-5 years - in 63, after 10 years - 48, 15 years - 39 and 20 years - 35 patients. Since the first month there has been a positive trend. Improves mood, sleep becomes superficial, muscle pain and hemorrhage in the sclera decrease. Positive dynamics from the third month is on the increase. Sleep is not broken, deep, the mood is more often positive, the character acquires balanced features. The pains do not disturb, the hemorrhage disappears, and stays stable up to 15 - 24 months. The social significance of transplantation of pancreatic cell cultures is confirmed by the studied long-term results in terms of 5-20 years. 35 patients (women - 20, men - 15), who underwent transplantation, noted a transformation from severe form in moderate severity (n=15), from middle to lung - 20. Out of 20 women: 16 married, 12 gave birth one a child, 2 - two healthy children. Mild diabetes mellitus were diagnosed in 2 children aged 10 and 14 years. None after the transplantation consulted for diabetic angiopathy and other complications of diabetes mellitus. Extremely complex technology and control of the preparation of pancreatic tissue cultures require conditions in

specialized laboratories of cellular technologies. In patients with diabetes mellitus at the age of 16 to 35 years, transplantation of pancreatic tissue cells undoubtedly has a persistent clinical effect up to 18-20 months. The identified positive therapeutic effect is extremely important especially for young patients who plan to create a family and have a baby.

140

THE SAFETY AND EFFICACY OF SPLENIC ARTERY LIGATION IN LIVING DONOR LIVER TRANSPLANT RECIPIENTS

Yusuf Gunay¹, Abhinav Humar²

¹*Bulent Ecevit University, General Surgery Department*

²*Starzl Transplant Institute, University of Pittsburgh Medical Center, Pittsburgh, USA*

Introduction. Portal hypertension is one of the main cause of post-transplant graft dysfunction in living donor liver transplant (LDLT). Modification of the portal flow has been suggested to decrease portal pressure. One possible, splenic artery ligation (SAL), has been performed in recipients with elevated portal vein flow. Even though the short term results with SAL in LDLT are excellent, the long term outcomes and postoperative complications have been yet to be determined.

Methods. From August 2010 to August 2016, 87 LDLT were performed at the STI (Starzl Transplant Institute) of the University of Pittsburgh. Two patients had previous splenectomy and were excluded. Of 85 patients, 42 had SAL preformed. We compared results in patients with SAL or without SAL retrospectively after an IRB approved by STI. LDLT was performed using either the right or left lobe.

Results. The study showed that SAL significantly decreased mean portal pressure (19.2±1.7 pre-SAL vs 15±1.8 post-SAL, p=0.0014). Of the 42 patients that had SAL, 7(16.6%) developed splenic infarction as noted on routine CT imaging, but only one developed splenic abscess. No statistically difference was found in postoperative infection, postoperative wound complication and surgical complication rates between patients with/without SAL(p=0.50,p=0.166, p=0.237). Although the mortality rate was lower in patients with SAL, it was not statistically significant(11% vs 28%, p=0.059).

Conclusion. Overall, SAL is safe and effective to decrease portal pressure without increasing risk of morbidity and mortality in recipient undergoing LDLT.

141

INFLUENCE OF DRAIN PLACEMENT ON POSTOPERATIVE PAIN FOLLOWING LAPAROSCOPIC ROUX-EN-Y GASTRIC BYPASS FOR MORBID OBESITY: RANDOMIZED CONTROLLED TRIAL

Ersin Gundogan, Cuneyt Kayaalp, Aydin Aktas, Kutay Saglam, Mufit Sansal, Cihan Gokler, Egemen Cicek, Ufuk Uylas, Fatih Sumer
Turkey

Introduction. There is currently no evidence to support the routine use of abdominal drain following laparoscopic Roux-en-Y gastric bypass (RYGB). Our aim was to investigate the necessity of drain use in laparoscopic RYGB and its effects on postoperative pain.

Materials and Methods. Sixty-six patients were randomly divided into two groups as no-drain and with-drain. Intraoperative (time, blood loss, complications) and postoperative outcomes (morbidity, pain scores, hospital stay) were compared.

Results. Demographics of both groups were comparable. Three patients in the no-drain group required a drain (8.3%). Postoperative pain scores were found higher in the with-drain group. postoperative VAS scores were lower. Per-protocol outcomes of VAS scores for days 1-2-3 for with-drain and no-drain groups were 4.8 ± 1.8 vs. 3.2 ± 2.1 (p=0.002), 3.1 ± 1.7 vs. 2.4 ± 1.6 (p=0.09) and 2.0 ± 1.5 vs. 0.8 ± 1.2 (p=0.001), respectively. There was no difference between the groups in terms of complications and length of hospital stay.

Conclusion. Drain use increased the postoperative pain following laparoscopic RYGB. Drain placement following laparoscopic RYGB should be selective instead of a routine application.

142

POSTOPERATIVE OUTCOMES OF ROBOTIC GASTRECTOMY VERSUS LAPAROSCOPIC GASTRECTOMY USING INTRACORPOREAL BILLROTH RECONSTRUCTION SINCE 2009

Sang-UK Han, Bo Wang, Ho-Jung Shin, Sang-Yong Son, Hoon Hur

Department of surgery, Ajou University School of Medicine, San5, Wonchon-Dong, Yeongtong-Gu, Suwon 443-749, Korea

Background. Even-though robotic gastrectomy (RG) for gastric cancer have demonstrated favorable short-term outcomes, the cost-effectiveness and its advantages over to laparoscopic gastrectomy (LG) are still remaining issues for RG. Also, there are few study about intracorporeal Billrothanas-tomosis between RG and LG and long-term outcomes analysis,

which suggests RG is comparable to LG on gastroduodenostomy, The objective of this study was to assess the long-term outcomes after RG and LG on gastroduodenostomy, find any potential benefit between RG and LG.

Methods. We retrospectively evaluated total 367 patients, each 92 and 275 patients underwent RG or LG, using intracorporeal BillrothI anastomosis method to reconstruct, respectively, at Ajou University Hospital for gastric cancer between January 2009 and December 2016. We analyze the entire cohort and a propensity-score matched cohort.

Results. Compared with LG, RG was associated with longer operation time (167.4±36.4 vs 132.1±37.8, $P < 0.001$), less postoperative hospital stays (6.4±2.0 vs 7.4±4.7, $P = 0.006$), more bile reflux after 5 years ($p = 0.018$) in entire cohort. In propensity-score matched cohort, postoperative hospital stays was similar (6.0 [IQR 6.0, 7.0] vs 6.00 [IQR 5.7, 7.0], $p = 0.258$), but operation time still longer in RG (165.00 [IQR 143.75, 191.25] vs 120.00 [IQR 105.00, 150.00], $p < 0.001$).

Conclusion. Although there are potential benefits of robotic system over laparoscopy, it does not improve surgical outcomes after gastrectomy. Long-term endoscopic finding outcomes in LG are even better than that in RG using entire cohort analysis in current study. More studies are warranted for defining the benefit of RG.

143

IMMUNOMODULATION AFTER RADIOFREQUENCY ABLATION OF PANCREATIC CANCER

Kai-Wen Huang

*Centre of Mini-invasive Interventional Oncology,
National Taiwan University, Taiwan*

Objective: Few patients with pancreatic cancer are cured of their disease, most patients are not eligible for radical surgery due to metastatic disease. Endoscopic ultrasound-guided Radiofrequency ablation (RFA) of pancreatic cancer has been demonstrated to be feasible and safe with a positive impact on survival. The aim was to investigate whether an immune reaction is activated after ablation.

Methods: Peripheral Blood samples of pancreatic cancer-bearing hamster were obtained preoperatively and on post-operative days 1, 3 and 28. Evaluated parameters were: cells CD4+, CD8+ and activated subsets, T-Reg, Monocytes, myeloid Dendritic cells (DC) and cytokines [Interleukin (IL)-6, IL-1b, Tumor-Necrosis Factor (TNF)-alpha, Interferon (IFN)-gamma, Vascular Endothelial Growth Factor (VEGF), chemokine (C-C motif) ligand 5 (CCL-5), Transforming-Growth Factor (TGF)-beta].

Results: CD4+, CD8+ and CD3+ increased from day 3 suggesting the activation of the adaptive response. Immunosuppressive T-Reg cells were decreased despite the possibility that heating might favor their expansion till day 28. Myeloid DCs, that present tumor-associated antigens, increased on day

28. RFA dramatically increased circulating IL-6 and IFN-gamma on day 1 and 3 but this decreased to baseline by day 28, consistent with the supposed anti-tumor effect. RFA did not significantly modulate essential chemokines, such as CCL-5, VEGF, TGF-beta and TNF-alpha, that favour tumour-growth by sustaining cancer angiogenesis and fueling tumor-associated inflammation.

Conclusions: This study provides the evidence of RFA-based immunomodulation in pancreatic cancer. We observed a general activation of adaptive response along with a decrease of immunosuppression. Furthermore, most cells showed prolonged activation some weeks after the procedure, suggesting true immunomodulation rather than a normal inflammatory response.

144

THE POTENTIAL OF COMBINED IMMUNOTHERAPY AND LOCAL TUMOR ABLATION FOR LIVER CANCERS

Kai-Wen Huang

*Centre of Mini-invasive Interventional Oncology,
National Taiwan University, Taiwan*

Hepatocellular carcinoma (HCC) has been recognized as a majority of liver cancer. Surgical resection is a treatment option but is limited by patient characteristics. Local ablation such as radiofrequency ablation (RFA), microwave ablation (MWA) or irreversible electroporation (IRE) has been used to treat HCC that are not amenable to surgical resection. The local ablation of tumors has been expected to work as an immune-stimulating factor for generation of systemic anti-tumor immunity. Recently, tumor immunotherapy has developed as a promising method to inhibit tumor progression through activation of tumor-specific immune response and disruption of immune tolerance. For instance, programmed cell death protein-1 (PD-1)/ programmed cell death ligand 1 (PD-L1) signaling and cytotoxic T lymphocyte antigen 4 (CTLA4) has been associated with T cell exhaustion while blockade of these immune-inhibitory molecules could recover T cell activity, cytokine secretion and cytotoxic capability. We treated mice with a combined therapy of local ablation (RFA, MWA, IRE) and/or anti-PD-1 antibody, the growth of tumors in local ablation group was significantly inhibited compared with the untreated control group ($p < 0.01$), anti-PD-1 treatment administered on day 0, 2, 5 after RFA and MWA slightly retarded the growth of tumors. As for IRE treatment, the synchronous effect is prominent significantly. Interestingly, administration of two different types of immunotherapy augmented growth retardation of RFA/MWA-treated tumors compared with the untreated control group ($p < 0.001$). In this study, we proved ablation therapy with anti-PD-1 treatment would employ antitumor activity through modulating suppressive populations of the immune cells by animal studies.

145**THE SURGICAL MANAGEMENT OF EXTENSIVE HIDRADENITIS SUPPURATIVA IN THE PERIANAL AND GLUTEAL REGION: SINGLE SURGEON'S EXPERIENCE****Amil Huseynov, Veli Vural, Ramazan Eryilmaz***Akdeniz University Hospital, Turkey*

Purpose: Hidradenitis suppurativa (HS) is chronic, recurrent, inflammatory and progresif disease of apocrine glands that affects the axilla, inframammary folds, genitoinguinal regions, perineum, perianal regions, and intergluteal clefts. Effective medical treatment for patients with HS is limited. In our study, we evaluated the surgical results of patients. Five distinct surgical approaches can be considered: (1) local destruction; (2) incision and drainage (I&D); (3) mini-unroofing by punch debridement; (4) standard unroofing (deroofting) to all involved margins; and (5) surgical excision beyond all clinically apparent margins.

Methods: Patients with chronic and extensive Hurley stage III disease, if not amenable to unroofing, may be managed by wide excision of the entire affected area with surgical margins beyond the clinical borders of disease activity. Aggressive medical management must be initiated or continued. Local excision with primary closure has a lower morbidity than wide en bloc excision, but also has a higher recurrence rate. Of note, wound dehiscence is an increased threat in the population with advanced disease. Seventy one (71) HS patients were operated on under local anesthesia within five years. Most patients had inguinogenital/gluteal disease (96%, $P < .001$). Involvement of both the axillary and the inguinogenital/gluteal areas were pronounced in male patients ($P = .014$). Most patients (69.8%) had a disease history of >5 years at the time of presentation.

Results: The mean duration of hospital stay was 2.55 ± 1.0 (range, 1–4) days. At the end of the follow-up period no recurrence was observed in any patient. Twenty-seven percent of patients had postoperative complications, most frequently pain and scarring. The vast majority of patients (60.3%) were satisfied with the cosmetic results.

Conclusion: There are multiple options for wound healing after removal of active areas of hidradenitis suppurativa. Healing by secondary intention has shown good results. It permits residual activity to surface and spontaneous healing. Even large surgical defects may be allowed to heal by secondary intention, without contractures or reduced range of motion. In order to prevent bridging, wound care may require meticulous attention to preserving specific planes of healing. After extensive tissue removal, mesh grafting and vacuum-assisted closure techniques may accelerate wound closure. Extensive surgical excision and grafting has at times been associated with the increased possibility of scarring, scar contraction, and limitation of motion. Closure with local flaps may be appropriate and the results may be acceptable. Significant treatment issues surround the need for general anesthesia and sometimes prolonged hospitalization. In

summary, the surgical treatment of hidradenitis suppurativa should be individualized based on the stage and treatment history of the patient. It ranges from treating individual acute lesions to complete removal of persistent disease. Concurrent medical therapy is essential for HS/AI, with surgical options chosen as indicated. Evidence-based management guidelines have been established for the management of this disease. Wide local excision significantly improves the quality of life of HS patients. Recurrence of disease is common and should not be thought of as a failure of surgical treatment, but rather as a feature of the disease that must be anticipated and managed.

146**THE RELATIONSHIP BETWEEN PREDICTIVE, PROGNOSTIC BIOLOGIC MARKERS AND PATHOLOGIC DIAGNOSIS IN COLORECTAL CANCERS****Amil Huseynov, Muhittin Yaprak***Akdeniz University Hospital, Turkey*

Object: Colorectal cancers (CRC) arise mainly from genetic and epigenetic changes in colon epithelial cells and then turn into adenocarcinoma. Since CRC is largely asymptomatic until the advanced stages of the alarm feature, the application of the screening program is crucial to reduce cancer incidence and mortality rates. Carcinoembryonic antigen (CEA) and Carbohydrate Antigen (CA) 19-9 are tumor markers commonly used in patients with colorectal cancer. The aim of this study is to assess the relationship between ameliorating previous tumor markers and subsequent pathological diagnosis in CRC.

Materials and methods: A total of 108 patients who underwent curative surgery for primary colorectal tumors in Akdeniz University Hospital between 2015 and 2017 were included in the study. For each patient, institutional medical records were checked and demographics, clinical, operative, pathological and follow-up data were collected from a prospectively maintained database. Tumor markers were included in addition to pre-operative routine blood tests.

Results: Only elevated CA 19-9 levels were present in 11.9% of patients without elevated CEA levels, and there was an increase in CEA levels 38.0% and CA levels 19-9 33.3%. Postoperative pathology was interpreted as adenocarcinoma in 88.0% of patients with positive markers before surgery ($p = .013$). In addition, 57% of those with negative markers had adenocarcinoma of the postopathology.

Conclusions: Today, plenty potential biomarker specimens are successfully used in clinical practice (fecal hemoglobin, carcinoembryonic antigen (CEA) and CA19.9, etc.). However, this personalized envy is not a very promising diagnostic target. Although positive biomarkers guiding our study, interpretation of pathology adenocarcinoma next half of patients have negative indicators requires the work done in this area. Therefore, there is necessity for genetic markers

that will make reliable, minimally invasive, sensitive and specific individualized and optimized patient treatment to detect disease at the earliest possible stage.

147

CANCER OF THE STOMACH: THE DYNAMICS OF MORBIDITY, MORTALITY AND THE STATE OF CANCER CARE IN THE REPUBLIC OF NORTH OSSETIA-ALANIA IN 1993-2012.

C. Hutiev, A. Bosieva, S. Hutiev, U. Beslekov, N. Hutieva
North Ossetian state medical Academy, Russia

Stomach cancer (RJ) remains an urgent health problem.

Purpose of the study. Analysis of the state of oncological care for breast cancer and ways of improvement in the Republic of North Ossetia-Alania (RNO-Alania).

Materials and methods. Forms No. 7, 35, 5 (Table C51), Table 2 PH, the history of diseases of the deceased.

Results. For 20 years on treatment there were 2499 patients with RZ in the Republican Oncology Dispensary. Men - 1404 (56.2%) and women - 1095 (34.8%). The average age of patients was 65.1 (65.4 m, 66.2 w.). The standardized indicator (world standard) of the incidence, in general, was 12.1 (m. - 17.8 and w-8.5) per 100 000 population. The incidence of men is 2.1 times greater than that of women. The averaged five-year figures for both sexes in 1993-1997. - 14.5; 1998-2002 - 12.2; 2003-2007 - 11.4; 2008-2012 - 10.4. The indicator of the last 5-year period compared with the first decreased by 1.4 times. In men, these indicators: 21.0, 17.5, 17.1 and 15.5 respectively. Decrease in 1,4 times. In women: 10.3, 8.7, 7.8 and 7.1 decrease by 1.5 times. The overall rate of decline is 37.5 (m. - 33.5 and w.41.7). The average annual rate of decline is 1.9 (m - 1.7 and w. - 2.2). Died 2204 patients from RZ. M. - 1210 (54.9%) and w. - 994 (45.1%). The average age of the deceased is 66.7 (66.2 m, 66.8 w.). The standardized mortality rate in general is 8.1 (m - 10.9 and w. - 5.7) per 100 000 population. Mortality γ is 1.9 times greater than that of women. The averaged five-year figures for both sexes in 1993-1997. - 8.7; 1998-2002 - 8.1; 2003-2007 - 7.6; 2008-2012 6.9. The last 5-year indicator in comparison with the first decreased by 1.2 times. In men, these indicators: 13.8, 11.6, 11.4 and 10.3 respectively. Decrease in 1,3 times. In women: 6,8, 5,8, 5,2 and 4,7 decrease in 1,4 times. The rate of decrease is 28.8 (m - 26.4 and w - 31.8). The average annual rate of decline is 1.8 (m - 1.9 and w. - 2.0). Active detection of RJ on average 1.1%. Morphological verification of the diagnosis 72,4%. Detection of RJ in the I-II stage was 20.8% on average, III - 36.0% and IV stage - 43.2%. The prevalence of RD is 38.6 per 100 000 population on average. Survival of patients 5 years or more on average 42.5%. In the last 5 years compared with the first increased 1.2 times. On average, only 28.2% of patients received special treatment. Surgical 77.4% and combined 22.1%. In the last 5 years,

56.6% of surgical treatment was received, which is 1.5 times lower compared to the first (86.8%), and combined, respectively 43.3 and 13.2, increased 3.3 times. Mortality in the 1st year is on the average 50.6%. The indicator of the last 5-year period compared with the first decreased by 1.2 times.

Conclusion. Incidence of RJ for the observed period decreased. The active detection and detection of RJ I-II stages are low, the percentage of neglect is high. Mortality remains high. Survival is 5 years and lower. It is necessary to increase the literacy of the population, carry out endoscopic screening programs of the population at risk for RJ and precancerous gastroduodenal diseases, and their timely treatment.

148

COLORECTAL CANCER (COLON): MORBIDITY, MORTALITY AND SURVIVAL OF PATIENTS IN THE REPUBLIC OF NORTH OSSETIA-ALANIA IN 1993-2012

C. Hutiev, A. Bosieva, S. Hutiev, U. Beslekov, N. Hutieva
North Ossetian state medical Academy, Russia

Actuality. Stomach cancer (RJ) remains an urgent health problem. The purpose of the study. Analysis of the state of oncological care for breast cancer and ways of improvement in the Republic of North Ossetia-Alania (RNO-Alania).

Materials and methods: Forms No. 7, 35, 5 (Table C51), Table 2 PH, the history of diseases of the deceased.

Results. For 20 years on treatment there were 2499 patients with RZ in the Republican Oncology Dispensary. Men - 1404 (56.2%) and women - 1095 (34.8%). The average age of patients was 65.1 (65.4 m, 66.2 w.). The standardized indicator (world standard) of the incidence, in general, was 12.1 (m. - 17.8 and w-8.5) per 100 000 population. The incidence of men is 2.1 times greater than that of women. The averaged five-year figures for both sexes in 1993-1997. - 14.5; 1998-2002 - 12.2; 2003-2007 - 11.4; 2008-2012 - 10.4. The indicator of the last 5-year period compared with the first decreased by 1.4 times. In men, these indicators: 21.0, 17.5, 17.1 and 15.5 respectively. Decrease in 1,4 times. In women: 10.3, 8.7, 7.8 and 7.1 decrease by 1.5 times. The overall rate of decline is 37.5 (m. - 33.5 and w.41.7). The average annual rate of decline is 1.9 (m - 1.7 and w. - 2.2). Died 2204 patients from RZ. M. - 1210 (54.9%) and w. - 994 (45.1%). The average age of the deceased is 66.7 (66.2 m, 66.8 w.). The standardized mortality rate in general is 8.1 (m - 10.9 and w. - 5.7) per 100 000 population. Mortality γ is 1.9 times greater than that of women. The averaged five-year figures for both sexes in 1993-1997. - 8.7; 1998-2002 - 8.1; 2003-2007 - 7.6; 2008-2012 6.9. The last 5-year indicator in comparison with the first decreased by 1.2 times. In men, these indicators: 13.8, 11.6, 11.4 and 10.3 respectively. Decrease in 1,3 times. In women: 6,8, 5,8, 5,2 and 4,7 decrease in 1,4 times. The rate of decrease is 28.8 (m - 26.4 and w - 31.8). The average annual

rate of decline is 1.8 (m - 1.9 and w. - 2.0). Active detection of RJ on average 1.1%. Morphological verification of the diagnosis 72,4%. Detection of RJ in the I-II stage was 20.8% on average, III - 36.0% and IV stage - 43.2%. The prevalence of RD is 38.6 per 100 000 population on average. Survival of patients 5 years or more on average 42.5%. In the last 5 years compared with the first increased 1.2 times. On average, only 28.2% of patients received special treatment. Surgical 77.4% and combined 22.1%. In the last 5 years, 56.6% of surgical treatment was received, which is 1.5 times lower compared to the first (86.8%), and combined, respectively 43.3 and 13.2, increased 3.3 times. Mortality in the 1st year is on the average 50.6%. The indicator of the last 5-year period compared with the first decreased by 1.2 times.

Conclusion: Incidence of RJ for the observed period decreased. The active detection and detection of RY I-II stages are low, the percentage of neglect is high. Mortality remains high. Survival is 5 years and lower. It is necessary to increase the literacy of the population, carry out endoscopic screening programs of the population at risk for RJ and precancerous gastroduodenal diseases, and their timely treatment.

149

INDOCYANINE GREEN FLUORESCENT IMAGING AS A SIMPLE INTRA-OPERATIVE TOOL DURING LAPAROSCOPIC SURGERY OF POST-TRASPLANT LYMPHOCELE

Giuseppe Ietto¹, Domenico Iovino¹, Gabriele Soldini¹, Elia Zani¹, Cristiano Parise¹, Veronica Raveglia¹, Enrico Ferri¹, Lorenzo Latham¹, Dorotea Confalonieri¹, Giovanni Saredi², Matteo Tozzi¹, Giulio Carcano¹

¹General, Emergency and Transplant Surgery

Department, Ospedale di Circolo e Fondazione Macchi University of Insubria, Varese, Italy

²Urology Department, Ospedale di Circolo e Fondazione Macchi, Varese, Italy

Introduction and background. Lymphoceles are common and well-known complications that occur in 1% to 26% kidney transplant recipients. It is a lymph-filled collection without an epithelial lining, most commonly located in the retroperitoneal space. Lymphoceles are usually small, asymptomatic, but depending on their size and position, may affect transplant function by mass effect directly on the kidney, ureter or transplant vasculature. The therapeutic options include aspiration, drainage and laparoscopic or open surgery to fenestrate the lymphocele into the peritoneal where the lymph will be absorbed. Laparoscopic surgery seems to be the preferred surgical option, associated with a lower overall rate of recurrence of 8% and the lowest rates of surgical complications. However, risks include the need to convert to open surgery, especially in presence of abdominal adhesions and iatrogenic lesions to the urinary tract. The goal of the present study was to demonstrate that intraoperative ICG fluores-

cent imaging is a safe and feasible technique that can be used as a beacon light in laparoscopy to overcome the crucial step to establish the exact location of the lymphocele and to reduce the risk of damage of urinary structures during fenestration of the cyst wall.

Methods: 50 mg of ICG dissolved in 20 mL of saline solution were injected through percutaneous drainage placed into the lymphocele to decompress the transplanted kidneys surrounded by the fluid collection two weeks before laparoscopic lymphocele marsupialization.

Results: During the first exploratory laparoscopy fluorescence was identified on three raised areas in the flank and right iliac fossa proximally to the two renal grafts. These raised areas were the internal side of the lymphocele lobes. The blood vessels visible on the surface of the lymphocele were cauterized and urinary structures presence was excluded. The wall of the lymphocele was gently dissected and after puncturing approximately 300 ml of serous fluid was subsequently aspirated, thereby providing the positive diagnosis of a lymphocele and then a 5-cm breach was made into the cyst wall using the harmonic scalpel Ultracision® (Ethicon US, LLC). Inspection of the cavity revealed smooth interior surfaces. After that a pedicle of the inferior free edge of the omentum in the lymphocele core was interfered with and fixed by two stitches

Conclusions: The treatment of choice of lymphoceles is not definitively established. Laparoscopic surgery seems to be the preferred surgical option for the treatment of primary symptomatic lymphocele after kidney transplantation. Intraoperative ICG fluorescent imaging is a safe and feasible technique that can be used as a beacon light in laparoscopy to overcome the crucial step to establish the exact location of the lymphocele and to reduce the risk of damage of urinary structures during fenestration of the cyst wall.

150

PERITONEAL DIALYSIS RECOVERY AFTER SURGERY IN ADPKD (AUTOSOMAL DOMINANT POLYCYSTIC KIDNEY DISEASE) PATIENTS BEFORE TRANSPLANTATION? YES

Giuseppe Ietto¹, Veronica Raveglia¹, Elia Zani¹, Domenico Iovino¹, Cristiano Parise¹, Gabriele Soldini¹, Nicholas Walter Delfrate¹, Lorenzo Latham¹, Giovanni Saredi², Fabio Benedetti¹, Matteo Tozzi¹, Giulio Carcano¹

¹General, Emergency and Transplant Surgery

Department, Ospedale di Circolo e Fondazione Macchi University of Insubria, Varese, Italy

²Urology Department, Ospedale di Circolo e Fondazione Macchi, Varese, Italy

Autosomal Dominant Polycystic Kidney Disease (ADPKD) is characterized by relentless development and growth of cysts causing progressive kidney enlargement and progressive renal failure (Figure 1). Diuresis and fluid volume control is often

preserved also during the dialytic period. The choice of modality for renal replacement therapy in patients with ADPKD varies, often based on patient choice, physician-related factors, and resource availability. For a long time peritoneal dialysis (PD) was considered as relative contraindication due to the possible limited intraperitoneal space. In recent years, some studies suggested it is a valid option also in patients with ADPKD to be considered as a first line treatment in potentially fit patients. Native kidneys are not routinely removed before transplantation in consideration of the significant morbidity and mortality associated to the procedure. Indications for nephrectomy include recurrent and/or severe infection, symptomatic nephrolithiasis, recurrent and/or severe bleeding, intractable pain, suspicion of renal cancer and space restrictions prior to transplantation (Figure 2). Nephrectomy in PD patients, especially if bilateral, carry a twofold risk: a decline of diuresis volume and a potential permanent damage of peritoneal integrity, both leading to a necessary switch to hemodialysis.

Objective: We performed a retrospective analysis of patient underwent native polycystic kidney nephrectomy in order to state the possibility to recover peritoneal dialysis after surgery.

Materials and Methods: During the last five years (from December 2012 to December 2017) thirty-three patients, all affected by ADPKD related ESRD, underwent nephrectomy in our transplant surgery department. Among them six (20%) underwent peritoneal dialysis as replacement therapy. We performed a retrospective analysis considering the pre and post-surgery residual diuresis, pre and post nephrectomy creatinine value, indications for nephrectomy, data concerning the intervention, and any peri and post-operative complications.

Results: In all cases nephrectomy was performed with laparoscopic transperitoneal surgical technique through subcostal incision. The whole procedure was carried out using the harmonic scalpel in order to limit postsurgical bleeding and lymph spread. After completing nephrectomy the posterior peritoneal flap was always reconstructed to preserve peritoneal cavity avoiding visceral adhesions for future peritoneal dialysis recovery. Only two patients never recovered peritoneal dialysis after the nephrectomy because of peri-operative complications occurred. The remaining four patients started again peritoneal dialysis after a mean time of 35±5 days after surgery with a sufficient diuresis (Table 1). No difficulty in loading dialytic fluid into the peritoneum or to evacuate it after dialysis was reported and purifying efficacy of the treatment was satisfactory.

Conclusion: Our experience suggests monolateral nephrectomy with laparoscopic approach as a safe and feasible procedure also for very large kidneys. Performed before transplant with meticulous surgical technique allows peritoneal preservation avoiding common complication and limiting adherence syndrome in order to rapid peritoneal dialysis recovery.

151

THE USE OF CRYODESTRUCTION IN METASTASES OF COLORECTAL CANCER IN THE LIVER

D. Ionkin, O. Zhavoronkova, Yu. Stepanova, N. Karelskaya, A. Chzhao

A.V. Vishnevsky National Medical Research Center of Surgery, Moscow, Russia

Relevance. Up to 80% of patients with metastases to the liver are not subject to radical surgical treatment. It is this category of patients that shows the application of local thermal destruction methods.

The aim: improving the life quality, and increase life expectancy (in combination of chemotherapeutic treatment) in patients with metastatic of colorectal cancer in the liver (MCRC).

Materials and methods. Cryodestruction have been performed in 20 patients with MCRC. There were 9 women, 11 men. The median age was 56.4 + 3 years. "CRYO-MT" and "CRYO-01" were used, as well as porous-sponge applicators made of titanium nickelide. RFA in a combination of cryodestruction was performed in 3 patients, Cryo + liver resection - in 7, a combination of liver resection + RFA + Cryo - in 5 patients. The target temperature: -186°C. Exposure time: 3-5 min. All patients subsequently underwent adjuvant chemotherapy, supplemented with regional chemoembolization in 12 cases.

Results. In the postoperative period intra-abdominal bleeding - 1(5%) case; renal and hepatic failure led to the development of the syndrome of multiple organ failure and then to death on the 47th day after the intervention (liver resection+ Cryo+RFA) -1(5%), biliary fistula - 1(5.30%), ascites - 6(30%), hydrothorax - 4(20%), right lower lobe pneumonia - 2(10%). The survival rate (Kaplan-Meier): 6 months-95%, 12-72%, 24-60%, 36-28%.

Conclusion. Cryodestruction in case of MCRC unresectable patients is greatly improves the quality of life of patients, primarily by reducing pain. Cryodestruction in connection with adjuvant chemotherapy leads improve in survival rates.

152

SARCOPENIA ADVERSELY IMPACTED SHORT-TERM OUTCOMES FOLLOWING GASTROINTESTINAL SURGERY BUT WAS NOT ASSOCIATED WITH POSTOPERATIVE INFECTIOUS COMPLICATIONS

Masashi Ishikawa, Tomoe Mishima, Yoshihiko Tashiro, Kazuo Matsuyama, Takayuki Miyauchi, Taketo Oshio

Department of Surgery, Shikoku Central Hospital, Japan

The aim. Recent studies have shown that sarcopenia is associated with adverse short-term outcomes after certain

procedures. However, most of these studies did not evaluate whether sarcopenia was predictive of postoperative infectious complications after surgery. The aim of this study was to investigate the predictive effect of sarcopenia on postoperative infectious complications of aged gastrointestinal cancer patients who underwent gastrointestinal resection.

Materials and methods. Skeletal muscle mass was evaluated in 41 patients who underwent gastric (n=13) or colorectal (n=28) resection in our hospital from January 2016 to March 2017. A multifrequency bioelectrical impedance analysis (In Body 10: Biospace, Tokyo, Japan) was used to assess skeletal muscle mass just before surgery. The lowest quartiles defined as sarcopenia in men and women were 7.0 Kg/m² and 5.7 kg/m², respectively. In addition, preoperative immunonutritional parameters including a lymphocyte blastoid transformation test induced by concanavalin A (Con A), prealbumin and Geriatric Nutritional Risk Index (GNRI) were evaluated in all patients. The impact of sarcopenia on postoperative complications and several other parameters was assessed. Univariate and multivariate analyses evaluating the risk factors for postoperative complications grade II or above according to the Clavien-Dindo classification were conducted.

Results. Of 41 total patients enrolled in the study, 21 patients (9 men and 12 women) were diagnosed as having sarcopenia. Significant differences in preoperative serum prealbumin and GNRI (P<0.01) were detected between sarcopenia and control groups, but no significant correlation was present in preoperative Con A levels. Postoperative complications occurred in 10 patients, including 8 with sarcopenia and 2 without sarcopenia (P=0.03). Multivariate analysis demonstrated that sarcopenia was a strong independent risk factor for postoperative complications (P=0.03, odds ratio 2.89). However, there was no significant difference in postoperative infectious complications, including SSI, between the two groups (n=3 in sarcopenia group and n=2 in control group, respectively).

Conclusion. Sarcopenia was identified as an independent risk factor for postoperative complications of elderly patients with gastrointestinal cancers. However, sarcopenia was not significantly correlated with postoperative infectious complications.

Introduction. Tumors of papilla Vateri constitute 3-7% of hepatopancreatobiliary tumors. Most of them 92-95% are adenomas with high and low grade dysplasia which can be removed endoscopically. For pseudotumors: hyperplastic and fibrous inflammatory polyps of papilla Vateri, which constitute 23-31% of papilla Vateri. The aim of study is to evaluate the results of treatment and observation patients with diagnosed adenomas, hyperplastic and fibrous inflammatory lesions of papilla Vateri

Materials and methods. First study was performed in 2006-8, included laboratory tests, duodenoscopy with biopsy, histology and DNA-cytometry. There have been 247 patients (3 cancers, 18 adenomas, 24 hyperplastic, 22 fibrous inflammatory pseudopolyps and 181 chronic papillitis). 67 patients were able to observe during 10 years prospective study period with illness history analysis, duodenoscopy control in 1-5 year interval and 1-7 year interval of endoscopic biopsy. Age of patients: 32-78, male/female - 12/35.

Results. 3 patients with cancer of papilla Vateri have not pass 5 year period. 8 patients from 18 with adenomas have gone endoscopic surgical treatment and showed positive result without relapse of tumors with US-endoscopy and morphological control. There have been registered 4 cases of acute pancreatitis, treated conservatively in surgical unit. In 3 cases of adenomas with high grade dysplasia have not been found negative dynamic in 10 years, 7 cases considered be unknown due to lost compliance. 15 patients with fibrous inflammatory lesions of papilla Vateri have had bile gallstones and cholecystectomy was performed in 11 cases. There have been symptoms of chronic pancreatitis in 13 cases, in 7 cases papillotomy with endoscopic lithoextraction have been performed in different time. 9 patients with hyperplastic pseudopolyps showed low symptomatic in 10 years and repeated biopsy did not evaluate negative dynamics. 32 patients with chronic papillitis were observed in different intervals in 10 years with multiply symptoms and comorbidity. Endoscopical examinations of them have evaluated 6 new cases of hyperplastic pseudopolyps and 4 cases fibrous lesions, in 10 cases visual changes have been reduced to normal and biopsies were refused.

Conclusions. 1. Tumors and pseudotumors of papilla Vateri constitute up to 27% of pathological changes of that organ. True tumors: cancer and adenomas constitute 1,2% and 7,3%. 2. Adenomas of papilla Vateri can be treated endoscopically with positive 10 year result. 3. Hyperplastic and fibrous inflammatory polyps, as well as chronic papillitis need more detail dynamic observation with modern US-endoscopy and manometry diagnostic, evaluation functional and structural disorders for further tactic of treatment.

153

DYNAMIC 10 YEARS STUDY OF TUMORS, PSEUDOTUMORS AND CHRONIC INFLAMMATORY DISEASES OF PAPANILLA VATERI

M. Ivantsova¹, L. Grinberg², N. Sorokina²

¹Medical center of plastic surgery, ²Ural medical university, Laboratory of pathomorphology, Yekaterinburg, Russia

154**COMPARATIVE ANALYSIS OF MINIMALLY INVASIVE AND OPEN SURGICAL TECHNIQUES OF CHRONIC BILIARY PANCREATITIS****S. Ivanusa, M. Lazutkin, D. Shershen, A. Eliseev, D. Boyarinov***S.M. Kirov Military Medical Academy, St. Petersburg, Russia*

The study is based on the analysis of 516 patients with chronic biliary pancreatitis in the General surgery clinic of S.M. Kirov Military Medical Academy in the 2005 – 2015. 2 groups of patients were created for comparative analysis of surgical treatment. The control group included 259 (62,7%) patients in the 2005 – 2010 which were given traditional and laparoscopic technologies. The main group consisted of 154 (37,3%) patients who were treated in 2011 – 2015. Surgical treatment was performed in 413 (80.0%) patients. In order to determine the effectiveness of surgical treatment the time spent in hospital and the frequency of postoperative complications were evaluated. The quality of life (QOL) was tested in patients to study the long-term results of treatment (from 2 to 10 years). In 356 (69.0%) observations general EQ-5D questionnaire and specialized questionnaire by S. F. Bagnenko were used. The average duration of treatment in patients with minimally invasive treatment was the shortest and amounted to 10.0 [7.0÷16.0] days. The duration of treatment with open interventions and combination of different techniques were comparable and amounted to 18.0 [13.0÷24.0] and 19.0 [9.0÷24.0] days, respectively. Thus, in chronic biliary pancreatitis, the minimally invasive technologies (sphincterotomy, stenting of common bile duct and pancreatic duct, laparoscopic interventions) leads to reducing the duration of inpatient treatment. Development of postoperative complications was noted in 105 (25.4%) patients. There was a significant prevalence of II and IIIA degree complications (by Clavien-Dindo) in patients who had undergone minimally invasive surgery. The results of the QOL study revealed the unequal impact of various factors. The decrease in the patients QOL with chronic biliary pancreatitis before surgery is mainly due to pain syndrome. Six months after surgery, there was a gradual recovery of working capacity and physical activity against the background of pain syndrome reduction. In the long term perspective the greatest impact on patients QOL was of dyspeptic disorders and reduced physical capacity, with the pain syndrome's less importance. The use of minimally invasive technologies leads to more rapid restoring of QOL indicators of patients in the postoperative period. In the long-term period the results of using minimally invasive techniques and open surgical interventions did not have significant differences and were close to the normal values.

155**EFFICIENCY OF EMBOLIZATION AND FOAM SCLEROBOLITATION OF LEFT GASTRIC VEIN IN TRANSJUGULAR INTRAHEPATIC PORTOSYSTEMIC SHUNT IN TREATMENT AND PREVENTION OF GASTROESOPHAGEAL BLEEDING****S. Ivanusa, S. Alentyev, M. Lazutkin, A. Muzharovskiy, I. Onnycev***Military Medical Academy S.M. Kirov, Department of General Surgery, Saint-Petersburg, Russia*

The urgency is determined by the search for an effective method for the prevention of gastroesophageal bleeding in patients after portocaval shunting. Purpose is to assess the effectiveness of endovascular foam sclerotherapy of the left gastric vein (LGV) in transjugular intrahepatic portosystemic shunting (TIPS).

Materials and methods. The study included 25 patients with portal hypertension syndrome on the background of cirrhosis of the liver, who had TIPS with occlusion of LGV. Intraoperatively, hepatofugal blood flow for LGV was detected in all observations with established esophageal bleeding (n = 25). Embolization of the vein was performed using spirals with synthetic nap. In 18 cases, the effect of occlusion was enhanced by foam sclerobliteration of 1 % polydocanol solution.

Results. Intrahepatic shunting in combination with embolization of LGV (n = 25), in all cases, led to regression of the varicose veins of the esophagus to 0-II st. There was no recurrence of bleeding. However, the combination of embolization with foam sclerobliteration of LGV and short veins of the stomach in all cases (n = 18) resulted in a more pronounced and rapid regression of the degree of esophageal varices (up to 0-I st., for 1–3 days) than without the introduction of polydocanol foam (up to 0-II st., for 6–9 days).

Conclusions. Intraoperative embolization by spirals with PTFE pile and transcatheter foam sclerobliteration of the left gastric and short veins of the stomach allows reliable and in a shorter time to achieve regression of the degree of VRF and stomach.

156**MINIMALLY INVASIVE METHODS OF SURGICAL CORRECTION OF RESISTANT ASCITES IN PATIENTS WITH DECOMPENSATED LIVER CIRRHOSIS****S. Ivanusa, I. Onnicev, S. Alentiev, A. Yankovsky, A. Muzharovskiy***Military Medical Academy S.M. Kirov, Department of General Surgery, Saint-Petersburg, Russia*

Introduction. Ascites-one of the most common complications of liver cirrhosis, occurring in more than 50% of

patients. In 20% cases, ascites become resistant. More than 50% of them die within a year. Treatment of diuretic-resistant ascites against the background of portal hypertension remains one of the topical and complex issues of modern surgical Hepatology.

Purpose. To improve the results of surgical treatment of resistant ascites through the introduction and optimal use of minimally invasive interventions.

Materials and methods. The analysis of the results of stage surgical treatment of 37 cases with resistant ascites was carried out. Among them, 23 (62.1%) were men and 14 (37.9%) were women. The mean age was 46.4 ± 12.9 years. Esophageal varicose veins III-IV degree established in 29 (78.3%) patients. According to the Child – Pugh classification, all patients were assigned to class "C".

Results. The initial stage of treatment of 37 cases with intense ascites was large volume paracentesis and correction of protein losses by reinfusion of extracorporeally modified ascitic fluid. On the second day of hospitalization, after the relief of tense ascites, with the goal of preventing esophageal-gastric bleeding performed endoscopic ligation of the veins of the esophagus (n=29). In 26 cases with resistant ascites and severe thrombocytopenia, combined treatment was performed, including splenic artery embolization in combination with reinfusion of the modified fluid. Good results of treatment in the early period were achieved in 16 (61.5 %) cases. The presence of ascites (1-2 degrees) on the background of taking diuretics persisted in 10 (38.4%) cases. Relapse of ascites was observed in the period from 3 to 8 months (average 168 ± 25 days) after surgery. After the stabilization of the patients, the question of radical correction of portal hypertension was considered. TIPS operation was performed in 10 patients. The main indication for the formation of TIPS was diuretic-resistant ascites and a high risk of esophageal-gastric bleeding, despite preventive endoscopic ligation and reinfusion of ascitic fluid. In the postoperative period there was a clear regression of esophageal varicose veins. Esophageal bleeding caused by stenosis and stent thrombosis occurred after 6 months and 1 year in 2 patients. The effectiveness of TIPS for diuretic-resistant ascites at the time of discharge from hospital was 80 %, after three months – 70 %, a year – 60%, 2 years – 30%. Four cases had contraindications to portocaval shunting. They performed laparoscopic devascularization of the esophagus and stomach with ligation of the splenic artery. The final stage performed a fragmentary deperitonization abdominal wall. All patients with the aim of eradication of esophageal varicose veins underwent a ligation session during the operation. The postoperative period in all patients was safe and amounted to $10 \pm 2,3$ days. The maximum follow-up period after surgery was 3 years. No episodes of recurrent bleeding were noted. Signs of ascites 1-2 degree on the background of diuretics persisted in all patients. Progression of ascites was observed in one case on the background of portal vein thrombosis.

Conclusion. The results of treatment of patients with liver cirrhosis and resistant ascites showed that surgical interventions should be performed in a delayed or planned manner

after the patient's preparation. The absence of early post-operative deaths after surgery in this group of the patients may indicate the effectiveness of a step-differentiated, minimally invasive approach.

157

PATHOGENETICALLY BASED TREATMENT OF RESISTANT ASCITES IN LIVER CIRRHOSIS

S. Ivanusa, I. Onnicev, A. Sokolov, A. Khokhlov, A. Yankovsky

Military Medical Academy S.M. Kirov, Department of General Surgery, Saint-Petersburg, Russia

Introduction. The course of liver cirrhosis is complicated by edema-ascetic syndrome in 28-50% of cases. In 10-20% of cases with liver cirrhosis and ascites there is resistance to conservative therapy. In 50-86% of patients, life expectancy is no more than a year, 20-50% live up to 2 years.

Purpose. To evaluate the effectiveness of the application of reinfusion of ascitic fluid at the stage of preoperative preparation and as an independent treatment using a new method of extracorporeal treatment.

Materials and methods. Depending on the method of treatment, 3 groups of patients were formed. The first group (n=34) consisted of patients who underwent reinfusion of ascitic fluid treated with a FILTRYZER series BK-F. The second group (n=22) – were patients who underwent large volume paracentesis (LVP) with albuminotherapy – 10 g per 1 liter of the removed fluid. The third group (n=18) patients underwent reinfusion of ascitic fluid processed by the dialyzer DIP – 02 – 02 and subsequent cryosorption and sorption on the sorbent "Aktilen". All patients underwent cytological and biochemical study of ascitic fluid. The dynamics of changes in biochemical parameters of blood, daily diuresis, body weight, abdominal circumference, glomerular filtration rate, daily excretion of sodium in the urine was evaluated. According to computed tomography, ultrasound, gastroscopy, the character of ascites, varicose veins of the esophagus, stomach, size and structure of the spleen after treatment was evaluated.

Results. The average duration of hospitalization in the first group was 14.5 ± 8.6 days, of the second- 13.5 ± 7.5 days, of the third- 34 ± 4.1 days. Patients in the first group during the period of hospitalization have been performed from 2 to 5 sessions of reinfusion, patients in the third group – from 1 to 2 sessions. The time of treatment of ascitic fluid from patients in the first group was 185 ± 14 min, in the third group-more than 2 days. Compared to the second group, the daily diuresis from the patients in the first and third increased 2,7 fold, blood protein increased 1,9 fold, albumin increased 1,7 fold, the daily excretion of sodium in the urine increased 1,6 fold, the glomerular filtration rate increased 2 fold. The average duration of relapse - free period of ascites

in the first group was 6.3 months., in the second group -1.3 months., in the third group-4.8 months. The incidence of complications of reinfusion in the first group was 25 %, in the second group was 62.5 %.

Conclusion. The reinfusion of ascitic fluid shows a higher treatment efficiency compared to the traditional correction of protein losses in the background of the LVP. The use of reinfusion with a new method of extracorporeal treatment of ascitic fluid can reduce the time of preparation and procedure, increase the number of sessions during the period of hospitalization, improve the tolerability of the procedure.

158

THE MINIMALLY INVASIVE METHOD IN THE TREATMENT OF PATIENTS WITH PURULENT-NECROTIC COMPLICATIONS OF THE DIABETIC FOOT SYNDROME

S. Ivanusa, P. Zubarev, B. Risman, A. Yanishevskiy

Russia

One of the most serious complications of diabetes is diabetic foot syndrome. Despite the achievements of modern conservative treatment, the emergence of high-tech diagnostic methods, highly effective drugs, the number of patients with purulent- necrotic complications of the diabetic foot syndrome is growing every year. Patients with this disease suffer from the proliferation of the infectious process that is the main cause of non-traumatic amputations of the lower limbs. Unsatisfactory results of treatment, introduction of new minimally invasive surgical techniques for the treatment of purulent-necrotic complications in patients with diabetic foot syndrome.

Purpose: To assess the results of surgical treatment purulent-necrotic complications of the diabetic foot syndrome.

Materials and methods: The results of 10 patients in treatment the General Surgery Clinic of the Military Medical Academy with purulent-necrotic imbalances of the diabetic foot syndrome - with a deep phlegmon of the plantar surface of the foot, from 2015 to 2017, were analyzed according to the form of the diabetic foot syndrome, patients suffered mainly neuropathic (70%), rarely neuro-ischemic (30%), patients with ischemic form did not enter the study. According to the degree of severity of the pathological process in the foot region, patients are distributed in degrees: grade III in 70%; IV degree - in 30% (F.V. Wagner's classification, 1979). Patients with I-II, and also V degree were not included in the study. In all cases the purulent-necrotic process was localized in deep cellular spaces. To clarify the location of the purulent-necrotic process, magnetic resonance imaging of the feet was performed at the first day after admission. As part of the surgical treatment, a well-developed, anatomically valid, minimally invasive method for the treatment of purulent-necrotic complications of the diabetic foot syndrome was used in all patients.

This included the opening, sanitation and drainage of deep phlegmon of the plantar surface of the foot, stage ultrasound treatment of wounds with endovideoscopic sanitation, flow-washing drainage.

Results: 10 operations were performed in total - autopsy, sanitation and drainage of deep phlegmon of the foot's plantar surface with anatomically justified mini-invasive access application. Fever's cupping was observed on average on the 3 day. The pain syndrome according to the Visual Analogue Scale reached 6 points on the 3-4 day. Normalization of the level of leukocytes in the blood came on the 4th day. Reduction of blood glucose level to the reference values occurred on 3-4 days. The terms of hospitalization averaged 22.5±13.2 days.

Conclusions: The use of the method of minimally invasive treatment of purulent-necrotic complications of the diabetic foot syndrome, to be sanitized in a short time, to stop the pain syndrome and restore the foot's ability to resist.

159

TRANSJUGULAR INTRAHEPATIC PORTOSYSTEMIC SHUNT IN TREATMENT AND PREVENTION OF GASTROESOPHAGEAL BLEEDING IN PATIENTS WITH PORTAL HYPERTENSION SYNDROME

S. Ivanusa, S. Alentyev, M. Lazutkin, A. Muzharovskiy, I. Onnycev

Military Medical Academy S.M. Kirov,

Department of General Surgery, Saint-Petersburg, Russia

The urgency is determined by the discrepancy of the issue of choosing the diameter of the stent and the presence of a coating on it in the transjugular intrahepatic portosystemic shunting (TIPS).

Purpose. Compare the results of the use of holometallic stents and stent grafts with a diameter of 8-10 mm in TIPS. **Materials and methods.** The study included 25 patients with portal hypertension syndrome on the background of liver cirrhosis, which was performed by TIPS. In 13 patients, uncovered stents were used for bypass surgery. As early as 12 observations, TIPS was performed with the installation of stent grafts. In 11 cases, 8 mm prostheses were used for TIPS. Implantation of stents with a diameter of 10 mm was performed by 14 patients.

Results. In the early postoperative period, no complications were detected. After performing the TIPS procedure, all patients experienced a decrease in the portosystemic pressure gradient from 40–24 mm Hg. up to 20–7 mm Hg. (in the late postoperative period). However, with the use of 10 mm prostheses in 12 out of 14 cases, a total discharge of portal blood through the shunt was noted. With the use of stents 8 mm in diameter, in all observations of this group (n = 11), according to control portography hepatopetal blood flow in the portal vein branches and partial preservation of

portal perfusion of the liver were noted. During the entire period of dynamic monitoring (2-72 months), patients with a stent-graft had no thrombosis and no occlusion of the shunt. Out of 13 patients with established holometallic stents, occlusion of the shunt developed in 3 cases, which required its recanalization, and in 4 cases stenosis for resolving it was performed by balloon dilatation (n = 4) and stent-to-stent (n = 1).

Conclusions. TIPS is effective and minimally invasive technique for the treatment and prevention of hemorrhage from the varicose veins of esophagus and stomach. In this case, stents with a diameter of 8 mm can provide adequate decompression of the portal system, keeping hepatopetal blood flow in the branches of the portal vein, thereby reducing the risk of hepatic insufficiency. The absence of thromboses, occlusions and stenoses confirms the advantage of stent grafts over holometallic stents.

160

CLINICOPATHOLOGICAL FACTORS ASSOCIATED WITH OUTCOMES OF ENDOSCOPIC SUBMUCOSAL DISSECTION FOR COLORECTAL LATERALLY SPREADING TUMORS

Young-Hoon Jeong, Ik-Joo Chung, Hyun-Soo Kim, Young-Eun Joo

Department of Internal Medicine, Chonnam National University Medical School, Gwangju, Korea

Object: Colorectal laterally spreading tumor (LST) is a large and superficial flat elevated neoplasms with diameters of at least 10 mm. Endoscopic submucosal dissection (ESD) is an advanced technique to treat precancerous and early colorectal neoplasms by facilitating en bloc resection irrespective of tumor size. This study aimed to investigate the factors associated with clinical outcomes of ESD for colorectal LSTs. **Materials and Methods:** A total of 210 patients with colorectal LSTs who underwent ESD was enrolled. Clinical outcomes of enrolled patients were analysed by reviewing their medical records retrospectively.

Results: The nodular mixed (NM) and pseudo-elevated (PD) were most commonly found in the distal colon, compared to than homogenous (HG) and flat elevated (FE) subtypes. The frequency of cancerous pit pattern (Vi/Vn) was significantly higher in PD than that of FE subtype. The incidence of adenocarcinoma in the PD and NM subtypes are significantly higher than that of the other two subtypes of LST. The mean procedure time was 60.0 ± 55.6 min. The en bloc resection and R0 resection rates were 89.0 and 85.7%, respectively. The bleeding and perforation rates after ESD were 5.2% and 1.9%, respectively. The procedure time was significantly longer in PD than in FE subtypes. The en bloc resection rate

was significantly higher in NM than in HG subtypes. However, no statistically significant differences were found in mean procedure time, en bloc resection rate, R0 resection rate, bleeding rate, or perforation rate between LST-granular and LST-non-granular types. **Conclusions:** These results indicate that ESD is acceptable for treating colorectal LSTs with regard to en bloc resection, curative resection, and risk of complications, and careful consideration is required for complete resection in the PD and NM subtypes because of their higher malignant potential.

Table 1 - Baseline characteristics of the patients with colorectal laterally spreading tumors undergoing endoscopic submucosal dissection

Factors		n=210 (%)
Patient-related factors		
Age (years)	Mean±SD (range)	65.3±10.1 (40.0-87.0)
Gender	Male/Female	125/85 (59.5/40.5)
Smoking status	Non-smoker/current or ex-smoker	157/53 (74.8/25.2)
Alcohol drinking	No/Yes	148/62 (70.5/29.5)
BMI (kg/m ²)	Mean±SD (range)	24.0±2.7 (16.9-32.5)
Comorbidity	No/Yes	86/124 (41.0/59.0)
	Hypertension	No/Yes 131/79
	(62.4/37.6)	
	Diabetes mellitus	No/Yes 170/40(81.0/19.0)
Aspirin or NSAIDs	No/Yes	171/39 (81.4/18.6)
Lesion-related factors		
Size (mm)	Mean±SD (range)	33.3 ±13.3 (10.0-130.0)
Location	Distal colon	130 (61.9)
	Rectosigmoid colon	118 (56.2)
	Descending colon	12 (5.7)
	Proximal colon	80 (38.1)
	Transverse colon	11 (5.2)
	Ascending colon, Cecum	69 (32.9)
Endoscopic morphology	LST-G type	154 (73.3)
	HG	31 (14.8)
	NM	123 (58.6)
	LST-NG type	56 (26.7)
	FE	37 (17.6)
	PD	19 (9.0)
Pit pattern (n=176)	Non-neoplastic (Type I/II)	20/8 (11.4/4.5)
	Adenomatous (Type IIIs/III/IV)	24/75/9 (13.6/42.6/5.1)
	Cancerous (Type Vi/Vn)	25/15 (14.2/8.5)
Histologic grade	Low grade dysplasia	90 (42.9)
	High grade dysplasia	49 (23.3)
	Adenocarcinoma	71 (33.8)
	Mucosal	51 (71.8)
	SM 1	15 (21.1)
	SM 2	5 (7.0)
Procedure-related factors		
Procedure time (min)	Mean±SD (range)	60.0±55.6 (1.0-360.0)
Resection method	En bloc resection	187 (89.0)
	Piecemeal resection	23 (11.0)
Complication	Bleeding	11 (5.2)
	Perforation	4 (1.9)
Margin	Negative	180 (85.7)
	Positive	20 (9.5)
	Undetermined	10 (4.8)

SD, standard deviation; BMI, body mass index; NSAIDs, nonsteroidal anti-inflammatory drugs; LST-G, laterally spreading tumor-granular; LST-NG, laterally spreading tumor-non-granular; HG, homogenous; NM, nodular mixed; FE, flat elevated; PD, pseudo-depressed; SM, submucosa

Table 2 - Comparison of the patient-related factors of the laterally spreading tumor subtypes according to endoscopic appearance

	Granular type			Non-granular type			P value
	HG (n=31)	NM (n=123)	P1	FE (n=37)	PD (n=19)	P2	
Mean age (range)	66.5 (45-81)	63.9 (40-85)	0.208	68.0 (42-82)	67.3 (51-87)	0.815	0.034
Male	16 (51.6)	74 (60.2)	0.388	26 (70.3)	9 (47.4)	0.094	0.596
Smoking (yes)	8 (25.8)	32 (26.0)	0.981	11 (29.7)	2 (10.5)	0.107	0.684
Alcohol (yes)	12 (38.7)	35 (28.5)	0.268	14 (37.8)	1 (5.3)	0.009	0.600
Mean BMI (range)	23.5 (18.9-28.2)	23.8 (16.9-30.8)	0.594	24.9 (19.0-32.5)	23.9 (18.7-27.7)	0.247	0.055
Comorbidity	17 (54.8)	70 (56.9)	0.835	25 (67.6)	12 (63.2)	0.741	0.212
Hypertension	11 (35.5)	42 (34.1)	0.889	20 (54.1)	6 (31.6)	0.110	0.112
Diabetes mellitus	4 (12.9)	26 (21.1)	0.301	8 (21.6)	2 (10.5)	0.305	0.791
Aspirin or NSAIDs	6 (19.4)	20 (16.3)	0.681	9 (24.3)	4 (21.1)	0.784	0.297

HG, homogenous; NM, nodular mixed; FE, flat elevated; PD, pseudo-depressed; BMI, body mass index, NSAIDs

Table 3 - Comparison of the lesion-related factors of the laterally spreading tumor subtypes according to endoscopic appearance

	Granular type			Non-granular type			P value
	HG (n=31)	NM (n=123)	P1	FE (n=37)	PD (n=19)	P2	
Mean size (range)	29.6 (15-60)	34.2(10-130)	0.094	31.3 (11-60)	37.2 (20-70)	0.077	0.993
Location			0.021			0.029	0.592
Distal	14 (45.2)	83 (67.5)		18 (48.6)	15 (78.9)		
Proximal	17 (54.8)	40 (32.5)		19 (51.4)	4 (21.1)		
Pit pattern (n=176)			0.283			0.000	0.254
I/II	5 (20.0)	16 (15.5)		6 (20.7)	1 (5.3)		
III/III/IV	18 (72.0)	64 (62.1)		22 (75.9)	4 (21.1)		
Vi/Vn	2 (8.0)	23 (22.3)		1 (3.4)	14 (73.7)		
Histologic grade			0.048			0.015	0.916
Low grade dysplasia	19 (61.3)	46 (37.4)		21 (56.8)	4 (21.1)		
High grade dysplasia	6 (19.4)	31 (25.2)		8 (21.6)	4 (21.1)		
Adenocarcinoma	6 (19.4)	46 (37.4)		8 (21.6)	11 (57.9)		

HG, homogenous; NM, nodular mixed; FE, flat elevated; PD, pseudo-depressed

Table 4. Comparison of the procedure-related factors of the laterally spreading tumor subtypes according to endoscopic appearance

	Granular type			Non-granular type			P value
	HG (n=31)	NM (n=123)	P1	FE (n=37)	PD (n=19)	P2	
Mean procedure time (range)	74.2 (12-330)	59.3 (3-360)	0.213	42.2 (1-185)	75.4 (20-200)	0.006	0.310
En bloc resection	24 (77.4)	113 (91.9)	0.047	32 (86.5)	18 (94.7)	0.652	0.947
Bleeding	1 (3.2)	7 (5.7)	1.000	3 (8.1)	0 (0.0)	0.544	1.000
Perforation	1 (3.2)	0 (0.0)	0.201	2 (5.4)	1 (5.3)	1.000	0.059
R0 resection	25 (80.6)	105 (85.4)	0.501	32 (86.5)	18 (94.7)	0.649	0.792

HG, homogenous; NM, nodular mixed; FE, flat elevated; PD, pseudo-depressed.

161**COMPARISON OF ADENOMA DETECTION BY POLYPECTOMY DURING BOTH INSERTION AND WITHDRAWAL VERSUS ONLY WITHDRAWAL OF OUTPATIENT COLONOSCOPY: A RANDOMIZED, CONTROLLED MULTICENTER TRIAL****Jeong-Seon Ji¹, Seung-Woo Lee², Jeong Rok Lee³, Tae-Geun Gweon¹, Hwang Choi¹**¹*Department of Internal Medicine, Incheon St. Mary's Hospital, College of Medicine, The Catholic University of Korea, Incheon, Korea*²*Department of Internal Medicine, Daejeon St. Mary's Hospital, College of Medicine, The Catholic University of Korea, Daejeon, Korea*³*Department of Internal Medicine, Konkuk University Chungju Hospital, Chungju, Korea*

Relevance: Standard practice of colonoscopy is to insert the colonoscope rapidly to reach the cecum, with careful inspection and polypectomy during the withdrawal phase. However, small polyps (e.g. <1 cm) seen during insertion phase are difficult to find during withdrawal phase. Also, colon is in different configuration during insertion and withdrawal phases. There were a few single center studies with expert endoscopists evaluating the effect of inspection and polypectomy during insertion phase of colonoscopy. However, improvement of adenoma detection rate was not concluded.

Object: We designed a randomized, controlled multicenter trial to verify the effect of inspection and polypectomy during both insertion and withdrawal of colonoscopy in colonic adenoma detection.

Materials and methods: This study was conducted at the three university hospitals. Patients aged 50 to 80 years were included. In the study group, inspection and polypectomy performed during both colonoscope insertion and withdrawal. In the control group, inspection and removal of polyps performed entirely during colonoscope withdrawal. The primary outcome measure was the adenoma detection rate (ADR), which was defined as the proportion of patients with ≥ 1 adenoma.

Results: A total of 1001 patients were randomized into the study group (501 patients) or the control group (500 patients). Polyp detection rate was 45% in the study group and 43% in the control group ($P=0.551$). There was no difference in the ADR between the study arm (37%) and control arm (36%) ($P=0.907$). In both groups, mean number of adenomas detected per patients were similar (0.81 vs. 0.77, $P=0.278$). Mean insertion time was significantly longer in study group (6.7 vs. 5.5 min, $P=0.002$).

Conclusions: Inspection and polypectomy during both colonoscope insertion and withdrawal offered no additional advantage on the ADR compared to inspection and polypectomy performed during only withdrawal phase.

162**ASSESSMENT OF THE FINANCIAL ASPECT FOR LAPAROSCOPIC LIVER SURGERY: A SINGLE-CENTER COST ANALYSIS****Jitpanu Wongyongsil, Rawisak Chanwat***Department of surgery, National Cancer Institute, Bangkok, Thailand*

Objective: Laparoscopic liver surgery has been worldwide popularity in last decade, also in Thailand. In selected center, rapidly increase laparoscopic liver surgery approaches as surgeons continue to gain experience, the better surgical outcome has been achieved. However, it is still unclear about cost advantages. This manuscript aims to assess the financial implications of the laparoscopic liver surgery compared to conventional operation.

Material and methods: A cross-sectional comparative study of patient undergoing liver surgery was performed. Data was collected between Jan 2015 and Dec 2017, including operative cost (surgeon/anesthetic cost, cost of instrument, blood and blood component transfusion cost), postoperative cost (hospital stay, ICU and ward admission, complication management) and overall costs.

Results: A total of 147 patients were included: 74 patients underwent open liver surgery (OLS) and 73 patients underwent laparoscopic liver surgery (LLS). For OLS mean operative costs, postoperative and overall costs were $\text{฿}41,343$ ($p < 0.001$), $\text{฿}9,370$ ($p < 0.001$) and $\text{฿}50,714$ ($p=0.009$). Regarding LLS, the mean operative, postoperative and overall costs were $\text{฿}53,217$ ($p < 0.001$), $\text{฿}6,001$ ($p < 0.001$) and $\text{฿}59,218$ ($p=0.009$).

Conclusion: Our data support the cost advantage of the postoperative cost and show slightly increase operative and overall costs in laparoscopic liver surgery approaches.

163**A PROSPECTIVE RANDOMIZED, CONTROLLED TRIAL OF ECULIZUMAB TO PREVENT ISCHEMIA-REPERFUSION INJURY****Kaabak Michael, Babenko Nadeen, Shapiro Ron, Zokoyev Allan, Dymova Olga, Kim Edward***National Research Center of Surgery*

Ischemia-reperfusion injury (IRI) has multiple effects on a transplanted allograft, including delayed or impaired graft function, compromised long-term survival and an association with an increased incidence of rejection. Eculizumab, a monoclonal antibody blocking terminal complement activation, has been postulated to be an effective agent in the prevention or amelioration of IRI. The PROTECT study, a phase 2/3 study of eculizumab infused at the time of reperfusion to prevent

delayed graft function in kidney transplantation, did not reach its primary endpoint of improving DGF rates. Purpose we hypothesized that a single dose of eculizumab at a dose of 700 mg/m² administered to recipient prior to transplantation, would reduce IRI.

Patients and methods: we performed a single center prospective, randomized controlled trial involving 57 pediatric kidney transplant recipients between 2012 and 2016. The immunosuppressive protocol included two doses of alemtuzumab; half of the patients were randomized to receive a single dose of eculizumab prior to transplantation. We utilized an early dosing regimen based on pharmacodynamic analysis, which may be a better approach to complement neutralization. Maintenance immunosuppression was based on a combination of low-dose tacrolimus and mycophenolate, without steroids.

Results: Eculizumab-treated patients had a significantly better early graft function, less arteriolar hyalinosis and chronic glomerulopathy on a protocol biopsies taken on day 30, one year, and three years after transplantation. In the eculizumab group, four non vaccinated children lost their grafts during the course of a flu-like infection.

Conclusions: Eculizumab is associated with better early graft function and improved graft morphology.

164

MODERN MINI-INVASIVE TECHNOLOGIES IN THE TREATMENT OF MECHANICAL JAUNDICE OF VARIOUS GENESIS

M. Kabanov, K. Sementsov, D. Yakovleva, I. Soloviev, D. Degterev, M. Belikova, T. Aksenova, S. Zdasiuk

The Hospital for Veterans of Wars¹, The Department of General Surgery by Mechnikov North West State Medical University², The Department of Naval Surgery by Military Medical Academy named after S.M. Kirov³, St. Petersburg, Russia

Relevance and AIMS: On time minimally invasive biliary decompression is an important component of the stage or final surgical treatment of patients with diseases of the hepatopancreatobiliary zone causing mechanical jaundice. Endoscopic and endobiliary interventions can quickly and effectively restore liver function and reduce postoperative mortality, especially in elderly and senile individuals.

Materials and methods: From 2015 to 2017, we treated 807 patients with mechanical jaundice. Of these, there were 505 patients with malignant strictures of the bile ducts, 17 patients with benign strictures and 264 patients with choledocholithiasis.

Results: The treatment of patients under study was gradual. In malignant lesions two-step approach was mostly used: the percutaneous or endoscopic drainage the primary intervention was followed by the stenting of the bile ducts. The

characteristics of the nitinol stent were selected individually in each case. A multi-stage or hybrid approach was used in benign strictures. In cases of iatrogenic lesions, percutaneous drainage intervention was combined with laparoscopic or laparotomic intervention. As far as complicated forms of pancreatitis are concerned the intervention volume was selected individually depending on the pancreatic lesion nature, thus percutaneous or endoscopic cystogastroanastomosis, percutaneous cholangio drainage (PCD) in combination with cyst drainage methods being used. PCD followed by endoprosthesis with or without percutaneous lithoextraction was performed in cases of benign strictures with biliodigestive anastomosis, combined with or without suprastenotic choledocholithiasis. The gradual replacement of the endoprosthesis was carried out as it became obturation. In the primary sclerosing cholangitis the right and left liver lobe biliary drainage with subsequent stenting was performed. The most frequent postoperation complications were: cholangitis, bile leakage into the free abdominal cavity, severe pancreatitis with an outcome in pancreatic necrosis. Haemobilia, subdiaphragmatic abscesses and clinically significant subcapsular hematomas, bleeding from the gastric mucosa, empyema of the pleura appeared to be among the rare ones. In the case of oncological pathology, there were 56 cases of lethal outcomes during the minimally invasive interventions, which amounted to 10.6%. 47 patients died from progression of multiple organ failure, 13 - after performing percutaneous and 13 - endoscopic interventions. In the cases of endoscopic interventions, 4 patients died from pancreonecrosis, 9 from biliary sepsis; after PCD - 2 died from pancreonecrosis, 11 - from sepsis. There were no lethal outcomes in cases of treatment of benign strictures.

Conclusions: Our experience allows us to draw the following conclusions: the application of hybrid mini-invasive technologies in the treatment of patients with mechanical jaundice improves immediate and long-term results of treatment. It's important to maintain complete consistency between the doctor performing the drainage intervention and the attending physician, which determine the further tactics of patient management and its curability.

165

NEW IN THE SURGICAL MANAGEMENT OF PATIENTS WITH CHRONIC CALCULOUS PANCREATITIS

R. Kalashnik, Y. Parkhisenko

Department of the hospital surgery, FSBE HE "Voronezh State Medical University named after N.N.Burdenko", Russia

There is currently no consensus on the question of testimony to the operational interventions (especially when clinic of ductal hypertension is without an extension of the main pancreatic duct (MPD)), and to the most rational surgical procedure for chronic calculous pancreatitis (CCP). The aim of

this work was to improve the results of surgical management of patients with CCP.

Materials and methods. 13 patients were involved in this study. Cutting-draining operations were carried out in the period from January, 2011 up to December, 2016. 6 patients after Frey's procedure (n = 4) and Izbicki's operation (n = 2) were included in the first group. 7 patients after our modification of Frey's procedure with ultrasonic selective dissection of the pancreatic parenchyma were included in the second group. The clinic of ductal hypertension during expansion of the MPD more than 5-7 mm (according to the instrumental diagnostic methods) was absolute indication for surgical management. Clinical manifestations in patients with CCP (primarily intensive pain syndrome) without dilatation of the MPD or with its extension up to 3-4 mm were relative indications for the surgical procedures.

The results. Postoperative complications were: I degree of Clavien-Dindo classification – relapses of the abdominal pain syndrome in two patients in the first group, II degree – the attack of acute pancreatitis with the outcome in the necrosis of head and body of the pancreas in one patient in the second group (we link that with violation of patient treatment (alcohol) on the 6th day of the postoperative period). Complications III-V degrees of Clavien-Dindo classification after cutting-draining operations were not observed. Indicators of the best quality of life on all scales of the international questionnaire MOS SF-36 and all indicators of the questionnaire for postoperative patients with chronic calculous pancreatitis developed by the authors are marked in the second group. Ultrasonic selective dissection of the pancreatic parenchyma around the fixed pancreatolithes of ducts I-II order on the side surfaces and on the back wall of the MPD with subsequent removal of the pancreatolithes (patent RF A61B17/00; № 2580197) allows to improve significantly the results of the surgical management of patients with CCP. We have sought to remove the fixed pancreatolithes of ducts I-II order with partial dissection of the pancreatic tissue on the upper and lower edges of cleaved by the front surface MPD. Thereby, we have applied the method of ultrasonic selective dissection of the pancreatic parenchyma around the pancreatolithes to improve outflowing the pancreatic juice from ducts I-II order. This method enables to select and delete pancreatolithes in stratum of the pancreatic parenchyma during the local resection of the head of the pancreas. Expansion of the MPD on the border of the head and the body of the pancreas leads to prevent the obliteration of the pancreatico-jejunoanastomosis. Selective dissection of the head of the pancreas by using ultrasonic dissector-aspirator is preferable to the use of electrocautery, because it provides a gradual layered promotion deep the tissue of the head and the uncinate process of the pancreas with exposing stromal vessels and promoting opportune hemostasis, which reduces blood loss and improves outflow of pancreatic juice.

Conclusion. The application of a method (developed by the authors) of ultrasonic selective dissection of the pancreatic parenchyma around the pancreatolithes with subsequent

removal of latter, significantly improved the treatment results of patients with CCP. Statistically significant improvement of the total values of the parameters of the quality of patient's life was received after our modification of Frey's procedure in comparison with the total value of the parameters of the quality of patient's life after Frey's and Izbicki's operations.

166

OVERWEIGHT OR OBESITY IS AN UNFAVOURABLE LONG-TERM PROGNOSTIC FACTOR FOR PATIENTS WHO UNDERWENT GASTRECTOMY FOR STAGE II/III GASTRIC CANCER

Yuichi Kambara, Norihiro Yuasa, Eiji Takeuchi, Hideo Miyake, Hidemasa Nagai, Yuichiro Yoshioka, Masataka Okuno, Kanji Miyata

Japanese Red Cross Nagoya First Hospital, Japan

Relevance: Obesity has been reported to be a prognostic factor for many diseases in epidemiological studies, however, the results of studies examining the relationship between obesity and gastric cancer (GC) prognosis are inconsistent.

Object: The aim of this study was to investigate whether BMI is a prognostic factor for patients who underwent gastrectomy for GC.

Materials and methods: A total of 460 patients with Stage II and III GC who underwent R0-gastrectomy were included. Age, sex, body mass index (BMI: classified into <18.5, 18.5-25, 25-30, ≥ 30 kg/m²), stage, and postoperative adjuvant chemotherapy (PAC) were analyzed to investigate the correlation with relapse-free survival (RFS).

Results: Five-year RFS was 51% for the study patients. Five-year RFS were 48%, 54%, 43% and 22% for patients with BMI<18.5, 18.5-25, 25-30, ≥ 30 kg/m², respectively. The forest plot for relapse risk according to BMI showed a U shape. Multivariate analysis for RFS showed significant differences in stage and BMI; hazard ratio (HR) for recurrence in patients with BMI ≥ 25 kg/m² were 1.42 (95% confidence interval: 1.01-2.02, p=0.0423) with reference to patients with BMI<25kg/m². BMI ≥ 25.0 were associated with longer operation time, more blood loss, less number of lymph node dissected, and more frequent postoperative surgical site infection and intra-abdominal abscess.

Conclusions: BMI ≥ 25 kg/m² is an unfavourable prognostic factor independent of stage for patients who underwent gastrectomy for Stage II and III GC.

167

PORTAL VEIN EMBOLIZATION IN PATIENTS WITH MALIGNANT LIVER TUMORS

P. Kan, D. Kislitsin, K. Kolmachevsky, P. Pavlov, A. Mizin, K. Kipro, A. Gorgun, R. Galimov, A. Binogerov
District clinical hospital, Khanty-Mansiysk, Russia

Currently, surgical operation remains one of the methods to achieve long-term survival of patients with malignant liver tumors. However, resection is often impossible or extremely risky if the estimated remaining volume of the liver (future remnant liver – FRL) is very small, since the risk of postoperative liver failure is very high, which can lead to a fatal outcome. One of the methods for expanding the indications for liver resection is preoperative portal vein embolization (PPVE), which plays a key role in obtaining substitution hypertrophy of the remaining liver, helping to reduce postoperative complications and lethality after extensive liver resection.

Purpose. To evaluate the effectiveness of the technique of preoperative portal vein embolization in preparation for extensive liver resection in primary and metastatic lesions.

Materials and methods. In the period from 2016 to March 2018 preoperative embolization of portal vein 9 scheduled patients, performed - 8. The average age of the patients was 57 years, there were 6 men and 3 women. Metastases of colorectal cancer had 4 patients, metastasis of mammary gland cancer - 1, gallbladder cancer - 2, cholangiocarcinoma - 1, Klatskin tumor - 1. Transhepatic ipsilateral access implemented 4 patients, open access through v. ileocolica - 4 patients. In laparoscopic access in one case revealed carcinomatosis of the peritoneum - refusal of surgical treatment. In all patients, the technique of distal-proximal embolization of the right branch of the portal vein was used, in two cases - with the 4th segmental branch. According to information to CT data, liver volumetry was performed on TLV (total live volume), FLR before PPVE and after 4-5 weeks.

Results. The average growth of FLR was 6.8%. In volume of extended right-side hemihepatectomy operated four patients, in the volume of hepatopancreatoduodenal resection - two, right-side hemihepatectomy - one. One patient with a Klatskin tumor, after a preliminary percutaneous transhepatic cholangiostomy of the left lobar duct and S IV concerning a mechanical jaundice and cholangitis, increase FLR 4 weeks not received, continued monitoring, planned dynamic renal scintigraphy with evaluation of FLR. The average volume of intraoperative blood loss was 900 ml (400-1500 ml). In the postoperative period in four patients there were no signs of liver failure, in two patients they were treated with conservative measures. The patient after hepatopancreatoduodenal resection with portal vein prosthesis (gallbladder cancer) died in the early postoperative period against the background of portal vein thrombosis. Four patients were observed in the III clinical group without signs of relapse, two patients were transferred to the IV clinical group due to the progression of the underlying disease.

Conclusion. The use of preoperative portal vein embolization is an effective method of preparing patients for extensive liver resection. A multidisciplinary approach is the basis of success in the treatment of patients with this pathology.

168

THE RESULTS OF TREATMENT THE PATIENTS WITH HEPATOCELLULAR CARCINOMA AFTER LIVER TRANSPLANTATION

S. Kaniev, Z. Baimakhanov, M. Doshanov, E. Nurlanbayev, T. Tajibayev, E. Enin, E. Serikuly, A. Skakbayev, A. Chormanov, B. Ilyasova, U. Medeubekov, M. Seisenbayev, B. Baimakhanov
Department of HPB surgery and liver transplantation, A.N. Syzganov's National Scientific Center of Surgery, Almaty, Kazakhstan

Background and aim. Hepatocellular carcinoma (HCC) arising from the end stage of liver cirrhosis is a common indication for liver transplantation (LT). A present study was intended to analyze the clinical outcomes in such patients following LT.

Methods. Between December 2011 and December 2017, 88 LTs (71 living donor liver transplantations (LDLT) and 17 deceased donor liver transplantations) were performed at A.N. Syzganov's National Scientific Center of Surgery, 7 patients had the diagnosis of HCC. Of them, in 3 cases, HCC was verified after morphological evaluation of the whole liver (undetected HCC). Indications for liver transplantation were liver cirrhosis with Child Pugh B and C and hepatocellular carcinoma (within the Milan criteria). A bypass system was used in one case during hepatectomy because of patient's AFP level > 1000. One patient had transarterial chemoembolization before LT. By comparing the pathological features of undetectable 3 cases and detectable HCC 4 cases. Clinical and morphological data was retrospectively analyzed.

Results. The average AFP level was 749 (2.3 - 2194), of them, 4 patients had AFP levels within normal rate. The average tumor size was 2.88 (1-5.5) cm. There was no vascular invasion. Grade of differentiation was moderate in all cases. There was no tumor recurrence during the follow-up period. The lethal outcome was in one case due small for size syndrome.

Conclusion. Precise postoperative histological evaluation can identify undetected HCC. However, there was no difference in clinical and survival outcomes between detected and undetected HCC after LT.

169**INTRAHEPATIC CHOLANGIOCELLULAR CARCINOMA: PITFALLS OF RADIOLOGICAL DIAGNOSIS****G. Karmazanovsky, A. Zhao, V. Vishnevsky, A. Stepanova, D. Kalinin***A.V. Vishnevsky National Medical Research Center of Surgery, Russia***Relevance:** Cholangiocellular carcinoma (CCC) is the second most frequent malignant primary tumor affecting the ductal system of the liver and extrahepatic ducts.**Purpose:** In the intrahepatic form, 3 subtypes are distinguished (intraductal, periductal and mass-forming). The mass-forming subtype is predominant and must be differentiated with hepatocellular carcinoma and liver metastases. The aim of this study is to evaluate the possibility of radiological examination for differential diagnosis of CCC.**Materials and methods:** the institution database and the PACS-system for the period 2015-2018 have been studied. In 52 patients with histologically proven CCC, a complex abdominal MRI (3T) and MDCT were performed.**Results:** The coincidence of MDCT and MRI data and morphology was in 38 cases. In 15 cases, the following radiological findings were made: differential diagnosis between HCC and CCC - 1, HCC - 4, metastases - 2, gall bladder carcinoma - 1, malignant tumor without indication of morphology - 1, absence of liver lesion and IPMN of the pancreas - 1, hepatic adenoma -1, liver abscess 2, post-inflammatory bile ducts stricture - 1. Consequently, the malignant nature of focal liver lesions was established in 47 cases (38 + 9 of 52 or 47/52 = 90.38%). The reasons for the discrepancy between the radiological conclusion and the morphological data were analyzed and explanations of their occurrence at radiology are given.**Conclusion:** Radiological diagnosis of intrahepatic form of cholangiocellular carcinoma is quite effective. Possible discrepancies in diagnoses are most often due to radiological conclusions about malignant nature of the tumors. The optimal radiological options for diagnosing CCC according to own research and world literature data are MRI-DWI, enhanced MRI, and dynamic MDCT.³*"National center of clinical and morphological diagnosis", Saint-Petersburg, Russia*⁴*Saint-Petersburg State University*

Today, fine-needle puncture under endosonographic (EUS) guidance is the most accurate and minimally invasive way to obtain material for morphological examination in identifying focal lesions of the pancreas. Cystic lesions can be difficult to diagnose. However, puncture of the cystic formations of the pancreas is associated with an increased risk of complications (such as bleeding, infection). In addition, according to a number of authors, the effectiveness of morphological diagnosis of the contents of the cyst is often lower than the study of punctate of solid formations. The aim of this work was to compare the effectiveness of morphological evaluation of the material of punctate solid and cystic focal pancreatic formations.

Materials and methods: the study involved 97 patients with focal lesions of the pancreas, in which as a result of surgical treatment or sectional study the tumor nature of focal changes was confirmed. In 83 of these, education was solid, and another 14 – cystic. In 61.2% of the lesions was localized in the head of the pancreas, 28.2% – the body and 7.6% – in the tail of the pancreas. In 2% there was a multiple defeat. All patients underwent fine needle aspiration puncture of pancreatic formation with a 22G needle. The material was sent to the morphological laboratory, where the methods of standard cytology and liquid cytology, cell block production were used. Within the framework of this work the results of morphological research were evaluated as: positive, in the event that came morphological confirmation of the tumor process; negative – in the case where among the tissues of the pancreas was not detected tumor cells; not informative – in the absence of cells specific to the area**Results:** positive results of puncture were obtained in 81.4% of all cases. At the same time, for solid lesions this figure was 84.3%, for cysts it was significantly lower and amounted to 64.3% (t – 1.5). Negative results were obtained in 12.4% of all lesions, for solid lesions they were 10.8%, for cysts – 21.4% (t – 0.92). Uninformative punctures were noted in 6.2% of punctures, while in the case of solid lesions this percentage was 4.8%, for cysts – 14.3%. (t – 0.98).**Conclusions:** Fine-needle puncture of the focal lesions of the pancreas is an effective method of obtaining material for morphological examination. Puncture of the cystic lesions of the pancreas has significantly less efficiency of morphological confirmation, compared with the puncture of solid lesions. In this regard, as well as given the high risks of manipulation, puncture of cystic neoplasia of the pancreas should be performed only in doubtful cases, when it can affect the choice of further diagnostic or therapeutic strategy. In addition, to improve the effectiveness, the study of cyst punctate should be supplemented by non-morphological methods (assessment of amylase levels, tumor markers, the presence of mucin, molecular-biological markers).**170****COMPARISON OF THE EFFECTIVENESS OF FINE-NEEDLE PUNCTURE OF FOCAL PANCREATIC LESIONS****V. Kashchenko^{1,4}, E. Solonitsyn^{2,4}, S. Vorobyev³, E. Vasyukova^{1,4}, A. Vanyan¹**¹*Sokolov Hospital No122 FMBA of Russia, Saint-Petersburg, Russia*²*«NMSC named by V.A. Almazov» Ministry of health of Russia, Saint-Petersburg, Russia*

171

EFFICIENCY OF FINE-NEEDLE PUNCTURES OF FOCAL PANCREATIC LESIONS UNDER ENDOSONOGRAPHIC GUIDANCE

V. Kashchenko^{1,4}, E. Solonitsyn^{2,4}, S. Vorobyev³, E. Vasyukova^{1,4}, A. Vanyan¹

¹*Sokolov Hospital No122 FMBA of Russia, Saint-Petersburg, Russia*

²*«NMSC named by V.A. Almazov» Ministry of health of Russia, Saint-Petersburg, Russia*

³*"National center of clinical and morphological diagnosis", Saint-Petersburg, Russia*

⁴*Saint-Petersburg State University*

Morphological verification of focal lesions of the pancreas is often key in the choice of treatment tactic. To date, the method of choice of obtaining material for morphological studies in focal pancreatic formations is a fine needle aspiration puncture (FNA) under endosonographic (EUS) guidance. This method is limited in Russia for a number of reasons related to economic and technical difficulties.

Objective: to evaluate the effectiveness of the FNA focal lesions of the pancreas.

Materials and methods: the study included 103 patients with focal pancreatic lesions. Women – 49, men – 54. The mean age of patients was 61±8.5 years. The patients underwent 110 punctures, including 7 repeated punctures, with a primary negative result. Of the 103 entities, 83 (80.6%) were solid, 14 (13.6%) were cystic and 6 (5.8%) had mixed cystic-solid structure. All punctures were performed with a 22G needle, according to the standard procedure. Morphological study included cytological study with the production of cell blocks. If necessary, the study was supplemented with immunohistochemical methods or methods of liquid cytology. The results of the puncture were regarded as positive, when obtaining morphological confirmation of the type of education. In the case of pancreatic tissue, without signs of tumor growth, the results were regarded as negative, in the absence of pancreatic tissue punctate or formation, the result was regarded as not informative. The study included patients whose final diagnosis was confirmed as a result of the study of surgical or postmortem material, or a long (more than 2 years) follow-up period.

Results: as a result of the primary puncture, morphological confirmation of the tumor type was obtained in 82.5%. Negative results were obtained in 11.7%, non-informative puncture was in 5.8% of cases. In two cases of uninformative puncture, and five cases of negative one – repeated FNA was performed. In all cases of uninformative puncture and three cases of negative puncture, the presence of tumor formation was confirmed. Sensitivity, specificity and efficiency of primary FNA were 90.4%, 100.0%, 90.9%, respectively.

Taking into account repeated punctures, sensitivity, specificity and efficiency of FNA were 95.7%, 100.0%, 96.0%, respectively. In both cases, the predictive value of the positive result was 100%, but the predictive value of the negative result was 35.7% for the primary puncture and 55.6% for the second puncture.

Conclusions: FNA under EUS guidance of focal pancreatic lesions is an effective method of obtaining material for morphological diagnosis. Negative results of the primary puncture have a low predictive value. Repeated punctures with negative or uninformative results significantly increase the diagnostic value of the technique.

172

PANCREATIC CYSTIC NEOPLASMS: SINGLE-CENTER EXPERIENCE

V. Kashchenko^{1,3}, E. Vasyukova^{1,3}, E. Solonitsyn^{2,3}, V. Toidze¹, A. Vanyan¹

¹*Sokolov Hospital No122 FMBA of Russia, Saint-Petersburg, Russia*

²*«NMSC named by V.A. Almazov» Ministry of health of Russia, Saint-Petersburg, Russia.*

³*Saint-Petersburg State University, Saint-Petersburg, Russia*

Background. Pancreatic cystic neoplasms include serous cystic neoplasms (SCN), intraductal papillary mucinous neoplasms (IPMN), mucinous cystic neoplasms (MCN) and solid pseudopapillary neoplasms (SPPN). Cystic tumors of the pancreas have been increasingly recognized in the last two decades. All these tumors except for SCN are potentially malignant.

Methods. We retrospectively reviewed patients with pancreatic cystic neoplasms in our hospital between 2012-2016.

Results. Data were collected from 75 patients: 58% males and 42% females. Median age: 58. Many of these tumors are diagnosed incidentally. The sensitivity for CT scan was 58%, MRI – 76%, EUS – 89%. Decision of surgical procedure in IPMN cases was made in according to Fukuoka criteria. Twenty-two patients underwent surgery: Whipple procedure – 9 patients, distal pancreatectomy – 12, central pancreatectomy – 1. Final diagnoses by histological study were: SCN in 6 cases, IPMN -8, MCN - 7 and SPPN in 1 patient. The median follow-up was 3,2 years (range 2-6). The postoperative morbidity rate was 21%. There were no deaths.

Conclusion. Pancreatic cystic neoplasms require special diagnostic program which helps to determine surgical procedure.

173**TREATMENT OF GASTRIC CANCER:
STANDARDISATION OR INDIVIDUALISATION?****V. Kashchenko, A. Lodygin, E. Vasyucova, A. Akhmetov**¹*Sokolov Hospital No122 FMBA of Russia, Saint-Petersburg
Russia*²*Saint-Petersburg State University, Saint-Petersburg, Russia*

The aim of the work is to summarize the main strategic approaches in the treatment of gastric cancer. The extent of D2 lymph node dissection has been accepted in Japan as the standard in advanced gastric cancer for many decades. Recently European trials have concluded a decrease of recurrence after D2 procedure as well. Unfortunately even after a D2 node dissection disease recurs in more than 60% of patients with advanced gastric cancer. The reason of tumor recurrence is considered to be small amounts of residual cancer cells. Recently remarkable scientific progress enables to reveal the existence of occult cancer cells. They are called "micrometastases", but its clinical implication remains still unclear. Therefore it seems logical that neo-adjuvant treatment with postoperative chemotherapy has become standard approach for high-risk patients. Three major guidelines for treatment are commonly used in gastric cancer, as follow: Japanese (JGCA), European (ESMO) and North American (NCCN). The standardization has become the mainstream in the evolution of clinical methodology during past decades. In recent years, the strategy of gastric cancer treatment have been moving from a standardized to individualized approach. Recently, a new molecular classification of gastric cancer has been introduced. It gave a great impetus to the development of a new strategy. Currently tailored approach also may include accurately pre-treatment staging, integration of high technology into diagnosis process, laparoscopic surgery based on individual anatomy, knowledge of metastases patterns and careful patients evaluation. Tailored treatment can vary from endoscopic resection to different extent of lymph node dissection with neo-adjuvant or adjuvant therapy. Even in stage IV or initially unresectable disease, patients who had shown partial or complete response to chemotherapy, could be re-considered for the so-called conversion surgery.

Conclusion: Tailored approach is an important component of the standardized gastric cancer treatment.

174**HUGE EXTRAGASTROINTESTINAL STROMAL TUMOR
OF THE LESSER OMENTUM: A CASE REPORT****Kawai Naoyuki***Department of clinical center for ultrasonography,
Takamatsu Red Cross Hospital, Japan***Actuality.** GIST.

The aim. To the best of our knowledge, few cases of EGIST of the lesser omentum were reported.

Materials and methods. A 40 year-old Japanese woman presented to our department with symptoms of early satiety and epigastralgia. Physical examination revealed a mass in the central abdominal space from inferior margin of liver to iliopsoas muscle.

Results. The results of laboratory tests including complete blood count, amylase, liver function tests, and all tumor markers were within normal range. Ultrasonography, CT and MRI of her abdomen showed a large mass (maximum diameter 20 cms) that was confined between the left hepatic lobe, the stomach and the retroperitoneum. This tumor had a lot of cystic and blood compartments inside. We preoperatively suspected it is a huge stromal tumor. On exploratory laparotomy, after entering the lesser sac a large solid tumor was found located posterior to the gastric wall and anterior to the pancreas. There was a clear plane of dissection without invasion of either organ and a complete resection of the mass was performed with safety. It was assumed that the tumor originated from tissues of the lesser omentum. Neither metastatic liver lesions nor lymphadenopathy were observed. The postoperative course was uneventful and the patient was discharged after 7 days. The specimen measured 22 cms and weighed 610 grams. Histological examination revealed spindle cells with severe pleomorphism and high mitotic activity (mitotic count of 44 mitoses/50 high-power fields). Immunohistochemically, the tumor cells showed strong positivity for DOG-1 and p16. Immunostains for CD34 and CD117 (c-kit) were partially positive. Immunostains for desmin and SMA were negative. The expression of Ki67 protein was 18%. Considering tumor's size, its morphology and high mitotic index, the estimated risk of recurrence after surgery was high and subsequently the patient was referred to a medical oncologist for further management. Regular dosing of 400 mg imatinib mesylate was initiated.

Conclusion. EGISTs are very rare mesenchymal tumors. They originate from cells outside the gastrointestinal tract and tend to have a greater size, higher mitotic index and more aggressive biological behavior than their GI counterparts.

175

SYSTEMATIC REVIEW OF 106 CASES: WHAT ARE THE OUTCOMES OF ROBOTIC RESECTIONS FOR CHOLEDOCHAL CYSTS?

Cuneyt Kayaalp, Fatih Sumer

Inonu University, Turkey

Aim: Our objective was providing a preliminary data on the robotic resections of choledochal cysts. By the way we can compare the outcomes of robotic surgery to laparoscopic technique.

Methods: Three databases (Pubmed, Scopus, Google Scholar) were searched by key words and publication details, patient demographics, cyst type (Todani) and size, surgical features and outcomes were recorded.

Results: Total 106 patients were analyzed in 26 studies. Most patients were pediatric (77%), female (78%) and Todani type I cysts (91%). Mean operating time, blood loss and length of hospital stay were eight hours, 112 ml and eight days, respectively. Conversion rate was 9.4% and the overall morbidity was 19% (5% biliary leak, 5% intestinal obstruction and 3% hepaticojejunostomy stricture) without mortality. Duration of surgery and length of hospital stay were longer in the intracorporeal jejunojunostomies than the extracorporeal jejunojunostomies (511+105ml vs. 440+97ml, $p=0.002$ and 6.7+3.1 vs. 8.7+4.8, $p=0.04$). Two thirds of the patients had no long-term follow-ups.

Conclusion: Robotic surgery for choledochal cysts is in an emerging period. Postoperative hospital stay and overall morbidities were similar to the previously reported laparoscopic technique but operating time was longer. It provides a comfortable hepaticojejunostomy to the surgeron, but the outcomes were not superior than the laparoscopic surgery yet.

176

INTRODUCTION OF CRYOPRECIPITATE INTO THE LIVER LEADS TO IMPROVEMENT OF PORTAL BLOOD FLOW

D. Kazakova, Y. Poluektov, R. Karpova

Clinic of Faculty Surgery No.1, Federal State Autonomous Educational Institution of Higher Training I.M. Sechenov First Moscow State Medical University of the Ministry of Health of the Russian Federation (Sechenov University), Russia

Introduction: Liver cirrhosis is a very common pathology in the structure of gastrointestinal diseases. The amount of five-year survival rate is 62% in the compensation stage of cirrhosis whereas it decreases to 19% in the decompensation stage. However, the hepatic tissue has a unique ability for regeneration due to hypertrophy and hyperplasia of ultra-

structure of hepatocytes. In this respect, we give preference to minimally invasive techniques with the use of agents influencing an inflammation process and liver regeneration such as cryoprecipitate. The cryoprecipitate is a highly concentrated solution of fibrinogen derived from donor plasma by cryoprecipitation, which consist of growth factors to decrease macrophage activity and cirrhosis progress.

Aim: To study the changes in portal blood flow in patients with liver cirrhosis after introduction of cryoprecipitate into cirrhotic liver tissue.

Materials and methods: 40 patients (28 men and 12 women) aged from 25 to 60 (the mean age 45 years) with liver cirrhosis were supervised from 2000 to 2017 in Faculty Surgery Clinic №1. 27 patients had alcoholic cirrhosis and 13 patients had mixed (viral and toxic) cirrhosis. Cirrhosis of Class A according to Child-Pugh was diagnosed in 8 patients, Class B in 13 patients, Class C in 19 patients. Cryoprecipitate was injected into liver tissue (1.5-2 ml in each segment) by percutaneous puncture under ultrasonic guidance. The portal blood flow study was conducted before and 6 and 12 months after the procedure using duplex ultrasound examination.

Results: Statistically significant changes were obtained after 6 months in 92% of patients. Stagnation index (ratio of the linear velocity of flow to the diameter of the vessel) became normal in 6 months in all patients, which correlates with the risk of bleeding from esophageal veins. In patients with long-term cirrhosis of the liver class A, B and C, the circulation in the portal system was normalized, and the risk of bleeding from the esophageal veins was minimal in 6 months. The results obtained 12 months after the procedure did not changed.

Conclusion: Stimulation of liver regeneration with cryoprecipitate in patients with long-term cirrhosis reduces portal hypertension after 6 months in 92%.

177

TELECONSULTATION OF PATIENTS IS MORE SUSTAINABLE AGE

V. Kazennov¹, K. Baburin²

¹Far Eastern State Medical University, Khabarovsk, Russia

²The Far Eastern Telemedicine Center, Khabarovsk, Russia

Annotation. The possibility and effectiveness of telecommunication consulting on a free basis with a minimal set of equipment and software in the Far East, almost without regular transport infrastructure, is shown.

The possibility and effectiveness of telecommunications in the Far East, having almost no transport infrastructure. The share of persons older than working age in the population of Russia increased from 20.5% in 2002 to 23.5% at the beginning of 2014 [4]. In the Khabarovsk Territory, the proportion of people over working age in 2013 is 21.5%, and life

expectancy, according to data for 2014, is 68 years [5]. An important public health objective is to improve the quality of life of people older than working age [2]. The Far Eastern branch of the gerontological society of the Russian Academy of Sciences considers the introduction of telemedicine technologies as one of its tasks. The Far East Telemedicine Center of the Far Eastern State Medical University (FESMU) in 2001 developed the draft target program "Geriatric Telemedicine" [6], participated in the "V scientific-practical conference" Pushkov Readings ", St. Petersburg, 2009 with the report "Geriatric Telemedicine in the Far Eastern Federal District "In total for 2013-2015, FESMU organized 388 free asynchronous requests from doctors and patients, 20.4% of whom are older than working age, mainly from the Far Eastern Federal District (59.5% from Khabarovsk, 34 - from the Chukotka Autonomous Okrug, 2%, Khabarovsk Territory - 5.1%, Primorsky Territory - 1.3%) on the The equipment of the center: low-cost PC, digital camera, video camera, speakers, microphone, standard office equipment, fiber optics at speeds up to 12 Mbps; technology: e-mail; FTP; IP-telephony; web-platform; years - forums, mailing lists. We created a site on a free server, the second option is <http://www.dvctelemed.ucoz.ru>, we organize consultations on the ring scheme of tele-consulting, file form of work with information [1]. Doctors were subscribers in 48.1% of cases, patients - 51.9%; Inquiries were received: by e-mail - 29,1%, e-mail + FTP-server - 8,9%, telephone - 15,2%, paper carriers - 46,8%; More than half of the inquiries were for surgical profiles due to a shortage of specialists in the regions. On the basis of prevalence: tactics of treatment - 53.2%, surgical treatment - 12.7%. All clinical inquiries from doctors were complicated. The first category - 34.2%, the second - 21.5%, the third (unknown diagnosis, severe concomitant pathology) - 44.3%. Requests with images were 46.8%; (9), neurosurgery (6), orthopedics (4), e-mails sent to consultants (52 percent), e-mails + FTP (29%) (with image files), by phone - 13%, on paper - 4%, the web platform - 2%. Distribution of requests at the place of counseling: Moscow - 31.6%, Khabarovsk - 29.1%, St. Petersburg - 10.1%, other cities (Ekaterinburg, Novosibirsk, etc.) - 25.4%, foreign countries (Belarus, Israel, Germany) - 3.9%. Distribution according to the executors: consultants of the central clinics - 38.0%, practitioners of practical health care - 25.3%, staff of the Far Eastern State Medical University - 3.8%, employees of the DVCTM - 16.5% (management, information search); clinics abroad - 3.8%. In Khabarovsk, 78.3% of all requests made by the local authorities were conducted per day; in Moscow for a day - 16%, 8 days or more - 48%. The results of consultations: completed - 72.2% of requests, unfinished - 27.8% (additional data request - 77.3%, need for face-to-face consultation - 18.2%, need for video telephony - 4.5%); there are no ineffective ones, which is much better than the work of other centers (22% of ineffective and incomplete consultations at the Nizhny Novgorod Telemedicine Center in 2001-2011. [3] All patients were hospitalized in the consultation: in the Novosibirsk NIIPK named after E.Meshalkin - 2, Federal Center of High Technologies FMBA, Moscow - 1.

Teleconsultation continues to this day. Prevailing extremely difficult cases of neurosurgery, hematology, neurology from the PrJSC, where there is a shortage or lack of these specialists.

Conclusions: Tele-consulting is possible even with a small budget financing: on simple equipment, with a low speed of the Internet. It is necessary to create regional TM networks, to develop home and mobile telemedicine, to overcome the psychological barrier of the leaders of MU.

178

TELEMEDICINE IN THE FAR EAST

V. Kazenov, K. Baburin

Department of Traumatology and Orthopedics, State Institution of Higher Professional Education of the Far-Eastern State Medical University of the Ministry of Health of Russia, Khabarovsk, Russia

Annotation. An analytical review of the state of general and private telemedicine in the Far East on Internet resources and the experience of the work of the Far Eastern Telemedicine Center was conducted.

Conducted an analytical review of the state of public and private telemedicine in the Far East for the Internet resources and experience of the Far Eastern Center for Telemedicine. TMC in the regions, except for Khabarovsk, is only in RB No. 2 p. Sakha (Yakutia), the Children's Regional Hospital of Yuzhno-Sakhalinsk has a telemedicine office. The most developed teleradiology. So, the PACS system is in a number of large clinics. Telepsychiatry in the Far Eastern Federal District is absent, even by Skype. MIS are implemented in Khabarovsk in most MUs, but access to the Internet is often limited to the head physician; even in the District Hospital of the ChAO, all units are computerized, MIS introduced, and an "Electronic Registry" [3]. There is no FOCL in Chukotka, which will soon be built from Petropavlovsk-Kamchatsky [14] There is no fast Internet in Koryakia (Kamchatka Territory). In October 2015, a team of Amur doctors together with doctors from ChAO developed the possibilities of telemedicine in Anadyr district, processing information about patients from remote villages [14]. Still cases of application in the Far Eastern Federal District of mobile telemedicine in JSC Russian Railways: the train "Matvey Mudrov" regularly travels to remote regions [5]; on the basis of a portable telemedicine complex on solutions for video-conferencing of Tandberg production, a network of goods and materials from Sakhalin to Kaliningrad [8] is organized. Telepathology is used only in the Republic of Belarus. Sakha (digital video with Karl Zeiss microscope). [2]. March 30, 2016 in the Far Eastern Federal University (FEFU) commissioned a laser microscope ZEISS Microscopy, which is involved in developments in the field of biomedicine [9]. There is no special medical equipment in the DMC DFO;

There is no single electronic archive of documents, there is no intra-regional segment of the TM system, except for the p. Sakha [1.11]; there are no expert systems. In the Republic of Belarus № 2 r. Sakha paper medical history is replaced by doctor's tablets and bar-code bracelets for patients: the doctor brings an electronic tablet to the patient's wrist strap and in a minute all information on the patient's history appears on the tablet screen (the nurse when completing fills the patient's medical history and prints out on a special printer a plastic bracelet); Also use the telecardiograph Valenta (the only case of telecardiography in the Far Eastern Federal District). There is no telemonitoring, home or personal telemedicine in the DFO. Video EEG monitoring is carried out only at the Road Hospital st. Khabarovsk-1 JSC Russian Railways [10]. As for the medical portal of Primorsky Krai, "Vladmedicina" conducts asynchronous consultations, there is a forum for patients - the only case of a medical Internet portal in the Far Eastern Federal District [7]. Telesurgery is in its infancy: the robot Leonardo da Vinci works at the FEFU clinic in Vladivostok. Residents of the Far Eastern region can receive medical services in the Russian-Japanese center "Hokuto"; for the spread of telemedicine services in the region, mobile operator MTS [12] started its work. The Regional Clinical Oncology Center is the only institution in the Khabarovsk Territory that conducts TMK [6]. A personal electronic medical record is available in the Khabarovsk Territory in single institutions: at the Viveya CCDC, its medical centers conduct only international consultations with the aim of hospitalization abroad; on the basis of the regional MIAC, a "cloud" storage of a single e-medical card of a resident of the province was created, which will fully work by 2020 with exports to the federal service; in the province there is a unified regional IP of preferential medicinal provision of the population, a service of recording to a doctor at all polyclinic institutions through the portal of public services [4]. There are almost no interregional conferences on TM in the Far Eastern Federal District. Teaching telemedicine in the Far East State Medical University was liquidated in 2009, at the Federal State Educational Institution of Higher Professional Education of the North-Eastern Federal University. M.K. Amosov, r. Sakha telemedicine is taught to students.

Conclusions. It is necessary to create regional TM-networks, to develop private telemedicine.

179

COMPARATIVE ASSESSMENT OF VARIOUS SPECIES OF SYNTHETIC NETWORK EXPLANTS IN EXPERIMENT

E. Kchibekov, M. Serdyukov, V. Bondarev, D. Kaliev
*FGBOU VO Astrakhan State Medical University,
 Astrakhan, Russia*

The incidence of hernias of the anterior abdominal wall

among the population is 5% -7%. In the surgical treatment of hernias, the frequency of relapses ranges from 10 to 40%. The use of modern synthetic reticular endoprotheses has made it possible to reduce the frequency of relapses to 1.8-10%, however, the introduction of alloplasty of hernial defects caused an increase in the number of complications of healing of the postoperative wound: suppuration, sequestration, graft rejection, gray, ligature fistulas, whose frequency varies according to the literature the limits of 10-30%. In this connection, the study of the problems of inflammation and reparative regeneration, the morphological study of the characteristics of the response of tissues to implantation will allow an adequate assessment of their use. Improve the results of treatment of patients with hernias of the anterior abdominal wall with the help of a differentiated approach to the use of synthetic explants. An experimental study was performed on 292 rats. The reaction to 6 types of synthetic reticular explants was investigated, 5 of them "light" polypropylene and 1 metallic. As a result of studies carried out on laboratory rats, it is established that a minimal fibrous capsule is formed after implantation of a mesh explant with the smallest content of polypropylene. Of all the polypropylene nets, the explant with the largest pore size grew most intensively after implantation with a fibrous tissue. A more pronounced fibrous capsule is formed after implanting the rats with a metal explant "titanium silk". The data obtained differ from the properties of endoprotheses, claimed by manufacturers, and this fact should be taken into account when choosing a reticular endoprosthesis for alloplasty of ventral and inguinal hernias. Thus, some polypropylene and metal mesh, as well as some polypropylene, effectively perform another function besides mechanical: create conditions for permanent inflammation and collagen neoplasm.

180

TRANS-ANAL HAEMORRHOIDAL DE-ARTERIALISATION AND HAEMORRHOIDOPEXY (THD). WHERE DOES IT STAND IN HAEMORRHOIDAL TREATMENT ECHELON?

Shandana L Khan, Haytham Abudeed, Abdul Latif Khan

Aims: THD is a new, minimally invasive, non-excisional surgery for symptomatic prolapsing haemorrhoids. The long-term outcome of this procedure however, remains to be established. We aim to analyse the long-term outcome of THD-mucopexy in the management of prolapsing haemorrhoids based on the evidence of a prospective data from a single institution.

Methods: A prospective data was collected on 100 consecutive cases of grade 3 and 4 symptomatic haemorrhoids. We look at the short term (less than 6 weeks) and long term (2 years) results of THD in patients who underwent surgery as

a day case under general anaesthesia. Pre- and postoperative symptoms were assessed with a view to evaluate the nature of complications and long-term recurrence rate.

Results: The average age of the patients was 54 years (34–79 years). Gender distribution was 61% males and 39% females. The commonest pre-operative symptoms were bleeding with 74 (74%) followed by prolapse 31 (31%) and perianal pain 15 (15%). Other less common pre-operative symptoms include discharge 5 (5%), itching 2 (2%), anal fissure 4 (4%). The statistically significant pre-operative symptoms improved by THD were bleeding & prolapse both with P-values of <0.0001. This was followed by perianal pain & discharge both of which improved although not statistically significant. Importantly, the most common complication of THD was recurrence at about 13%. 88% of patients reported >70% improvement in their symptoms with 20 of them citing a 100% improvement. 78% of patients expressed satisfaction score of 4 and above on satisfaction scale questionnaire with 63% of them having maximum satisfaction of 5.

Conclusion: THD mucopexy remains a safe and effective minimally invasive modality for prolapsing symptomatic haemorrhoids with acceptable complication and recurrence rate. Recurrence could be dealt with repeat procedure without any significant risk to patients. Appropriate case selection (symptomatic prolapsing haemorrhoids) forms the basis for a successful outcome as demonstrated in this series. It is hard to justify its use in non-prolapsing piles. Longer follow up and randomised multicentre trials with larger sample sizes are warranted to compare its efficacy with that of conventional excisional surgery.

181

IMMEDIATE OUTCOMES OF LAPAROSCOPIC OPERATIONS BY COLON CANCER IN HIGH RISK GROUP ELDERLY PATIENTS

M. Khanevich¹, G. Khrykov^{1,2}, N. Maystrenko¹, A. Khalikov¹, P. Romashchenko², A. Khazov¹

¹SPb SBHCI «City clinical oncology dispensary» Saint-Petersburg, Russia

²FSBMEI HE «Military Medical academy by the name of S.M. Kirov» MB RF, Saint-Petersburg, Russia

Background. In real time each ninth human of the world more than 60 years old and percent of elderly people constantly increases. In Russia, as in majority of world countries, the most occurrence of colon cancer among people 60 years and over. The results of surgical treatment in oncologic patient older than 60 years worse than in such younger patients. An indications to laparoscopic approach using in elderly and senile patients with high comorbidity and ASA III-IV are controversial.

Aim. To compare an immediate outcome of laparoscopic operations in conditions of low intraabdominal pressure by

colon cancer elderly high risk group patients.

Methods. Laparoscopic operations made in low intra-abdominal pressure (less than 8 mm Hg), with the help of deep neuro-muscular block (NMB) by rocuronium bolus injection 0,6 mg/kg with it constant infusion 0,3 mg/kg/per hour. In the end of operation before extubation NMB-reversion performed by Sugammadex (4 mg/kg) injection (patent for invention). Patients in postoperative period exposed to early activation using multimodal analgesia without opioids and early enteral nutrition.

Results. 204 colon cancer patients were include. Median age 75 [69; 80] years. 119 patients (58,3 %) older than 75 years. All cases were high risk group by ASA classification: ASA III – 117 (57,4 %), ASA IV – 87 (42,6 %). Cardiovascular complications risk were high in 96 (47,1 %) and very high in 94 (46,1 %) cases. Median Charlson comorbidity index was 8 [7; 9]. Median CR-POSSUM was 17 [15; 21]. Open approach used in 156 (71,6 %), laparoscopic approach in 58 (28,4 %). All patients before hospitalization consulted by anesthesiologist. Weight loss on 2% and more during 2 months or BMI less than 17,5 was indication to using by «sipping» method hypercaloric hypernitrogenous nutrient mixes 7-10 days before operation. Anemia corrected with 3-valent iron drugs, stimulator of erythropoiesis, and blood transfusion. Threshold level were 120 g/l. An ejection fraction less than 40 % was an indication to 24-hours infusion of Levosimendan. Complications in laparoscopic group were in 9 cases 15,5 % (95 % CI 7,2–24,9 %), that significantly lower than in open group – 33 cases 22,6 % (95 % CI 15,8–28,6 %), p< 0,001. The Clavien–Dindo severity class of complications was significantly lower in laparoscopic group too. Pain intensity, blood loss, infusion volume, median length of stay in ICU, postoperative and in hospital were significantly lower in laparoscopic group (p < 0,001).

Conclusions. Implementation new method of laparoscopic operation realization allow to expand indications to minimally invasive treatment, reduce number and severity of complications, length of stay in ICU and in hospital, increase quality of life, providing early rehabilitation and enhance postoperative recovery in high risk elderly patients.

182

TREATMENT OF PATIENTS WITH STOMACH CANCER, TREATED WITH CARDIOVASCULAR PATHOLOGY AND ANEMIA

M. Khanevich, E. Yuryev, M. Giparovich

¹Russian Research Institute of Hematology and Transfusiology of the Federal Medical and Biological Agency

²St. Petersburg State Clinical Hospital "City Clinical Oncology Center", St. Petersburg, Russia

Patients with stomach cancer more than 25% have a pronounced accompanying pathology of the cardiovascular system and often the course of the disease in these patients

is accompanied by anemia, which is due to gastric bleeding, folic acid deficiency and a decrease in the level of iron in the body. Correction of anemia in such situations is not an easy task because of the high risk of decompensation of cardiovascular diseases during blood transfusions. To study the possibility of reducing the volume of transfusion therapy by including in the perioperative treatment complex preparations stimulating erythropoiesis (iron-containing preparations, erythropoietins). To assess the effect of transfusion of erythrocyte-containing media on the development of postoperative complications. Drugs that stimulate erythropoiesis in perioperative therapy were used in 30 patients, weighed down with cardiovascular pathology in the pre- and postoperative period. The control group consisted of 30 patients, weighed down with cardiovascular pathology, which correction of anemia was carried out by transfusion of erythrocyte suspension. In all patients, gastrectomy or subtotal resection of the stomach, including D2 lymphadenectomy, was performed. The complications were classified according to the Dindo-Clavien scale. Complications in the intra- and postoperative periods were in 35.2% of patients. Lethality 3.4%. The most frequent complications were heart rhythm disturbances in 9 (15%) patients, acute coronary syndrome - in 5 (8.3%), inflammatory purulent complications from the operating wound in 7 (11.6%), nosocomial postoperative pneumonia - in 4 (6.6%). See Table 1. The use of drugs that stimulate erythropoiesis made it possible to increase the level of red blood counts, which made it possible to turn out to be a blood transfusion. In the postoperative period, the risk of cardiovascular and inflammatory-purulent complications decreases in the group of patients who have not undergone transfusion of erythrocyte suspension, regenerative abilities improve, immunological reactivity of the organism increases. Patients burdened with cardiovascular pathology were subject to postoperative complications more than without it. The use of stimulating erythropoiesis drugs in patients with gastric cancer with severe cardiovascular pathology contributes to an adequate correction of anemia, which allows not to apply transfusion and significantly reduces the volume of infusion-transfusion therapy. The rejection of blood transfusions reduces the number of postoperative complications and lethality.

Results of treatment of patients with gastric cancer, fatigued by cardiovascular pathology and anemia (n=25)

	Erythrocyte stimulating drugs		Blood transfusion	
	No	%	No	%
Staging according to the results of histology (according to TNM classification, 7 revision):				
Stage I	4	13,3	3	10
II stage	9	29,7	10	
III stage	16	53	17	56,1
IV stage	1	3,3	0	0
Without complications	20	66	16	53
Mild complications	10	33	12	10,3
Severe complications	5	16,6	7	23,3
List of complications *:				
Insufficiency of the esophagogastric anastomosis	1	3,3	2	6,6

Exudative pleurisy	1	3,3	1	3,3
Event	0	0	1	3,3
Acute pancreatitis	3	10	4	13,3
Acute cardiovascular failure	2	6,6	3	10
Impaired heart rate	4	13,3	5	16,6
Acute myocardial infarction	0	0	1	3,3
Subhepatic abscess	1	3,3	0	0
Anastomoses	1	3,3	3	10
Postoperative pneumonia	2	6,6	2	6,6
Encephalopathy	1	3,3	1	3,3
Suppuration of a postoperative wound	3	10	4	13,3
Hyperthermia	4	13,3	4	13,3
90-day lethality	0	0	1	3,3
Postoperative bed-day, day more than one complication	13±22;	10-40	12±19;	8-34
	6		13	

183

COMPLICATIONS AFTER LAPAROSCOPIC PANCREATODUODENECTOMY: WHO IS AT RISK

I. Khatkov, R. Izrailov, M. Baychorov, P. Tyutyunnik, A. Andrianov, M. Mikhnevich

Moscow Clinical Scientific Center named after A.S.Loginov Russia

Background: Two hundred and fifty laparoscopic pancreatoduodenectomies (LPDE) were performed by single surgical team. Total Clavien-Dindo IIIa-V complications rate was 31,8% (80 patients). Objective is to assess the short-term and long-term outcomes of LPDE performed in patients with pancreatic head and periampullary area diseases and to reveal the risk factors for having the Clavien-Dindo IIIa-V complication.

Methods: 250 patients underwent LPDE during last 10 years. Among 230 patients 138 were females and 112 were males. Mean age was 60 years (range 29-82). 216 patients were operated on because of malignancies and 34 because of benign diseases. Postoperative complications including pancreatic fistula (PF) and biliary leak (BL), delayed gastric emptying (DGE) and postpancreatectomy hemorrhage (PPH) were analyzed.

Results: Mean operative time was 412 (range 240-875) min and mean blood loss was 350 (range 10-2100)ml. The Postoperative course of 31,8% of patients was complicated by Clavien-Dindo IIIa-V complication. Among them IIIa – 21,9%, IIIb – 7%, IV – 0,45%, V – 5,6%. Clinically relevant postoperative pancreatic fistulas were diagnosed in total of 13,4% patients, among them 11% were classified as grade B POPF and 2,4 as grade C. The PF rate during the first 100 procedures was 21% and decreased to the 8,2% in last 150 procedures. Patients with ampullary carcinoma and distal cholangiocarcinoma more likely were in group of complicated patients: 28,9% and 22,7% versus 7,1% in patients with pancreatic cancer. The BL was diagnosed in 6 patients (2,4%) who was in group of the first 100 procedures. DGE was dragnosed in 7% of patients. Negative trend was revealed over the 250 procedures: the frequency decreased to 4,2% in last 150 procedures with slight modification of technique. PPH complicates the postoperative course of 11 patients

(4,4%). Nine of them had concomitant PF.

Conclusion: Patients with ampullary carcinoma and distal cholangiocarcinoma are at risk to have PF. Rate of PF, BL and DGE rates are higher during the learning curve. PF is the risk factor for having the postoperative hemorrhage.

184

ROBOTIC RECTAL RESECTION - FIRST EXPERIENCE

I. Khatkov, S. Pozdnyakov, A. Atroshchenko, M. Danilov, Z. Abdulatipova, G. Saakjan

The Loginov's Moscow Clinical and Scientific Center, Colorectal surgery Department, Moscow, Russia

Introduction: laparoscopic rectal resection remains technically challenging but feasible with proven oncological results. The introduction of the robotic proctectomy can overcome the negative impact of a narrow field of vision in a small pelvis, magnifying the autonomic nerves preservation and mesorectal fascial excision

Purpose: to outline the initial experience of the robotic surgery for an unselected range of benign and malignant rectal diseases.

Methods: prospective non-randomized single-center study that analyzed of 26 robotic rectal resection.

Results: the initial group included 10 females and 16 males (mean age 61.6 years), 2/3 of patients had significant comorbidities (median ASA score 4.5-5.5). All patients underwent robotic rectal resection among them: 23 for rectal cancer, 3-villous adenomas; TME performed in 19 with 6 patients undergoing a multivisceral resection. The mean operating time- 358 min.; mean blood loss- 203 mL. All mesorectal excision specimens were adjudged as Sate Grades Specifically with a mean of 18.5 lymph nodes identified. Lymph node metastases admitted in 10 patients (38.5%). The mean pain score was 2.1/10 on the visual analogue scale and 1.5/10 on the BPI. There were 3 patients with post-operative urinary difficulty. The median 10-day postoperative Wexner continence score-3.1 and a 6 month post-operative-1.6. One patient underwent early repeat surgery for an adhesive small bowel obstruction. The median length of hospital stay- 11 days

Conclusion: our initial experience of robotic rectal resection has shown it to be safe and feasible, particularly in patients where conventional laparoscopic rectal resection would be anticipated to be challenging

185

ROBOTIC RECTAL RESECTION: PRELIMINARY RUSSIAN EXPERIENCE

I. Khatkov, S. Pozdnyakov, A. Atroshchenko, M. Danilov, Z. Abdulatipova, I. Dolgopyatov, G. Saakjan, Y. Streltsov
"The Loginov's Moscow Clinical and Scientific Center", Colorectal surgery Department, Moscow, Russia

Purpose. To outline the preliminary experience of the da Vinci[®] robotic system used in a Moscow tertiary colorectal referral center for an unselected range of benign and malignant rectal conditions.

Methods. Prospective non-randomized single-center study which analyzed results of 26 robotic rectal resections performed between January 2014 and December 2016.

Results. The cohort included 10 females and 16 males (mean total age 61.6 years). Three patients underwent surgery for benign rectal villous adenomas. The median overall ASA score was 4 (ranged from 2 to 5). Of the surgeries, there were 19 total mesorectal excisions (TME) with 6 patients undergoing a multivisceral resection. The mean operating time was 358 minutes with a mean blood loss of 203 mL. All total mesorectal excision specimens were adjudged according Philip Quirke classification as Mesorectal plane – Grade 3 with a mean of 18.5 lymph nodes identified (from 12 to 35). Of these there were 10 patients (38.5%) with lymph node metastases. After surgery the average pain score was 2.1 out of 10 on the "Visual-Analogue Pain Intensity Scale" and 1.5 score out of 10 on the "Brief Pain Inventory with quality of life (QOL)". Anal continency after rectal resection with TME estimated according Wexner Scale: 10-days after surgery avarege score was -3.1 and a 6 month afte surgery -1.6 score. The median length of hospital stay was 11 days (from 10 to 15)

Conclusion. Our initial experience with a totally robotic rectal resection has shown the technique to be safe and feasible, particularly in patients where conventional laparoscopic rectal resection would be anticipated to be challenging.

186

MAPPING OF LOCAL RECURRENCE AFTER PANCREATICODUODENECTOMY FOR DISTAL EXTRAHEPATIC CHOLANGIOCARCINOMA: IMPLICATIONS FOR ADJUVANT RADIOTHERAPY

Kim Kyubo¹, Jung Wongeun¹, Jang Won Il²

¹Department of Radiation Oncology, Ewha Womans University College of Medicine

²Department of Radiation Oncology, Korea Institute of Radiological and Medical Sciences

Purpose: To generate a map of local recurrences after

pancreaticoduodenectomy (PD) for patients with resectable distal extrahepatic cholangiocarcinoma (DEHC) and to evaluate an adequate target volume coverage encompassing the majority of local recurrences for DEHC when the clinical target volume (CTV) for pancreatic cancer after PD was applied.

Methods: Records of DEHC patients who underwent PD and had postoperative computed tomography (CT) scans available between 1991 and 2015 were retrospectively reviewed. Patients were divided into three categories: no adjuvant therapy (NA), chemotherapy alone (CTA) and adjuvant radiotherapy (ART). The sites of local recurrence were delineated on individual CT scans, and then mapping was manually performed in relation to the portal vein, celiac axis, superior mesenteric artery, and renal vessels onto a template CT images. Coverage of each site of local recurrence was evaluated by applying the CTV defined according to Radiation Therapy Oncology Group (RTOG) consensus guidelines (CTVRTOG) for target delineation in the postoperative radiotherapy of pancreatic cancer.

Results: Of 99 patients, 31 (31.3%), 59 (59.6%), and 9 (9.1%) were included in the NA, CTA, and ART groups, respectively. Local recurrence occurred in 36 of 99 patients overall (36.4%) and in 10 (32.3%), 22 (37.3%), and 4 (11.1%) of the NA, CTA, and ART groups, respectively. Thirty six patients had a total of 62 local relapses identifiable by postoperative CT scans: PD bed in 13 (21.0%), para-aortic lymph nodes in 10 (16.1%), choledochojejunostomy sites in 11 (17.7%), and portal vein area in 9 (14.5%). Twenty one sites (33.9%) were not fully covered by the CTVRTOG and the most common site of local recurrence outside CTVRTOG was choledochojejunostomy site.

Conclusions: Mapping of local relapses evaluated according to the CTVRTOG suggests that relapses of the choledochojejunostomy site need be covered by applying additional margin to the anastomosis. These findings may help to construct a target volume for adjuvant radiotherapy in DEHC.

187

HEPATOBIILIARY SCINTIGRAPHY IN ESTIMATION OF THE FUNCTIONAL RESERVE FOR THE LIVER RESECTION

P. Kim, L. Bondar, M. Efanov, R. Alikhanov

The Loginov Moscow Clinical Scientific Center, Russia

Aim: to assess the role of hepatobiliary scintigraphy for prognosis of posthepatectomy liver failure (PHLF); to determine threshold index of hepatic uptake (IHU) of radioactive agent as an indication for surgical prevention of PHLF.

Material and Methods. The study included two groups of patients who underwent hepatobiliary scintigraphy. The 1st group consisted of 53 patients with diffuse liver diseases (chronic hepatitis, liver cirrhosis) in whom histological examination of liver was performed according to METAVIR. Ninety six patients with liver tumors underwent advanced liver

resections (>3 segments by Couinaud). Criteria for PHLF were elevated levels of bilirubin (> 145%) and INR (> 35%) from the baseline on the 5th day of the postoperative period. According to hepatobiliary scintigraphy IHU and scintigraphy volume as a sign of PHLF formed a model of logistic regression is obtained: $PHLF = 17.49 - 0.29 * SG - 5.98 * IHU + 0.09 * SG * IHU$. IHU - index of hepatic uptake. SG - scintigraphy volume of the remnant

Results. The highest median of IHU (2,7±0,6) was revealed in patients with liver fibrosis F0-3, the lowest (2,04±0,2) - in patients with liver fibrosis F4. Threshold value of IHU was 2,4. In 18 patients with IHU 2,4 and remnant liver 40% surgical prevention of PHLF was performed: portal vein ligation (1), portal embolization (12), percutaneous embolization with radiofrequency ablation along the plane of future liver dissection (5). An increase of IHU up to 2.7 ± 0.47 was revealed in the area of liver regeneration and hypertrophy in 14-21 days after surgery.

Conclusions: Dynamic hepatobiliary scintigraphy can be used as non-invasive assessment of the safety of the functional reserve at the preoperative stage. The developed model is useful for pre-operatively evaluation the probability of PHLF.

188

SCINTIGRAPHY METHOD IN ESTIMATION OF THE FUNCTIONAL RESERVE OF THE LIVER IN SURGICAL HEPATOLOGY

P. Kim, L. Bondar, M. Efanov, R. Alikhanov

The Loginov Moscow Clinical Scientific Center, Russia

Aim: to assess the role of hepatobiliary scintigraphy for prognosis of hepatic failure after liver resection; to determine threshold index of hepatic uptake of radioactive agent as an indication for surgical prevention of hepatic failure.

Material and Methods. From June 2014 to April 2018 in Moscow Clinical Research Centre were observed 149 patients with different pathology of the liver. The study included 2 groups of patients who underwent hepatobiliary scintigraphy. The 1st group consisted of 53 patients with diffuse liver diseases (chronic hepatitis, liver cirrhosis) in whom histological examination of liver was performed according to METAVIR. 96 patients with liver tumors underwent advanced liver resections (over 3 segments by Couinaud).

Results. The highest median of hepatic uptake (2,7±0,6) was revealed in patients with liver fibrosis F0-3, the lowest (2,04±0,2) - in patients with liver fibrosis F4. Threshold value of hepatic uptake was 2,4. In 18 patients with hepatic uptake index 2,4 and remnant liver 40% surgical prevention of hepatic failure was performed: portal vein ligation (1), portal embolization (12), percutaneous embolization with radiofrequency ablation along the plane of future liver dissection (5). An increase of hepatic uptake index up to 2.7 ± 0.47 was revealed in the areas of liver regeneration and hypertrophy

in 14-21 days after surgery.

Conclusion. Criteria for PHLF were elevated levels of bilirubin (> 145%) and INR (> 35%) from the baseline on the 5th day of the postoperative period. According to hepatobiliary scintigraphy IPZ and scintigraphy volume as a sign of PHLF formed a model of logistic regression is obtained: $PHLF = 17.49 - 0.29 * SG - 5.98 * LUI + 0.09 * SG * LUI$. LUI – liver uptake index. SG - scintigraphy volume of the remnant

Conclusions: Dynamic hepatobiliary scintigraphy can be used as non-invasive assessment of the safety of the functional reserve at the preoperative stage. Static and dynamic hepatobiliary scintigraphy allows a comprehensive assessment of the volume and status of the function of various liver fragments. The developed model allows us to pre-operatively evaluate the probability of an increase in the level of bilirubin and INR in patients who are scheduled for extensive liver resections, but it requires additional prospective evaluation.

189

APPLICATION OF THE PARIETAL BONE AUTOGRAFTS IATROGENIC DEFECTS IN THE PLASTIC OF THE FRONT WALL OF FRONTAL SINUS CHRONIC SINUSITIS

I. Kirichenko¹, A. Karayan², K. Shumov², N. Subbotina²

¹*Peoples, Friendship University of Russian*

²*Research clinical center of otorhinolaryngology Federal Medical Biological Agency*

The importance of the reconstruction of the anterior wall of the frontal sinus after external surgical interventions is determined by the complexity of reconstructing the shape of the anterior wall of the frontal sinus without a cosmetic defect and ensuring tightness of the sinus. Bone parietal autografts give the best result when plastics large defects in the anterior wall of the frontal sinus due to their convex-concave form and the possibility of collecting a sufficient amount of material. Resorption of bone after plastic surgery is not more than 15-20% of the total weight of the established graft. This property is based on the features of embryonic development. The dark bone belongs to the primary, endemic bone and is formed directly from the mesenchyme, bypassing the stage of the hyaline cartilage model. The split bone graft is taken directly from the patient, which facilitates its engraftment. The defect formed at the site of the transplant pick-up is small, it is covered with hair and is hardly noticeable.

Purpose. Determine the effectiveness of the use of parietal autografts in the plastic of iatrogenic defects of the anterior wall of the frontal sinus

Materials and methods. Our method of sampling split parietal autografts, characterized by the use of oscillating saws and diamond disks to cut the bone block, allowing safe and economical collection of donor material without the use of bits and a hammer in strictly established and verified

parts of the parietal bone. In 2017, we operated on 6 patients with previous operations external access to the frontal sinuses and defect the anterior wall of the frontal sinuses with the formation of deforming cicatrix, 2 men and 4 women aged 23 to 57 years, in two cases with the formation of purulent fistula in the scar area. According to the computer spiral tomography of the paranasal sinuses, all patients had a block of frontal recess, osteitis and increase in thickness of the frontal sinus walls. We used bicoronal access to the anterior wall of the frontal sinuses, this access makes it possible to radically excise scar tissue in the area of the sinus revision without the formation of an external incision of this zone and to take a parietal autografts of the required size for the plasticity of the defect. We simultaneously performed the correction of intranasal structures under the control of the endoscope. The size of the transplant was measured in advance, taking into account the existing updated defect of the front wall. In three cases, stenting of this zone with individually manufactured stents according to the original technique was performed to prevent narrowing of the frontal recess.

Results. The desired cosmetic effect persisted in all patients one year after the operation, inflammatory events in the ONP were repeated only in one patient with severe osteitis against a background of prolonged inflammation in the frontal sinus and restenosis of the frontal recess.

Conclusions. The technique of plasty of iatrogenic defects of the anterior wall of the frontal sinus with the use of parietal autografts can provide a stable and positive functional and cosmetic result in an integrated approach to the treatment of chronic inflammation in the paranasal sinuses.

190

COMPARISON OF STAPLED AND HAND-SEWN SLEEVE GASTRECTOMY

Serdar Kirmizi, Cuneyt Kayaalp, Servet Karagul, Ismail Ertugrul, Ali Tardu, Fatih Sumer

Department of Gastrointestinal Surgery, Faculty of Medicine, Inonu University, Malatya 44315, Turkey

Aim: Sleeve gastrectomy is a stapler dependent bariatric procedure. A hand-sewn sleeve gastrectomy can be necessary in certain circumstances. Here, we aimed to compare the outcomes of hand-sewn and stapled sleeve gastrectomies for the first time.

Material-Method: In the hand-sewn group, no staplers were used and after vertical resection of the stomach by energy devices and remnant stomach was closed in two rows intracorporeal sutures. In stapler group was contracted by the usual way.

Results: Total 13 patients were compared (hand-sewn:6 and stapled: 7). All the sleeve gastrectomies completed laparoscopically. The operating time was longer (200±68 vs. 135±51

min., $p:0.07$) and amount of bleeding was higher (108 ± 49 vs. 33 ± 11 ml., $p:0.004$) in the hand-sewn group. There was postoperative complication in the hand-sewn group (leak and gastrointestinal bleeding) but no in the stapler group. Metabolic outcomes and excess of body mass index loss (EBMIL) were similar after one and three years follow-up (EMBIL% 68.1 vs. 74.3 and 52.9 vs. 60).

Conclusion: Laparoscopic hand-sewn sleeve gastrectomy can be an alternative procedure to stapled sleeve gastrectomy in certain circumstances. Longer procedure time and more blood loss were associated with hand-sewn sleeve gastrectomy.

191

MANAGEMENT OF EXTRAHEPATIC PORTAL HYPERTENSION CAUSED BY EXTRAHEPATIC PORTAL VEIN OBSTRUCTION

E. Kitsenko, G. Manukyan, V. Lebezev, E. Fandeyev, E. Kosakevich

Federal State Budgetary Scientific Institution B. V. Petrovskiy Russian National Research Center of Surgery, Moscow, Russia

Relevance. Extrahepatic portal vein obstruction (EHPVO) is the 2-nd most common etiological factor of portal hypertension in adults (after liver cirrhosis). Polyetiological character of the disease determines the need for detailed analysis of thrombosis risk factors and management of patients, primarily, taking to account the etiology of EHPVO and the presence of a prothrombotic statement.

Aim. Improvement of treatment and surgical care in patients with extrahepatic portal hypertension caused by EHPVO.

Materials and Methods. A retrospective analysis of 325 patients with EHPVO was performed in the period from 2007 to 2017: 171 women (52.6%) and 154 men (47.4%). The age was from 18 to 75 years (median – 35.3 years). There were 96 patients who suffered since their childhood (29.5%). The disease manifested in adulthood in 229 patients (70.5%), furthermore, in 94 adult patients (28.9%) chronic myeloproliferative disease (CMPD) was diagnosed. The spectrum of diagnostic examination included detection and analysis of various local and systemic risk factors for EHPVO. “Side-to-side” mesentericocaval or splenorenal shunting (direct or with synthetic graft interposition) was performed in 110 patients (33.9%) for the prevention of variceal (re)bleeding. Total thrombosis of the portal system in 214 patients (65.9%) was the impending factor for shunting surgery. These patients were treated by endoscopic band ligation of varices – 95 patients (29.2%). Or, in case of large diameter of gastric varices (>15 mm), gastric devascularisation with direct surgical ligation of varices was performed – 120 patients (36.9%). In the postoperative period all the patients received long-term anticoagulation with low-

molecular heparin and succeeding conversion to oral intake of direct thrombin inhibitors or direct factor Xa inhibitors.

Results. The spectrum of local and systemic risk factors included hereditary thrombophilia – 127 patients (39%): 32 (9.8%) with factor V Leiden polymorphism, 9 with prothrombin gene mutation (2.8%), 32 patients (9.8%) with hereditary deficiency of natural anticoagulants (antithrombin, protein C and protein S: 12 (3.7%), 16 (4.9%) and 4 (1.2%), respectively); 49 patients (15.1%) homozygous polymorphism of plasminogen activator inhibitor (PAI-1), hyperhomocysteinemia associated with methylene tetrahydrofolate reductase (MTHFR) gene mutations was detected in 14 patients (4.3%). Acquired thrombophilia was detected in 116 patients (35.1%): CMPD in 94 patients (28.9%), antiphospholipid syndrome in 19 patients (5.8%) and paroxysmal nocturnal hemoglobinuria in 3 patients (1%). Local risk factors of EHPVT (inflammatory abdominal diseases, abdominal trauma, surgical intervention etc.) were discovered in 104 patients (32%). There was no mortality in the nearest postoperative period. The main complications of both nearest and long-term postoperative period were hemorrhagic (erosive and variceal bleeding) and thromboembolic (including recurrent thrombosis in the portal system, pulmonary thromboembolism etc.). Five- and 10-year survival rates were 97.6% and 92.8%, respectively. These complications occurred during the long-term follow-up, mainly, in patients who refused anticoagulation (including 2 patients who developed a lethal outcome).

Conclusion. The choice of management strategy in patients with extrahepatic portal hypertension caused by EHPVO should be based on etiological risk factors. The presence of a prothrombotic statement in patients with EHPVO increases the risk of recurrent thrombosis in the portal system and other localizations. Long-term anticoagulation decreases the frequency of hemorrhagic complications such as variceal rebleeding (from 22.5% to 6.1%) and thromboembolic complications (from 51.55 to 9.2%) during the long-term follow-up ($p < 0.05$). Rejection of antithrombotic prophylaxy reduces the effectiveness of the surgery and can sharply worsen the prognosis.

192

CHANGES IN THE HEMOSTATIC SYSTEM IN PATIENTS WITH ULCERATIVE COLITIS DEPENDING ON THE DEGREE OF ACTIVITY OF THE DISEASE

O. Knyazev, A. Kagramanova, A. Lishchinskaya, G. Dudina, N. Fadeeva, K. Noskova, V. Subbotin, A. Parfenov

Moscow Clinical Scientific Center named after A. S. Loginov, Russia

Patients with inflammatory bowel disease (IBD) showed more frequent development of thromboembolic complica-

tions, compared with the general population. To identify changes in the hemostatic system in patients with ulcerative colitis, depending on the degree of activity of the disease. The study included 15 patients with total lesions, who were divided into three groups, depending on the degree of activity of the disease on the meio scale. The 1st group of patients was in remission, the 2nd group of patients with UC had moderate activity of the disease, the 3rd group-high. The state of the blood coagulation system of the patients was assessed by the method of extended coagulogram (prothrombin by Kvik, antithrombin III, protein S, factors VII and VIII) and using the method of thromboelastography (TEG). Patients were excluded hereditary coagulopathy. In all three groups of patients with UC, according to the extended coagulogram, no changes in the indicators typical for the disorders of the blood coagulation system were revealed. According to the TEG data in group 1, the time from the beginning of clot formation to the achievement of a fixed level of clot strength (amplitude = 20 mm) (K) was on average 3.7 minutes, an increase in the angle built tangentially to the thromboelastogram from the point of clot formation (Angle) to 48.9, the maximum amplitude characterizing the maximum dynamic properties of the fibrin and platelets compound by GPIIb/IIIa receptors (MA) to 57.9 mm. In the 2nd group, the time from the beginning of clot formation to the achievement of a fixed level of clot strength (amplitude = 20 mm) (K) was on average 2.45 min, an increase in the angle built tangentially to the thromboelastogram from the point of clot formation (Angle) to 58.9, the maximum amplitude characterizing the maximum dynamic properties of the fibrin and platelet compounds by GPIIb/IIIa receptors (MA) to 63.05 mm. In group 3, the time from the beginning of clot formation to the achievement of a fixed level of clot strength (amplitude = 20 mm) (K) was on average 2.92 min, an increase in the angle built tangentially to the thromboelastogram from the point of clot formation (Angle) to 63.9, the maximum amplitude characterizing the maximum dynamic properties of the fibrin and platelets compound by GPIIb/IIIa receptors (MA) to 71.24 mm. The method of thromboelastography is a more sensitive method for detecting hemostatic disorders in patients with ulcerative colitis, compared with a standard coagulogram. According to thromboelastography in patients with ulcerative colitis there is a hypercoagulation state of the blood system, regardless of the activity of the inflammatory process. The degree of hypercoagulation increases with the activity of the disease.

193

ORGANIZATIONAL PRINCIPLES OF FIELD STAGING ADJUVANT OZONE THERAPY

V. Knyazev

Military Clinical Hospital, Special Task Medical Detachment of Moscow Region of the Russian Federation, Dolgoprudny Clinical Hospital of Federal Government Health Institution "Medical Unit of MIA of Russia in Moscow city", Moscow, Russia

In the trauma surgery of present day, the ozone therapy is presented as an option of adjuvant treatment-evacuative support. The material includes the best practices and other authors' data on staging surgical approach of battle wounds and injuries. The combination of local infiltration and regional ozone therapy with an ozone concentration of 1.0-3.0 mg/l blocks the tissue hypoxia, ischemia, sludge, and hypertensive compartment syndrome. The range of emergency aid for the wounded and injured defines the stage of treatment-evacuative support. The paramount importance has the urgent delivery of the wounded and injured to the stages of medical care having the urgent ozone therapy in the form of blockades which simultaneously complements the surgical aid. On the advanced points, it is necessary to carry out the local ozone blockades. In the reception and sorting module of field hospitals at the stage of qualified care during the primary surgical treatment, the sectional saturation of tissues with ozone accompanies the main elements of the debridement: discission, extirpation, fasciotomy, drainon a step-by-step basis. In the in-patient hospitals of specialized base hospitals and traumatic centers, the ozone therapy can be used in complex treatment as a sorption method of detoxification. By the bandaging and surgical treatments, the wound cavities are drained with the active ozonation, by closing of tissue with ozonized oil. The treatment is supported by the chambered aerations with the ozone-aseptic environment. Thus, at all stages, along with the surgical aid, the ozonation systematic method is successively implemented. By influencing the general and local stages of the wound process the conditions for morphological zones regression are formed. Forming the effect of hydro-preparation, vacuum, antiseptic, adsorbent and drainage, the ozone-surgical debridement acquires the status of military-field ozone therapy in providing of urgent assistance during the evacuation stages.

194**LAPAROSCOPIC PYELOLITHOTOMY FOR STAGHORN RENAL STONES****A. Kochkin, E. Gallyamov, F. Sevryukov, E. Gallyamov, G. Gololobov**¹*Urological Center of Russian Railways Hospital, Nizhny Novgorod, Russia*²*«Privolzhskiy Research Medical University», Nizhny Novgorod, Russia*³*I.M. Sechenov First Moscow State Medical University of Minzdrav of Russia (Sechenov University), Moscow, Russia*⁴*Federal State Institution «Federal Scientific and Clinical Center for Specialized Methods of Medical Care and Medical Technologies» - the Federal Medical Biological Agency, Moscow, Russia***Aim.** The present work studies the effectiveness and safety of laparoscopic pyelolithotomy (PL) in surgery of Staghorn nephrolithiasis.**Materials and methods.** Conducted a multicenter retrospective analysis of the results of the PL, made 2010 to 2017 y. Inclusion criteria: patients with staghorn calculi undergoing laparoscopic pyelolithotomy alternatively PNL. The frequency and structure of intra - and postoperative complications, the causes of access conversions, as well as the duration of surgery and inpatient treatment were evaluated; degree of elimination of stones.**Results.** The inclusion criteria were met by 137 patients, 78 of them (56.93%) men. There was no lethality and no access to conversions. Intraoperative complications occurred twice (1.46%). The duration of the intervention was 130 [100;150] minutes with the volume of blood loss of 150 [100; 200] ml; the need for blood transfusion has not arisen even once. The total rate of postoperative complications reached 5.11%. The degree of elimination of stones is 86.13%. Median postoperative hospital stays of patients - 7 [7; 11] days.**Discussion.** Urolithiasis remains the most common disease in urology. Absolute standard of treatment for large kidney stones percutaneous nephrolithotomy remains. However, its low efficiency with dense coral-like lithium does not allow to completely abandon traditional interventions. The study demonstrated the efficacy and safety of laparoscopic pyelolithotomy when the Staghorn nephrolithiasis.**Conclusion.** In the presence of a dense coral Cup spurs which correspond to the diameter of their necks, are located in the large "application of the" pelvis, laparoscopic pyelolithotomy is an alternative to not only "open", but percutaneous intervention.**195****LAPAROSCOPIC SURGERY OF HORSESHOE KIDNEY TUMORS****A. Kochkin^{1,2}, E. Galliamov³, A. Sanzharov⁴, V. Sergeev⁵, F. Sevryukov^{1,2}**¹*Urological Center of Russian Railways Hospital, Nizhny Novgorod, Russia*²*«Privolzhskiy Research Medical University», Nizhny Novgorod, Russia*³*Federal State Autonomous Educational Institution of Higher Education I.M. Sechenov First Moscow State Medical University of the Ministry of Health of the Russian Federation (Sechenov University), Moscow, Russia*⁴*Federal Scientific Clinical Center FMBA of Russia, Moscow, Russia*⁵*A.I. Burnazyan Federal Medical Biophysical Center FMBA of Russia, Moscow, Russia***Introduction.** Tumors of the horseshoe kidney (THK) - an extremely rare pathology. In PubMed, we found only 3 references to laparoscopic resections and several "clinical observations" on laparoscopic heminephrectomy in THK.**Materials and methods.** A multicenter retrospective analysis of the results of treatment of patients with THK, subjected to laparoscopic resection or heminephrectomy. Evaluated intra - and postoperative complications, especially istratii, duration of surgery and inpatient treatment. 19 patients from 27 to 62 years (9 men) met the inclusion criteria. Body mass index-from 27 to 36 kg/m². In 10 patients, the tumor was localized on the left. Made 11 gaminiratne (6 left). Eight patients underwent renal resection. In one case, it was possible to perform a standard resection, regardless of the features of the structure of the body. Other observations were performed segmental resection of one half of a horseshoe, periodically, together with the isthmus and the lower group of cups, compressed by the tumor (videoproto - <https://youtu.be/nk-WlBjNtIs>). Isthmotomia produced in 15 operations. In one observation made isterectomy with tumors of the isthmus.**Results and discussion.** No conversions. The maximum time of thermal ischemia of the kidney with its resection reached 19 minutes. Intra-and postoperative complications were avoided. Operation time-from 130 to 270 minutes. The terms of postoperative hospital stay of patients did not exceed 8 days. The minimum period of postoperative follow - up was 6 months-there were no data for relapse or progression of the disease.**Conclusion.** The first own experience demonstrated not only the possibility of technical execution, but also the effectiveness of laparoscopic heminephrectomy and resection in tumors of the horseshoe kidney parenchyma.

196**LAPAROSCOPIC ILEAL URETERAL SUBSTITUTION. FIRST 40 CASES RESULTS****A. Kochkin^{1,2}, E. Gallyamov³, S. Popov⁴, R. Biktimirov⁵, A. Sanzharov⁶**¹*Urological Center of Russian Railways Hospital, Nizhny Novgorod, Russia*²*«Privolzhskiy Research Medical University», Nizhny Novgorod, Russia*³*Federal State Autonomous Educational Institution of Higher Education I.M. Sechenov First Moscow State Medical University of the Ministry of Health of the Russian Federation (Sechenov University), Moscow, Russia*⁴*St. Luke's Clinical Hospital, St. Petersburg, Russia*⁵*Federal Clinical Center for High Medical Technologies FMBA of Russia, Moscow Region, Khimki, Russia*⁶*Federal Scientific Clinical Center FMBA of Russia, Moscow, Russia*

Introduction. Substitution intestinal plastic is the latest variant of the reconstructive surgery multiple and long strictures of the ureter. Here the analysis of our own series of laparoscopic substitution of intestinal plastics of ureters, made entirely intracorporal at term postoperative follow-up of 6 months to 7 years.

Materials and methods. Multisentr conducted a retrospective analysis of the results of reconstructive procedures undertaken in 2010 to 2017 at a pathology, requiring replacement of the ureter. Inclusion criteria: patients undergoing laparoscopic uni - or bilateral substitution ureteroplasty preconfiguring a fragment of the ileum. Exclusion criteria: patients undergoing laparoscopic appendiceal, fat or small bowel plasty reconfigured segments, and their combination with a Boari flap. There were no restrictions on gender, age, body weight or others. Studied the etiology of the long strictures and obliterate of the ureter. The frequency and structure of intra - and postoperative complications, causes of access conversions, duration of operation and hospital stay of patients were determined. The functional results were evaluated by excretory urography or tomography, which was performed every six months after the surgery.

Results. 40 patients met the inclusion criteria, 23 (57.5%) of them were women. The average age is 48.4 (27-70) years, and the BMI is 29.3 (23-40) kg/m². Bilateral replacement was performed in 8 patients, unilateral – in 32 (20 on the right). The most common indications for the operation were long strictures and ureter obliteration, which were complications of endourological interventions in the upper urinary tract and radiation therapy. Such patients in our study were 13 and 11, respectively. The average duration of intervention was 335 (150-680) min. with the volume of blood loss of 221 (50-400) ml; the need for hemotransfusion has not arisen even once. Intraoperative complications occurred three times (7.5%) - were eliminated laparoscopically. Conversion of access and mortality was avoided.

Postoperative complications of Clavien III is marked by three (7,5%) Average duration of hospital treatment of patients - 13.5 cm (10-35) days. During this time, we achieved full rehabilitation and removal of all drains, including internal stents. After examining the catamnesis of 36 patients from 6 months to 7 years, we did not find any delayed complications, significant metabolic or urodynamic disorders, as well as inhibition of renal function.

Conclusion. The presented material is the largest available in the literature, and the results, including long-term functional outcomes, demonstrate the effectiveness and safety of laparoscopic technologies in the treatment of this category of patients. Regardless of the access – open or laparoscopic – total substitution of intestinal plastics of ureters remains a rare and technically complex intervention, combining a thousand of nuances and a lot of pitfalls.

197**ENDOVASCULAR EMBOLIZATION IN TREATMENT OF PANCREATIC BLEEDINGS****I. Kochmashev, V. Sherstobitov, M. Prudkov, J. Mansurov**
Russia

Relevance. Pancreatic bleeding is a very dangerous complication of chronic pancreatitis and pancreatic surgery. Despite advances in surgical techniques it still carries substantial morbidity and mortality. Endovascular embolization has become a viable alternative to open surgical hemostasis. Object. To analyze experience of endovascular embolization in 54 patients with pancreatic bleedings treated with from March 2012 to July 2018.

Materials and methods. Overall, 56 embolization procedures were performed in 54 patients from March 2012 to July 2018. Causes of bleeding were: complications of pancreatic surgery in 9 patients, acute pancreatitis in 14 patients, complications of chronic pancreatitis in 31 patients and pancreatic tumor in 1 patient. Clinically bleeding site was located in gastrointestinal tract lumen in 19 patients, in pancreatic cyst - 7 patients, retroperitoneum in 2 patients, in abdominal cavity in 6 patients, in postoperative wound in 2 patients. 6 patients had combined variants of bleeding. In the majority of cases bleeding source was detected on contrast-enhanced computed tomography by direct and indirect signs. In hemodynamically unstable angiography was the imaging modality of choice. The bleeding source was located in splenic artery in 22 patients, in gastroduodenal artery in 13 patients, in pancreatoduodenal arteries in 5 patients. Left and right hepatic, left gastric, cystic, lumbar and colic arteries were bleeding sources in the rest of cases. In one patient experienced variceal bleeding from gastric varices after splenic vein occlusion. Embolization was performed after superselective catheterization with microcatheters. Coils were the most common embolization agent.

Results. Technical success was achieved in all 54 patients. 2 patients had recurrence of bleeding in 30 days period after embolization. In one case rebleeding occurred due to arrosion of the vessel distal to the covered stent, in the second case due to transcollateral filling of the vessel defect. Repeated embolization stopped the bleeding in both cases. Complication occurred in one case when colic ischemia was caused by middle colic artery embolization.

Conclusions. In our experience endovascular embolization appears to be a safe, effective, minimally invasive method in management of pancreatic bleedings. Complication rate was low. A multidisciplinary approach and optimization of management protocols and patient logistics are essential.

198

EMBOUZATION OF GASTRO-ESOPHAGEAL VARICES IN PATIENTS WITH VARICEAL BLEEDING

I. Kochmashev, V. Sherstobitov, M. Prudkov, J. Mansurov
Russia

Variceal bleeding is the leading cause of mortality in patients with portal hypertension. TIPS has become a standard treatment for this life-threatening condition, however this option can be too risky in some patient due to severe hepatic encephalopathy or technical considerations. Different techniques of obliteration of gastro-esophageal varices has shown to be an viable alternative to TIPS in selected patients. To evaluate efficacy of variceal embolization for acute variceal bleeding in patients in portal hypertension. From May 2013 to June 2018 51 procedures were performed in 40 patients with variceal bleedings due to portal hypertension of different origin. Our group included: 28 patients with liver cirrhosis; 7 patient with portal vein occlusion; 5 patients with recurrent variceal bleeding due to splenic vein thrombosis.

Interventions: Balloon-occluded retrograde transvenous obliteration (BRTO) – 5. Balloon-occluded antegrade transvenous obliteration (BATO) – 27. Splenic embolization – 24. Portal vein stenting – 4. Transjugular intrahepatic portosystemic shunt – 5. Procedures were carefully planning after multiphase contrast-enhanced CT. For the access to the portal vein transhepatic and transsplenic approaches were used. Parenchymal tract was embolized with gel foam and colis. An ileocolic vein approach was performed through a mini-laparotomy in two patients. BRTO procedures were performed though gastorenal shut. Transfemoral and transjugular approaches were used for gastorenal shunt catheterization. Cone-beam CT arterial portography via splenic artery was developed as the method to obtain detailed information about anatomy and afferent and efferent routes of the varices. Combination 3% Polidicanol foam (1:4), NBCA glue, coils and gel foam were used for

variceal embolization. Microparticles were used for splenic embolization after splenic artery catheterization via transfemoral and transradial approach. Technical success was achieved in 100% of cases. The main endpoint was cessation of the bleeding. Clinical success was achieved in 94%. Rebleeding occurred in 3 patients after incomplete embolization of the varices. Complications occurred in 13% of cases: 1 death in after TIPS due to rebleeding. Haemorrhagic complications of the transsplenic approach in 3 patients (1 - splenectomy, 2 – haematoma drainage). Complications of splenic embolization: portal vein thrombosis – 1, splenic abscess – 2. Cerebral air embolism after sclerosant foam injection with complete regression of symptoms in patient with patent foramen ovale. Variceal embolization combined with other endovascular techniques was considered to be an relatively safe and effective technique in treatment of acute variceal bleeding.

199

NECTIN-1 EXPRESSION IN COLORECTAL CANCER CELLS IS ASSOCIATED WITH EARLY DISEASE RECURRENCE

Kontzoglou Konstantinos¹, Tampaki Ekaterini Christina¹, Nonni Afrodite², Kostakis Ioannis D¹, Tsourouflis Gerasimos¹, Patsouris Efstratios², Kouraklis Gregory¹, Tampakis Athanasios^{1,3}

¹*B Department of Propaedeutic Surgery, Laiko General Hospital, School of Medicine, National and Kapodistrian University of Athens, Athens, Greece*

²*A Department of Pathology, School of Medicine, National and Kapodistrian University of Athens, Athens, Greece*

³*Department of General and Visceral Surgery, Basel University Hospital, Basel, Switzerland*

Background: Colorectal cancer remains the second leading cause of cancer-associated death among western societies. Although surgical resection with adjuvant chemotherapy, when indicated, constitutes the cornerstone of therapy, recurrence of disease remains the major cause of mortality. Cancer stem cells represent a subpopulation of self-sustaining tumorigenic cells within tumors and are characterized from their ability to self-renew and therefore to promote the maintainance of the tumor. Interestingly, cancer stem cells are considered to be highly resistant to conventional chemotherapy and thus responsible for disease recurrence. Epithelial to mesenchymal transition is a major pathway that is considered to be involved in this process. Nectin-1 belongs to the family of nectins which are immunoglobulin-like cell adhesion molecules and regulate the formation of various types of cell-cell junctions between adjacent epithelial cells and fibroblasts. In various types of cancer nectin expression has been associated with the EMT pathway and mediates cell proliferation. The role of nectin in colorectal cancer to date remains unknown.

The aim of this study was to investigate the expression of nectin in colorectal cancer patients and its impact on disease recurrence.

Patients and Methods: 111 patient specimens with colorectal cancer were analyzed by immunohistochemistry to investigate the expression patterns of nectin-1 in colorectal cancer. Results were correlated with clinicopathological data. Disease free survival was defined as the primary outcome of the study to assess the impact of nectin-1 on disease progression.

Results: High expression of Nectin-1 was demonstrated in 59.46% of the specimens. Nectin-1 was expressed in colorectal cancer cells. High expression of Nectin-1 was significantly associated with the stage of disease ($P=0.035$) and the presence of lymph node metastasis ($P=0.009$). No correlation was observed with the T stage ($P=0.286$), the presence of distant metastasis ($P=1.00$), the grade of cellular differentiation ($P=0.827$) and the presence of vascular ($P=0.658$) or perineural ($P=0.736$) invasion. Analysis of the Kaplan Meier curves revealed a significant lower 5-year disease free survival ($P=0.028$) in patients with high expression of Nectin-1 (57.7%; 95%CI=52-76% vs 80.6%;95%CI= 72-95%). Interestingly, in the first 27 months after surgery, recurrence occurred in 34.6% of patients with high Nectin-1 expression versus 14.7% of patients with low or no Nectin-1 expression.

Conclusion: Our results show for the first time that high Nectin-1 expression is associated with early disease recurrence in colorectal cancer occurring in a high rate in the first 28 months after surgery.

200

THE PRELIMINARY RESULTS OF ORGAN TRANSPLANTATION IN THE ROSTOV REGIONAL CLINICAL HOSPITAL

V. Korobka^{1,2}, M. Cherkasov², M. Kostykin¹, E. Pak¹

¹*The Rostov Regional Clinical Hospital, Rostov-on-Don, Russian Federation*

²*The Rostov State Medical University, Rostov-on-Don, Russian Federation*

Relevance. Organ transplantation is the best therapeutic modality for patient suffering from liver cirrhosis, end-stage forms of renal disease (ESRD), and heart failure.

Objectives. Analysis of the preliminary results of the organ transplantation program carried out in the Regional health care settings of the Rostov region.

Materials and methods. From July 2015 to June 2018, 84 organ transplants were performed: kidney – 55; liver – 25 (including split transplantation); heart – 4. Time for patients on waiting lists: for kidneys 10.11±6.23 months, liver – 9,78±5.42 months, the heart – 2.72±0.33 month. The average age of the operated patients was 42.18±13.07 years. Among the operated patients: men – 46 (54,76%), women – 38 (45,24%). Of total transplanted organs from Living

related donors 7 (8.33), from deceased – 77 (91.67). Indications for liver transplantation: PBC-8 (32.00%); Wilson's disease – 3 (12.00%); ADL – 5 (20.00%); chronic viral hepatitis (HCV – PPD, UVO 100%, HBV+HDV – Entecavir+Immunoglobulin) – 7 (28.00%); Hepatic sclerosis 2 (8.00%). Indications for kidney transplantation: Chronic nephritic syndrome -36 (65,85%); Congenital malformation of kidney, unspecified -7 (12,19%); polycystic kidney disease-3 (4,88%); systemic lupus erythematosus-3 (4,88%); Chronic tubulo-interstitial nephritis – 3 (4,88%); Renal dysplasia -1 (2,44%); Gout due to renal impairment, – 1 (2,44%); Drug induced Nephropathy – 1 (4,84%). 2.44%). Heart transplantation was performed in 4 patients with dilated cardiomyopathy.

Results. Out of 25 liver transplantation complications occurred in 6, Postoperative complications thrombosis of hepatic veins – 1; bile leak– 4; thrombosis of the common hepatic artery – 1. Re-operated-5. Out of 55 kidney recipients, 9 had delayed graft function one of them developed tubular necrosis requiring graft removal. Re-operation has a place in 3 patients. Recipients of the heart had no postoperative complications. The average time of hospital stay was 29,25±9.12 day. Early postoperative mortality was 1.19%. Among the complications and concomitant diseases recorded from 1.5 to 6 months after the operation: auto-immune return – 3, drug-induced nephropathy – 4, hypertension – 3, glucose tolerance – 2, obesity – 2, ileo-femoral thrombosis – 2, progression of systemic atherosclerosis – 1, fungal sepsis – 1, adenocarcinoma of the lung – 1, acute form of viral hepatitis A – 1. Currently, 77 patients under close follow up are in satisfactory condition, 58 of them returned to work, 5 – at the early postoperative stage, 14 – at the rehabilitation stage. The remote mortality rate is 4.82%.

Conclusion. A high percentage of complications and mortality, in our opinion, is associated with two main points: Learning curve of transplant surgery and the pre-existent severe somatic state of recipients with multiple comorbidities. To improve the quality of transplant care, in our opinion, a multidisciplinary approach is required for each patient with an individual selection of an immunosuppressive protocol and careful monitoring of the infectious status.

201

PREVENTION OF POSTOPERATIVE INTRA-ABDOMINAL SEPTIC COMPLICATIONS FOLLOWING PANCREATIC RESECTION

V. Korobka, R. Korobka, A. Shapovalov

¹*The Rostov Regional Clinical Hospital, Rostov-on-Don, Russian Federation*

²*The Rostov State Medical University, Rostov-on-Don, Russian Federation*

Relevance. Developing of pancreatic fistula and septic intra-

abdominal complications due to the failure of PJA are the leading life-threatening complications following pancreatic resections; they remain the main cause of death of 4.5-25% of patients.

Objective. To determine the advantage of using our sophisticated complex of surgical techniques including isolation of PJA to reduce intra-abdominal complications due to anastomotic leak and pancreatic fistula for patients who underwent pancreatic resection.

Materials and methods. 521 patients underwent pancreas resection for chronic pancreatitis (235) and pancreatic tumors (286). The number of operated patients: men - 272 (52.2%), women - 249 (47.8%). The average age is 56.4 ± 13.6 years. The main type of operation was pancreatoduodenal resection - 262, partial pancreatic resections - 126, Frey's procedure - 74, Beger's procedure - 59. In 479 (91.9%) cases, the procedure was completed with formation of PJA. In 214 (41.1%) cases, surgical treatment was performed using standard surgical techniques in the beginning of establishment of regional surgical center (group 1), in 307 (58.9%) a complex of surgical techniques including isolation of PJA (group 2) were used. Induction of inhibitors of proteolysis (gordoks or kontrikal) into Wirsung's duct - 67, enforcement of PJA and isolation of it zone (after Beger's procedure) with adequate drainage of omental bursa - 240.

Results. The results of the study were estimated by the presence or absence of postoperative necrotizing pancreatitis, leakage of PJA with subsequent development of pancreatic fistula and intra-abdominal purulent inflammation. In group 1, the number of patients with necrotizing of pancreatitis and the failure of PJA was 14 (6.5%), peritonitis - 12 (5.6%), with intra-abdominal abscesses - 8 (3.7%), phlegmonous collections - 16 (7, 5%). 13 patients were re-operated: diffuse peritonitis - 6, arrosive bleeding - 3, intra-abdominal abscesses - 4. In group 2 Necrotizing pancreatitis - 8 (2.6%), leakage of PJA - 11 (3.5%), No patient was operated for peritonitis, or abscess formation. Two people were re-operated - for arrosive bleeding. Early postoperative mortality in group 1 was 4.2% (9 patients), in group 2 - 0.7% (3 patients).

Conclusion. The complex of proposed surgical techniques including enforcement of PJA, isolation of resected pancreatic stump in combination with induction of inhibitors of proteolysis has shown to reduce the number of postoperative intra-abdominal complications due to necrotizing pancreatitis, anastomotic leak and subsequently decrease the mortality rate significantly.

²*The Rostov State Medical University, Rostov-on-Don, Russian Federation*

Relevance. Due to the increasing number of patients with cirrhosis, terminal forms of renal and heart failure, the organ transplantation becomes the most favorable radical method of treatment.

Aim. The analysis of the first results of the organ transplantation program performed at the Rostov Regional Clinical Hospital.

Materials and methods. From July 2015 through June 2018, we performed 84 organ transplantations: kidney - 55; liver - 25 (including split-transplantation); heart - 4. The mean time on the transplant wait list for kidney was 10.11 ± 6.23 months, for liver - 9.78 ± 5.42 months, for heart - 2.72 ± 0.33 months. The mean age of the recipients was 42.18 ± 13.07 years. Among the operated patients: men - 46 (54.76%), women - 38 (45.24%). Indications for liver transplantation: PBC - 8 (32.00%); Wilson's disease - 3 (12.00%); alcohol induced cirrhosis - 5 (20.00%); viral hepatitis (HCV – direct-acting antivirals, sustained virologic response 100%, HBV + HDV - Entecavir + Immunoglobulin) - 7 (28.00%); sclerosing cholangitis 2 (8.00%). Indications for kidney transplantation: chronic glomerulonephritis - 36 (65.85%); anomalies of kidney development - 7 (12.19%); polycystic kidney disease - 3 (4.88%); systemic lupus erythematosus - 3 (4.88%); tubulointerstitial nephritis - 3 (4.88%); multicystic dysplasia - 1 (2.44%); gouty nephropathy - 1 (2.44%); drug-induced glomerulonephritis - 1 (2.44%). Heart transplantation was performed in 4 patients with dilated cardiomyopathy.

Results. All the operations were in regular mode. Of 25 liver recipients, 7 complications occurred in the postoperative period: thrombosis of the hepatic veins - 1; biliary complications - 4; thrombosis of the common hepatic artery - 1. Reoperated - 5. Out of 55 kidney recipients, 9 had delayed graft function (1 - tubular necrosis - transplant removal). Reoperated - 3. Heart recipients had no postoperative complications. The mean length of stay at the hospital was 29.25 ± 9.12 days. Early postoperative mortality was 1.19%. Among complications and concomitant diseases recorded from 1.5 to 6 months after the operation: recurrence of the autoimmune disease - 3, drug-induced nephropathy - 4, arterial hypertension - 3, violation of glucose tolerance - 2, obesity - 2, ileo-femoral thrombosis - 2, generalization of systemic atherosclerosis - 1, fungal sepsis - 1, adenocarcinoma of the lung - 1, acute form of viral hepatitis A - 1. Currently, 77 patients are in satisfactory condition, 58 of them returned to work, 5 - discharge period, 14 - at the rehabilitation stage. The index of long-term mortality is 4.82%.

Conclusions. A high percentage of complications and lethality, in our opinion, is associated with two key points: the early stage of the development of liver transplantation and the initially severe somatic state of recipients. To improve the quality of transplant care, in our opinion, a multidisciplinary approach is required for each patient with an individual selection of an immunosuppressive protocol and careful monitoring of the infectious status.

202

THE FIRST RESULTS OF ORGAN TRANSPLANTATION AT THE ROSTOV REGIONAL CLINICAL HOSPITAL

V. Korobka^{1,2}, M. Cherkasov², M. Kostykin¹, E. Pak¹,

¹*The Rostov Regional Clinical Hospital, Rostov-on-Don, Russian Federation*

203**PREVENTION OF PURULENT COMPLICATIONS AT PANCREAS RESECTION****V. Korobka^{1,2}, R. Korobka^{1,2}, A. Shapovalov¹**¹*The Rostov Regional Clinical Hospital, Rostov-on-Don, Russian Federation*²*The Rostov State Medical University, Rostov-on-Don, Russian Federation*

Relevance. Destructive pancreatic stump pancreatitis and purulent complications of the abdominal cavity due to the leakage of PJA remain the leading complications in pancreas resections, which are the main cause of death of 4.5-25% of patients.

Aim. Evaluation of the effectiveness of the original methods for the prevention of postoperative destructive pancreatitis and diffuse purulent-inflammatory complications of the abdominal cavity with patients who underwent resection of the pancreas.

Materials and methods. We report 521 patients underwent pancreas resection because of chronic pancreatitis (235) and pancreatic or Vater's papilla tumors (286). The number of operated patients: men – 272 (52.2%), women – 249 (47.8%). The average age is 56.4 ± 13.6 years. The main types of operation was Whipple's procedure – 195, Frey's procedure – 74, Beger's procedure – 59, pylorus-preserving pancreatoduodenectomy – 67, distal pancreatectomy – 68, medial pancreatectomy – 58. In 479 (91.9%) cases, the operation was completed by the formation of PJA. In 214 (41.1%) cases, surgical treatment was performed using standard technologies, without additional measures to prevent postoperative pancreatitis and purulent-inflammatory complications (group 1), in 307 (58.9%) original methods of prevention (group 2) were used. Intrapancreatic infusion of inhibitors of proteolysis – 67, protection of PJA and zone of resection of the head of the pancreas (Beger's procedure) drained outward by "omental bags", formed from the greater omentum flap – 240.

Results. The results of the study were estimated by the presence or absence of destructive pancreatitis after surgery, leakage of PJA and accompanying inflammatory-purulent complications of the abdominal cavity. In first group the number of patients with destruction of the pancreas stump and the leakage of PJA was 14 (6.5%), peritonitis – 12 (5.6%), with abdominal abscesses – 8 (3.7%), infiltrates – 16 (7, 5%). 13 (6.1%) patients were reoperated. In second group destruction of the pancreas stump and the leakage of PJA was 8 (2.6%). Peritonitis, abscesses and infiltrates of the abdominal cavity were absent. 2 (0.7%) patients were reoperated in cause of with arrosive bleeding. Early postoperative mortality in first group was 4.2% (9), in second group – 0.7% (3).

Conclusions. Isolation of pancreatic anastomosis and pancreas stump in combination with local pancreatoprotection reduces

the number of postoperative infiltrative and purulent-inflammatory complications of the abdominal cavity, reduces the lethality from these causes, improves the quality of resectional interventions

204**MULTIVISCERAL RESECTIONS FOR LOCALLY ADVANCED COLON CANCER****P. Korolev, D. Sidorov, M. Lozhkin, A. Troickiy***FSBI National Medical Research Radiological Center of the Ministry of Health of the Russian Federation, Department of abdominal oncological surgery, Moscow, Russia*

Background (relevance). Locally advanced colon cancer with involving surrounding organs is challenging to surgeons and oncologists. The surgical approach in the treatment of locally advanced colon cancer still remains the principal method.

Aim. The aim of this study was to evaluate the results after multivisceral resections.

Materials and Methods. All patients underwent multivisceral resection for locally advanced colon cancer between January 2006 and December 2016. Data were collected retrospectively and included content concerning demographics, tumor characteristics, specificities of surgery, perioperative and long-term results.

Results. A total of 74 patients (62,7±12,1 years old, 34 [46%] males) were abstracted. All patients underwent multivisceral resections for clinical T4 tumors. R0-resection status was achieved in 64 (86.5%). Direct invasion in adjacent organs was identified in 47 (63,5%) cases (pT4b). Due to the tumor localization, these types of "en bloc" resections were applied: extended right hemicolectomy 25 (33.8%), extended left hemicolectomy 20 (27%), sigmoidectomy 29 (39.2%). Operation time and blood-loss medians were 227 minutes and 420 ml, respectively. A rate of postoperative complications (24 cases [32.4%]) and 30-day mortality (2 cases [2,7%]) were, as expected, higher. The 5-year cancer-specific survival was 64,6% [95% ДИ: 55,8-73,5], and 5-year disease-free survival was 57,0% [95%ДИ: 48,4-65,7]. R1 resection, lymph node involvement, and low-grade adenocarcinoma were identified as important factors had an impact on bad prognosis.

Conclusions. Multivisceral resection for locally advanced colon cancer with en bloc removal of involved structures can provide radical operative status. Performing a multivisceral resection is certainly associated with an increased risk of early complications and postoperative lethality. However, R0-resection achieved in 64 (86.5%) patients, which allowed to ensure local tumor control and improve long-term results.

205

SURGICAL MANAGEMENT OF CHOLANGITIS AND BILIARY SEPSIS ON THE BACKGROUND OF CHOLECYSTO - CHOLEDOCHOLITHIASIS

A. Korolkov, D. Popov, T. Tantsev, M. Kitaev

Pavlov First Saint Petersburg State Medical University, Research Institute for Surgery and Emergency Medicine, Saint-Petersburg, Russia

Introduction. The most often and severe complications of concomitant gallbladder and common biliary duct (CBD) stones are mechanical jaundice (MJ), cholangitis and biliary sepsis (BS). Nowadays the ideal method for managing cholecysto - choledocholithiasis is debatable.

Aim. The aim was to improve the results of treatment of patients with MJ, cholangitis and BS at the background of cholecysto - choledocholithiasis.

Method. In the period from 2013 to 2018 in the Pavlov First Saint Petersburg State Medical University 162 patients with cholecysto - choledocholithiasis were treated. All patients were divided into groups: MJ, cholangitis and BS, as well as subgroups with acute and chronic cholecystitis. In each group the following values were measured: the frequency of postoperative complications, the total time of operation, the efficiency of stone clearance, the total time of anesthesia, mortality, the duration of hospital stay, economic efficiency. Research result. The following types of operations were performed: one-stage laparoscopic cholecystectomy (LC) and endoscopic papillosphincterotomy (EPST) – 93, LC and laparoscopic common bile duct exploration (LCBDE) - 62 and 7 patients with BS were managed in two stages with decompression of the biliary tract using EPST and lithoextraction on the first stage, and performing LC as second stage in a few days. Comparison of one-stage methods in groups of patients with MJ and cholangitis with acute cholecystitis, as well as with the chronic one revealed that in the group of patients who underwent single-stage laparoscopic treatment was significantly noted: higher efficiency of stone clearance (96.7% vs 88.2%), less total time of surgery (129.1±10.5 vs 164.8±14.1) , lower rate of postoperative complications (3,2% vs 11.8 %), shorter duration of anesthesia (160,4±10,8 vs 197,9±14,5) , less hospital stay (6,2±0,7 vs 8,8±1,0; and higher economic efficiency (67412,8±4476,5 991,6 vs 85±6418,1). In 7 patients with BS and chronic cholecystitis two - stage surgical management were performed. In 4 cases of BS and acute cholecystitis was successfully performed one-stage management. In the group of patients with BS, operated with minimally invasive techniques, in comparing with group of patients underwent open surgery were noted less mortality (18,1% vs 37,5%), less hospital stay (16,3±2.1 vs 28,7±5,2), and higher economic efficiency (177 467,2±6408,3 568,1 vs 210±14106,5) .

Summary. In patients with MJ, cholangitis and BS on the

background of acute and chronic cholecystitis, the usage of one-stage LC and LCBDE is preferable. In case of BS without inflammation of the gallbladder two-stage treatment is a method of choice. In case of BS with acute cholecystitis it is possible to perform one-stage operations. The usage of minimally invasive technologies, in comparison with open surgery, in patients with BS can reduce mortality, duration of hospital stay and improve economic efficiency.

206

LAPAROSCOPIC CHOLECYSTECTOMY IN SITUS INVERSUS TOTALIS: TECHNICAL DIFFICULTIES AND MEASURES TO OVERCOME

Koshariya Mahim, Jain Mohit, Salam Varun, Garg Surabhi, Gehlot Singh Puspendra, Vinayak Kunal, Soni Mayank, Suhail Hussain, Alex Sharon, Gupta Bramhanand

Department of General Surgery, Gandhi Medical College and Associated Hamidia Hospital, Bhopal, India

Relevance. Situs inversus totalis (SIT) is a rare defect of genetic predisposition.. Its incidence has been reported as 1 in 5,000 to 1 in 15,000. It may cause difficulties in the diagnostic and therapeutic management of abdominal pathology due to the mirror-image anatomy. The presence of symptomatic gallstones in a case with situs inversus totalis, can be a diagnostic dilemma. There is no current evidence that situs inversus predisposes to cholelithiasis We report our experience and its laparoscopic management with emphasis on its surgical technique combined with certain modification.

Object. To know the technical difficulties in performing laparoscopic cholecystectomy in a Situs Inversus condition and measures to overcome it.

Materials and methods. We Share our experience of Laparoscopic Cholecystectomy in situs inversus and the technical difficulties faced while performing the procedure by a right handed surgeon and the technical adaptation and modifications taken to overcome the difficulties to perform the operation successfully.

Results. Laparoscopic Cholecystectomy in a situs inversus patient is a technically challenging procedure to perform laparoscopically, as for a right handed person surgeon left hand becomes the dominant as the total anatomy is mirror image.

Conclusions. The procedure can be performed safely, as well as with the precision by a right handed surgeon with meticulous preoperative planning and intraoperative adaptation.

207

A RARE CASE OF BILATERAL SPIGELIAN HERNIA MANAGED LAPAROSCOPICALLY

**Koshariya Mahim, Jain Mohit, Parihar Manish,
Hussain Suhail, Gupta Bramhanand, Tiwari Shahshikant,
Gautam Somveer, More Rameshwar, Sharma Anurag,
Balkar Pal Krishna, Malviye Arun**

*Department of General Surgery, Gandhi Medical College
and Associated Hamidia Hospital, Bhopal, India*

Background/relevance: Spigelian hernia or lateral ventral hernia is a rare type of hernia through spigelian fascia which is the aponeurotic layer between the rectus abdominis muscle medially and the semilunar line laterally. It is a rare type of anterior abdominal wall hernia. B/L spigelian hernia is a very rare clinical entity. Spigelian hernias occurs through slit like defects in the anterior abdominal wall adjacent to the semilunar line which extends from the tip of the ninth costal cartilage to the pubic spine at the lateral edge of the rectus muscle inferiorly. Most of spigelian hernias occur in the lower abdomen where the posterior sheath is deficient. It is also called “spontaneous lateral ventral hernia” or “hernia of semilunar line. We report a case of B/L spigelian hernia successfully repaired with excellent cosmetic and clinical outcome using advanced laparoscopic techniques.

Objectives: To manage a case of bilateral spigelian hernia laparoscopically with minimal invasion and better outcome

Material and Methods: We present our experience of managing a case of bilateral spigelian hernia in a 47 years old female laparoscopically. Bilateral hernial defects were dissected using harmonic and then bilateral defects were closed by transfixing sutures using prolene 1-0 and then composite mesh was fixed over the closed defects bilaterally using secure strap tackers.

Results: Patient was managed successfully by laparoscopic technique and postoperative course was uneventful. After a six month long follow up the patient has now no residual swelling or scar mark of hernia surgery and is having a very normal life with no complaints.

Conclusions: We here by report a case of a 47 years old female with bilateral spigelian hernia successfully repaired with excellent cosmetic and clinical outcome using laparoscopy.

208

A STUDY ON GASTROINTESTINAL STROMAL TUMOURS AND ITS MANAGEMENT: OUR EXPERIENCE

**Koshariya Mahim, Vinayak Kunal, Soni Mayank,
Gehlot Singh Puspendra, Behram Sheikh, Salam Varun,
Prakash Jai, Rathore Ashay, Songra M.C**

*Department of General Surgery, Gandhi Medical College
and Associated Hamidia Hospital, Bhopal, India*

Background / Relevance: Gastrointestinal stromal tumours (GISTs), though rare, are the most common mesenchymal tumours of the gastrointestinal tract. Their origin is believed to be from gastrointestinal pacemaker cells known as the interstitial cells of Cajal, but it has nowadays been recognized that GISTs arise from multipotent mesenchymal stem cells. The term was first coined by Mazur and Clark in 1983 to describe a heterogeneous group of gastrointestinal non-epithelial neoplasms. In 1998, Hirota and co-workers reported that GISTs contained activating c-kit or PDGFR α mutations, which play a crucial role in its pathogenesis. GISTs are now defined as pleomorphic mesenchymal tumours of the GI tract that express the KIT protein CD117 (and often, CD34) on immunohistochemistry. Kit is a transmembrane receptor tyrosine kinase responsible for cellular proliferation, adhesion, apoptosis and differentiation. In GIST, a mutation in the Kit gene is responsible for constitutive activation of Kit protein, causing unopposed stimulus for cell proliferation. The worldwide incidence and prevalence of GISTs are estimated to be approximately 1–1.5 per 100,000 per year and 13 per 100,000, respectively. Over 90% of GISTs occur in adults over 40 years old, in a median age of 63 years. GISTs may occur anywhere along the length of the digestive tract. The prediction of malignant potential of GISTs based on clinical and pathological features is difficult. Categorizing GISTs into low, intermediate and high-risk tumours based on their potential for recurrence and metastasis is more appropriate than dividing them into benign and malignant categories. Surgical management remains the mainstay to achieve cure. Molecular targeted therapy in the form of Imatinib has revolutionized the medical management of advanced GISTs. GISTs can be difficult to manage. One must be familiar with this disease so as to reduce the chances of misdiagnosis and to impart standardised treatment.

Objectives: To review clinico-pathological characteristics and various management strategies of GISTs

Materials and Methods: A retrospective analysis of 50 cases of GIST admitted in Hamidia Hospital, Bhopal was conducted in the period from 2009-2016. Their clinical, radiological, pathological and treatment details were collected. Ultrasound and CT scan were the radiological modalities used. From pathological point of view, we assessed tumour size, mitotic

index and CD117 testing was done.

Results: The male to female ratio was 1:1. The mean age at diagnosis was 60 years. Stomach was the most common organ to be involved. At presentation, abdominal pain was reported in 22 patients. The chief radiological finding was a mass with peripheral hyper vascularity and central necrosis. Spindle cell variety was seen in most of the cases. Mitotic count of <5/HPF were seen in 19% cases, 5–10/HPF in 53% cases and >10/HPF in 28% cases. Kit immunoreactivity was positive in 92% cases.

Conclusions: GISTs can be difficult to manage hence, a multispeciality approach may be required. Surgical resection is the mainstay of treatment of GIST. Tumour size, mitotic index, gastric origin and primary presentation are important predictors for disease severity. Therapeutic agents, such as Imatinib have now been approved for the treatment of advanced GISTs. More research should be undertaken to study its role in neoadjuvant and adjuvant setting.

209

A STUDY ON SERUM LIPID PROFILE AND ITS SIGNIFICANCE IN THE PATIENTS OF BENIGN AND MALIGNANT BILIARY TRACT DISEASES IN THE PATIENTS ATTENDING HAMIDIA HOSPITAL, BHOPAL

Koshariya Mahim, Vinayak Kunal, Soni Mayank, Gehlot Singh Puspendra, Behram Sheikh, Alex Sharon, Sharma Agamy, M. Songra

Department of General Surgery, Gandhi Medical College and Associated Hamidia Hospital, Bhopal, India

Background/ Relevance. Biliary tract cancers, include tumors of the gallbladder, extrahepatic bile ducts, and ampulla of Vater. It is a relatively common disease, usually carrying a grim prognosis. Gallstone disease is an important known risk factor. Cholesterol gallstones (composed mainly of cholesterol) and mixed gallstones (composed of both cholesterol and bilirubin) have the strongest association with gallbladder cancer. Given the strong link between hyperlipidemia and gallstones and the association between gallstones and biliary tract cancers, it is reasonable to believe that hyperlipidemia may be associated with biliary tract cancers. We performed this study to understand the role of serum lipids in biliary tract cancers.

Objectives. To study the spectrum of serum lipid profiles among the patients suffering from biliary tract disease. To study the correlation between hyperlipidemia and gall bladder cancer/biliary tract malignancy.

Materials and Methods. 100 patients with benign and malignant biliary tract diseases attending Hamidia Hospital, Bhopal were recruited and enrolled in this study. Equal number of age matched hospital based controls without any prior history of biliary tract disease were also enrolled. Informed consent was obtained from all patients.

Participants were interviewed by trained interviewers/residents and clinical data was recorded. A fasting sample of blood for serum lipid profile and liver function tests was drawn and studied. Diagnosis was based on clinical evaluation, lab reports, radiological investigations and histopathology, wherever possible. At the end of the study the data was analysed.

Results. Most of the patients of biliary tract cancers in our study presented with advanced disease. Biliary tract malignancies have a strong correlation with dyslipidemia, mainly higher triglycerides, higher total cholesterol and lower HDL values. This association is statistically significant (p value<0.005) when controlled against stone disease subgroup or against healthy controls. Patients with malignant biliary diseases have serum lipids in the highest quartile, with levels being proportional to bilirubin levels in jaundiced individuals.

Conclusions. When comparing stone disease patients with healthy controls there is statistically significant difference only between Serum HDL values. The study suggests a definite association between serum lipids and gall bladder cancer. Further studies are required to confirm these results and to investigate the association of serum lipid profiles with biliary tract malignancy and stone disease.

210

COMPARATIVE STUDY OF CATHETER DRAINAGE VERSUS NEEDLE ASPIRATION IN MANAGEMENT OF LIVER ABSCESS : OUR EXPERIENCE

Koshariya Mahim, Gehlot Singh Puspendra, Vinayak Kunal, Soni Mayank, Behram Sheikh, Hussain Suhail, Dhodi Deepti, Tiwari Shashikant, Gupta Bramhanand, Chaudhary Anuradha, Rai A

Department of General Surgery, Gandhi Medical College and Associated Hamidia Hospital, Bhopal, India

Relevance. Amoebic liver abscess and pyogenic liver abscess are common problems in India and other tropical countries and increasing incidence rate in the United States and Europe. It could result as a complication of various intra-abdominal infections, or haematogenous spread via portal vein from the gastrointestinal tract, or may develop after traumatic injury to the liver. The high morbidity and mortality rates associated with the treatment of pyogenic liver abscess were improved significantly with the introduction of ultrasound and computed tomography

Objective. The aim of the study is to evaluate the clinical presentation and to investigate the effectiveness of continuous catheter drainage in comparison to needle aspiration in the treatment of liver abscess

Method. Observational study includes only those patients having liver abscess greater than 5 cm who were admitted in Hamidia Hospital, Bhopal from March 2013 to March 2018

were included in this study and were exposed to catheter drainage or needle aspiration, All interventions were performed under ultrasonographic guidance.

Results. Out of 651 needle aspiration was successful in 302 out of 354 patients (85.3%) one aspiration 98 , two aspiration in 192 and three aspiration in 12, whereas catheter drainage was successful in 291 (297)patients duration to attain clinical relief was 12 days and 9 day and parenteral antibiotic needed was 15 days and 10 days were significantly lower in catheter drainage group duration of hospital stay was similar in both groups, The mean age of the patients was 41.13 years (range: 10 to 80 years), Male to female ratio was 12:1, about two-thirds of the patients (67.5%;) were from lower socioeconomic class with regards to education, occupation, and per capita income and the rest were from the middle class families. Etiological analysis of revealed that 69% were of amoebic origin, 18% of pyogenic, 4% of mixed amoebic and pyogenic process, 7.5% of tubercular, and 1.5% of fungal infections

Conclusion. Our study concluded that in view of greater volume of pus drained in first sitting results in early clinical recovery and shorter duration of hospital stay. Catheter drainage is a better treatment modality then needle aspiration for the management of large liver abscess of size > 5 cm in terms of duration to attain clinical relief and duration for which parenteral antibiotic are needed.

211

EVALUATION OF THE EFFECTIVENESS OF ROBOTIC FUNDOPLICATIONS IN THE TREATMENT OF GERD

M. Koshkin, O. Vasnev, A. Belousov

Moscow clinical Scientific Center, Moscow Russia

Surgical treatment is one of the most effective options for treatment of gastroesophageal reflux disease. Laparoscopic approach became is a "gold standard" over the time demonstrating all advantages of minimally invasive techniques over the open procedures. However the utility of robotic anti-reflux operations still remains controversial.

Aim of the study: Evaluate the initial experience of robotic antireflux operations in compare to laparoscopic procedures.

Materials and methods. Since the January till the December of 2017 thirty operations were operated on. Mean age was 57,2 (35-76), among them 21 (70%) were female and 9 (30%) were males. Mean BMI was 29,4 (24,1-41,0). Laparoscopic procedures were performed in15 patients (1st group), robotic procedures with DaVinci system were performed in 15 patients of the second group. Chernousov modified Nissen fundoplication was performed in 25 patients, Toupet fundoplication was used for 4 patients, Nissen type was performed in 4 cases.

Results: The median operative time in laparoscopic group was

125 min (80-200 min), in robotic group - 124 min (90-210 min). There were no statistical differences between two groups (p=0,93). Blood loss was minimal in both groups. Mean post-operative hospital stay was 4 days (2-7 days) in the 1st group and 4 days (2-6 days) in the second. There were no statistical differences between two groups (p=0,19). Postoperative course was uneventful in all patients of both groups.

Conclusion: Robotic antireflux operations are safe and effective in treatment of patients with reflux-esophagitis. There were no statistically significant differences in short-term results of laparoscopic and robotic operations.

212

GENDER DYNAMICS OF GLOMERULAR FILTRATION RATE IN LIVER TRANSPLANT RECIPIENTS: LONG-TERM POSTOPERATIVE RESULTS

H. Kosmacheva, A. Babich

State Budgetary Healthcare Institution "Research Insnitute Regional Clinical Hospital No 1 n.a. professor S.V. Ochapovskiy " of Ministry of Health of Krasnodar Region, Krasnodar, Russia

Background. As improved surgical techniques and intensive care capabilities continue to improve outcomes from liver transplantation, long-term native kidney function in these recipients assumes a more critical role in patient survival. There are conflicting data on the role of sex in reducing kidney function in liver recipients. The aim of our retrospective study was to assess glomerular filtration rate (GFR) at different time stages of the postoperative period in patients who underwent LT in Research Institute - Regional Clinical Hospital №1, Krasnodar, taking into account gender differences and calcineurin inhibitors therapy.

Methods. According to the available data of the local retrospective register, 30, 35, 29 and 25 women and 50, 53, 40 and 33 men, respectively, were included in the analysis groups of the dynamics of GFR at period 6, 12, 24 and 36 months. We used a calculated glomerular filtration rate (from the Chronic Kidney Disease Epidemiology Collaboration Modification of Diet Renal Disease (CKD-EPI). Results. Initially, prior to transplantation, GFR was evaluated in 86 patients (51 men and 35 women). Reduction of GFR is less than 90 ml/min/1.73 m² before transplantation in 28 men and 21 women without reliable differences. Six month post-OLT a reduced level of GFR < 90 ml/min/1.73 m² was in 76% men and 90% women, at one year post-OLT - 85% men and 89% women, at two years post-OLT - 88% men and 97% women, at three years post-OLT -79% men and 88% women. The reliability of the difference GFR between the cyclosporin group and the tacrolimus group was not observed at all periods, except for 6 and 24 months. Against the background of cyclosporine, the level of GFR decreased by 8.0 % at 6 months (p = 0.34), by 20.4% (p = 0.01), 17.5% (p = 0.046)

and 16.9% ($p = 0.032$) in a year, 24 months and 36 months, respectively. In the tacrolimus group, the level of GFR decreased at 6 months, 1 year, 2 and 3 years at 17.2% ($p = 0.004$), 23.7% ($p = 0.001$), 25.8% ($p = 0.0004$), 30.2% ($p = 0.0006$), respectively. There was no differences, depending on gender, for the level of GFR in the tacrolimus and cyclosporine groups.

Conclusions. Both cyclosporine and tacrolimus caused an increased level of GFR in women and men compared with the baseline. Differences in GFR in tacrolimus and cyclosporine groups are not recorded three years after OLT, depending on the gender. The prevention of renal dysfunction requires after transplantation a better use of immunosuppressive drugs and also an optimal control of risk factors for chronic kidney disease in both women and men.

213

NUTRITIONAL SUPPORT IN THE STRUCTURE OF THE INTERDISCIPLINARY APPROACH IN THE COMBINED TREATMENT OF PANCREATIC CANCER

L. Kostyuchenko, T. Kuzmina, N. Dobrovolskaya, A. Kruglov, A. Lychkova

State budgetary institution of health care « Moscow clinical scientific center named after A. S. Loginov», Moscow, Russia

Urgency. It is known that nutritional support (NS) has a beneficial effect on the outcome of surgical treatment and after chemotherapy (HT). However, until now the role of the nutritionist is not sufficiently taken into account in the interdisciplinary approach to the treatment of such patients. The goal is to evaluate the role of the nutritionist and adjuvant nutritional support (NS) in interdisciplinary approach to the treatment of patients with non-metastatic and metastatic cancer of pancreatic head.

Material and methods. 35 patients with ductal adenocarcinoma (5 people with T1N0M0, 7 – with T2N0M0, 14 – with metastatic pancreatic cancer T3N0M1, 3 – with T4N1M1 and 6-ro – not verified at the stage of the cancer). Nutritional risk (NR) was assessed by the NRI scale, quality of life- by SF-36 and ECOG, body composition – using bioimpedance technique.

Results. We studied the mechanisms of muscle catabolism, body composition, phase angle. In patients with high NR skinny mass body (SMB) and the body fat mass decreased but at an elevated content of extracellular fluid. After adjuvant NS in patients with T1N0M0, T2N0M0 it was possible to keep SMB as the fitness standard for a long time, which was accompanied with a positive dynamics of biochemical parameters, a tendency to normalize the phase angle. In patients with T3N1M1 and T4N0M1 (even during hyperalimentation) the extracellular water increased and the actual loss of muscle mass masked. The quality of life was higher in all patients with NS. Bioimpedance assessment of the body composition served as a fast and informative method of monitoring the dynamics of

metabolism in the considered category of patients, and NS was one of the main components of the combined treatment.

Summary. 1) Quality of life is ensured not only by surgical treatment, but also by timely relief of metabolic (including nutritious) complications of the tumor process. 2) The role of the nutritionist in a multidisciplinary approach (joint with surgeons, oncologists, etc.) is very important, because of positive effect the NS (including a detoxifying nutrition). 3) Bioimpedance assessment of body composition is a fast and informative method of monitoring the dynamics of metabolism.

214

ASSESSMENT OF QUALITY OF LIFE IN PATIENTS WITH IRRITABLE BOWEL SYNDROME

S. Kosyura, U. Varaeva, E. Livantsova, A. Starodubova

Federal Research Centre of Nutrition, Biotechnology and Food Safety, Pirogov Russian National Research Medical University (RNRMU), Russia

The Effects of Prebiotics on the Health-Related Quality-of-Life among Patients with Irritable Bowel Syndrome (IBS)

Introduction: Affecting from 10 to 15 or even 20% of worldwide population Irritable Bowel Syndrome is considered as the most common gastrointestinal disorder. General Irritable Bowel Syndrome symptoms as diarrhea and abdominal pain cause a significant impairment in patients' health-related quality-of-life and negatively affect their day-to-day life.

Aims and methods: The main aim of this 2 months, open-label, parallel-arm, prospective study was to assess the influence of prebiotics as part of complex treatment on health-related quality-of-life scores in comparison with standard treatment regime. To achieve this aim 52 patients with Irritable Bowel Syndrome were recruited into the study at Nutrition Clinic of the Federal Research Center of Nutrition, Biotechnology and Food Safety, Moscow, Russian Federation. All patients met the Roman IV criteria (2016). Participants was divided into two groups according to prescribed treatment regime: standard therapy (the first group) and standard therapy in combination with prebiotics - butyric acid and inulin (the second group). The health-related quality-of-life was assessed using SF-36 Health Survey at the beginning of the study and after two months of follow-up.

Results: There was a prevalence of females among participants: 65.38% (N34) comparing to 34.62% (N18) of males. Mean age of participants was 31.17 years (95%CI:28.81; 33.53). Gender characteristics and mean age were comparable between study groups. Initially the mean Physical Health (PH) score was significantly lower at the second group - 37.66 ((95%CI: 36.01 39.31) than at the first one - 41.3 (95%CI: 39.87; 43.79) with p -value=0.002. This fact reflects the

intensity of medical staff to add prebiotics to standard therapy to participants with more intensive IBS's symptoms and associated with it lower quality-of-life levels. At the same time the mean Mental Health (MH) score was comparable between groups: 29.1 (95%CI: 27.06; 31.76) versus 30.99 (95%CI: 28.83; 33.15) respectively. After two months of follow up the overall Physical Health score increased significantly from 39.87 (95%CI: 38.58; 41.26) to 47.65 (95%CI: 45.69; 49.62) with p-value equally to $2 \cdot 10^{-8}$. The overall Mental Health score changed at the same way from 30.15 (95%CI: 28.58; 31.72) to 44.11 (95%CI: 42.27; 45.94) with p-value=10-18. In inter and between group analysis was established that Physical Health score increased in both groups up to 42.63 (95%CI: 40.47; 44.79) in the first group and 52.90 (95%CI: 51.72; 54.08) in the second but high statistical significance levels were achieved only in the second group with p-value=10-18. The second group performed reliably higher results than the first with p-value= $8 \cdot 10^{-10}$. Mental Health scores also presented positive dynamics in both groups with high significance levels: raise to 40.39 (95%CI: 37.82; 42.95) in the first group (p-value= $4 \cdot 10^{-8}$) and to 48.00 (95%CI: 46.55; 49.44) in the second (p-value= $5 \cdot 10^{-18}$). Simultaneously, the second group showed greater positive changes compare to the first group with p-value= $4 \cdot 10^{-6}$.

Conclusion: In short-term follow up inclusion of prebiotics in standard IBS's therapy reliably increased health-related quality-of-life assessed by SF-36 Health Survey in comparison with standard treatment alone due to both aspects: Physical as well as Mental Health. The standard treatment did not achieve reliable levels in Physical Health score improvement and performed lower level of Mental Health score increase than combined with prebiotics therapy regime. Research work carried out at the expense of subsidies for carrying out public tasks in the framework of the Program for Basic Research of state academies of science for 2013-2020 (topic № 0529-2015-0013).

Keywords: Irritable bowel syndrome, Butyric acid, Inulin, Quality of life, SF-36

215

RESULTS OF SURGICAL MANAGEMENT OF PATIENTS WITH PANCREATIC METASTASES FROM RENAL CELL CARCINOMA

A. Kotelnikov¹, Y. Patyutko¹, D. Podluzhny¹, I. Proskuryakov¹, I. Fainshtein^m, G. Galkin², M. Magomedov², A. Kriger²

¹FSBI "N.N. Blokhin National Medical Research Center of Oncology" of the Ministry of Health of the Russian Federation, Moscow, Russian Federation

²FSBI "A.V. Vishnevsky National Medical Research Center of

Surgery" of the Ministry of Health of the Russian Federation, Moscow, Russian Federation

Medical Research Center of Surgery" of the Ministry of Health of the Russian Federation, Moscow, Russian Federation

Relevance. Surgical treatment of patients with pancreatic metastases (PM) from renal cell carcinoma (RCC) is considered to confer a survival benefit, however data to approve such management are limited.

Purpose. The purpose of this retrospective study was to evaluate outcomes of patients undergoing surgery for RCC metastatic to the pancreas.

Patients and Methods. Forty-nine patients (twenty-seven men and twenty-two women; median age: 60 years; range: 40–70 years) with PM from RCC (clear cell type) undergoing surgery between 1995 and 2017 were retrospectively identified from a database from 2 Russian centers.

Results. PM were synchronous in 7 (14%) patients and metachronous in 42 (86%) patients. The median interval from nephrectomy (total or partial) to surgery for metachronous PM was 10 years (range, 1–19 years). The following surgical procedures were performed: 29 (59,2%) distal pancreatectomy (DP) (in two cases, the procedure was associated with the enucleation of metastases of the head), 10 (20,4%) pancreatoduodenectomy (PD), 6 (12,2%) total pancreatectomy (TP), 1 (2%) middle-preserving pancreatectomy, 1 (2%) middle pancreatectomy, 1 (2%) duodenum-preserving resection of the head of the pancreas, 1 (2%) cryosurgical destruction. One patient included in the TP group experienced recurrence in the pancreatic head 72 months after a DP. He underwent extirpation of the stump of the pancreas, resulting in TP. Twenty (41%) patients underwent surgery for extrapancreatic RCC metastases both before and during an operation for PM. For pathological findings, solitary metastases were identified in 59%, oligometastases (2 - 3 nodes) in 29%, multiple metastases in 12%. The mean size of metastases was $3,4 \pm 2,5$ mm (range, 7–80 mm). Postoperative complications occurred in 53% patients and included pancreatic necrosis (4%), pancreatic fistula (29%), biliary fistula (4%), abdominal abscess (4%), delayed gastric emptying (4%), wound infections (4%), myocardial infarction (2%), myocardial ischemia (2%), transient aggravation of renal dysfunction that required hemodialysis (2%). The 90-day mortality rate was 6 %. Two patients died from pancreatic necrosis after PD and one patient died from infectious complications after DP. After pancreatic surgery, the median survival was 88 month (range, 4 – 168 month). Kaplan-Meier 5-year overall survival was $81 \pm 7\%$.

Conclusions. Surgery for PM of RCC is associated with acceptable postoperative complications and long-term survival.

216

VASCULAR RESECTION IN PATIENTS WITH PANCREATIC CANCER

A. Kotelnikov, Y. Patyutko, D. Podluzhnyj, E. YAstrebova, I. Proskuryakov, N. Kudashkin

N.N. Blokhin National Medical Research Center of Oncology, Moscow, Russia

Relevance: Surgical treatment of pancreatic cancer is often followed by vascular resection. The results of such treatment remain controversial.

Object: To evaluate the results of surgical treatment of patients with pancreatic cancer.

Materials and methods: This retrospective observational study included all patients undergoing pancreatic resection with or without vascular resection at N.N. Blokhin National Medical Research Center of Oncology between January 2004 and December 2017.

Results: A total of 535 patients had pancreatic resection. 192 (36%) patients underwent vascular resection, of whom 145 (76%) had pancreaticoduodenectomy (PD) or total pancreatectomy and 47 (24%) distal pancreatectomy. Venous resection was performed in 179 (93%) patients, of whom unilateral resection was in 47 (26%) cases, circumferential resection in 132 (74%) cases. For patients with circumferential vein resection 92 (70%) had an "end-to-end" anastomosis, 38 (28%) an interposition graft and 2 (2%) an autologous vein graft. Circumferential resection of celiac trunk and common pancreatic artery in patients who underwent distal pancreatectomy was performed in 23 cases. Venous resection resulted in a longer operating time (median 280 versus 240 min), greater estimated blood loss (EBL) (median 2000 versus 1200 ml), higher morbidity (69 versus 50 %) and mortality (12 versus 4%) than standard PD ($p < 0,05$). Venous resection in patients who underwent total pancreatectomy showed no significant difference in operating time, EBL, morbidity and mortality. The rate of operating time and blood loss was significantly higher in patients after distal pancreatectomy with blood vessel resection comparing with standard distal pancreatectomy: 180 vs 150 min ($p = 0,0001$), 1600 vs 1000 ml ($p = 0,0001$), respectively. There was no significant difference in morbidity and mortality between these groups. The 5-year overall survival in patients after PD with venous resection with and without histological vein involvement was 11+4% vs 17+ 8 % (median 11 vs 23 months), respectively, without venous resection 15+ 3%, median 16 months. 1 and 3-year overall survival in patients after distal pancreatic resection with artery resection was 33+11 % and 10+8%, respectively, median 10 months. Whereas in patients with histological artery involvement only 1-year survival was achieved - 31+12%, median 7,5 months.

Conclusions: Though vascular resection leads to higher morbidity and mortality, it can be used in treating patients with pancreatic cancer. Overall survival depends on histo-

logical vessel involvement. Distal pancreatectomy with artery resection is feasible in patients with pain syndrome.

217

THE EXPERIMENTAL SUBSTANTIATION OF VENOUS RECONSTRUCTION AT GASTROPANCREATIC DUODENAL RESECTION

A. Kotiv, I. Dzidzava, A. Smorodsky

S.M. Kirov military medical academy, Russia

Relevance: surgical treatment of pancreatic cancer is still a difficult problem of modern surgery.

Purpose: topographic-anatomic and clinical rationale of reconstruction variants of the portal system in gastropancreatic duodenal resections (GDPR).

Materials and methods. The anatomical part of the study was performed on 30 embalmed organocomplexes and on 10 embalmed corpses of people without pathology of the internal organs of the abdominal cavity.

Results. Experimental modeling of variants of vascular plastic in GDPR with excision of the mesenteric-portal venous segment showed that in connection with the possibility of displacement of the mobilized root of the mesentery of the small intestine in the direction of the gates of the liver, conditions exist for performing direct mesenteric portal anastomosis without significant vascular tension. If it is necessary to resect the superior mesenteric vein below the level of the main trunk and the absence of conditions for the connection with the portal vein, it is possible to perform an 'end to lateral' mesenteric-caval anastomosis that allows adequate venous blood outflow from one of the suprarenal mesenteric inflows to the lower vena cava. Porto-hepatic blood flow under such conditions can be provided by the creation of an 'end-to-end' splenportal anastomosis. Ensuring the outflow of venous blood from the stomach, spleen and stump of the pancreas in case of resection of the portal vein confluence depends on the length of the stump of the unaffected splenic vein. Investigations with filling of veins showed that in case of splenic vein ligation distal to the inferior mesenteric vein, the latter provides adequate blood flow through the arch of Riolan partly into the portal vein and partly into the system of the inferior vena cava via sigmoid and rectal venous vessels. If it is necessary to tie the lower mesenteric vein or insert it into the superior mesenteric vein for an adequate outflow of blood from the remaining part of the stomach, spleen and stump of the pancreas, the splenic vein must be anastomosed with the left renal vein or with sufficient length with a portal vein.

The conclusion. The proposed tactic of vascular reconstruction demonstrates a number of advantages: rapid restoration of portal blood flow along one of the inflows of the portal vein; the minimum number of vascular anastomoses in comparison with the use of autovenous plastic; exclusion of possible infec-

tion of a synthetic prosthesis in conditions of postoperative pancreatitis.

218

ACUTE PORTAL THROMBOSIS: SURGICAL TACTICS

B. Kotiv, I. Dzidzava, D. Kashkin, A. Smorodsky, A. Slobodyanik, S. Soldatov

Department of Hospital Surgery, S. M. Kirov Military Medical Academy Saint Petersburg, Russia

Relevance. The progress of ultrasound, x-ray endovascular and tomographic technologies in the recent years has contributed to a significant increase in life-time diagnosis of portal vein thrombosis. The mortality rates, reaching 20% in specialized hospitals and 100% with the natural course of acute portal thrombosis, determine the urgency of improving diagnostic and therapeutic approaches. There is no consensus on the problems of screening and preclinical diagnosis, classification and staging, individual choice of optimal treatment tactics and rehabilitation of patients with portal vein thrombosis remain controversial.

Objective: to demonstrate the results of treatment of acute portal thrombosis.

Material and methods: 24 patients with acute and subacute portal thrombosis were examined and treated in the clinic of hospital surgery of the Kirov Military Medical Academy from 2007 to 2017. The main triggers of thrombosis of the portal vein and its branches were: intra-abdominal infection (pancreatitis, pileflebitis with underlying diverticulitis, mesadenitis, peritonitis) – 7 (31.2%); myeloproliferative diseases (true polycythemia, essential thrombocythemia, subleukemic myelosis, chronic myeloleukemia) – 6 (25%); malignant neoplasms of the abdomen and small pelvis – 3 (12.5%); traumatic and iatrogenic lesions – 4 (18.8%). Etiology remained unclear in 4 patients (12.5%).

Results. The diagnosis was based on targeted ultrasonography with dopplerography of the main arteries of the portal vein system in patients with progressive abdominal pain, ascitic syndrome, splenomegaly and fever of unknown origin. In-depth laboratory and immunogenetic study revealed a number of hereditary factors of thrombophilia, predisposing patients to the development of portal thrombosis: mutation of factor V gene, 20210A mutation of prothrombin gene, protein C deficiency, protein S deficiency, antithrombin deficiency, C677T mutation of methylentetrahydrofolate reductase, 2 Janus V617F mutation of the kinase gene and homocysteine level of more than 22 mmol/l. At present, the most common and proven effective treatment of acute portal thrombosis is early systemic prolonged therapy with anticoagulants, which allows to reduce the frequency of deaths from 22% to 6.3%. In our experience, complete recanalization was achieved in 37.5% of cases: 44,4% for portal vein recanalization, 77,8% for splenic vein, 44,4% for the superior mesenteric. Partial

recanalization of the portal system veins was archived in 33.3% of cases. In five patients, due to the ineffectiveness of conservative therapy and increase of portal hypertension, thrombectomy with distal splenorenal (3) and mesentericocaval (2) shunts was performed through the portal vein lumen.

Conclusion. The conditions for and the effectiveness of regional thrombolysis through percutaneous catheterization of the portal vein branches, transjugular intrahepatic access or catheterization of the superior mesenteric artery remain controversial and require further studies.

219

DISTAL SPLENORENAL ANASTOMOSIS OR TIPSS IN PATIENTS WITH CIRRHOSIS OF LIVER.

B. Kotiv, I. Dzidzava, D. Granov, A. Polikarpov, P. Tarazov, S. Alentiev, A. Smorodsky, I. Onnitsev, S. Soldatov, A. Muzharovsky, S. Shevtsov, A. Petrov, S. Bugaev

Military Medical Academy S. M. Kirov, Department of Hospital Surgery; Department of General Surgery; FGBU Russian Research Center for Radiology and Surgical Technologies, Saint-Petersburg, Russia

Relevance: Surgical decompression of the portal vein system in patients with cirrhosis of the liver is a radical method of treatment and prevention of bleeding portal genesis. The most common surgical correction of portal hypertension is made by performing a distal splenorenal anastomosis (DSRA) or a transjugular intrahepatic portosystemic shunting (TIPSS). The question of the advantages of each of them remains controversial.

Purpose: compare the results of DSRA and TIPSS in liver cirrhosis with portal hypertension syndrome. In the present two-center study included 145 patients with cirrhosis of the liver with the syndrome of portal hypertension.

Materials and methods: On the Child-Pugh scale, Class A was 22,1%, Class B – 49 %, Class C – 28,9%. Indications for surgical correction of portal hypertension were recurrent esophageal-gastric bleeding, with ineffectiveness of repeated endoscopic ligation. A DSRA was performed in 108 patients, 37 TIPSS were installed.

Results. Indications for DSRA were class A Child-Pugh, the absence of ascites or its transient nature, the absence of clinical signs of encephalopathy. With severity of hepatic dysfunction of class B and C and a rate of elimination of indocyanine green > 8 %/min, V liver > 1200 ml, volume flow the portal vein > 600 ml/min formulated the indications for DSRA. With persistently relapsing esophageal-gastric bleeding, the ineffectiveness of endoscopic methods and the inability to perform DSRA, as well as with diuretic-resistant ascites in combination with pronounced varicose veins, TIPSS was performed. In all cases of DSRA, recurrences of gastroesophageal hemorrhages and shunt thrombosis cases were not observed in the long-term period. Regression

of the varicose veins up to the I-II degree was observed. Clinical signs of encephalopathy of mild degree were established in 15,7%. Life expectancy after DSRA for 5 years was $85,6 \pm 7,8\%$ and was determined by the degree of hepatic decompensation: median for class A - 85 m., and for classes B and C - 53 and 24m. ($p = 0,001$). After TIPSS, clinical signs of post-shunt encephalopathy of mild and moderate severity occurred in 43,2% of cases. In a long period of observation, stenosis and thrombosis of TIPSS was diagnosed in 9 (24,3%) patients, which required repeated endovascular interventions. Relapses of esophageal-gastric bleeding occurred in 4 (10,8%) patients. During the follow-up period, 16 patients died. The causes of deaths were: sepsis - 1 (1 month), recurrence of bleeding portal genesis - 4 (2, 3, 12, 24 m.), progression of hepatic insufficiency - 11 (from 2 to 12m.).

Conclusions. Thus, the method of choosing surgical decompression of portal hypertension in patients with compensated and subcompensated hepatic insufficiency is the DSRA. If it is not possible to perform an DSRA and inefficiency of endoscopic interventions in patients with a high risk of recurrence of bleeding, TIPSS is indicated.

220

ENDOASCULAR HEMOSTASIS IN POSTOPERATIVE AND POSTTRAUMATIC HEMMORAGES IN THE HEPATOPANCREATODUODENAL AREA

B. Kotiv, S. Alentyev, I. Dzidzava, S. Ivanusa, M. Lazutkin, O. Fedun, A. Molchanov, A. Smorodsky
Federal State Budgetary Educational Institution of Higher Professional Education S. M. Kirov Military Medical Academy, Saint Petersburg

Purpose. The problem of postoperative bleeding after abdominal surgery is one of the most difficult conditions currently.

Study objective. Evaluating the results of X-ray endovascular diagnostics and treatment for bleeding after surgical interventions and traumas of hepatopancreatoduodenal zone.

Materials and methods. Postoperative and post-traumatic bleeding from the hepatopancreatoduodenal vessels occurred in 35 patients treated in the clinics of general and hospital surgery of the Kirov Military Medical Academy from 2006 to 2016. 8 patients were diagnosed with bleeding into the lumen of the cysts of the pancreas due to percutaneous or transgastric drainage; 6 patients had hemorrhages from the splenic artery to the pancreaticoenteroanastomosis; in 6 other cases bleeding from the hepatic artery to the hepatoconteroanastomosis and/or into the peritoneal cavity through the safety drains; 3 patients had bleeding from the from the basin of the basilar mesenteric artery to the lumen of the hepatoconteroanastomosis and/or into the peritoneal cavity through the safety drains; 8 patients had

hemobilia due to percutaneous transhepatic drainage of the bile ducts, in 4 patients bleeding was from the liver vessels after injuries and operations in that area.

Results: Endovascular hemostasis was performed by embolization with metal spirals with pile, histoacryl, non-adhesive liquid embolic agent Onyx, pieces of hemostatic sponge. In 9 cases with pseudoaneurysms of large visceral arteries stent-grafts were used. In most cases, for the purpose of hemostasis, embolization of the damaged arteries with spirals until the extravasation of the contrast drug ceased was performed. Embolization of the gastroduodenal artery with a positive effect was performed in all cases of bleeding from pancreatic arteries. In cases of segmental hepatic arteries bleeding embolization of the proximal artery was performed. In cases of bleeding from the spleen artery trunk, embolization with spirals of the proximal part of the spleen artery trunk proved effective, in one patient it was not possible to achieve hemostasis with the use of spirals, therefore histoacrylic composition was used. In two cases of liver damage, percutaneous transhepatic embolization of the portal vein branches was performed. Primary hemostasis was achieved in all cases. 2 patients developed postoperative complications. In one patient, total embolization of the spleen artery trunk with histoacryl resulted in a large spleen infarction with abscessing on the fourth day, which required puncture drainage of the abscess under ultrasound control. Recurrences of bleeding were registered in 4 patients 4-12 days after embolization. In one of the cases embolization was repeated, in the remaining cases, an emergency laparotomy was performed, and the bleeding was stopped. No mortality in the immediate postoperative period.

Conclusion. Methods of endovascular hemostasis are effective in stopping bleeding after surgical interventions and traumas of hepatopancreatoduodenal zone, are characterized by a minimum number of complications and low lethality.

221

THORACOSCOPIC LOBECTOMY IN PATIENTS WITH NON-SMALL CELL LUNG CANCER

B. Kotiv, I. Dzidzava, E. Fufaev, R. Gunyat, O. Barinov, D. Yasyuchenya, A. Alborov, I. Kurakevich, I. Dmitrochenko
S.M. Kirov Military Medical Academy

Relevance. Currently, the surgical method is the main in the treatment of lung cancer. Videothoracoscopy is method of choice for the early forms of non-small cell lung cancer (NSCLC).

Purpose: to evaluate the results of thoracoscopic interventions in patients with non-small cell lung cancer (NSCLC).

Study materials. The study included 34 patients with operable NSCLC. The operations were performed by patients with I-II stage of disease. The scope of intervention included the

removal the lobe of the lung and the systematic lymphadenectomy. In 9 (26,5%) cases, operations were performed for central cancer, in 25 (73,5%) – peripheral NSCLC. The histological variant of the tumor lesion included adenocarcinoma in 25 (73,5%) and squamous cell carcinoma in 9 (26,5%) cases. The types of operations were distributed as follows: upper lobectomy on the right (n = 8, 23,5%), mean lobectomy on the right (n = 3; 8,8%), lower lobectomy on the right (n=6, 17,6%), lower lobectomy left (n=14; 41,2%), upper lobectomy on the left (n=3; 8,8%).

Results. The duration of drainage of the pleural cavity depended on the nature and complexity of the intervention and ranged from 1 to 12 days, averaging 2 days. A prolonged discharge of air through the drainage was observed in 8 (23,5%) operated patients and was associated with the intraoperative complications of the division of the interlobar sulcus and the presence of a commissural process in the pleural cavity. In 1 (2,9%) cases, the postoperative period was complicated by chylothorax, which required rethoracoscopy with clipping of the damaged thoracic lymphatic duct. Infectious complications were registered in 3 (8,8%) patients. There were no lethal outcomes. In general, the postoperative period was characterized by not expressed pain syndrome and early activation of patients. The long-term follow-up period was 6 to 36 months. In 2 (5,8%) cases, progression of the disease in the form of the appearance of distant metastases 1 and 2 years after the operation was noted. These patients are receive chemotherapeutic treatment. The overall three-year survival rate was 100%.

Conclusions. In patients with stages I-II of NSCLC, thoracoscopic lobectomy provides radical surgical intervention. Long-term results after such interventions are comparable to those in traditional operations. At the same time, minimally invasive access promotes faster recovery of patients, improvement of immediate results of treatment of patients in this category.

222

VIDEOTHORACOSCOPY IN THE SURGICAL TREATMENT OF THE MEDIASTINUM NEOPLASMS

B. Kotiv, I. Dzidzava, I. Dmitrochenko, E. Fufaev, D. Yasyuchenya, O. Barinov
S.M. Kirov Military Medical Academy

Relevance. Due to the high trauma of traditional surgical interventions aimed at the removal of mediastinal tumors, the use of minimally invasive technologies is of particular interest.

Purpose: to demonstrate the advantages of minimally invasive treatment of mediastinal tumors

Materials and methods: There are 213 videothoracoscopic surgical interventions for mediastinal neoplasms were performed – 96 (45%) and mediastinal lymphadenopathy –

117 (55%) in the period from 2007 to 2016. The average age of patients was 44,5±13,6 years, the majority of patients were men – 132 (62%).

Results: The mean duration of the operation was 73±23 minutes. The volume of intraoperative blood loss did not exceed 200 ml. The duration of drainage of pleural cavities in the postoperative period was 1,8±0,9 days. The average length of hospital stay is 5,7±1.4 days. Complications developed in 9 (4,2%) patients (pneumonia – 2, ciliary arrhythmia – 2, myasthenic crisis – 2, prolonged (more than 7 days) air discharge – 1, damage to the diaphragmatic nerve – 1). It was necessary for access conversion due to the development of intraoperative bleeding in one case (0,4%). The histological study of distant tumors, thymoma was diagnosed in 38 cases (17,8%), thymus hyperplasia in 21 (9,9%), pericardium cyst (9,2%), in 6 (2,8%) neurinoma, in 5 (2,4%) – Hodgkin's lymphoma, 4 (1,9%) cases - bronchogenic cyst, non-Hodgkin's lymphoma, cardio-diaphragmatic angle lipoma, in 2 (0,9%) - teratoma, thymus cyst, in 1 (0,4%) - seminoma 1. Based on the results of a histological examination of the mediastinal lymph nodes, sarcoidosis was diagnosed in 78 (66.6%), tuberculosis –26 (22.2%), Hodgkin's lymphoma –5 (4.2%), non-Hodgkin's lymphoma and mediastinal form of lung cancer – 4 (3,5%).

Conclusions. Thus, high informativity and low traumatism of videothoracoscopic surgical interventions makes them the "gold standard" in the diagnosis and treatment of neoplasms of the mediastinum and provides optimal tactics for patients.

223

NEW CONCEPT OF THE RADICAL OPERATIONS FOR HILAR CHOLANGIOPHYSIOMA

Yu. Kovalenko¹, Yu. Zharikov², V. Vishnevsky¹, A. Zhao¹
¹A.V. Vishnevsky Centre of Surgery; ²-Sechenov First Moscow State Medical University Russia

Background. Radical surgical operation for hilar cholangiocarcinoma allows to increase of survival, however recurrence after R0-resection reaches 75% in the first 2 years after operation.

Purpose. To evolution new criteria of radical operations in patients with hilar cholangiocarcinoma.

Methods. From 1986 to 2017 in A.V. Vishnevsky Centre of Surgery operated 172 patients with hilar cholangiocarcinoma. TNM stage distribution: stage I – 5 (2,9%), II – 50 (29%), IIIA – 23 (13,4%), IIIB – 42 (24,4%), IVA – 35 (20,3%), IVB – 17 (9,9%). Bismuth-type IV tumor was 53 (35,6%), IIIa – 14 (9,4%), IIIb – 35 (23,5%), II – 20 (11,6%), I – 16 (10,7%) (total n=149). 101 (58,7%) patients underwent major hemihepatectomy. 71 (41,3%) patients underwent minor hepatectomy. The influence histological differentiation (n=48), invasion depth (n=36), microvascular invasion (n=35), lymphatic invasion

(n=34), N-status (n=49), perineural invasion (n=36), microscopic liver invasion (n=35), wedge resection (n=49), surrounding adipose tissue invasion (n=39) on survival were tested by the Cox's models.

Results. 5-year survival for resections with negative wedge resection was 34,6%. 5-year survival rate for resections with positive wedge resection was 0%. Wedge resection, nodal status, microvascular invasion, microlymphatic invasion, perineural invasion, microscopic liver invasion, surrounding adipose tissue invasion were used as new criteria for curability (R+, from 1 to 7 factors). For status R0 are negative 7 factors. For status R1 (R+1, R+2) are negative 5 factors. For status R1+ (R+3, R+4, R+5, R+6, R+7) are positive from 3 to 7 factors. 5-year survival rate was 100% for R0 and R1 resections and 55 months survival rate (largest) was 18% for R1+ resections (p=0,004).

Conclusions. The new radical criteria of operations are necessary for optimization of strategy in treatment for hilar cholangiocarcinoma.

choscopy; in 1221 cases concretions smaller than 6 mm with a basket of Dormia were removed; in 647 observations the size of the stones exceeded the diameter of the fistula formed and they were destroyed by contact shock wave lithotripsy. Another 553 patients were found to have strictures of the terminal part of the choledochus, which was the basis for performing antegrade endoscopic papillosphincterotomy. Patients with strictures of the upper parts and biliodigestive anastomosis performed 128 balloon dilations. Complications included perforation of the fistula, which occurred in 34 patients (2%). Acute cholangitis against the background of manipulations in narrow ducts developed in 47 patients (2.8%), but was in mild form and did not require additional appointments. The lethal outcome was registered in 1 patient (0.05%). Analyzing the results, we were convinced of the high efficiency and feasibility of the method and the concentration of such patients in specialized centers. The experience gained can be useful in other regions of the Russian Federation.

224

STEP-BY-STEP TREATMENT OF PATIENTS WITH COMPLICATED FORMS OF GALLSTONES BY ENDOSCOPIC SURGERY THROUGH EXTERNAL BILE FISTULAS

A. Kovalevskii

"Step-by-step treatment of patients with complicated forms of gallstones by endoscopic surgery through external bile fistulas». The problem of treatment of patients with cholelithiasis, entering small surgical hospitals, continues to be one of the most urgent. Small hospitals of the General health care network provide emergency surgical care to the majority of the population of our country. The lack of planned operational sanitation of the population, especially in rural and sparsely populated areas, leads to an increase in the number of patients with complicated forms of cholelithiasis, the prevalence of forced operations, for urgent reasons, including patients of older age groups, whose incidence of cholangiolithiasis can reach 46%. In the period from 2002 to 2017, 1656 patients with complications from the gastrointestinal tract were treated in UIA GKB №14 of Yekaterinburg, who had previously undergone cholecystectomy with drainage of the bile ducts in hospitals of the Sverdlovsk region and the city of Yekaterinburg. First, within 3-4 weeks of drainage Percival formed access to the ductal system. Then perform the primary surgical technique, using a combination of direct visual control using a choledochoscope and remote fluoroscopy. In total, 4137 respectable endoscopic operations and manipulations were performed during this period. Of 1559 patients, T-shaped drainage was equipped. In 97 cases, drainage was carried out through the cystic duct stumps, which required a preliminary fugitive fistula. Of the total number of operations performed: 1357 diagnostic choledo-

225

DUODENUM-PRESERVING SUBTOTAL PANCREATIC HEAD RESECTION AND TOTAL PANCREATIC HEAD RESECTION WITH SEGMENTAL DUODENECTOMY IN CHRONIC PANCREATITIS

I. Kozlov, M. Baydarova, T. Shevchenko, V. Vishnevsky, A. Chzhao

A.V. Vishnevsky Institute of Surgery, Moscow, Russia

Relevance: The relevance of the study is due to the high frequency of choice of pancreaticoduodenectomy in surgical treatment of chronic pancreatitis.

Objectives: To estimate possibility of performance and results of the duodenum-preserving pancreatic head resections in chronic pancreatitis as alternatives to pancreaticoduodenectomy.

Method: 106 patients underwent duodenum-preserving subtotal pancreatic head resection (DPSPHR) or total pancreatic head resection combined with segmental duodenectomy (PHRSD). DPSPHR (Beger's or Kimura's procedure) was performed in 83 patients with a preoperative diagnosis of chronic pancreatitis with inflammatory mass of the head of the pancreas in case of suspected cancer. Alimentary tract reconstruction after DPSPHR was performed by pancreatojejunostomy (Roux-en-Y). Pancreatojejunostomy (Beger's procedure) was formed with the distal and proximal stump of the pancreas (n=67) or with the distal stump of the pancreas only (Kimura's procedure) (n=16). PHRSD was performed in 23 patients with chronic pancreatitis complicated by cystic (n=21) and fibrous forms (n=2) of duodenal dystrophy. Alimentary tract reconstruction was performed in all patients by duodenoduodenostomy combined with pancreatojejunostomy and choledochojejunostomy (Roux-en-Y)

(n=7) – first option; pancreatogastrostomy and choledochoduodenostomy (n=14) – second option, pancreaticoduodenostomy duct-to-mucosa and choledochoduodenostomy (n=2) – third option. Choledochoduodenostomy was carried out below the duodenoduodenostomy level always.

Results: Surgical parameters, postoperative complications, endocrine function, exocrine function, and long-term outcomes were evaluated. No differences were noted in the mean operation time and estimated blood loss between the two procedures and pylorus-preserving pancreaticoduodenectomy. Ischemia of duodenum didn't note in one case of DPSPHR. Careful attention paid to superior posterior pancreatico-duodenal artery preservation when performing DPSPHR. Major postoperative complication constituted the following: bile duct stricture (n=4) and postoperative bleeding (n=6) in DPSPHR, delayed gastric emptying (n=2) and postoperative bleeding (n=1) in PHRSD. Newly developed diabetes mellitus occurred in 12 patients. Exocrine pancreatic insufficiency after PHRSD was observed in 2 patients with chronic pancreatitis. There was no hospital or long-term mortality.

Conclusions: DPSPHR is recommended first for chronic pancreatitis with inflammatory mass of the head of the pancreas in case of suspected cancer. PHRSD is a safe and reasonable technique appropriate for selected patients with chronic pancreatitis complicated by duodenal dystrophy. Thus PHRSD can be an option for a lesion of the duodenal area as well as the pancreatic head. We found benign periampullary lesions could be conservatively treated with DPSPHR and PHRSD, which could substitute for pylorus-preserving pancreaticoduodenectomy.

226

RARE CASE OF SMALL BOWEL PERFORATION

M. Kozlov, N. Melnik, I. Lukyanchenko, S. Pyatakov, A. Lyutov

Municipal budgetary health-care institution, city of Sochi «City Hospital No 4», Sochi, Russia

Applicability: Growing popularity number of diagnostic manipulations under sedation explains the increasing number of complications as well. Same-day bidirectional endoscopy Esophagogastroduodenoscopy and colonoscopy became attractive for the patients. The number of gastrointestinal tract combined investigations in Sochi major medical facilities significantly increased in the last few years.

Methods and materials: 47 y.o . male sought medical help with complaints on acute stomach pain. HPI: Pt had bidirectional endoscopy (Esophagogastroduodenoscopy and colonoscopy) done 3 hours ago. At physical and instrumental examination Pt was diagnosed with peritonitis. After preoperative assessment, Pt was taken to the surgery room. It is worth noting, that the Pt had laparotomy in the past in

connection to destructive appendicitis. In abdominal cavity turbid exudate with intestinal contents , moderate adhesive process found. During ileum loop separation, in 100 sm from ileocecal angle , perforation opening D -15mm is detected, which initially considered to be a result of adheolysis iatrogenic injury. While further revision of abdominal cavity , no other solution of continuity in hollow viscus found. Taking into consideration occasional nature of ileum bowel perforation, and very recent colonoscopy, intraoperational colonoscopy and gastroscopy were indicated. No perforation of segmented intestine, gaster and dodecadactylon was found, bubble-test performed. On colonoscopy dehiscence of ileocecal valve and excessive amount of gas drawn our attention. Perforation opening of the bowel was sealed. Patient was discharged in satisfactory condition on the 8th day.

Result: Insufflation on colonoscopy, ileocecal valve dehiscence and excessive amount of gas as a result, adhesive process of abdominal cavity lead to ileum bowel perforation.

Conclusion: Adhesive process of abdominal cavity normally involves small bowel only. Possible complications should be kept in mind, when colonoscopy performed on Patients with adhesion process peritoneal adhesions in abdominal cavity.

227

MANAGEMENT OF BILE DUCT INJURIES AFTER LAPAROSCOPIC CHOLECYSTECTOMY IN A TERTIARY REFERRAL CENTER: A SERIES OF 74 CONSECUTIVE CASES

A. Kraft, F. Botea, M. Ionescu, V. Braşoveanu, D. Hrehoret, M. Eftimie, C. Gheorghe, I. Lupescu, M. Grasu, D. Tomescu, G. Droc, I. Popescu

¹“Dan Seilacec” Center for General Surgery and Liver Transplant, “Fundeni” Clinical Institute, Bucharest, Romania

²The Gastroenterology and Hepatology Center,

“Fundeni” Clinical Institute, Bucharest, Romania

³The Radiology and Medical Imagistics Department,

“Fundeni” Clinical Institute, Bucharest, Romania

⁴The Anaesthesia and Intensive Care Department,

“Fundeni” Clinical Institute, Bucharest, Romania

⁵“Titu Maiorescu” University of Medicine, Bucharest, Romania

⁶“Carol Davila” University of Medicine and Pharmacy, Bucharest, Romania

Aim: To report our experience of perioperative multidisciplinary management of post-laparoscopic cholecystectomy BDIs.

Methods: All patients treated in our institution for BDI between 2002-2017 were retrospectively analyzed.

Results: In total, 74 consecutive patients (24 men), median age 55.5 (range 17-78) met the above inclusion criteria of the study. 63 (85.1%) patients had sustained BDI at a

different center. 29 (46%) of them had undergone unsuccessful attempts of surgical management in other centers, prior to admission in our Department: 6 (9.5%) had anastomosis fistula. BDI was recognized during cholecystectomy in 8 (10.8%) patients, and postoperatively in 66 (89.2%). The main clinical presentations were: 27 external biliary fistulas (36.5%), 23 obstructive jaundice (31.1%), 17 recurrent cholangitis (23%), and 4 choleperitoneum (5.4%). Following Strasberg classification, 13 (19.4%) fell under type A, 1 (1.5%) B, 3 (4.4%) C, 6 (8.9%) D, 7 (10.5%) E1, 21 (31.3%) E2, 8 (12%) E3, 6 (8.9%) E4, 2 (3%) E5. The mean interval from time of BDI to repair was 48.8 wks (range 0-710 wks). The average length of stay was 20.8 days. 14 (18.9%) patients (type A, D, E3 and anastomosis fistula - following attempt at repair in other centers) were treated conservatively in our institution, by combinations of endoscopic and/or percutaneous treatments. 60 (81.1%) patients underwent definitive biliary reconstruction, including 42 (70%) hepaticojejunostomies, 12 (20%) direct repair and T-tube placement, 11 (18.3%) segmental biliary tract resection, 3 (5%) hepatic resection (right hepatectomy, bisegmentectomy II-III, right posterior sectionectomy), 2 (3.3%) hepaticoduodeno- and choledocoduodeno-stomies, 2 (3.3%) direct closure of a cystic leak. Concomitant right hepatic artery injury was demonstrated in 3 (4.05%). Morbidity rate 40% - 24 patients; most common complications: 7 biliary fistulas (29.1%), 6 intraabdominal abscess/bilioma (25%), 3 acute pancreatitis (12.5%), 3 sepsis (12.5%), and 2 wound infection (8.3%). 7 (11.6%) patients required reoperation in the postoperative period, consisting in: redo of hepaticojejunostomy (14.2%), abscess evacuation and drainage (85.7%), bile duct suture (28.5%). Postoperative interventions included: percutaneous abscess drainage 6 (10%); new percutaneous trans-hepatic cholangiography with stent placement 9 (15%). Postoperative mortality 6.6% - 4 patients; causes: uncontrolled sepsis after delayed referral 25%, pulmonary embolism 25%, bile peritonitis with systemic sepsis 50%.

Conclusions: Early referral to a tertiary care center providing multidisciplinary approach is of paramount importance to assure optimal results.

Key Words: Laparoscopic Cholecystectomy, Bile Duct Injury (BDI), Perioperative Management, Tertiary Referral Center. **Background:** Laparoscopic cholecystectomy, although commonly performed, remains associated with significant major morbidity, like bile duct injuries (BDI). Despite their frequency, optimal management is still debated.

228

PLACE OF THE ORGAN PRESERVING PROCEDURES IN TREATMENT OF PANCREATIC NEUROENDOCRINE TUMORS

A. Kriger, S. Berelavichus, A. Kaldarov, D. Gorin

A.V. Vishnevsky Institute of Surgery, Ministry of Health, Russian Federation

Background: pancreatic neuroendocrine tumor (NET) is tumor with the different malignant potential which can be finally diagnosed on morphological specimen examination. There is no universal treatment position for small benign pancreatic NETs (pNETs). Organ preserving procedures (OP) such as tumor enucleation and middle pancreatectomy can become an option in difficult cases and give a maximal benefit with minimizing of postoperative complications.

Aim: to improve results of treatment patients with pancreatic neuroendocrine tumors.

Material and methods: There were 137 patients with pancreatic NETs surgically treated for the period of 2007 – 2017 years in abdominal department №1 of A.V.Vishnevsky Institute of Surgery, Moscow, Russia. Most of them were female – 96 cases.

Results: most of the patients both in organ preserving (OP) and standard procedures (SP) groups were females with comparable median age 48 (38; 54) and 51 (41;62). Morphological specimen examination revealed that in the mean tumors diameter was significantly less in OP - 19 vs. 25 mm SP group, the similar difference in groups were in Ki67 Index and mitotic rate. There was significantly less estimated blood loss volume in OP group. Postoperative LOS and drainage placement time were although less in OP group but without significant difference.

Conclusion: the organ preserving procedures can become an option to treatment of small benign pNETs. It has better preoperative results with minimal parenchyma removal. Unfortunately there are not enough investigations in survival after OP comparing with standard procedures and wait-and-see position.

229

RESULTS OF ROBOT-ASSISTED PANCREATIC SURGERY MAJOR SINGLE-CENTRE RUSSIAN EXPERIENCE

A. Kriger, S. Berelavichus, A. Kaldarov, D. Gorin

A.V. Vishnevsky Institute of Surgery, Moscow, Russia

Background. Robotic technology is a fast developing part of contemporary surgery. There are insufficient researches about feasibility of the robotic pancreatic resections. We present our single-centre experience in the robot-assisted pancreatic surgery.

Aim. To estimate the feasibility of using robotic complex in

pancreatic surgery.

Material and methods. 93 patients were surgically treated for the period between 2009 and 2017 using robotic complex “DaVinci S” due to pancreatic tumors in abdominal department №1 A.V.Vishnevsky Institute of Surgery, Moscow, Russia. There were performed 17 pancreaticoduodenectomies, 49 distal pancreatectomies, 19 tumor enucleations, 6 median pancreatectomies and 2 total duodenumpancreatectomies.

Results. Operation time depended of surgeries volume: during pancreaticoduodenectomy it was 400 (360;505) min, distal pancreatectomy – 210 (178;250) min. Average blood loss in pancreaticoduodenectomy was 200 (150;500) ml, in distal pancreatectomy – 100 (50;300) ml, tumor enucleations and median pancreatectomies – minimal blood loss. Conversion to laparotomy was performed in 4 cases: 2 in pancreaticoduodenectomy, 1 in distal pancreatectomy and 1 in tumor enucleation. Postoperative complications occurred in 38 cases: there were 35 pancreatic fistulas; on the background of pancreatic fistula in 6 cases postpancreatectomy haemorrhage occurred.

Conclusion. Initial indications for robot- assisted procedures are malignant and borderline malignant pancreatic T1-T2 staged tumors, also benign tumors less than 5 – 6 sm. With learning curve indications for robot-assisted pancreatic surgery can be extended. Robot-assisted technology do not afford significant decrease quantity of postoperative complications.

230

A MID-TERM FOLLOW-UP ANALYSIS OF MIXED TYPE INTRADUCTAL PAPILLARY MUCINOUS NEOPLASMS UNDERGOING NON-SURGICAL MANAGEMENT

Atsushi Kubo, Masahiro Morita, Akina Omura, Teruyo Noda, Chikara Ogawa, Toshihiro Matsunaka, Hiroyuki Tamaki, Mitsushige Shibatoge,
Department of Gastroenterology, Takamatsu Red Cross Hospital, Takamatsu, Japan

Background & Aim; In the IPMN/MCN international consensus guidelines 2012, mixed type IPMNs (MX-IPMN) have changed from rather immediate resection to more deliberate observation and evaluation. In the previous guideline, surgical resection is recommended for all surgically fit patients. Natural course for MX-IPMN has been limited and still unclear. So we don't know how long their follow-up is appropriate and whether the increase in how much of the pace is. The aim of this study was to evaluate mid-term outcomes of MX-IPMN with no surgical resection.

Method; 534 patients with IPMN were treated in our institute from January, 2006 to November, 2017. 59 patients with MX-IPMN (MPD \geq 5 mm and cyst \geq 20 mm) had no surgical resection and more than 1-year imaging follow-up.

They were identified and their cases reviewed retrospectively. **Results;** Of 59 patients, the mean age was 74.7 ± 7.1 years (34 over 70 years, 13 over 80 years) and male was 71.2 %. 53 had “worrisome features” (WF), 6 “high-risk stigmata” (HF), and 2 mural nodule. The initial median size of the MPD dilation and the cyst was 5 mm (5-15) and 33 mm (20-61) respectively. The median observation period was 58.4 months (12.3-141.7). 46 patients (78.0%) of 59 exhibited progression (40/53 among WF group, 6/6 HF group, no significant difference). The details of progression were 25 cases with an increasing MPD diameter, 43 cases with an increasing cyst size, and 12 cases with appearance and/or enlargement of mural nodule (included overlapping). The median progression rate of MPD dilation and cyst size was 0.59 mm/year (0.18-4.78) and 1.96 mm/year (0.36-21.53) respectively. Compared with WF group, HS group had no significant difference of each progression rate. Surgical resection after follow-up was performed in 5 of 59 patients with progression (1 of invasive IPMC, 1 of high grade dysplasia, 2 of low grade dysplasia and 1 of located autoimmune pancreatitis). 13 patients were died (2 of invasive IPMC, 1 of pancreatic cancer, 2 of biliary cancer and 8 of cancer of other organ). The 5-year survival of MX-IPMN was 78.3%.

Conclusion; The progression rate of MX-IPMN was extremely high during this follow-up period, but few 3 patients died of IPMC and pancreatic cancer. Additionally, it is no significant difference of progression rate between WF group and HS group. This study suggested we could expect clinical course and progression rate for MX-IPMN with no surgical resection. Both group could have been observed, if malignant findings (mural nodule >5mm etc.) were not revealed. It is highly important that we decide how long we observe patients with MX-IPMN and when we suggest surgical resection to them with careful imaging follow-up toward incidence of IPMC and pancreatic cancer.

231

WHICH IS BETTER TIMING EARLY OR LATE TO CLOSE COVERING STOMA AFTER LOW ANTERIOR RESECTION FOR RECTAL CANCER?

Tadao Kubota, Ken Mizokami, Masaki Kanzaki, Kazuhiro Nishida, Jiro Kimura, Shingo Sasamatsu, Kentaro Yoshikawa, Shota Fukai, Naokazu Takata, Akiko Watanabe, Katsudai Shirakabe, Manako Kato
Department of General Surgery Tokyo Bay Medical Center

Relevance And Object: Staged surgery is sometimes applied for the case of rectal cancer. 1st surgery is low anterior resection with making a covering stoma (loop ileostomy is preferred) and 2nd surgery is stoma closure. To close the covering stoma, we have two options. One is late stoma closure, in which the closure was done with an interval of several months after 1st surgery. The other is early closure,

in which 2nd surgery was done in a couple of weeks within a same admission. In this study, we compared these two strategies.

Materials And Methods: We reviewed our cases of staged surgery for rectal cancer and compared the total lengths of each stay and total costs, from 2014 to 2017. Late closure is assigned as an Interval closure group (= Group I), and early closure group was assigned as a group of same admission (Group S).

Results: There were five cases of group I and six cases of group S. The differences of its age and sex were not statistically significant. Total length of stay was 36.6 days in group I and was 35.2 days in group S. Total cost was \$ 7,089(mean) in group I, and was \$ 5,589(mean) in group S, except for the surgery costs.

Conclusion: total length of stay was same in each group, and the cost of group I was slightly higher than that of group S. It took about ten times of visiting to outpatient department to care one's stoma for the patients during the interval in group I. There was no stoma care at home for the patients of group S, however 1st hospitalization was longer than group S. Each strategy is feasible, and it should be applied for a patient in an option most consistent with one's wishes by understanding the difference.

232

IMPROVEMENT RESULTS OF TREATMENT PANCREATIC ADENOCARCINOM

D. Kuchin, N. Kiselev, V. Zagainov
Russia

Relevance: Pancreatic cancer is the 6th most common oncological disease. The biology of the tumor is significant aggressive. Five-year survival in patients receiving undergoing systemic treatment does not exceed 15%. Pancreaticoduodenectomy is the first line of treatment for patients with adenocarcinoma of the head of the pancreas.

Aim: Improvement results of treatment pancreatic adenocarcinoma.

Materials and methods: Analyzed 215 patients with ductal adenocarcinoma which were underwent pancreaticoduodenectomy.

Results: Analyzed correlations between survival and volume of operation (standart vs extendet), tumors perineural invasion, lymph node damage (negativ vs positiv). None of the factors showed a significant effect on long-term survival. Only R0-resection significantly increase the median survival from 11 to 16 months. In cases of involvements of vein by tumors overall survival is reduced only in group of patients who have histologically authentically proven a true vascular invasion compared to the group without invasion (even if the vessel was resected) (10 vs. 16 months). Overall survival is higher in group of patients with G1 adenocarcinoma com-

pared to groups G2 and G3 adenocarcinomas (median 22 vs. 13 months). Adjuvant chemotherapy significantly increases the median survival rate from 12 months to 35 months. By retrospectively analysis with account factors of negative prognosis was singled out group of patients treated without chemotherapy but have a good long-term results. This group included patients with G1 pancreatic head adenocarcinoma, without a true vascular invasion. The five-year overall survival in this group was 52%.

Conclusion: Patients with G1 adenocarcinoma of the head of the pancreas without true invasion in main vessels have a better results of overall and disease-free survival.

233

ENDOSCOPIC TREATMENT OF METASTATIC MALIGNANT MELANOMA OF STOMACH

Y. Kudryavitsky¹, K. Ryabov², I. Perfilyev³, S. Pirogov³, T. Bayramova⁴, E. Bokova⁵

¹*V.M. Buyanov City Clinical Hospital, Moscow, Russia*

²*D.D. Pletnev City Clinical Hospital, Moscow, Russia*

³*P.A. Gertsen Moscow Research Oncology Institute, Moscow Russia*

⁴*Russian Medical Academy of Postgraduate Education, Moscow, Russia*

⁵*Sechenov First Moscow State Medical University, Moscow, Russia*

Relevance. A malignant melanoma of the digestive tract is a rather rare condition. At the moment there is no gold standard of metastatic melanoma treatment. Surgical excision is usually the preferred treatment for those with primary melanoma. According to current recommendations, melanoma metastases of any localization are to be excised. Radical endoscopic resection is most likely to be effective for patients with metastatic malignant melanoma of the gastrointestinal tract.

Aim. We report a case of gastric metastatic malignant melanoma treated with endoscopic mucosal resection. This method may give promising results (more than 2 years without recurrences) in patients with this diagnosis.

Materials and Methods. A 57-year-old man underwent an excision of a cutaneous femoral T3aN0M0 melanoma in 2008. In 2011 he had a neuroendocrine tumor of the pancreatic tail treated with subtotal pancreatic resection and splenectomy. Two years later the melanoma was discovered to have metastasized into the lower third of the gastric mucosa. The patient had a complete endoscopic mucosal resection performed. Histologic examination confirmed R0 resection of the tumor having confined to the superficial layers with invasion into the submucosal layer. In 2015 metastases of the neoplasm were discovered in the soft tissue of the back, in 2017 – in the right radius (osteosynthesis was performed), soft tissue of the back and left

retroperitoneal lymph nodes. In 2018 the patient was treated with Nivolumabum/Pembrolizumabum and Zoledronic acid.

Results. After the endoscopic mucosal resection the relapse-free period was recorded as 27–29 months. Surgery, combined with neoadjuvant therapy, remains the first-line treatment, or the salvage therapy of metastatic melanoma. Endoscopic resection is an effective treatment of mucosal malignant neoplasms. Currently the first-choice treatment of patients with malignant melanoma and one or few solitary metastases is a complete surgical resection with intact margins. According to some authors, the 5-year survival after sequential complete resection is about 19%. Complete resection is predicted to give a better prognosis (75% 1-year survival) than the incomplete one (25% 1-year survival).

Conclusion. Complete endoscopic mucosal resection may be an effective mini-invasive treatment of metastatic malignant melanoma with solitary mucosal metachronous metastases.

Keywords: endoscopic resection, melanoma, surgical treatment, EMR

234

EXPERIENCE OF PERCUTANEOUS BALLOON DILATATION WITH LONG-TERM TRANSHEPATIC BILIARY DRAINAGE IN TREATMENT OF BENIGN BILIODIGESTIVE ANASTOMOSIS STRICTURE

J. Kulezneva, O. Melekhina, I. Patrushev

Moscow Clinical Scientific Center of A.S. Loginov, Moscow, Russia

Background. Percutaneous balloon dilatation (BD) with long-term transhepatic biliary drainage has become the treatment of choice in patients with benign biliodigestive anastomosis (BDA) strictures since endoscopic procedures are usually not possible and surgical treatment is challenging and associated with high recurrence rate.

Aim. To determine the short-term effectiveness of BD in benign anastomotic strictures treatment.

Materials and methods. From 2015 to 2018 patients with benign strictures of BDA were referred for BD and transhepatic biliary drainage. BD was applied in patients with stricture of BDA after hepaticojejunostomy, which was previously performed for iatrogenic bile duct trauma during cholecystectomy or in patients underwent bile duct resection for biliary and pancreatic malignancy. The first step of treatment included percutaneous approach with the first balloon dilatation following by internal-external drainage placing. Elective BD with transhepatic drainages changes were performed at 2,5-3 month intervals until no balloon waists were observed on 2 consecutive sessions.

Results. A total of 68 patients (48 female, 20 male; mean age

- 53) had 320 surgical procedure (74 PTBD and 246 BD with transhepatic drainage change). At the first step of treatment it was unable to pass the stricture with a guidewire in seven patients, due to complete bile ducts occlusion. In five patients after transhepatic canal forming and unsuccessful attempts to cross the stricture, a neo-biliodigestive anastomosis was created using a guidewire rigid tip to perforate scar tissue and bowel wall under fluoroscopy control. In two of these patients, the neo-anastomosis formation was carried out under the control of antegrade percutaneous cholangioscopy, which in one case was supplemented with intraductal endo-ultrasound. Repeated attempts to create neo-anastomosis were unsuccessful in two patients. These patients underwent surgical intervention. Overall morbidity rate was 21% without mortality. All complications were treated with conservative therapy and/or minimally invasive surgery. The transhepatic drainage tubes were successfully removed in 35 (51%) patients. The median follow-up was 13.7 month (1-41 mo). The recurrent biliary stricture was noticed in one patient (1,5%) at 3rd year after treatment was completed. In three patients the recurrence of oncological disease was observed.

Conclusions. According to our initial experience, percutaneous BD with long-term transhepatic drainage is an effective treatment for benign BDA strictures. Further long-term results will be evaluated in order to clarify the efficacy percutaneous treatment of benign bile duct strictures.

235

THE MAIN PROPERTIES OF POROUS TITANIUM IN THE MANUFACTURE OF MEDICAL INSTRUMENTS

V. Kulikov¹, M. Sazonenkov², S. Lavrov³

¹Medical Institute of the Belgorod state national research University, Belgorod

²Belgorod regional clinical hospital of St. Ioasaf, Belgorod

³limited liability company Agrovi., Belgorod

Brief description of the article: Cryomedicine is relatively young: this science, which studies the impact of ultra-low temperatures on the human body, was formed in the 70s of the XX century. The development of cryomedicine in modern conditions has led to the creation of new materials and methods of work with them. This has led to the widespread use of materials with a porous structure. The principle of operation of the cryoapplicator and cryovalics is reduced to the absorption of liquid nitrogen into the pores of the instrument, followed by the return of the "accumulated cold" to the local area of cryotherapy. The porous structure of the instruments retains liquid nitrogen without leaking it to complete evaporation (usually 0.5 – 4 minutes). Subsequently, liquid nitrogen evaporates and maintains the cryogenic properties of the applicator and roller for the entire period of exposure. When using the device with a

porous work items result cryosurgery cumulative effect of chilled vapor liquid nitrogen contained in the pores of the work item and the work item that is chilled to ultra-low (-196°C) temperatures, resulting in instantaneous removal of heat from the contact surfaces of tissues. Evaporating nitrogen, creating a pillow, prevents the cryoinstriction from sticking to the exposed tissue. Thus was formed one of the problems of manufacturing cryoinstrument-the creation of a porous material with a higher volume fraction of the pores, capable of holding capillary forces a larger volume of liquid nitrogen without its runoff from the material. In this case, the material must meet the requirements for strength and viscosity, resistance to thermal Cycling, aesthetics and geometry of the tool. A useful model of cryoinstruments made of porous titanium was created and Patent No. 172978 "Cryosurgical endocardial applicator" was registered. One of the solutions to the above posed problem is to develop Agrovi, OOO (Belgorod) - cryoinstruments of porous titanium. Experience with the use of cryoapplication and krivelyova of porous titanium in fsbi "Institute of surgery. A. V. Vishnevsky", Federal state budgetary institution "national medical research center of Oncology. N. N. Blokhin" of the Russian Ministry of health, Military medical Academy named after S. M. Kirov, Saint-Petersburg State budgetary healthcare institution "City clinical oncological dispensary" of RSBEPH "Belgorod regional clinical hospital of Prelate ioasafa" and other medical institutions, create a database of methods and technologies of working with biomeditsinskie tools. Private use biomeditsinskih instruments of porous titanium – criocerinae medicine of productive and unproductive livestock.

Key words: Cryomedicine. cryoapplicator, cryo roller, porous titanium

236

PERCUTANEOUS RADIO-FREQUENCY ASSISTED LIVER PARTITION WITH PORTAL VEIN EMBOLIZATION IN STAGED LIVER RESECTION (PRALPPS) IN PATIENTS WITH PERIHILAR AND INTRAHEPATIC CHOLANGIO-CARCINOMA

N. Kulikova, O. Melekhina, R. Alikhanov, V. Tsvirkun, Y. Kulezneva, I. Kazakov, P. Kim, A. Vankovich, I. Khatkov, M. Efanov

A.S. Loginov Moscow Clinical Scientific Center, Moscow, Russia

Actuality. Curative resection is the only potential treating and opportunity to prolong survival in patients with cholangiocarcinoma which can be treated radically in 10-40% of cases. Unsatisfactory immediate outcomes of associating liver partition and portal vein ligation for staged hepatectomy (ALPPS) in surgery of cholangiocarcinoma suggested that patients with biliary cancer should not be treated by ALPPS. Short-term results of ALPPS variants with reduced surgical

trauma on the first stage in patients with cholangiocarcinoma remain underestimated.

The aim. We aimed to evaluate the short-term results of Percutaneous Radio-frequency Assisted Liver Partition with Portal vein embolization in Staged liver resection (PRALPPS) compared with Portal Vein Embolization (PVE) and subsequent major liver resection in patients with perihilar (PHCC) and intrahepatic (IHCC) cholangiocarcinoma.

Materials and methods. In retrospective observational case-control study PRALPPS and PVE were applied in 12 and 18 patients. The volume of future liver remnant (FLR) was estimated by CT. PRALPPS/PVE were indicated for patients with volume of FLR<40%. Contraindications for PRALPPS/ PVE considered as jaundice with total bilirubin >50 µmol/L; acute cholangitis and/or infected fluid collections, liver abscesses and other unresolved surgical complications of biliary draining procedures; prior anamnestic allergic reaction or any other sign of intolerance to iodinated contrast media. The maximum level of total bilirubin, duration of jaundice and presence of acute cholangitis were analyzed as the factors influence the rate of liver hypertrophy. The rate of hypertrophy was calculated using the standard formula: $[(\text{Post-PVE FLR} - \text{Pre-PVE FLR}) / (\text{Pre-PVE FLR})] \times 100$.

Results. The mean rate of FLR hypertrophy after PRALPPS/PVE was 43% and 32%, respectively. The mean duration of hypertrophy after PRALPPS/PVE was 17 and 20 days, respectively. Major morbidity rate (only IIIa grade, Clavien-Dindo) after the stage 1 was significantly larger for PRALPPS. There were no differences in blood loss, severe morbidity and liver failure rate after the stage 2.

Conclusion. According to preliminary short-term results estimation PRALPPS may be considered as an effective and safe minimally invasive variant of ALPPS for rapid FLR hypertrophy in patients with PHCC and IHCC.

237

EFFECT OF BACTIBILIA ON THE OUTCOME OF PATIENTS WHO UNDERWENT WHIPPLE'S PANCREATICO-DUODENECTOMY-A RETROSPECTIVE STUDY

Sree G Kumar, Manikandan, Puneet Dhar
Amrita Institute of Medical Sciences, Kochi

Relevance: TMultiple studies have shown that bactibilia is associated with increased morbidity and mortality following Whipple's pancreaticoduodenectomy.

Object: To correlate between bile culture positivity and postoperative morbidity and mortality in patients undergoing Whipple's pancreaticoduodenectomy and compare it with those without bactibilia.

Materials and methods: 200 patients underwent Whipple's pancreaticoduodenectomy in department of Gastrointestinal Surgery in Amrita institute of Medical Sciences, Kochi during the period 2010 to 2017. Their data was analyzed retrospec-

tively in terms of bile culture positivity and their risk in morbidity and mortality. Out of these 88 had bile culture positivity (Group 1) and 122 had bile culture negativity (Group 2). Post-operative ICU stay, hospital stay, duration of surgery, need for intraoperative blood transfusion, pancreatic leak and wound infection was recorded. Bile culture positivity was compared with those patients who were stented. The patients with pancreatic leak were divided into 3 groups. Group A (62 patients) - those who had leak but no change in hospital stay. Group B (34 patients) - Those who required intervention like pigtail. Group C (26 patients) - Those who required re-exploration.

Results: Commonest organism was E Coli. Other organisms were Klebsiella, Enterococcus, Pseudomonas, Enterobacter, Staphylococci, Streptococci and few mixed. There was no association of bile culture positivity and duration of surgery. Mean duration being 8 hours, 52 minutes. There was no association of bile culture positivity and intraoperative blood transfusion. 25 out of 200 needed intraoperative blood transfusion. Bile culture positivity had no statistical significance with ICU stay and hospital stay. Mean ICU stay was 5.03 days and mean hospital stay was 14.91 days. Out of 200 patients, 47 patients had wound infection. Rates of wound infection in group 1 was 29.5% and group 2 was 18.8%. P value of 0.074 which is not significant. Out of 24 patients who died, 12 were bile culture positive but p value was insignificant. Thirty three patients were stented. 65% of patients for who were stented had bile culture positivity. 40% of patients for who were not stented had bile culture positivity. There was significant association between patients who were stented and bile culture positivity (p value: 0.008). 122 patients had pancreatic leak. 70.5% of patients with pancreatic leak were bile culture positive (p value=0.015) But on detailed analysis dividing them into 3 groups. 48.4% in group A, 27.4% in Group B and 24.2% in Group C had bile culture positive. This was statistically insignificant. An incidental finding that 68% non-diabetic patients had pancreatic leak (p value 0.009) which is significant was obtained.

Conclusions: Bile culture positivity has significant association with patients who underwent stenting. Bile culture positivity has significant association with patients who had pancreatic leak however its significance in various groups couldn't be established. Bile culture positivity otherwise have no significant impact on outcome of patients undergoing Whipple's pancreaticoduodenectomy especially in hospital stay, wound infection and mortality.

238

TIPS TO PREDICT OPERATIVE DIFFICULTY AND PRINCIPLES TO ASSURE THE SAFETY DURING LAPAROSCOPIC CHOLECYSTECTOMY

Kung-Kai Kuo, SC Chuang, JW Huang, WL Su, SN Wang, JS Chen, Lee KT

Director, Division of General and Digestive Surgery, Kaohsiung Medical University Hospital, Kaohsiung city, 817, Taiwan

Laparoscopic cholecystectomy is one of the most common procedures for the general surgeon. However, how to minimize the mortality and major complications (such as common hepatic duct (CHD) severance, duodenum or colon injuries, postoperative hemorrhagic shock --- etc) remains a concern for program directors. Any major complications might cause legal liability to the staff, increase hospital stay with cost, and damage program's reputation. During the past two years, near two thousand cases underwent (urgent or elective) laparoscopic cholecystectomy (three trocars in majority) by a group of HBP specialists in our institution, which is a tertiary care University hospital. We had no mortality and very few major complications from this procedure. Our crucial experiences include: meticulously dissecting out the Calot's triangle is important; "99% assumed" cystic duct might not be the true cystic duct, so only divide "100% confirmed" cystic duct; when applying clips, relaxing and avoid excessive traction of gallbladder; over usage of energy device in the Calot's triangle should be avoided; dome-down circumferential dissection of gallbladder neck, partial cholecystectomy, intraoperative cholangiography study, 3D image are all techniques or equipment to increase the operative safety. Preoperative images may provide some tips implying operative difficulty such as pneumobilia, which indicates possible bilioenteric fistula or gallstones ileus. CT/MRI coronary view can be used to examine whether Calot's triangle is obliterated by impacted stone in the Harman's pouch, which overlaid upon the common hepatic duct (figure B). In this situation, the cystic duct usually is short and runs forward, ventrally to the CHD, not right side, laterally to the CHD. They are warning signs for high risk of bile duct injury and require tremendous patience in dissection. Building a culture of safety by effective education, self-reflection and mutual sharing experience, in addition to a clear identification of cystic structure may minimize the major complications from laparoscopic cholecystectomy.

239

VENOUS THROMBOEMBOLIC EVENTS IN CANCER PATIENTS: ANALYSIS AND SOLUTIONS

T. Kutseva, V. Zuev

Tyumen', State Autonomous healthcare institution of Tyumen' region Multidisciplinary Clinical Medical Center 'Medical City', Russia

Relevance: the incidence of VTE among cancer patients can be as high as 20%; the frequency of VTE revealed on postmortem examination of cancer patients can be as high as 50%; and the risk of death of cancer patients who developed VTE is four times as high as this parameter in similar patients without VTE. VTE in cancer patients is an important problem that affects the incidence, mortality rate, quality of life and prognosis. In our institution, following the analysis of complications for a period of 6 years (since 2012), a Decree regarding VTE prophylaxis has been introduced. • High frequency of complications. • Low frequency of the use of prophylaxis. • Inadequate prophylactic measures. • Insufficient duration of prophylaxis. • Incorrect treatment. Goal - prophylactic administration of LMWH is indicated for all outpatients with malignancies who receive chemotherapy and those patients who will undergo surgery. Evaluation of the risk of VTE in all patients admitted to hospital for inpatient treatment. Introduction of thromboprophylaxis into clinical practice. Introduction of VTE treatment algorithms.

Materials - analysis of medical records of patients with venous thromboembolic complications, treatment options, strict following state-of-the-art recommendations that have been developed based on cumulative world experience of physicians of all specialties. Clinical cases demonstrating various treatment options for patients with VTE treated in Intensive Care Units.

Methods - 'therapeutic window' for effective thrombolytic therapy for pulmonary thromboembolism (PTE) is not more than 14 days since the onset of symptoms. Patients with suspected PTE should be considered potential candidates for thrombolytic therapy if new symptoms of the disorder had developed within 2 weeks before they were admitted to the hospital. Indications for the use of therapeutic doses of LMWH in patients who developed VTE.

Results: - adequate prophylaxis was used in 38% of patients in hospitals before 2013, when no special attention was paid to this issue; - in 62% of patients in hospitals, when physicians began to train to do it (lectures, clinical discussions) in 2013-2014; - in 97% of patients in hospitals, when this education was updated by the development and mandatory use of a local protocol for determination of risk groups and adoption of SOPs for dealing with complications.

Conclusions: 40% reduction in the frequency of VTE and 40% increase in the number of successfully treated patients of the total number of patients in our oncology clinic since 2017 compared to 2012 was due to the implementation of requirements defined by the Decree for VTE prophylaxis and treatment, their timely diagnosis and treatment.

240

PANCREATECTOMY WITH ARTERIAL RESECTION FOR LOCALLY ADVANCED PANCREATIC CANCER IN 109 PATIENTS

Kwon Jaewoo; Shin Sang Hyun; Kim Song Cheol; Hwang Dae Wook; Song Ki Byung; Lee Jae Hoon; Lee Young-Joo

Division of Hepato-Biliary and Pancreatic Surgery, Department of Surgery, University of Ulsan college of Medicine and Asan Medical Center, Songpa-Gu, Seoul South Korea

Relevance: Presence of arterial involvement of pancreatic cancer, only a few patient suitable candidates for surgery. And the treatment is known to be difficult because technically difficulty, high perioperative morbidity, mortality and limited oncological benefit. The limitations of current studies are that the number of cases is small and there is a debate about effectiveness after pancreatectomy with arterial resection. It is meaningful to see its short-term and long-term outcome when performing pancreatectomy involving arterial resection.

Object: We experienced 109 cases of pancreatectomy with arterial resection. The purpose of this study was to evaluate the postoperative outcome after extended pancreatectomy including arterial resection in large volume single center.

Materials and Method: Data of 109 patients who underwent pancreatectomy with arterial resection between January, 2000 and February 2018 were collected. All of patients showed pancreatic cancer with arterial invasion in CT image. The patients were performed distal pancreatectomy, pancreaticoduodenectomy or total pancreatectomy with arterial resection which include common hepatic artery, celiac axis or superior mesenteric artery. Demographics, operative and pathological outcome, postoperative short term and long term outcomes were analyzed. We compared neoadjuvant chemotherapy and upfront surgery group, and we also compared partial response and stable disease group after neoadjuvant chemotherapy about postoperative survival.

Results: 71 patients were male, mean age was 58.58 years. 38 patients (35%) treated neoadjuvant chemotherapy before surgery. Only 4 patients had laparoscopic surgery. Concomitant vein resection was performed to 62 patients (57%). Pathological arterial invasion cases were 25 (23%). 80 patients (74%) showed R0 resection. Postoperative pancreatic fistula was occurred in 14 patients (13%), Clavien-Dindo classification three or more stages were occurred in 14 patients and 90 days mortality was 1 case. Median progression free survival after surgery of all patients was 7.36 months and overall survival after surgery was 16.43 months. Positive lymph node ratio, lymphovascular invasion was smaller in neoadjuvant chemotherapy group, but the other pathologic outcomes were not different between two group. Partial response after neoadjuvant chemotherapy group (15 patients) showed better overall survival after surgery (30.13 months).

Conclusions: The morbidity, mortality, and survival outcome

after undertaking pancreatectomy with arterial resection for locally advanced pancreatic cancer is acceptable. More research will be needed, but performing pancreatectomy with arterial resection should be considered, especially in partial response after neoadjuvant chemotherapy.

241

LAPAROSCOPIC EXTRA-LEVATOR ABDOMINO-PERINEAL EXCISION OF RECTUM (ELAPE) RESULTS IN IMPROVED SHORT TERM RESULTS AS COMPARED TO THE OPEN ELAPE

A. Latif Khan, S. Sahel, Sh. L Khan, A. A Alsammahi, A. M Al-Hazmi

*King Faisal Specialist Hospital and Research Centre
Jeddah, Saudi Arabia*

Introduction. Traditionally, abdomino-perineal resection (APER), was performed for low rectal cancer not amenable to sphincter sparing surgery. Lately, ELAPE is increasingly being performed due to lower CRM positive rate and lower intra-operative perforation (IOP) rates as compared to APER. This is achieved by a wider excision of levator plates. However, there is limited literature on laparoscopic ELAPE (L-ELAPE). We looked at our short term results after the first 60 consecutive cases of ELAPE and compared L-ELAPE with Open ELAPE (O-ELAPE).

Methods. This is an ongoing prospective audit of one surgeon's experience in extra-levator abdomino-perineal excision of rectum (ELAPE) in Scotland and Saudi Arabia. We reviewed our short term results in particular the rectal perforation rate, positive CRM rate, readmission rate, re-operation rate, length of post-operative hospital stay, morbidity and mortality. We studied 9 patient-related variables and 6 tumour-related variables to assess their impact on the surgical outcome.

Result. The total numbers of procedures carried out were 60. These were consecutive cases of low rectal and anal cancers requiring definitive surgery. All patients followed ERAS (enhanced recovery after surgery) protocol. 50 patients underwent neo-adjuvant radio-chemo therapy to downstage the tumors. One patient with aggressive anal cancer did not respond to radio-chemotherapy and underwent ELAPE. 23 patients had L-ELAPE while 37 patients had O-ELAPE. 3 patients had positive CRM in L-ELAPE and 2 patients had a positive CRM in O-ELAPE. The overall positive CRM rate was 8%. The overall intra-operative tumour perforation rate was 7%. IOP rate was 4% in L-ELAPE vs 8% in O-ELAPE. The overall morbidity was 29% and the mortality was 2% (Massive MI in a patient with ischaemic heart disease). The readmission rate was 2%. The re-operation rate was 7%. There were no statistically significant differences between the two groups in any of these parameters. The median post-operative stay of patients in the hospital was

7 days. The median post-operative stay was 5 days after L-ELAPE and 9 days after open ELAPE. This difference was statistically significant (0.001)

Conclusion. We have achieved a low rate of CRM positive specimen and a reduced rate of perforation during ELAPE. There was, however no difference between the L-ELAPE and O-ELAPE. The median post-operative stay which is a good index of enhanced post-operative recovery, was much shorter after L-ELAPE.

242

ANTERIOR APPROACH FOR RIGHT HEPATECTOMY AND RIGHT ANTERIOR SECTIONECTOMY WITH HANGING MANEUVER FOR LARGE HEPATOCELLULAR CARCINOMA: A SINGLE-CENTER EXPERIENCE IN VIETNAM (WITH VIDEO)

Hieu Le Trung, Thanh Le Van, Quang Vu Van

*Department of Hepatobiliary and Pancreatic Surgery,
Central Military Hospital 108, Hanoi, Vietnam*

Relevance: Right hepatectomy and right anterior sectionectomy for large hepatocellular carcinoma via the anterior approach without prior liver mobilization is an accepted technique and the liver hanging maneuver facilitates this procedure. Hepatic parenchymal transection remains a critical part of this operation during which excessive blood loss can occur. Control of blood loss is important in hepatectomy as excessive bleeding and blood transfusion are associated with increased postoperative morbidity/mortality rates and compromised long term oncological outcomes in these patients.

Object: To report the surgical and preliminary outcomes of major right hepatectomy and right anterior sectionectomy for large hepatocellular carcinoma (HCC) using the anterior approach with hanging maneuver in single center in Vietnam.

Materials and methods: In patients who had large HCC (over 10 cm in size) at the right lobe of liver and underwent hepatic resection such as right hepatectomy or right anterior sectionectomy, the technique of anterior approach with the liver hanging maneuver was used. All consecutive patients who underwent elective right hepatectomy or right anterior sectionectomy in our center using this technique from March 2014 to July 2016 were retrospectively studied. This study aimed to describe this technique and report the preliminary outcomes.

Results: Twenty one patients with hepatitis B-related hepatocellular carcinoma (HCC) with cirrhosis underwent the technique for right hepatectomy and right anterior sectionectomy using the anterior approach with the liver hanging maneuver. The mean blood loss, liver parenchymal transection time and operation time were 280.3 ± 72.6 ml (SD), 49.3 ± 8.1 min, and 291.7 ± 58.2 min, respectively. No

patients developed postoperative bleeding or bile leak. There was no 90-day mortality.

Conclusions: To achieve complete anatomic hepatectomy in a large hepatocellular carcinoma (HCC), hepatic transection through an anterior approach is required. Liver hanging maneuver is a useful procedure for transection of an adequately cut plane in anatomical liver resection. It may reduce intraoperative bleeding and transection time, and it caused no major complications and mortality.

243

THE CLINICAL USEFULNESS OF C. DIFFICILE TOXIN ENZYME IMMUNOASSAY AND NUCLEIC ACID AMPLIFICATION TEST FOR THE DIAGNOSIS OF C. DIFFICILE-ASSOCIATED DIARRHEA IN A KOREAN UNIVERSITY HOSPITAL

Seungok Lee¹, Jeong-Seon Ji², Dong-Wook Jekarl¹, Hye-Jin Yoo¹

¹Department of Laboratory Medicine, Incheon St. Mary's Hospital, The Catholic University of Korea, South Korea

²Division of gastroenterology, Department of Internal Medicine, Incheon St. Mary's Hospital, The Catholic University of Korea, South Korea

Background. Clostridium difficile is a major infectious cause of antibiotic-related diarrhea, and the appropriate rapid laboratory tests is important for diagnosis of C. difficile infection from other causes of hospital-acquired diarrhea. The aim of this study was investigate the clinical usefulness of C. difficile toxin enzyme immunoassay (EIA) and nucleic acid amplification test (NAAT) for the diagnosis of C. difficile-associated diarrhea (CDAD) by retrospective chart review.

Methods: From Dec 2015 to May 2018, a total of 92 patients suspicious of antibiotic-related diarrhea in cases showing at least one positive (including equivocal) for C. difficile toxin EIA (VIDAS toxin A/B enzyme-linked fluorescent assay, BioMerieux SA, France) and/or NAAT (the Seeplex Diarrhea ACE kit, Seegene, Korea) were investigated the correlation of clinical diagnosis of CDAD based on metronidazole and/or vancomycin medication treatment by retrospective chart review.

Results: Sixty seven (72.8%) out of 92 cases were treated for CDAD. All of 43 cases with C. difficile toxin EIA (+)/NAAT(+), 14 out of 36 cases with EIA (-)/NAAT(+), one case with EIA(+)/NAAT(-), Seven out of 10 cases with EIA equivocal/NAAT (+), and all of 2 cases with EIA equivocal/NAAT (-) were treated for CDAD. The overall AUC was 0.836 for EIA (\geq Equivocal), 0.522 for NAAT, and 0.821 for EIA combined with NAAT, respectively.

Conclusion: C. difficile toxin EIA was still considered a reliable diagnostic test for CDAD in clinical setting of antibiotic-related diarrhea. NAAT was not enough for a standalone test, but would helpful to diagnose in C. difficile toxin EIA(-) or equivocal case suspicious of CDAD.

244

NEOADJUVANT FOLFIRINOX FOR BORDERLINE RESECTABLE PANCREATIC CANCER: COMPARED WITH CONCURRENT CHEMORADIATION THERAPY

Sang Hyub Lee, Young Hoon Choi, Min Su You, Bang Sup Shin, Woo Hyun Paik, Ji Kon Ryu, Yong-Tae Kim

Department of Internal Medicine and Liver Research Institute, Seoul National University College of Medicine, Seoul, Korea

Relevance: The optimal treatment strategy for borderline resectable pancreatic cancer (BRPC) is not clearly known.

Object: In this study, we aimed to evaluate the efficacy of neoadjuvant FOLFIRINOX in comparison with concurrent chemoradiation therapy (CCRT) in BRPC.

Materials and methods: Between March 2011 and December 2016, patients who underwent FOLFIRINOX or CCRT as initial treatment for BRPC were analyzed. BRPC was defined according to the National Comprehensive Cancer Network (NCCN) resectability criteria.

Results: Twenty-two patients received FOLFIRINOX and 21 patients received CCRT. Surgical resection was performed in 9 patients in the FOLFIRINOX group and in 14 patients in the CCRT group, and R0 resection in 8 patients and 11 patients in each group. There were no differences in baseline characteristics between the FOLFIRINOX and CCRT groups, including age, sex, baseline CA 19-9 level, regional lymph node metastasis, location of pancreatic cancer, and reason for borderline resectability in patients with R0 resection. Among patients with R0 resection, the FOLFIRINOX group showed a trend toward improved relapse-free survival (RFS) compared to the CCRT group (median not reached, mean 549 ± 107.6 days vs. median 183 days [95% confidence interval (CI), 58.9-307.1], mean 366 ± 127.9 days; $P = 0.119$). The median progression-free survival (PFS) was 315 days [95% CI, 159.9-470.1] in the FOLFIRINOX group as compared with 270 days [95% CI, 207.2-332.8] in the CCRT group ($P = 0.381$).

Conclusions: The surgical resection rate was higher in the CCRT group, however the FOLFIRINOX group showed improved tendency in RFS and PFS. FOLFIRINOX could be considered as a neoadjuvant treatment option for BRPC compared to CCRT.

245**PROGNOSTIC VALUE OF NEUTROPHIL-LYMPHOCYTE RATIO AND PLATELET-LYMPHOCYTE RATIO DURING PALLIATIVE CHEMOTHERAPY IN PATIENTS WITH UNRESECTABLE GALLBLADDER ADENOCARCINOMA****Sang Hyub Lee, Jae Woo Lee, Young Hoon Choi, Min Su You, Bang Sup Shin, Woo Hyun Paik, Ji Kon Ryu, Yong-Tae Kim***Department of Internal Medicine, Liver Research Institute, Seoul National University College of Medicine, Seoul, Korea***Relevance:** Neutrophil-lymphocyte ratio (NLR) and platelet-lymphocyte ratio (PLR) is a valuable prognostic marker in several kinds of solid tumors.**Object:** This study aimed to evaluate the NLR, PLR and change of NLR and PLR over time as a prognostic marker in unresectable gallbladder cancer (GBC) which is treated with palliative chemotherapy.**Materials and methods:** A total of 161 patients with pathologically confirmed unresectable GBC were enrolled. Baseline and post 1-cycle chemotherapy NLR and PLR were used in analysis. The changes in NLR and PLR were defined as the ratio of post chemotherapy value to baseline value. The relation between survival time and NLR and PLR changes were analyzed.**Results:** NLR and PLR had AUC value of 0.679, 0.660 in predicting 1-year overall survival (OS) and NLR 1.96 and PLR 111 were the optimal cutoff value with the highest sum of sensitivity and specificity. NLR change and PLR change had AUC value of 0.517, 0.519 in predicting 1-year OS and NLR change 0.4, PLR change 0.6 were the optimal cutoff value. Patients with NLR lower than 1.96 had better OS (16.1 months vs 9.5 months, $p < 0.001$) and similarly patients with PLR lower than 111 had better OS (17.3 months vs 9.5 months, $p < 0.001$). However, NLR change lower than 0.4 didn't show better OS (9.2 months vs 11.6 months, $p = 0.178$), and the same with PLR change lower than 0.6 (8.5 months vs 11.3 months, $p = 0.138$).**Conclusions:** Baseline NLR and PLR is a valuable predictor of overall survival in unresectable GBC undergoing palliative chemotherapy, whereas NLR and PLR change over time is not.**246****DINACICLIB AND TRAIL OVERCOMES SORAFENIB-RESISTANCE OF HEPATOCELLULAR CARCINOMA****J. Lemke, Elle Kitzig, Anna-Laura-Kretz, Chantal Allgöwer, Uwe Knippschild, Doris-Henne-Bruns***Clinic of General and Visceral Surgery, University of Ulm, Germany***Introduction:** Sorafenib remains the standard therapy for

patients with advanced HCC despite considerable side-effects and the fact that systemic treatment only prolongs survival by a few months. One major reason for its limited efficiency is the fact that HCC cells commonly exhibit or acquire resistance to Sorafenib. Therefore, novel effective and cancer-selective therapeutic strategies are urgently needed. Recently, we identified the combination of the death ligand TRAIL and CDK9 inhibition as an exceptional potent strategy to selectively kill tumor cells. Here, we evaluated the combination of the clinical tested CDK9-inhibitor Dinaciclib and TRAIL for HCC and investigated underlying molecular mechanism.

Methods: Tumors of HCC patients was immunohistochemically analyzed for CDK9 and TRAIL-receptor expression. Moreover, the therapeutic potential of the clinical CDK9-inhibitor Dinaciclib on HCC cells was evaluated alone and in combination with TRAIL by analysis of cell viability, long-term survival and apoptosis and characterized using western blotting and flow cytometry. Moreover, HCC cells with acquired Sorafenib-resistance were generated and challenged with our novel therapy.**Results:** TRAIL-receptors and CDK9, targets of our newly devised therapeutic strategy are highly expressed in human HCC. The combination of Dinaciclib and TRAIL synergistically and effectively reduced cell viability in HCC cells and, importantly, almost completely abolished clonogenic survival of these cells. The combination induced cell cycle arrest and caspase-8-dependent apoptosis in these cells. Moreover, this combination displayed a superior cytotoxic effect in HCC cells compared to Sorafenib treatment alone. Interestingly, this combination overcame acquired Sorafenib-resistance in HCC cells by the shift of the ratio of pro- and anti-apoptotic proteins on the transcriptional level.**Conclusions:** In conclusion, due to its potency, CDK9-inhibition in combination with TRAIL provides a novel and promising therapeutic approach for Sorafenib-resistant HCC.**247****SECONDARY CANCERS IN COLORECTAL CANCER PATIENTS: INCIDENCE, SURVIVAL AND RISK FACTORS****Johannes Lemke¹, Philipp Glück¹, Silvia Sander², Marko Kornmann¹, Doris-Henne-Bruns¹**¹*Clinic of General and Visceral Surgery, University of Ulm, Germany*²*Institute of Epidemiology and Medical Biometry, University of Ulm, Germany***Introduction:** Due to improvement in diagnosis and therapy, today long-term survival can be achieved in most colorectal cancer patients. In addition to the extended live expectancy in general, this fact accounts for an increased risk to develop secondary cancers. In this study we analyzed the incidence and survival of patients developing secondary cancers after

or simultaneously to colorectal cancer.

Methods: Between January 2000 and December 2012 1144 patients diagnosed with colorectal cancer were treated in our clinic. All patients were postoperatively followed up in our clinic. Here, we analyzed the incidence and survival of patients that developed secondary cancers.

Results: Of all 1144 patients, 137 patients (12%) developed secondary cancers. 67 patients (49%) were diagnosed with synchronous secondary cancer, whilst 70 patients (51%) developed a secondary malignancy postoperatively. Secondary cancers developed included, colorectal, other gastrointestinal, urological, and gynecological tumors. Interestingly, in general, the development of secondary cancers was not associated with impaired survival. Moreover, we identified risk factors for the development of secondary cancers.

Conclusions: In conclusion, secondary cancers are commonly encountered in colorectal cancer patients. Moreover, our study suggests, that several factors may contribute to the development and prognosis of secondary cancers in these patients.

248

EFFECTS OF DIETARY GLUTAMINE ON THE HOMEOSTASIS OF CD4+ T CELLS IN MICE WITH GUT-DERIVED POLYMICROBIAL SEPSIS

Cing-Syuan Lei¹, Ting-Chun Kuo¹, Po-Da Chen¹, Po-Chu Lee¹, Yu-Chen Hou², Sung-Ling Yeh³, and Ming-Tsan Lin¹

¹Department of Surgery, National Taiwan University Hospital and College of Medicine, National Taiwan University, Taipei, Taiwan

²Master Program in Food Safety, College of Nutrition, Taipei Medical University, Taipei, Taiwan

³School of Nutrition and Health Sciences, College of Nutrition, Taipei Medical University, Taipei, Taiwan

Sepsis remains the leading cause of death in hospital patients with major surgery or critical illness. Sepsis-induced imbalance between pro- and anti-inflammatory profiles is related to loss or dysfunction of CD4+ T cells. CD4+ T cells can differentiate into T helper (Th) cells and regulatory T (Treg) cells. Th cells are divided into several subsets, including Th1, Th2, and Th17, characterized by different effector differentiation pathways and distinct cytokines. Treg cells are implicated in suppressing an excessive T cell response. Glutamine (Gln), a conditionally essential nutrient for patients with catabolic conditions, serves as an important fuel for proliferating immune cells. At present, no in vivo studies investigated the impact of Gln on the balance of Th/Treg cells during sepsis. This study investigated the effects of dietary Gln on Th and Treg cell homeostasis and inflammatory mediator expression in mice with gut-derived

polymicrobial sepsis. Mice were randomly assigned to 4 groups with 2 control (C and G) and 2 sepsis groups (SC and SG). The C and SC groups were fed with AIN-93 diet, while the G and SG groups received a modified AIN-93 based diet with part of the casein replaced by Gln, which provided 25% of the total amino acid nitrogen. Mice were administered diets for 2 weeks. Then the mice in the control groups performed sham operation, while those in the sepsis groups performed cecal ligation and puncture (CLP) to induce sepsis. Mice were sacrificed at 24 or 72 h after the surgery. Blood, spleens and lungs were collected for further examination. Results showed that sepsis resulted in decreased blood T lymphocyte percentage, while percentages of Interferon- γ -, Interleukin (IL)-4- and IL-17-expressing CD4+ T cells were upregulated. Compared with the SC group, Gln administration before sepsis reduced Th1, Th2, and Th17 percentages in blood. Also, the transcription factors, T-bet, GATA-3 and ROR- γ t gene expression and bcl-2/bim ratio in splenocytes were lower whereas interstitial inflammation in lung tissues were more severe after CLP. These results suggest that pretreatment with Gln had higher CD4 cell apoptotic rate and dysregulated balance that may result in T cell exhaustion and dysfunction and remote organ injury.

Key words: Sepsis, Cecal ligation and puncture, Glutamine, CD4+ T cells, Th1/Th17/Treg

249

A PROSPECTIVE RANDOMIZED CLINICAL STUDY EVALUATING THE EFFICACY AND COMPLIANCE OF ORAL SULFATE SOLUTION AND 2-L ASCORBIC ACID PLUS POLYETHYLENE GLYCOL

Yun Jeong Lim¹, Ki Hwan Kwon¹, Ji Ae Lee², Beom Jae Lee², Moon Kyung Joo², Yu Ra Sim², Wonjae Choi², Taehyun Kim², Ji Yoon Kim¹, Ei Rie Cho¹, Yoon Tae Jeon³, Jong-Jae Park²

¹Department of Internal Medicine, Dongguk University Ilsan Hospital, Dongguk University College of Medicine, 27 Dongguk-ro, Ilsandong-gu, Goyang, Korea

²Department of Internal Medicine, Korea University Guro Hospital, Korea University College of Medicine, 148, Gurodong-ro, Guro-gu, Seoul, Korea

³Department of Internal Medicine, Korea University Anam Hospital, Korea University College of Medicine, 73, Incheon-ro, Seongbuk-gu, Seoul, Korea

Background: Oral sulfate solution (OSS) is an emerging cleansing agent for bowel preparation but there are few comparative data to other conventional bowel preparations in Asian patients. The objective of this study was to compare the efficacy and tolerability of OSS to ascorbic acid plus polyethylene glycol (AA+PEG).

Methods: This was a prospective, randomized, parallel, investigator-blind study performed in two university hospi-

tals in Korea. We evaluated the bowel preparation efficacy using both the Ottawa Bowel Preparation Scale (OBPS) and Boston Bowel Preparation Scale (BBPS). Results: Among the 173 patients, 86 and 87 patients received OSS and AA+PEG, respectively, for bowel preparation. The total OBPS score was 2.80 ± 2.48 in the OSS group, which indicated significantly better efficacy than the AA+PEG group (4.49 ± 3.08) ($p < 0.001$). Total BBPS indicated superior bowel preparation quality in the OSS group (7.43 ± 1.49 versus 6.51 ± 1.76 ; $p < 0.001$). Preparation-related adverse events were generally acceptable; patients receiving OSS had more nausea (1.92 ± 0.94 versus 1.54 ± 0.76 ; $p = 0.004$) and abdominal cramping (1.45 ± 0.78 versus 1.17 ± 0.51 ; $p = 0.006$) than the AA+PEG. However, overall satisfaction and taste were similar between the groups.

Conclusion: OSS had better bowel cleansing efficacy than AA+PEG regardless of the colon segment.

250

THE USE OF EXTRACORPOREAL MEMBRANE OXYGENATION IN PATIENTS UNDERGOING ABDOMINAL SURGERY

Chih Hao Lin, Po Da Chen, Jin Ming Wu, Ming Tsan Lin

Department of Surgery, National Taiwan University Hospital, Taipei, Taiwan

Relevance: Mechanical circulation such as veno-arterial or veno-venous extracorporeal membrane oxygenation (VA- or VV- ECMO) may provide emergent life support for temporary circulatory collapse or pulmonary failure. Nevertheless, in previous research, there was limited experience in instituting ECMO for patients with sudden collapse after abdominal surgery, thus its potential benefits as well as limitations in such situation may need further review.

Object: In this study, we aim to examine the result and the rationale for the use of mechanical circulation among patients who underwent abdominal surgery in our institution where the setup of ECMO was both highly available and affordable.

Materials and Methods: We retrospectively review patient who was admitted to surgical intensive care unit due to cardiopulmonary collapse within 30 days after abdominal surgery between 1998-2018, among whom mechanical circulation including veno-arterial or veno-venous extracorporeal membrane oxygenation (VA- or VV- ECMO) had been implemented.

Results: For the 20 patients that met the inclusion criteria, 9 VA-ECMO and 11 VV-ECMO were implemented. The median age was 55, including 5 patients of age more than 65 years. Amongst, 11 patients underwent elective surgery including 8 for curative or palliative cancer surgery and 3 for non-cancer surgery such as kidney transplantation or laparoscopic surgery for morbid obesity. The other 9 received emergent

bowel surgery for none malignant diagnosis. Mainly, ECMO was instituted due to refractory septic shock or acute respiratory distress syndrome (ARDS). It was implemented for acute coronary disease or pulmonary thromboembolism only in 3 cases. Overall, no intractable intra-abdominal bleeding was encountered in all the cases. ECMO was successfully weaned off in 5 cases, including 4 received VV-ECMO for ARDS and survived to hospital discharge while 1 received VA-ECMO for underlying cardiac disease and developed thromboembolic event followed by intracranial hemorrhage. Besides, 2 out of the 4 survival cases were more than 65 years of age, and both were cancer patients with stage I gastric cancer and stage III colon cancer with total luminal obstruction.

Conclusions: Despite heterogeneous abdominal surgeries in our cohort, temporary ECMO support provided clinicians with additional chances to survey and treat the cause leading to sudden patient collapse. Clinical benefit may particularly be warranted in cases with respiratory failure caused by ARDS following severe sepsis. In addition, there was no significant outcome difference between those with or without cancer diagnosis as well as between different age groups. None in our cohort encountered serious intra-abdominal bleeding cause by mechanical circulatory support and heparinization.

251

EXPERIENCE OF TREATMENT FOR BILIARY COMPLICATIONS FOLLOWING LIVER TRANSPLANTATION

A. Lischenko, A. Popov, M. Davydenko, A. Petrovskiy, A. Baryshev, V. Porhanov

SBHCI Scientific Research Institution – Ochapovsky Regional Clinical Hospital No 1, Krasnodar, Russia

Relevance. Biliary complications occur more often than others after liver transplantation.

Aim: improving treatment techniques in patients with biliary complications following liver transplantation.

Materials and Methods: From May, 2010 to June, 2018, 150 orthotopic transplantations of the entire cadaveric liver have been performed. At assessment and treatment we applied available x-ray and endoscopic diagnostic tools, in particular computer tomography and magnetic resonance imaging, ultrasonography, endoscopic transpapillary interventions, antegrade transhepatic mini-invasive interventions on biliary ducts.

Results: Initial biliodigestive anastomosis was performed in 5 patients (3,3%). In other 145 cases (96,7%) we created choledochocholedochostomy end-to-end. Later on in this group we found biliary complications in 25 patients (16,7%). Of those in 6 cases (4,0%) within the early postoperative period we observed abdominal bilomas that were treated by mini-invasive draining under the ultrasound guidance. Of

those patients 3 had treatment of bile leakage by means of endoscopic papillotomy. In other 19 cases (12,7%) we observed events of subhepatic cholestasis. For its arresting, we started with endoscopic retrograde transpapillary stenting of a choledoch duct. In 8 cases it was absolutely effective and became a final treatment. In other 11 patients it was necessary to undertake antegrade mini-invasive percutaneous transhepatic interventions. Thus, we successfully eliminated cholestasis in 4 cases. In other 7 patients stricture of the biliary anastomosis was not re-canalized. Therefore, after the jaundice termination they were operated on with formation of biliodigestive anastomosis on the defunctionalized loop according to Roux technique. We should point at high mortality rate (9 of 25; 36,0%) in the group of patients with biliary complications. Immediate causes of death were 2 purulent septic complications; 3 progressing tumors; 2 transplant rejections; 2 transplants fibrous cholangiolitic hepatites.

Conclusions: For biliary complications treatment one should have skills of endobiliary and interventional surgery. If mini-invasive approach is inefficient, open reconstructive operation with participation of highly qualified specialists is required. Even without being an immediate cause of fatality, biliary complications serve as an adverse background for other diseases leading patients to death after orthotopic liver transplantations. Further studies are required to investigate reasons and prevention of biliary complication development.

252

ELECTIVE GENERAL SURGERY: RISK FACTORS FOR SEPSIS DEVELOPMENT

E. Lishova, V. Nikoda, T. Mrugova, A. Prusova, O. Dymova

Petrovsky Russian Research Centre of Surgery, Moscow, Russian Federation

For many decades the problem of sepsis of the nosocomial nature does not lose its relevance, despite the increased attention of researchers of various disciplines to this issue. The result of surgical treatment is largely determined by the development of infectious complications and, according to international studies, there is an increase in the incidence of sepsis with a high percentage of mortality. Modern technologies expand the possibilities for conducting operations in patients with long-existing diseases of varying degrees of compensation.

Objective: Assessment of clinical and laboratory parameters of patients with sepsis

Materials and methods: The study included all patients diagnosed with sepsis in the period 2017-2018 yr who were in the intensive care unit of the general surgical profile (n = 15). The average age is 58 ± 26 years. Patients were divided into

two groups depending on the outcome of the treatment.

Results: In 67% of patients, sepsis developed against the background of diseases of the hepatobiliary zone (cholangitis, abscesses of the liver), 20% of transplantation profile, 13% had a gastrointestinal leak in the postoperative period (anastomotic leak, intestinal perforation). Comorbidity occurred in 73% of patients. The duration of stay in the ICU is 14 ± 14 (1; 57), in the hospital - 43 ± 33 (9; 120) days. The evaluation of organ dysfunction is carried out on the scale of SOFA, at the time of diagnosis of sepsis was 12 ± 3 (7; 18). All patients had a failure of ≥ 2 organs and systems. Ventilation for more than 24 hours was performed by 60% of patients, mean duration of 11 ± 9 days (2, 34). Mortality in the group was 20% (n=3, the average age was 85 ± 8.5 years). According to laboratory data, the growth of gram-negative flora of several species was observed in all deceased patients.

Conclusion: Comorbidity, age, severity of organ dysfunction are the main factors of mortality due to sepsis. The main danger is nosocomial gram-negative antibiotic-resistant infections.

253

DYSPHAGIA AFTER LAPAROSCOPIC ANTIREFLUX SURGERY

A. Lodygin, V. Kaschenko, A. Ahmetov

Sokolov Hospital No 122 FMBA of Russia, Saint-Petersburg, Russia.

Saint-Petersburg State University, Saint-Petersburg, Russia

There is the steady rise of disease rate of the gastro-esophageal reflux disease (GERD) all over the world. The incidence of GERD in USA is 20-27%, in Great Britain - 18-28,7%, in China -4,8%, in Russia - 23,6%. As will as the spread of disease rate a number of operations as to GERD rises. Laparoscopic antireflux surgery (LARS) has become a common option of surgical GERD cure giving good results and significant improvement of quality of life for a long time. Despite increasing of GERD disease rate, patients and their doctors often regard LARS as unwilling because of the fear of complications and poor results. One of the most frequent complications is postoperative dysphagia, occurrence of which after LARS varies from 10 to 25%. Having analyzed the publications from all over the world and our own experience, we tried to investigate the causes of dysphagia occurrence. Dysphagia after LARS is usually transitory and stops in some weeks after the operation. Small number of patients develops persistent dysphagia after the operation. What are the causes of this undesirable outcome? The answer could be related to the insufficient preoperative examination of the patients, incorrect selection of the patients for the operation, unreasonable indications for surgery, incorrect choice of the type of fundoplication. The

so called “individual approach» towards antireflux surgery minimizes the thread of postoperative dysphagia, namely you select patients on the grounds of the results of preoperative esophageal motility examination and you form the wrap type. The following frequent reasons of postoperative dysphagia are different technical errors – a problem of hiatal closure, deformation, rotation, bend of esophagus, migration cuffs and psychogenic character of dysphagia. In our work we could fix 9 out of 280 cases of postoperative dysphagia, which makes 3,2% out of total number of patients. All the patients had laparoscopic Nissen fundoplication. Only 3 out of 9 had the full algorithm of preoperative examination. Six patients haven't had esophageal manometry, 3- daily Ph-metry. Two patients had endoscopic dilation of the cardia, which brought their recovery. Two patients had the second operation, which was transferring Nissen's wrap in to Toupet's. Five patients were cured without operation. We came to the conclusion, that the course of dysphagia in 6 cases was insufficient preoperative examination, in 2 cases – technical errors, and 1 case showed psychogenic character of dysphagia.

Conclusions: Dysphagia after LARS should be considered as a complication. This complication can be avoided. It is necessary to strictly follow the algorithm of preoperative examinations. An individual approach to the choice of fundoplication technique is required. The technical aspects of the operation must be strictly observed.

254

THE CAUSES OF THE RISK OF PANCREATIC CANCER AFTER SURGICAL TREATMENT OF PATIENTS WITH CHRONIC PANCREATITIS

V. Lubianskii¹, V. Seroshtanov¹, I. Arguchinskii², E. Semenova²

¹*Altai State Medical University, Barnaul, Russia,*

²*Altay regional clinical hospital, Barnaul, Russia*

Relevance: In recent years, the number of patients with chronic pancreatitis has increased throughout the world. The literature discusses the problem of pancreatic cancer on the background of chronic pancreatitis. In surgical treatment, the use of duodenum-preserving resections with the pancreatic tissue retained, from which a tumor can subsequently develop.

Aim: to analyze the results of surgical treatment of patients with chronic pancreatitis and to assess the causes of pancreatic cancer after surgical treatment.

Materials and methods: The clinic operated on 137 patients with chronic pancreatitis who underwent duodenum-preserving resections of the pancreas: Frey's operation - 106 (84.7%), Beger - 5 (3.6%), PDR - 16 (11.7%). Among them were 105 (76.6%) men and 32 (23.4%) women. The mean age was 48.6 ± 4.0 years. All patients before the operation

and in the postoperative period were subjected to clinical and biochemical studies, tumor markers CA-19-9. Instrumental examination included MSCT of the abdominal cavity with intravenous contrast, endosonograph. During the operation, the pancreatic tissue site was excised for a cytohistological examination followed by examination of the permanent preparations.

Results: When analyzing the results of histological examination of pancreatic tissues removed during the operation, it was found that in patients with chronic pancreatitis, intralobular and periductal growth of fibrous tissue was registered in varying degrees, which in 19 (13.8%) largely replaced acinar. In 13 cases (9.5%), the presence of lymphoid-histiocytic infiltration with signs of autoimmune inflammation and proliferation of subintimal structures in the vascular wall of the arteries of the pancreas was established. In 13 (9.5%) patients, papillomatous proliferation of the ductal epithelium was found, with an increase in the number of nuclei, hyperplasia of small ducts, lymphocytic and plasmacytic infiltration in the periductal and acinar structures. In the long term after the operation from 6 months to 2 years, 8 patients (5.8%) had pancreatic cancer. When analyzing the causes of the tumor, a significant factor is not eliminated ductal hypertension, which has a pathological effect on the status of the protocol epithelium. So in two of these patients in the process of Frey's operation, an insufficient volume of resection of the head of the pancreas was made. In the case of leaving a large array of fibrous tissue, local hypertension is retained in the region of the ductal structures of the head, which possibly leads subsequently to the transformation of the epithelium of the protocol. An essential factor in the problem of the preservation of pancreatic hypertension remains the stenosis of pancreatic intestinal anastomoses, which arose in the long term in 4 patients (2.9%). An important role in the proliferation of the protocol epithelium is played by autoimmune inflammation.

Conclusions: 1. After a pancreas resection for chronic pancreatitis, a tumor was diagnosed in 5.8% of patients. 2. In carrying out Frey's surgery for chronic pancreatitis, it is necessary to eliminate pancreatic hypertension by extensive excision of the pancreatic head tissue.

255

THE ROLE OF USING SURGEON-PERFORMED ULTRASOUND SCREENING IN DIAGNOSING ACUTE CHOLECYSTITIS

I. Lukyanchenko, A. Lyutov, S. Pyatakov, N. Brytska, G. Okhotina, I. Khrenova

MBHI (Municipal budgetary healthcare institution)

“City hospital No 4”, Sochi, Russia

Background. Acute cholecystitis is one of the most common surgical disease. The clinical and ultrasound signs for acute

cholecystitis often do not conformity, which leads to diagnostic and tactical errors. Therefore, using of primary surgeon-performed ultrasound screening is promising in the further treatment tactics in patients with acute cholecystitis. The aim of the study. To estimate the possibility of using ultrasound screening in diagnosing acute cholecystitis directly by surgeons for providing emergency surgical care.

Materials and methods. Between March 2017 and June 2018 the diagnostic and surgical outcomes of 246 patients with acute cholecystitis were analyzed. Since 2014, the surgeon-performed ultrasound screening in patients with abdominal pain syndrome was introduced into MBHI "City hospital №4". The abdominal ultrasound screening was performed directly by surgeons for diagnosing of acute cholecystitis in patients with abdominal pain syndrome upon admission to the hospital at once outside the radiology department. The wall thickness, the gallbladder size, the stratification of contours, the size and amount of stones, the localization of stones, the paravesical fluid, the infiltration of surrounding tissues, the free fluid in the abdominal cavity were evaluated during the ultrasound screening.

Results. The surgeons had studied the implementation methodology of ultrasound screening. The median time of education was 8 weeks (from 6-week-long to 2 months) depending on the length of experience and the intensity of training. The ultrasound findings of the surgeon and of the radiologist were compared to final diagnosis. The percentage of patients who were diagnosed acute cholecystitis from all surgical pathology was 15%. The discrepancy between the clinical signs (complaints, objective status, laboratory findings) and ultrasound signs, confirmed intraoperatively during laparoscopic cholecystectomy was observed in 25% of patients. The sensitivity, specificity and accuracy of ultrasound screening for acute cholecystitis performed directly by surgeons were 92.5%, 98,8% and 96,7%, respectively.

Conclusions. Primary ultrasound screening for the diagnosis of acute cholecystitis performed directly by surgeons is demonstrated the effectiveness in improving the quality of diagnosis, predicting surgical benefits in patients with acute cholecystitis. The obtained outcomes is proved the positive aspects of the introduction of surgeon-performed ultrasound screening into surgical hospitals.

256

THE EXPERIENCES OF USING THE CONCEPT OF FAST-TRACK SURGERY IN THE TREATMENT OF PATIENTS WITH ACUTE CHOLECYSTITIS

I. Lukyanchenko, S. Pyatakov, A. Lyutov, A. Bukarev, N. Brytska, D. Kovalev, I. Khrenova
MBHI "City Hospital No 4", Sochi, Russia

Introduction. Nowadays the protocol of FAST-track surgery is effective for patients with chronic cholecystitis. However some studies are devoted to using of FAST-track surgery in emergency surgery, in particular in patients with acute cholecystitis. In this regard, the study of using the concept of FAST-track surgery in emergency surgery is relevant.

The aim of the study. To analyze the effectiveness of the FAST-track surgery protocol in the treatment of patients with acute cholecystitis.

Materials and methods. Currently, the protocol of the FAST-Track surgery is introduced in MBHI "City Hospital №4" for both urgent and planned surgeries. The concept of Fast-track surgery or 'enhanced recovery after surgery' or 'multimodal rehabilitation after surgery' is based on improving the next III stages of the treatment - preoperative preparation, surgical intervention and the level of anesthesia, postoperative care programme. The main aspects of FAST-track surgery concept are multimodal analgesia, the rejection of opioid analgesics, perioperative nutritional support, the avoidance of bowel preparations, the use of minimally invasive surgical approaches, the refusal to routinely using drains into the abdominal cavity, active patient mobilization and verticalization in the postoperative period. The outcomes of surgical treatment of 268 patients with acute cholecystitis who underwent laparoscopic cholecystectomies were analyzed for the period 2016-2018. All patients were divided into 2 groups - the main group consisted of 150 patients who were treated using the protocol of the FAST-track Surgery and the control group consisted of 118 patients who were not used the protocol of the FAST-track Surgery.

Results. The analysis of the Clavien-Dindo complications showed the significant decrease of complication rate II-IV classes in the main group by 1.75 times. The median postoperative day in the main group was 1.5 ± 1.5 days, in the control group was 3.5 ± 2.5 days. There were no mortality in the both groups. The frequency of readmissions for using of the FAST-Track surgery protocol was 2%, in the control group - 3.8%.

Conclusions. The introduction of the protocol FAST-track surgery in the treatment of patients with acute cholecystitis at our hospital led to the reduction of length of stay, complications and costs of treatment, without increase readmissions compared with the previous traditional protocol.

257**LAPAROSCOPIC RECONSTRUCTION OF COLON AFTER OBSTRUCTIVE RESECTION****O. Lutsevich¹, E. Galliamov², M. Agapov³, G. Starkov⁴, A. Pokshubinam²***¹A.I. Yevdokimov Moscow State University of Medicine and Dentistry, Moscow, Russia; ²Federal State Autonomous Educational Institution of Higher Education I.M. Sechenov First Moscow State Medical University of the Ministry of Health of the Russian Federation (Sechenov University), Moscow, Russia; ³University clinic Lomonosov Moscow State University, Moscow, Russia; ⁴Federal State Institution "Central Hospital of Civil Aviation", Moscow, Russia*

Objective. To show the possibility of improving the results of treatment of patients with pathology of the colon which requires staged surgical treatment by optimizing the time of reconstructive stages.

Materials and Methods. The clinical case of the treatment of the patient M., 46 years old, hospitalized into the surgical Department of KB-2, CJSC Group of companies "Medsi".

Results. The patient was hospitalized after 12 h from the onset of the disease with the clinical picture of the perforation of a hollow organ, of generalized peritonitis. A diagnostic laparoscopy was conducted in the case of emergency. The intraoperative diagnosis was diverticular disease of the sigmoid colon complicated by the diverticulitis, perforated sigmoid colon, generalized purulent-fibrinous peritonitis. A laparoscopic obstructive resection of the sigmoid colon with the formation of the single-sigmoscopy, sanitation and drainage of the abdominal cavity were made. A programmable repair relaparoscopy was made on the third day. Intraoperatively there was a significant regression of inflammatory changes in the visceral and parietal peritoneum. The conservative treatment was continued. The patient was activated 12 h after the surgery. On the 9th day after the relaparoscopy a barium enema was made through sigmostoma. The area of the descending colon affected by the diverticular disease was determined. On the 15th day after the first surgery a laparoscopic reconstructive descendorectal anastomosis with the resection of the diverticular modified distal area of the descending colon, as well as the altered distal area of the sigmoid colon was conducted using colonoscopy navigation. Intraoperatively friable adhesions were revealed at the site of the resected area of intestine, and there were no laparoscopic signs of peritonitis. The total stay in hospital lasted 22 days.

Conclusion. The use of video-endoscopic technologies and complex management of the patient on the Fast Track system allowed to make the reconstruction of the colon 2 weeks after the obstructive resection. The optimizing of the time of reconstructive and recovery stages of surgical treatment of pathology of the colon requires the scientific support of objective criteria of the readiness of the intestinal tract for reconstruction.

258**OPTIMIZATION OF SURGICAL TREATMENT OF INGUINAL HERNIAS****O. Lutsevich¹, E. Galliamov², M. Agapov³, T. Biktimirov⁴, A. Allakhverdieva²***¹A.I. Yevdokimov Moscow State University of Medicine and Dentistry, Moscow, Russia; ²Federal State Autonomous Educational Institution of Higher Education I.M. Sechenov First Moscow State Medical University of the Ministry of Health of the Russian Federation (Sechenov University), Moscow, Russia; ³University clinic Lomonosov Moscow State University, Moscow, Russia; ⁴Federal State Institution "Federal Clinical Center of High Medical Technologies of the Federal Medical and Biological Agency", Moscow, Russia*

The problem of surgical treatment of inguinal hernia in the last 25 years has experienced global shocks. Today, laparoscopic technique of inguinal hernia correction is an un-disputed favorite (more than 55%). The widespread of laparoscopic hernia repair is limited by the need for special training of doctors, expensive equipment and requires general anesthesia. However, these disadvantages are fully compensated by the advantages: low traumatic of the method and, as a consequence, the possibility of early activation and rehabilitation of patients, a low number of intra- and postoperative complications, a high cosmetic effect, the possibility of examination of the abdominal cavity, diagnosis and treatment of simultaneous surgical pathology. But this technique has disadvantages and complications of the early or late postoperative period - pain syndrome and relapse of the disease (from 0.2 to 1.5%). These complications are related to the quality of the implant and the method of fixation.

Materials and methods. We have a joint experience in the treatment of more than 4,000 patients with inguinal hernia. Since 2013, we have started using the Progrid Covidien mesh. The operation was subjected to 367 patients. Most (94%) of them were men between the ages of 24 and 89 years. The disease duration constituted from 4 months to 14 years, median 1.1 years. During the operation we used the standard technique of three ports. The following deserve notice: individual cutting mesh - 15x10 cm; delivery of the mesh to the abdominal cavity in the folded state through the optical port; in the inguinal hernia, the mesh center is placed in the middle of the hernial gates; low mobilization of the parietal peritoneum - 3.5-4 cm from the lower edge of the hernial opening; when straightening mesh should avoid tucking its lower edge; the integrity of the parietal peritoneum is restored by hand suture of the absorbable thread 3/0; for the prevention of pain in the first hours after surgery, it is advisable to irrigate the area of operation with a solution of local anesthetic;

Results. The surgical intervention time increased by an average of 7.5 minutes, and ranged from 30 to 45 minutes per side of the lesion. Practicing skills of laying a mesh and

manual suture of the peritoneum can reduce the time of this stage of operation. All patients on the operating table were given a single preventive injection of an antibiotic, after the operation - anesthesia of NSAIDs according to indications. The intensity of postoperative pain syndrome was evaluated on a 10-point scale, the vast majority of patients after 6 hours showed only minor pain, within 1-3 points. The duration of inpatient treatment was from 1 to 2 days, the median was 1.17 days. There were no intraoperative, early postoperative complications and relapses.

Conclusion. The use of lightweight prostheses of sufficient size with a fundamentally new fixation system allows to significantly improve the results of treatment of hernia inguinal localization.

259

RESULTS OF ENDOSCOPIC RESECTION OF THE MUCOSA IN EPITHELIAL FORMATIONS OF THE LARGE INTESTINE

O. Lutsevich¹, E. Galliamov², M. Agapov³, Yu. Bysirev², D. Buzadzi²

¹A.I. Yevdokimov Moscow State University of Medicine and Dentistry, Moscow, Russia; ²Federal State Autonomous Educational Institution of Higher Education I.M. Sechenov First Moscow State Medical University of the Ministry of Health of the Russian Federation (Sechenov University), Moscow, Russia; ³University clinic Lomonosov Moscow State University, Moscow, Russia

Introduction. For today, endoscopic resection of the mucosa is the safest and widespread method of endoscopic treatment of flat or raised epithelial colon formations (0-II a 0-II b according to the Paris classification of GI neoplasia).

Aims. Studying the results of endoscopic resection of the mucosa in colon's epithelial formations at the stage of mastering the method.

Materials and methods. From 2014 to 2018 18 patients (6 men and 12 women, average age of patients 63.6 years) underwent endoscopic mucosal resection for epithelial colon lesions.

Results. In 18 patients, 23 epithelial and 1 non-epithelial colon formations were removed. The Paris classification of gastrointestinal neoplasia was used to determine the macroscopic type of formations. 15 formations were classified as type 0-IIa, 4 formations of type 0-Is, 2 formations of 0-Ip type, 2 formations of LST-NG. The average size of the formations was 9.9 mm. (6 mm-25 mm). To determine the boundaries of the formations and the topography of the mucosal surface, chromoscopy techniques were used for 1% r-ri of indigo carmine, 0.2% for crystalline violet, 1.5% for acetic acid, and for narrow-spectral and endoscopy for high definition. In 6 patients, epithelial structures were identified and verified earlier. In 12 patients with 0-IIa formations, resection was performed without prior biopsy. In these cases, the

resection decision was made on the basis of histological type prediction using a pit pattern classification (S. Kudo, 1994) or NICE for a narrow spectral inspection. In two cases, the formation of more than 20 mm was fragmented and removed. Histological analysis showed tubular and tubularly adenovirus adenoma with mild and moderate degree of dysplasia in 17 preparations, hyperplastic polyp in 2 preparations, jagged adenoma on a broad base in 1 preparation, suspicion of GIST in 1 drug. In 2 preparations of neoplastic changes it is not revealed. Early complications were noted in two cases. In one case, bleeding after removing a 20 mm formation located near the dentate line was stopped by the endoscopic method of coagulation, the mucosal defect was clipped. One patient developed a post-polypectomy syndrome in the early postoperative period after the removal of the cecal formation of 12 mm in size, conservative treatment.

Conclusions. The method of endoscopic resection of the mucous membrane is an effective and safe method of treatment of non-lipid epithelial colon formations up to 20 mm in size, including when mastering the method.

260

THE CHOLECYSTOSTOMY OR THE LAPAROSCOPIC CHOLECYSTECTOMY. WHAT HELP SHOULD BE GIVEN IN CASE OF GALLSTONE DISEASE?

O. Lutsevich¹, E. Galliamov², M. Agapov³, Yu. Bysirev², G. Gadlevskiy²

¹A.I. Yevdokimov Moscow State University of Medicine and Dentistry, Moscow, Russia; ²Federal State Autonomous Educational Institution of Higher Education I.M. Sechenov First Moscow State Medical University of the Ministry of Health of the Russian Federation (Sechenov University), Moscow, Russia; ³University clinic Lomonosov Moscow State University, Moscow, Russia

Treatment of complicated (destructive) forms of acute cholecystitis remains to this day one of the most urgent problems of emergency surgery.

Materials and Methods. We have experience in treating 109 patients aged 53 to 90 years with destructive forms of cholecystitis, which in surgical hospitals of the city between 1998 and 2017. at the initial treatment under the supervision of ultrasound was transdermal transhepatic puncture cholecystostomy was imposed. More than half of these patients turned to us for help in the last 6 years. Studying the anamnesis of these patients, we found that cholecystostomy was performed at the time from 2 to 9 days from the time of admission (on average on days 4-5), i.e. after a fairly long examination and conservative treatment. One more fact raises questions: the majority of patients entered the period from 1 to 3 days from the onset of the attack, i.e. at a time when radical surgery is accompanied by minimal risks of

iatrogenic damage!

Result. All patients with functioning cholesterol were subjected to surgical treatment within a period of 1.5 hours to 2 days from the time of contacting us for help. The timing of cholecystostomy at the time of repeated hospitalization was 3 to 48 days, an average of 10-15 days. All patients were successfully laparoscopic cholecystectomy, the duration of the operation was from 25 to 70 minutes (an average of 35-40 minutes), the period of postoperative hospital stay did not exceed 3 days. There were no serious postoperative complications and deaths.

Conclusion. Thus, our 26-year practical experience in the use of minimally invasive surgical methods for treating complicated forms of acute cholecystitis (more than 5000 laparoscopic cholecystectomies) allows us to draw a number of conclusions: 1. Cholecystostomy involves a rather long and complicated period of stage-by-stage treatment, which is often unacceptable for most able-bodied patients. 2. Presence of foci of necrosis of the wall of the gallbladder (with gangrenous cholecystitis in peri-vesical infiltration), as a rule, does not lend itself to conservative treatment, supporting inflammatory phenomena in this zone and chronic purulent intoxication of the patient even in the presence of a functioning cholecystostomy. In other words, the cholecystostoma does not solve the tasks in this situation. Such patients need urgent surgery at the earliest time of admission to the hospital. 3. In most cases, the use of cholecystostomy with destructive cholecystitis is impractical. The use of the technique is possible as a palliative care in patients of the older age group with extremely high operational risk. 4. Radical surgical intervention in the laparoscopic variant in the early (1-4 days from the onset of the attack) is accompanied by a minimum number of complications, and is the operation of choice in the vast majority of patients with destructive cholecystitis.

261

DOES PREOPERATIVE CHEMORADIOTHERAPY IMPROVE THE RESULTS OF TREATMENT UPPER RECTAL CANCER

J. Madyarov, A. Rasulov, D. Kuzmichev, Z. Mamedli, A. Polynovskiy

Colorectal department, N.N. Blokhin National Medical Research Center of Oncology Moscow, Russia

Relevance: in present time, neoadjuvant chemoradiotherapy for distal rectal cancer are part of clinical guidelines in Europe and USA. according to the literature, there is no unified standarts for upper rectal cancer

Objective: a comparative results of surgical and combined treatment for patients with upper rectal cancer.

Materials and methods: the study included data from patients over 18 years old, with histologically proven

adenocarcinoma with TNM stage T2-4aN0-2M0 and tumor location in the upper part of the rectum. In the main group (A), preoperative chemoradiotherapy was performed: short course radiotherapy (5x5 Gy), with capecitabine 2000 mg/m² × 2 times for 14 days, followed by surgical treatment. In the control group (B) only surgical treatment was performed - partial or total mesorectumectomy.

Results: from January 2004 to December 2014, 226 (99.6%) underwent surgical treatment. The incidence of postoperative complications by Clavien-Dindo scale was: group A - 17 (16.5%) and group B - 11 (8.9%). Locoregional recurrences in group A occurred in 1 patient (1.2%), in group B - in 3 (2.5%) patients (p = 0.413). Distant metastases in group A developed in 10 (10.2%) patients, in group B -15 (12.6%) patients (p = 0.581). Overall survival was in group A - 90.6%, recurrence-free - 89.6%; in group B - 82.8% and 81.9%, respectively (p = 0.46). Multivariate analysis showed that the affected regional lymph nodes were the main predictor of poor prognosis (p = 0.001, OR = 0.094, CI = 0.035-0.250) and significantly reduced the 5-year disease-free survival rate (p = 0.001, OR = 4.213, CI = 2.010-8.830)

Conclusion: the results of the study showed that neoadjuvant chemoradiotherapy in comparison with the surgical method do not have advantage for patients with upper rectum cancer.

262

SHUNTING INTERVENTIONS FOR THE CORRECTION OF PORTAL HYPERTENSION

G. Manukyan, V. Lebezev, E. Kitsenko, R. Musin, E. Fandeyev, A. Markarov

Federal State Budgetary Scientific Institution B. V. Petrovskiy Russian National Research Center of Surgery, Moscow, Russia

Relevance. Increasing amount of the diseases leading to various types of portal hypertension (PH), insufficient level of transplantational care in the country or the absence of indications to liver transplantation in certain groups of patients and the risk of gastroesophageal variceal bleeding make the problem of PH correction by means of shunting surgery highly relevant.

Aim. Demonstration of a differentiated approach to the choice of portosystemic shunting (PSS) technique for treatment of patients with various types of PH.

Materials and Methods. Five hundred and five PSS operations were performed in the Clinic of Urgent Surgery and Portal Hypertension during last 10 years. Including 389 operations in chronic diffuse liver diseases (mainly in liver cirrhosis) and 116 interventions in various types of extrahepatic portal hypertension (EPH). The overwhelming majority of the operations was performed by means of laparotomy, 16 interventions were endovascular (Transjugular Intrahepatic

Portosystemic Shunting – TIPS), and in 4 operations of distal splenorenal shunting were laparoscopic. The analysis of these operations shows the necessity of a differentiated approach to the choice of the shunting intervention.

Results. In EPH, the presence of any patent tributary of the portal system with an appropriate diameter (≥ 8 mm) is a basis for the application of PSS. The “side-to-side” or “H-type” mesentericocaval shunts are most commonly used. Long-term adequate anticoagulation should be performed to keep the shunt patent. In patients with liver cirrhosis, selective and partial types of shunting (with the diameter of the anastomosis 8 – 10 mm) are the operations of choice: splenorenal, splenocaval or gastricocaval shunting. The preference is given to distal types of shunting procedures (with the ligation of the proximal part of portal vessel) which are performed in different variations: “end-to-side” (Warren), “side-to-side” or “H-type” (with the synthetic graft interposition). TIPS procedure is indicated when endoscopic techniques for variceal eradication are ineffective, surgical decompression is impossible but there’s still a high risk of bleeding; in cases of combination of resistant ascites and high risk of variceal bleeding; and in patients with Budd-Chiari syndrome. In PH, portosystemic shunting is the only radical method for its correction and is able to influence in the most effective way morbidity and main symptoms of PH: esophageal and gastric variceal transformation, especially when there’s a risk of bleeding, portal hypertensive gastropathy, ascitic syndrome, large splenomegaly and hypersplenism, entero- and colopathy.

Conclusion. Surgical portosystemic shunting, method and type of the intervention are determined by the nature of pathological process, severity of the underlying disease, anatomic features of the portal basin vessels, the status of the basic parameters of portohepatic haemodynamics.

criteria and their quantitative values served as research data metabolic status and protein-energy malnutrition (PEM) in cirrhotic patients. Given the special role of violations "trophic homeokinesis" in the pathogenesis of the disease and the need for quantitative objectification "power status", in 166 patients with liver cirrhosis with varying severity of its current study was conducted in nutritional and metabolic status. The parameters of somatic protein known reserves used anthropometric indices, which is calculated by known formulas correlated with ideal values on the floor, and the degree of scarcity. The degree of protein deficit in the somatic department was determined on the basis of common dependencies. The parameters used visceral protein levels of serum albumin and transferrin, correlating the values obtained with the standard grading the degree of deficiency. In the study groups, catabolic intensity was assessed by level of daily excretion of 3-methylhistidine in urine, and also the dynamics of the nitrogen balance and the content of free amino acids in blood plasma.

Results. Violations of nutritional status detected in 90.4% of cases, and, mild protein deficiency was found in 52 (31.3%) patients, the average degree - in 55 (33.1%) patients and in 43 (26%) patients with established severe protein deficiency. In connection with the findings have been allocated five clinical groups or functional classes corresponding to the stages of progression CLF and reduce backup capacity of the patient (table). According to the allocated treatment groups and received in the course of the study data to quantify indicators of nutritional status, changes in hemo-dynamic parameters, as well as the dynamics of the most important clinical disease syndromes such as ascites, hepatic encephalopathy and jaundice, was developed a modified assessment system surge capacity cirrhotic patients.

Conclusions. The clinical experience of using modified childa classification indicates its effectiveness in optimizing surgical tactics in the treatment of patients with cirrhosis and portal hypertension. This classification is not an alternative system of tests Child and its modifications, but complements them in difficult situations for the clinical assessment for more precise characteristics of surge capacity in cirrhotic patients and GHG, especially with the need to prepare for surgery and post-operative during monitoring.

263

A MODIFIED SYSTEM FOR ASSESSING THE RESERVE CAPACITY OF THE BODY AND THE DEGREE OF COMPENSATION FOR THE DISEASE IN PATIENTS WITH CIRRHOSIS AND PORTAL HYPERTENSION

G. Manukyan, A. Sherzinger, R. Musin

Russian Research Center of Surgery named B.V. Petrovskiy

Relevance. Dissatisfaction in the application of the scale of Child and its modifications (Puqh, Turcotte) when choosing a differentiated treatment program in surgery in patients with liver cirrhosis (LC) and portal hypertension (PH), was the basis for the modification of the prediction system in assessing the severity and extent of compensation disease.

Aim. Optimization of assessment of the degree of disease compensation and surgical tactics in the treatment of patients with cirrhosis and portal hypertension.

Material and Methods. Locomotive to revise the evaluation

Parameter	Modified functional classes				
	A	A-B	B	B-C	C
Somatic Protein (% of deficit)	0-5	5-10	10-15	15-20	>20
Visceral Protein Albumin (g/l)	>40	40-35	35-30	30-25	<25
Ascites	abs	USG visual	I gr. IAC	II gr. IAC	III gr. IAC
PSE (grade)	abs	Asthenia	±Latent	I-II gr.	III-IV gr.
Bilirubinemia	N	transient	≤2 N	2-3 N	≥3 N
Central Hemodynamics	Normokinetic type of circulation		Hyperkinetica SV>60 ml	Hypokinetica SV 60-40 ml	Hypokinetica SV<40 ml
Velocity of Bl. Fl. in the Portal Vein (ml/min)	≥1200	1200-900	900-600	600-300	≤300 or portal thrombosis

264

THE MODIFIED SYSTEM OF ASSESSMENT OF RESERVE OPPORTUNITIES OF AN ORGANISM AND EXTENTS OF COMPENSATION OF A CHRONIC LIVER FAILURE

G. Manukyan, R. Musin

Russian Research Center of Surgery named B.V. Petrovskiy, Russia

Dissatisfaction in the application of the scale of Child and its modifications (Puqh, Turcotte) when choosing a differentiated treatment program in surgery in patients with liver cirrhosis (LC) and portal hypertension (PH), was the basis for the modification of the prediction system in assessing the severity and extent of compensation disease. Locomotive to revise the evaluation criteria and their quantitative values served as research data metabolic status and protein-energy malnutrition (PEM) in cirrhotic patients. Given the special role of violations "trophic homeokinesis" in the pathogenesis of the disease and the need for quantitative objectification "power status", in 166 patients with liver cirrhosis with varying severity of its current study was conducted in nutritional status. The parameters of somatic protein known reserves used anthropometric indices, which is calculated by known formulas correlated with ideal values on the floor, and the degree of scarcity. The degree of protein deficit in the somatic department was determined on the basis of common dependencies. The parameters used visceral protein levels of serum albumin and transferrin, correlating the values obtained with the standard grading the degree of deficiency. Violations of nutritional status detected in 90.4% of cases, and, mild protein deficiency was found in 52 (31.3%) patients, the average degree - in 55 (33.1%) patients and in 43 (26%) patients with established severe protein deficiency. In connection with the findings have been allocated five clinical groups or functional classes corresponding to the stages of progression CLF and reduce backup capacity of the patient. According to the allocated treatment groups and received in the course of the study data to quantify indicators of nutritional status, changes in hemodynamic parameters, as well as the dynamics of the most important clinical disease syndromes such as ascites, hepatic encephalopathy and jaundice, was developed a modified assessment system surge capacity cirrhotic patients. This classification is not an alternative system of tests Child and its modifications, but complements them in difficult situations for the clinical assessment for more precise characteristics of surge capacity in cirrhotic patients and GHG, especially with the need to prepare for surgery and postoperative during monitoring.

265

INTRACORPOREAL ANVIL INTRODUCTION DURING ROBOTIC RECTAL RESECTION "VIJAN POP TECHNIQUE": TECHNIQUE AND INITIAL RESULTS (VIDEO)

Marino Marco Vito¹, Shabat Galyna²

¹Department of Surgery - Hospital Villa Sofia - Cervello of Palermo (Italy)

²Department of Colorectal Surgery -Brigham and Women's Hospital - Harvard Medical School Boston (MA, USA)

Object: Most of the minimally invasive colorectal procedures are associated to a laparotomy incision when the anvil should be introduced inside the colon before a mechanical anastomosis during a robotic rectal resection (RR).

Materials and methods: From April 2016 to March 2018, 40 patients underwent to robotic RR, with a new surgical technique for the anvil introduction "Vijan Pop", which consist in a intracorporeal insertion thus preserving the abdominal wall before the anastomosis

Results: Among 40 patients (22 Male, 16 Female), 28 presented a BMI higher than 30. The overall time required for introducing anvil and performing the anastomosis was 22 minutes (18-36). In only two cases we experimented a disposition of the anvil inside the colon lumen. No patients required a laparotomy to complete this surgical step. No one of patients experimented an anastomotic post-operative complication. In all cases the specimen extraction was completed trough a Pfannenstiel incision. The median wound incision length was 3 cm, and no wound infection was observed in the postoperative course.

Conclusions: The Vijan Pop technique seems to be safe and feasible approach offering interesting results mainly in obese patients or when a cosmetic incision is requested.

266

ROBOTIC PARTIAL CAUDATE LOBE RESECTION: TECHNICAL CONSIDERATION (VIDEO)

Marino Marco Vito¹, Galyna Shabat²

¹Azienda Ospedaliera "Villa Sofia" Palermo, Department of Surgery, University of Palermo, PA, Italy

²Brigham and Women's Hospital, Department of Surgery, Harvard Medical School Boston. MA, USA

Background: Firstly described in 2002, the widespread of robotic liver surgery didn't reach the desired consensus. It can overcome the traditional limitations of laparoscopic approach.

Methods: We analyzed the postoperative outcomes of 15 patients undergoing to robotic resection of caudate lobe since March 2015 to April 2017 in order to evaluate the

advantages of robotic approach also in hands of a young surgeon.

Results: The overall mean operative time was 425 min (range 2350,550) and the estimated blood loss was 212 ml (range 90,620), no blood transfusion was required. Only 2 patients (13.3%) underwent to conversion to open surgery for oncologic reason; the overall morbidity was 3/15 (20%) and all complications occurred (2 biliary fistula and 1 abdominal collection) were classified like minor. The histological characteristics showed a mean surgical margin of 18 mm and we achieved a R0 resection rate of 86.7% (13/15). The reoperation and 90-days mortality rate were both null. The 1-year overall and disease free-survival rate were 88% and 72% respectively.

Conclusions: The robotic resection of caudate lobe is a safe and feasible technique, providing interesting short-term outcomes and oncological results also in the initial phase of learning curve.

267

ROBOTIC REPAIR OF IATROGENIC COMMON BILE DUCT INJURY AFTER LAPAROSCOPIC CHOLECYSTECTOMY: A SINGLE INSTITUTION EXPERIENCE

Marino Marco Vito¹, Gianpaolo Vaccarella¹, Andrzej Lech Komorowski²

¹*Azienda Ospedaliera "Villa Sofia" Palermo, Department of Surgery, University of Palermo, PA, Italy*

²*Department of Surgical Oncology, Maria Skłodowska-Curie Memorial Institute of Oncology, Cancer Centre, Kraków, Poland*

Introduction: The bile duct injury after cholecystectomy can be a life-threatening complication. It is a difficult to manage event, especially when an extensive injury is diagnosed. The robotic surgery have already shown its potential advantages in operations requiring a fine dissection and microsuturing capabilities. The use of robotic approach to manage complex biliary injury is in its first phase.

Methods: We have performed a retrospective analysis of our prospectively maintained database that included 10 patients who underwent robotic-assisted repair of bile duct injury after laparoscopic cholecystectomy between 2013 and 2017.

Results: All patient underwent early robotic biliary repair (within 2 weeks after primary surgery). No conversion to open surgery was necessary, the estimated blood loss was 352 ml and the mean operative time were 260 min. The mean length of stay was 9.4 days (6-13 days). The 30-day complication rate was 30 % and included a subhepatic abscess, severe postoperative anemia and a recurrent episodes of cholangitis. No patient died during postoperative period.

Conclusion: The robotic-assisted bile duct injury repair seems to be safe and feasible. It can be successfully used also in a centre without important experience in laparoscopic biliary tree repair.

268

FIRST EXPERIENCE OF LAPAROSCOPIC OPERATIONS IN PATIENTS WITH LIVER CIRRHOSIS AND PORTAL HYPERTENSION

A. Markarov, R. Musin, S. Zhigalova, G. Manukyan V
FGBSI "Russian Scientific Center of Surgery named after acad. B.V. Petrovsky"

Actuality: An important trend in the surgery of portal hypertension (PG) of patients with liver cirrhosis (LC) is the desire to use minimal invasive interventions. In this regard, it becomes relevant to study the results of the use of laparoscopic technologies in this group of patients.

Objective: To assess the first results of the introduction of laparoscopic techniques in the clinical practice of surgical treatment of patients with LC and PG.

Materials and methods: 18 laparoscopic operations were performed: 14 operations for gastric devascularization and cardio-esophageal junction combined with combined endoscopic ligation, and 4 interventions to perform distal spleno-renal anastomosis (CPA). Distribution of patients according to Child's criteria: group A - 7 patients, group B - 11. All patients diagnosed varicose veins (VV) of the esophagus and stomach of grade 3 with recurrences of bleeding in the anamnesis: in 12 with localization of cardio-esophageal veins of type 1 and in 6 - 2 types. All patients, in addition to clinical and laboratory examination, performed computed tomography with 3D reconstruction of the vessels of the portal system. Only 4 patients with a relatively favorable topography of the splenic and renal veins by CT angiography, was revealed for performing a shunting operation by a laparoscopic method. Indications for the operations of azigo-portal dissociation (APD) were the age of patients, the presence of concomitant pathology and some patients with the presence of thrombosis of the vessels of the portal system.

Results: By four of 14 patients, was noted the reduction of the gastric VV, and therefore, no additional combined endoscopic ligation (EL) was required. The remaining 10 patients had a combined EL during laparoscopic operation. In 3 cases of attempt CPA, a conversion was required: 1 patient - due to damage to the functioning umbilical vein, 2 others - due to difficulties in identification the renal vein. All of them performed shunt by open operation. Only in 1 of 4 cases there was possible to perform Warren's operation. Repeated EL esophagus VV for preventive purposes were required for 8 patients which were underwent APD. There were not noted any complications by patients who underwent CPA, ; in the long-term period – identified eradication of VV.

Conclusions: Difficulties with performing shunt operations are associated with mastering the technique and making mistakes in the selection of patients. Careful selection of patients with appropriate constitutional data and a preliminary accurate assessment of the anatomical and topographic relationships of the vessels of the portal system is necessary. The advantage of laparoscopic interventions is the earlier rehabilitation of patients. APD operations require further improvement of the technology and composition of the intervention. Laparoscopic operations can have the niche in the general spectrum of surgical interventions for patients with LC and PG.

269

RECONSTRUCTION OF THE BILIARY TRACT USING A JEJUNAL CONDUIT INTERPOSITION OF VARIABLE DIAMETER

P. Markov

Kuban State Medical University, Krasnodar, Russia

Background. The standard surgical procedure for reconstruction of extrahepatic bile duct in case of major bile duct injury, biliary stricture and cyst is Roux-en-Y hepaticojejunostomy. Nevertheless this method is not anatomical and physiological. The ideal interposition for restoring the continuity between the biliary tract and duodenum is a pedicle graft of jejunum reduced in caliber to approximately that of the ductal system. But in case of high stricture this method cannot be used.

Aim. Improve the results of treatment of patients with major bile duct injuries, iatrogenic biliary strictures and biliary cysts.

Methods. We present new method of reconstruction extrahepatic bile duct using an isolated intestinal segment of a variable diameter: the proximal part remains of original intestine segment during 3-5 cm (to create hepaticojejunal anastomosis in the hepatic hilum or with separate anastomoses for isolated right and left hepatic ducts) and then the diameter of graft is reduced to 1 cm, proportional to the biliary tract. For this the antimesenteric part of the intestinal wall of the distal part of intestinal segment was resected, and the free edges of the intestinal wall were sewn together so that the diameter of the graft 1 cm throughout several cm was obtained. The distal anastomosis was formed with the end of the common bile duct or (in case the end of the common bile duct could not be used) with duodenum.

Results. This method was applied in 12 patients. 5 patients were Bismuth III and 7 - Bismuth IV. There were no intraoperative or postoperative deaths (30-day or in-hospital deaths). There were three postoperative complications. Long-term results were obtained in all patients up to 11 years. The mean follow-up was 6 years. There were no recurrence of stricture, cholangitis and normal biochemical parameters were observed.

Conclusions. This new technique is a new option for the reconstruction of extensive extrahepatic bile duct injuries and strictures.

270

PEDIATRIC LIVER TRANSPLANTATION FOR MALIGNANCY: RETROSPECTIVE ANALYSIS OF OUTCOMES IN A SINGLE CENTER

Angel Flores-Huidobro Martínez², Shiro Fujita¹, Rebecka Meyers⁴, Linda Book⁴, Ivan Zendejas⁴, Eric Scaife¹, Manuel I. Rodriguez-Davalos¹

¹Primary Children's Hospital, Transplant Department, Salt Lake City, UT USA

²Brigham and Women's Hospital, Harvard-MIT Program for Health Sciences and Technology, Harvard School of Medicine, Boston, MA USA.

Classifications. Type Clinical/Outcomes Clinical Area Transplantation Scientific Area Patient-Centered Outcomes Conflict of Interest Declarations: none. Introduction: Hepatoblastoma (HBL) is the most common type of liver malignancy in children, representing 80% of all liver tumors and 1-2% of pediatric tumors (1). It usually presents before the age of four and seems to affect more male patients over females in a ratio that varies from 1.2 to 3.6:1 (2). The standard of care for HBL remains to be the surgical resection of the affected portion of the liver (1, 4). Even when chemotherapy has shown to significantly reduce tumor size preoperatively, in 60% of the cases the tumor is unresectable due to its extensive hepatic involvement, thus leading to liver transplantation as the ultimate surgical resource. The aim of this study is to review patient and graft survival in a cohort of patients with liver malignancy who underwent liver transplantation at our center.

Methods: A retrospective review from 219 transplants performed at our institution was done. All patients diagnosed with liver malignancy who underwent a liver transplantation as treatment from 1998 to 2017 were analyzed. This study was approved by the Hospital's Institutional Review Board. Demographics, age at the time of transplant, prior resections, type of graft, vascular complications, salvage transplantation, survival rate and recurrence were evaluated.

Results: From the 219 transplants performed in our center over the last two decades, 16 transplants (7.3%) were performed for malignancies in 15 patients. Out of 16 cases, 13 transplants (81.2%) were performed for hepatoblastoma, 2 for hemangioendothelioma (12.5%) and 1 for pancreaticoblastoma (6.25%). 5 transplants were from living donors and 11 from deceased donors (3 technical variants and 8 whole). The mean age at transplant was 4.19 years (range: 0.6-7.1 years), 9 patients were female (60%). Out of 15 patients; 12 survived and 3 died (2 from recurrence and metastatic activity and one from graft dysfunction and cardiac failure).

All the patients with diseases other than hepatoblastoma are alive and doing well. Overall one year patient and graft survival was 80% and 75% respectively.

Conclusion: 100% survival rate was observed in patients that survived 6 months after transplant and an overall graft survival of 93% with an average follow-up of 8.6 years (7 months to 19 years). Half of our cohort received technical variants either from living donors or split/reduced size grafts. Histology of the patients that died from recurrence of disease was consistent with small cell undifferentiated variant of hepatoblastoma. Based on our results, primary liver transplantation is advised for patients suffering from liver malignancy.

271

SPLenic FLEXURE MOBILIZATION – STEP BY STEP

Martins Sónia Fortuna; Vilela Nuno; Ferreira Luis; Sintra Paulo; Jarimba Aldo; Lopes Maria

Hospital de Santarém, Santarém, Portugal

Introduction: The splenic flexure mobilization is a complex surgical maneuver associated with morbidity like bleeding (splenic, pancreatic and colic vessels) and lesions of pancreas, spleen and colon. The authors of this movie consider this procedure extremely important, and apply it routinely in all medium and low rectum surgery or when is needed a total excision of the mesorectum or in a low colorectal anastomosis. Sometimes, the authors also do it in left or transverse colon excisions. One of its big advantage is that it allows the reduction of the anastomosis tension, avoiding one of the anastomosis worst enemies: the ischemia. Because of that, the authors strongly believe that this approach should be systematized. Its association with laparoscopy improves the exposition and observation of structures lowering morbidity, and allows an easy way of teaching the maneuver to the others.

Methods and steps: The authors report a movie demonstrating the systematized splenic flexure mobilization. The steps are, in a laparoscopic approach from medial to lateral: Step one: Recognition of inferior mesenteric vein and its dissection until the inferior edge of the pancreas. Identification of the avascular plane that separates the left mesocolon from the Gerota fascia, and deviate the structures to create a tunnel by lifting the left mesocolon and move away the Gerota fascia, until identifying the left kidney and the pancreas; Step two: gain access to the epiploon retrocavity by opening the transverse mesocolon until reaching the gastric wall; Step three: inferior mesenteric vein ligation (in the inferior edge of the pancreas). Step four: Detachment of the left mesocolon from the pancreas (pancreaticocolic ligament) until the pancreatic tail, and leave a surgical dressing there; Step five: release of the left parietocolic fold until reaching the plane previously dissected (by reaching the

surgical dressing); Step six: Release the colon from the great omentum.

272

TRANSANAL TOTAL MESORECTUM EXCISION (TATME): RESULTS FROM A SECONDARY HOSPITAL

Martins Sónia Fortuna; Duarte Marina; Vilela Nuno; Ferreira Luis; Sintra Paulo; Lopes Maria

Hospital de Santarém, Santarém, Portugal

Introduction/Objective: aTME is a technique that combines abdominal and transanal endoscopic approach to overcome limitations and facilitate standard laparoscopic TME. We pretended to evaluate the results of the first years of taTME of our institution.

Methods: It was reviewed retrospectively the records of the all consecutive patients submitted to taTME in a single center between January 1st of 2014 and 31st May of 2018.

Results: 23 patients were submitted to taTME: 21 males, 2 females, with a medium age of 66 years. 20 of them had known comorbidities, like arterial hypertension, diabetes... Neoadjuvant quimioradiotherapy was given to 18 patients. 15 ASA II, 8 ASA III. All of the specimens had integral and incompact mesorectum, all R0 resections, with an average of 24 lymphatic nodes excised per person. The average hospital stay was 8,7 days. Six cases of post-op morbidity but only two cases of re-intervention: 1 urinary retention, 3 pelvic abscesses (treated with systemic antibiotics), 1 ischemia of the descending colon (submitted to left colon excision + colostomy) and 1 case of anastomosis leakage (submitted to conservative treatment with success). Only one patient was submitted to protective ileostomy.

Conclusion: taTME is a technically demanding but feasible technique, with apparently good results in the quality of the extracted specimen and the oncological safety of the procedure. In our series, it had an apparent low grade of complications and re-interventions. Nonetheless, we emphasize that only one patient were submitted to protective ileostomy, and that the procedure doesn't need to be done routinely.

273

TRANSANAL TOTAL MESORECTAL EXCISION (TATME) – HOW WE DO IT

Martins Sónia Fortuna; Vilela Nuno; Ferreira Luis; Sintra Paulo; Jarimba Aldo; Lopes Maria

Hospital de Santarém, Santarém, Portugal

Introduction: Transanal total mesorectal excision arise as a

technique that combines abdominal and transanal endoscopic approach to overcome limitations and facilitate the abdominal procedure. This is the ideal approach for patient with mid or low rectal cancer. Performing a good TME, especially in case of narrow pelvis, male patients, previous irradiation, advanced tumors and obesity, might be challenging. This procedure is complex and requires experienced surgeons aware of anatomical and technical aspects regarding this procedure.

Methods and steps: The authors report a movie demonstrating a transanal total mesorectal excision. The authors think that the two team approach has several advantages: it allows to save operative time and facilitate the procedure by guiding the transrectal team during the final part of the transanal dissection. The abdominal part of the procedure is performed as in standard laparoscopic anterior resection. Full mobilization of the splenic flexure is mandatory to have adequate bowel length for transanal specimen extraction and preparation of descending colon for a tension free low anastomosis. Dissect upper mesorectal plane posteriorly along the sacral plane and laterally, respecting hypogastric nerves and ureters while anteriorly the peritoneal reflection has only to be incised. In the transanal part, a purse-string suture is placed distal to the tumor. The surgeon should place "small bites" in order to obtain an air tight closure of the rectum that will allow a stable working field without blowing the colon above. Mark circumferentially the mucosa of the rectum with monopolar hook and then start full thickness rectotomy usually in the posterior plane (where the plane between the presacral fascia and mesorectal envelope is relatively easy to identify) and then circumferentially. In male patients anterolateral dissection proceeds toward the level of prostate-seminal junction, identifying small vessels penetrating the prostate (bundles of Walsh) that work as a landmark to find the correct plane of dissection entering Denonvilliers' fascia. The same plane is to be found in females where the anterior plane of dissection should be carried out at the level of the junction of lower and middle third of posterior vaginal wall. Excessive bleeding during mesorectal excision could reveal a wrong dissection plane. Once the specimen has been removed, coloanal anastomosis is performed, either end-to-end or side-to-end with hand-sewn or stapled technique, depending on the case. We place a transanal tube at the end of procedure to reduce endoluminal pressure in the anastomotic bowel portion, to prevent anastomotic leakage.

274

DIFFERENTIATED PROGRAM OF SURGICAL TREATMENT OF PATIENTS WITH ACUTE OBSTRUCTIVE COLON CANCER IN A MULTI-FIELD EMERGENCY HOSPITAL

G. Martynova¹, A. Demko¹, N. Sizonenko², O. Babkov¹, A. Sviatnenko^{1,2}, I. Soloviev², D. Surov²

¹Saint Petersburg I.I. Dzhanlidze research institute of emergency medicine, Russia

²S.M. Kirov Military Medical Academy, Saint Petersburg, Russia

Actuality. All over the world more than 1000000 new causes of colon cancer, that takes second place among women and third among men in structure of oncology, are diagnosed each year. Here with nearly 20% of patients go to emergency hospitals with various complications, most common of which is acute obstruction.

The aim. To assess the effectiveness of developed medical and diagnostic tactic of surgical treatment of patients with acute obstructive colon cancer.

Materials and methods. The study included 134 patients with complicated colon cancer operated during the period from 2016 to 2017. The middle age of patients is 70,3 years. Women – 44 (33%), men - 90 (67%). The medical and diagnostic tactics used is based on principles of early diagnosis of a developing complication of colon cancer, objective assessment of its severity, as well as the severity of the patient's condition (scale MODS II), which results determined the characteristics of intra-hospital routing of patients. Patients with a clinical status of advanced peritonitis and/or phenomena of multiple organ dysfunction (group 1, n=21) are performed emergency surgery after short-term preparation in a surgical intensive care department. Patients with a symptoms of acute colonic obstruction without the phenomena of widespread peritonitis and multiple organ dysfunction were hospitalized in surgical department for multicomponent conservative therapy and to try endoscopic recanalization of tumor. If it was ineffective (group 2, n=75), then urgent surgery were performed. The positive clinical effect of conservative therapy (group 3, n=38) created conditions for pre-examination of patients and surgery in a deferred order. We believe the main objectives of the operation are to eliminate life-threatening complications with modern principles of cancer radicalism and ensure high quality of life of patients in the postoperative period. The main elements of intraoperative tactics were decompression of the colon and small intestine (according to indications), rejection of long-term nasogastrintestinal intubation, creation of conditions for early enteral support, minimizing the number of drains, and rectus sheath catheterization to carry out rectus sheath block. We believe the basic requirements for operative surgery are its compliance with the principles of the embryological validity, focus on obtaining a quality medication (negative edges of resection) and ensuring adequate control of lymphogenous metastasis pathways. Tactics of post-operation patient management was based on individual components of

a multimodal rapid rehabilitation program adapted to the conditions of the urgent surgery.

Results. Postoperative complications were developed in 17% of patients (n=23): 4 patients – I-IIIa grade and 19 patients – IIIb-IV grade by Clavien-Dindo classification. The highest morbidity was registered in patients of the first and second group: 9 and 6 causes, respectively. 4 postoperative complications were registered in the third group. Total mortality is 12,5% (n=17). Improvement of the quality of life before the initial, as well as physical and psychological components of health on the 30th day after discharge was registered in 95 patients (82%).

Conclusion. This medical and diagnostic tactics is effective by improving the immediate results of surgical treatment.

275

GUT HORMONES IN BARIATRIC SURGERY. SYSTEMIC EFFECTS

E. Mayorova

1st MSMU, Moscow, Russia

Since the first pathophysiological works in gut hormones physiology and influence of various bariatric techniques, a great breakthrough have been made in understanding the weight loss hormonal regulation as well as other metabolic effects mediated by altered gut endocrine system. Gut hormones are involved in various bariatric (metabolic) surgery-related pathophysiological mechanisms. Besides food intake restriction and nutrient malabsorption, various incretin effects obviously make a contribution to reducing body weight, improving glycaemic control and thus long-term outcomes of bariatric operations, not only in morbid obesity, but in a range of metabolic disorders as well. Gut hormone effects, those of incretins first of all, are now widely investigated for possible impact on metabolic, dyslipidemic, endothelial and other systemic disorders improvement after bariatric surgery. Several regulatory hypotheses are assessed as possible mechanisms of remission of type 2 diabetes mellitus independent of weight loss after various bariatric surgical procedures, and none is solely capable to give reasonable explanation, but most probable are thought to be excluding ghrelin-producing stomach area, and involving entero-insular axis through foregut or hindgut pathways. An elaborated selective approach to possible surgical metabolic correction will enable rather personalized care based on risks of target organs lesions.

276

THE DIAGNOSIS OF GASTRINOMA IN URGENT ABDOMINAL SURGERY

E. Mayorova, E. Stolyarchuk

1st MSMU, Moscow, Russia

Acute ulcer complications are certain hallmarks of Zollinger-Ellison syndrome. Nevertheless, the problem of prompt diagnostics encounters the technical and time-framing capabilities, so that syndromal diagnosis is rarely available in emergent care. The feasibility of urgent surgical measures outweighs the need for appropriate clinical diagnosis, but in gastrinoma it may be crucial to neglect possible complications. 7 (4 male/3 female) patients with acute peptic ulcer complications (5 – upper bleeding, 5 – perforation/penetration of duodenal/stump/anastomosis ulcers, 3 – acute erosions) underwent numerous surgical interventions (3 – gastrectomy, 4 – vagotomy, 6 – ulcer suturing), 2 survived, 5 died. In 3 cases the gastrinoma diagnosis was confirmed by serum gastrin measurement (370 – 1911 pg/ml) and in 2 was localised afterwards (1- pancreatic body, 1 – duodenum). In 5 cases the tumors (4 – head/body of the pancreas, 1 - duodenum) were discovered at autopsy, in one of them serum gastrin was just slightly elevated (120 pg/ml, N 15-85). The life-threatening ulcer complications in the urgent abdominal surgery always need gastrinoma alertness, and the establishing of the syndromal diagnosis must be carried out simultaneously with the urgent aid. Serum gastrin evaluation can take several hours, but when available may strongly support the treatment success despite the difficulties of the topical diagnosis.

277

RADIOFREQUENCY ABLATION IN TREATMENT OF LIVER AND BILE DUCTS MALIGNANT DISEASES

O. Melekhina, J. Kulezneva, M. Efanov, A. Musatov

Moscow Clinical Scientific Center of A.S. Loginov; Russian Federation

Background. Radiofrequency ablation has been increasingly used in the treatment of hepatic and bile ducts tumors. Corresponding to literature data, RFA is a safety, locoregional treatment option for these patients that should be considered a useful alternative to liver resection in some clinical cases.

Aim. To determine the effectiveness of radiofrequency ablation both as substantive treatment method and in combination with other X-Ray surgical interventions in patients with liver and bile ducts malignant diseases.

Materials and methods. In Moscow Clinical Scientific Center the radiofrequency ablation was used in three patients groups: in first group (n=111) - as a substantive treatment or

in combination with liver resection; in second group (n = 3) – in combination with transarterial chemoembolization; in third group (n=20) – in combination with right portal vein embolization in order to induce liver hypertrophy to enable liver resection – PRALPPES (Percutaneous Radiofrequency Assisted Liver Partition with Portal vein Embolization for Staged hepatectomy).

Results. Recurrence in the radiofrequency ablation zone was not observed in any cases. In patients with hepatocellular carcinoma and liver cirrhosis, two-year survival rate was 55 %. In cases of colorectal cancer metastasis, four-year survival rate was also 55%. The combination of radiofrequency ablation with transarterial chemoembolization provided complete tumor destruction in patients with hepatocellular carcinoma (tumor size over 4-5 cm) and stabilization in patients with progressive intrahepatic cholangiocarcinoma. Liver hypertrophy after Percutaneous Radiofrequency Assisted Liver Partition with Portal vein Embolization for Staged hepatectomy was over 50 % in two weeks that enable liver resection in 95 % of patients with a small future liver remnant. Symptoms of liver failure after hemihepatectomy were not observed in any patients.

Conclusions. The combination of interventional radiology treatment methods provide better results in patients with liver and bile ducts malignant diseases.

Key words: radiofrequency ablation, transarterial chemoembolization, hepatocellular carcinoma, colorectal metastasis, right portal vein embolization.

278

HYBRID LAPAROENDOSCOPIC TECHNIQUES IN CHOLECYSTOCHOLEDOCHOLITHIASIS (RENDEZVOUS TECHNIQUE): PRACTICAL WORK EXPERIENCE

K. Mersaidova¹, M. Prudkov², E. Nishnevich^{1,2}, E. Tarasov¹, A. Alekseycev¹

¹City Clinical Hospital No. 40, 620102, Yekaterinburg, Volgogradskaya, 189, Russian Federation

²General Surgery Department of Ural State Medical University, 620028, Yekaterinburg, Repina, 3, Russian Federation

Background: The algorithm for cholecystocholedocholithiasis treatment management involves extraction of bile duct stones before or after cholecystectomy or in a single-stage operation. The choice of the best strategy is often led by the local presence of professional expertise and resources. Usually simultaneous or single-stage laparoscopic cholecystectomy and endoscopic removal of common bile duct stones requires not only participation of endoscopic team and special equipment but also usage of additional C-arm that resulting in additional X-Ray exposure of the patient and necessity of interventional radiologist attendance.

Objective: To examine possibility of laparoendoscopic

Rendezvous technique in cholecystocholedocholithiasis without radiologic equipment usage.

Methods: Laparoendoscopic Rendezvous technique without additional X-Rays control were performed in 39 patients suffering from cholecystocholedocholithiasis during 2-years period. 21 (53,8%) patients had uncomplicated cholangiolithiasis in narrow bile-ducts without any laboratory detected obstructive jaundice markers (Rendezvous was performed as method of choice for treatment). 18 (46,2%) patients had cholangiolithiasis complicated with obstructive jaundice (Rendezvous was performed when other treatment options had failed).

Results: In 2 cases (5,1%) transitory hyper amylasemia without any clinical manifestations of acute pancreatitis were detected in first 12 hours-period after endoscopic papillosphincterotomy. In other 2 cases (5,1%) complicated cholangiolithiasis which required transpapillary reintervention with rest concret extraction were found. And other 2 patients (5,1%) also had complicated cholangiolithiasis but endoscopic papillosphincterotomy Rendezvous technique didn't seem possible in these cases due to impossibility to pass guidewire through the stones.

Conclusion: Hybrid laparoendoscopic techniques in cholecystocholedocholithiasis (Rendezvous technique) without additional X-Rays control is sufficiently safe to be applicable to overwhelming majority of patients suffering from cholecystocholedocholithiasis both in asymptomatic cholangiolithiasis in narrow bile-ducts and in cholangiolithiasis complicated with obstructive jaundice.

279

MINIMALLY INVASIVE TREATMENT OF COMPLICATIONS AFTER LIVER TRANSPLANTATION

A. Metelin, E. Kim, A. Filin

Petrovsky National Research Center of Surgery, Russia

Relevance: vascular and biliary complications after related liver transplantation are the most frequent and dangerous, which lead to the loss of the graft

Aim: the aim of the study is to study the possibility of minimally invasive methods in the treatment of vascular and biliary complications after related liver transplantation.

Materials and methods: 145 patients who underwent liver transplantation in NRCS since 2008 were subjected to the analysis. 13 patients were subjected to medical manipulations about vascular complications, 9 of them about portal complications, 4 patients about arterial complications. 11 patients received minimally invasive treatment for biliary complications

Results: 13 patients were subjected to mini-invasive treatment procedures for vascular complications. Complications in the portal vein of the graft was diagnosed in 9 patients. Portal vein stenting was performed in 8 patients: in 6

patients percutaneous transhepatic puncture access was used, two of them were stented from mini-laparotomy with catheterization of the inferior mesenteric vein. In 1 patient the intervention was limited to balloon angioplasty without further stenting, percutaneous transhepatic puncture access was used. All patients in the postoperative period demonstrate significant regression of manifestations of portal hypertension syndrome in the form of reducing the size of the spleen, reducing the degree of varicose veins of the esophagus and stomach, as well as the normalization of the number of platelets. Mini-invasive treatment for arterial complications was performed in 4 patients (two patients underwent repeated operations with thrombectomy and reconstruction of arterial anastomosis in the early period after transplantation). Balloon angioplasty with subsequent stenting of the artery of the liver transplant was performed in 3 patients. In one patient, the intervention was limited to balloon angioplasty without stenting. In the Department of liver transplantation, external-internal drainage was performed in 12 patients. In 5 patients fulfilled the conversion of the standing transhepatic drainage in external-internal. In one patient, the procedure was limited to external drainage. Two patients (16.7%) died, one within a month after the manipulation, death due to septic complications and dysfunction of the liver graft; the second during the year, from causes unrelated to the liver graft. The median time between primary surgery and reconstructive intervention in the biliary tract was 19,62 months (25th – 75th 3,02 – 28,25 months; 0,23 min max 101.3 per month). Three patients (25%) underwent repeated reconstructive surgery before installing the external-internal drainage. The conversion of the transhepatic drainage on external-internal was conducted using of 8.93 months – median (25th – 75th 6,23 – 10.1 months; min 3,3 max 12,57 months), after the installation of transhepatic drainage. All patients underwent stage-by-stage replacement of the external-internal drainage every 3 months with an increase in the diameter of the replaced drainage. External-internal drainage were removed in eight patients (66%), the median time standing drainage has made 21,77 months (25th – 75th 17,16 – 24,26 months; of 13.93 min max 29,37 months). One case of relapse of the stricture of the biliodigestive anastomosis was recorded 6 months after removal, re-installation of external-internal drainage in the biliary tree with separate drainage of all segments of the liver transplant was performed. The median time of observation of seven patients (58.3 per cent) with remote external-internal drainage is 9.13 months (25th - 75th 8,9 -13,17 months; min 0,3 max 17,6 months).

Conclusions: minimally invasive treatment of complications after liver transplantation is a good alternative to open treatment and shows satisfactory results

280

CLINICAL CASE OF DIAPHRAGMATIC HERNIA (HERNIA OF BOHDALEK)

V. Midlenko, S. Shamsutdinov, P. Chavkin, E. Toneev, V. Orelkin, L. Balandina

*State Healthcare Institution Ulyanovsk Regional Clinical Center for Specialized Medical Assistance
Sixth surgical department, Russia*

To demonstrate the case of a 43-year-old woman with a right-sided hernia of Bohdalek, possible methods of treatment and complications of this pathology. Despite the fact that disease is rare, this pathology should be accepted, tested and processed properly in order to avoid complications. The diagnosis was established after laboratory and instrumental methods of investigation.

Introduction. Hernia of Bohdalek is a type of congenital diaphragmatic hernia, which usually occurs in childhood - occurs in 1 of 2500-4000 newborns. In 90% of cases the hernia is left-sided. Through the formed slit-shaped diaphragm defect (in the area of the Bohdalek triangle) the abdominal cavity organs move into the pleural cavity and squeeze the lung. The prognosis for this pathology is unfavorable. Mortality reaches 30-50%. The cause of death is respiratory failure.

Presentation of the case. The 43 - year - old patient entered the admissions department of the State Medical Center of the Russian Medical Center at a serious condition in the direction of emergency medical care, with complaints of prolonged constipation, severe shortness of breath and pain in the upper abdomen. The patient had two congenital diseases: Down syndrome and congenital heart disease with an open arterial duct. Independently did not take any medicine. Trauma of the abdominal cavity or thorax was not. With an objective examination, morbidity was determined in the epigastric and right hypochondrium regions, abdominal distension, and acrocyanosis. According to general clinical laboratory analyzes, there are no significant abnormalities. Gynecological examination and ultrasound examination of the abdominal cavity organs did not reveal another pathology. When chest radiography was performed, the signs of relaxation of the right dome of the diaphragm with prolapse of abdominal organs adjacent to it were visualized. The patient was hospitalized. In connection with the increase in respiratory insufficiency, acrocyanosis to clarify the diagnosis, the MSCT of the abdominal cavity was performed: a local defect of the right dome of the diaphragm was visualized between the rib side of the diaphragm, the outer border of its lumbar part, and the upper edge of the rib 12 (the area of the lumbo-costal triangle of Bohdalek). The migration of the right kidney, the right angle of the transverse colon, the large omentum, and the loops of the small intestine into the right pleural cavity is determined. The right lung is collapsed by 2/3 due to compression of the contents of the hernial sac. In the lower

lobe of the left lung, infiltration of the lung tissue. Indications for surgical treatment for urgent indications are given. Thoracotomy on the right, lowering of the abdominal cavity and retroperitoneal space, plastic of the right dome of the diaphragm, drainage of the right pleural cavity. Clinical diagnosis: Main: Lumbocostal diaphragmatic hernia on the right with a right kidney, hepatic angle of the transverse colon, large omentum, small intestine loops into the pleural cavity. Accompanying Down syndrome. Congenital heart disease: an open arterial duct. CHF 1A, 3 F.c. Obesity 3 s.

Complication: Respiratory failure 3 tbsp. In the postoperative period, she underwent treatment in ARC conditions. Heavy current. A fatal outcome from progressive multi-organ failure.

Conclusions. Thus, considering our own clinical example, we can consider: 1. With right-sided lumbocostal diaphragmatic hernia, there may be migration of the abdominal cavity organs and retroperitoneal space into the pleural cavity. 2. In patients with genetically determined diseases - Down's syndrome and congenital heart disease (open, compensated Botalluc duct), synchronous development of the hernia of Bohdalek with the event of retroperitoneal space organs is possible.

Results. 243 patients with locally advanced HCC underwent SIRT between January 2008 and January 2017. 20 of these patients were successfully down-staged to within Milan Criteria and underwent subsequent surgical resection and RFA. At median follow-up of 15.66 months, the overall 1-year, 3-year and 5-year survival were 94.7%, 73.7% and 73.7% respectively, compared to 100%, 93.8% and 66.7% in the control group (p=0.337). Median survival was not reached after maximum follow-up of 67.63 months. Recurrence at 1, 3 and 5 years were 18.0%, 73.8% and 73.8% respectively, compared to 26.7%, 55.6% and 75.3% in the control group (p=0.780). The median time to recurrence was 20.72 months (95% CI: 12.34 – 29.10). No statistically significant differences in overall survival and recurrence were found when compared to the matched control group.

Conclusions. Patients who are not initially eligible for surgical resection or RFA due to locally advanced HCC may benefit from down-staging with SIRT. If successfully down-staged, patients may benefit from outcomes comparable to that of curatively-treated early HCC. A large prospective study is required to formally establish the role of SIRT in down-staging HCC.

281

HEPATOCELLULAR CARCINOMA DOWN-STAGED TO WITHIN MILAN CRITERIA USING SELECTIVE INTERNAL RADIATION THERAPY – A MATCHED ANALYSIS OF OUTCOMES AFTER SURGICAL RESECTION AND RADIOFREQUENCY ABLATION

Mingzhe Cai

Singapore General Hospital, Singapore

Relevance. Hepatocellular carcinoma (HCC) resected or ablated within the Milan Criteria is potentially curative, conferring a median 5-year overall survival of >60%. It is unknown if down-staging to within Milan Criteria for surgical resection and radiofrequency ablation (RFA) confers similar survival. Selective internal radiation therapy (SIRT) is a form of local-regional brachytherapy that is capable of producing good objective tumor response and future liver remnant hypertrophy, and appears to be a highly eligible option for down-staging HCC.

Object. We investigate the outcomes of surgical resection and RFA, in locally advanced HCC down-staged with SIRT.

Materials and methods. All patients with HCC and underwent SIRT between January 2008 to January 2017 were reviewed. Those who were successfully down-staged to within Milan Criteria and underwent subsequent surgical resection and/or radiofrequency ablation (RFA) were matched to controls who were also within Milan Criteria and underwent the same definitive treatment upfront. Overall survival and recurrence statistics were derived using the Kaplan-Meier function.

282

THE ROLE OF INTRALUMINAL ENDOSCOPY IN THE TREATMENT OF GASTRIC CANCER

A. Mittrakov, V. Kriazhov, V. Slugarev, O. Ilynskaya, R. Pegov

Nizhny Novgorod Regional Oncological Hospital, Russia

Relevance. The cancer of the stomach takes the leading place among cancer diseases. The main condition for the successful treatment of oncological patients is the diagnosis of the tumor process in the early stages and treatment of precancerous pathology. In recent years, along with the diagnostic direction in endoscopy, the endosurgical direction is actively developing, which allows treating both precancerous diseases and early forms of cancer with observance of oncological principles of radical treatment. The development of technologies and the introduction of new methods of treatment on the one hand and the inconsistency of approaches in different clinics on the other makes the issue of diagnostics and treatment of neoplasms of the stomach especially urgent.

Aim. To evaluate the possibility of using therapeutic methods of intraluminal endoscopy in the treatment of stomach cancer.

Materials and methods. The study included 38 patients who in the period from November 2016 to June 2018 endoscopic removal of malignant neoplasms of the stomach was performed. Among them were 25 women (65.7%) and 13 men (34.3%). The median age was 67,05 years been used in the treatment of the following endoscopic procedures: endo-

scopic mucosal resection 12 (31.5%), a submucosal layer dissection - 20 (52.6%), loop dissection in the submucosa 6 (15.7%). Method endoscopic removal was chosen based on criteria such as the type of formation, its size, location, structure of vascular pattern, the result of pre-biopsy. After removal, a thorough evaluation of the removed drug was carried out, and in the case of detection of malignancy, the radicality of the performed operation was evaluated.

Results. The analysis of complications and the frequency of relapses, which were observed in 2 (5.2%) and in 1 (2.6%) cases, respectively. The results showed that endoscopic treatment of stomach neoplasia is a highly effective method with such advantages as low traumatism and organ preservation with a low risk of complications and relapses.

Conclusions. Necessary conditions for successful outcomes are compliance with the diagnostic algorithm, selection of the method of removal and postoperative morphological evaluation of the remote drug.

283

CONVERSION SURGERY FOR UNRESECTABLE PANCREATIC CANCER WITH DISTANT METASTASIS

Miyahara Yoji¹, Yoshitomi Hideyuki¹, Takano Shigetsugu¹, Kagawa Shingo¹, Furukawa Katsunori¹, Takayashiki Tsukasa¹, Kuboki Satoshi¹, Nojima Hiroyuki¹, Miyazaki Masaru, Ohtsuka Masayuki

¹Department of General Surgery, Chiba University, Graduate School of Medicine, Chiba, Japan

²Department of General Surgery, International University of Health and Welfare, Mita Hospital, Tokyo, Japan

Relevance. Surgical and complex treatment of pancreatic tumors; Treatment strategy in non-resectable pancreatic cancer

Object: There are several reports of surgical resection for initially unresectable pancreatic cancer following favorable response to chemo(radio)therapy. However, the prognostic impact of the conversion surgery (CS) still remains unclear. The aim of this study is to examine the impact of CS for initially unresectable pancreatic cancer with distant metastasis.

Materials and methods. Between 2006 and 2017, eleven patients underwent surgical resection following chemo(radio) therapy (NAT) at Chiba University Hospital were retrospectively analyzed. All patients underwent CS when distant metastases were disappeared or obviously decreased in CT image.

Results. Patients' backgrounds are as follows; Median age (range): 63.5 (45-75) years old, Sex M/F: 4/7, Tumor location Head/Body-tail: 9/2, Metastatic sites Liver/Lung/Peritoneum 7/3/1. All-caused major complications, classified as more

than Clavien-Dindo grade III, have occurred in two patients. There was no intra-hospital death. The duration of pre-operative chemo(radio)therapy was 14.6 months of median and 6.5-35.6 months of range. The overall survival rate and disease free survival rate at 2 years were 45.5% (5/11) and 18.2% (2/11), respectively. Furthermore, one patients with liver metastasis survived for more than 10 years.

Conclusion. In the selected patients with metastatic pancreatic cancer after favorable response to chemo(radio)therapy, CS might be safe and effective. Conversion surgery can be a reasonable strategy to treat initially unresectable pancreatic cancer.

284

BLOOD CELL MARKERS PREDICTING LONG TERM OUTCOME OF PATIENTS WITH COLORECTAL CANCER

Hironori Mizuno, Norihiro Yuasa, Eiji Takeuchi, Hideo Miyake, Hidemasa Nagai, Yuichiro Yoshioka, Kanji Miyata
Japanese Red Cross Nagoya First Hospital, Japan

Relevance. Recent studies have demonstrated that various routine blood test data are correlated with long-term outcomes of patients with colorectal cancer (CRC). However, the results of these previous studies are inconsistent.

Object. The aim of the present study was to identify blood cell markers predicting long term outcome of patients with CRC independent of tumor stage.

Materials and methods. Data from 892 patients with stage -II, and -III CRC who underwent R0 resection were included. We analyzed the correlations between the preoperative blood cell data, previously reported prognostic indices, clinicopathological factors and relapse-free survival (RFS) using univariate and multivariate analyses.

Results. The 5-year RFS of patients with Stage II and III CRC were 83.8% and 62.7%, respectively. Univariate analysis showed that tumor location, stage, postoperative adjuvant chemotherapy (PAC), mean corpuscular volume (MCV), platelet count, and lymphocyte/monocyte ratio (LMR) were significantly correlated with RFS. In multivariate analysis, MCV and LMR remained the significant biomarker independent of the stage: An MCV ≥ 82 fL was associated with inferior RFS than an MCV <82 fL (hazard ratio: 1.54, 95% confidence interval: 1.03-2.37, $p=0.0352$). A LMR <3.36 was associated with inferior RFS than a LMR ≥ 3.36 (hazard ratio: 1.50, 95% confidence interval: 1.16-1.98, $p=0.0032$). The RFS of patients in stage II and III were well stratified by a MCV (<82 or ≥ 82 fl) and LMR (<3.36 or ≥ 3.36).

Conclusions. MCV and LMR are blood cell markers predicting long term outcome of patients who underwent R0-resection for stage II/III CRC.

285

INFLUENCE OF PERIOPERATIVE INTRAARTERIAL SELECTIVE CHEMOTHERAPY ON THE TIME OF RECURRENCE OF DUCTAL ADENOCARCINOMA OF THE PANCREAS HEAD AFTER PANCREATODUODENAL RESECTION

V. Moiseenko, A. Pavlovskij, S. Popov, A. Polikarpov, A. Stacenko, D. Granov

Federal State Institution "Russian Scientific Center of Radiology and Surgical Technologies" named after academician A.M. Granov of the Russian Federation Ministry of Health

Relevance. Pancreatic ductal adenocarcinoma is currently the fourth leading cause of cancer death worldwide. Mostly tumor occurs in pancreatic head. Pancreatic ductal adenocarcinoma frequently recurs despite curative surgical resection.

Object. The aim of the study is to analyze evaluation of the effect of perioperative intraarterial selective chemotherapy on the time of recurrence of ductal adenocarcinoma of the pancreas head after pancreatoduodenal resection.

Materials and methods. 169 patients underwent combined treatment in our center. The surgical stage in all groups was represented by standard pylorus preserving pancreatoduodenal resection. The main group consisted of 52 patients who received combined treatment: neoadjuvant chemoembolization (CE) with gemcitabine (400 mg/m²) and oxaliplatin (50 mg/m²), surgical treatment, and up to 6 courses of chemoinfusion in the celiac trunk with gemcitabine (800 mg/m²) and oxaliplatin (45 mg/m²) in the adjuvant mode. The first control group was presented by 59 patients who underwent perioperative RCT (neoadjuvant CE and adjuvant chemoinfusion with gemcitabine (800 mg/m²)). The second control group consisted of 58 patients who underwent only operative intervention. Progression-free survival (PFS) and time of recurrence in all groups were analyzed.

Results. One-year progression-free survival (PFS) in the main group and the first control group was 80%, in the second control group 40% ($p < 0.01$). Three-year PFS in the main group was 37%, in the first control group - 14%, in the second control group - 0% ($p < 0.01$). Five-year PFS in the main group was 11%, in the first and second control groups - not registered.

Conclusions. Conducting regional intraarterial chemotherapy contributes to a decrease in the frequency of relapses and prolongs the duration of progression-free survival in patients after the operative treatment of pancreatic head adenocarcinoma. To further assess the effectiveness of regional chemotherapy requires the implementation of multi-center studies.

286

TRANSJUGULAR INTRAHEPATIC PORTOSYSTEMIC SHUNT (TIPS) IN PATIENTS ON THE WAITING LIST OF ORTHOTOPIC LIVER TRANSPLANTATION (OLT)

A. Moiseenko, A. Polikarpov, D. Granov, P. Tarazov

FGBO A.M. Granov Russian Scientific Center of Radiology and Surgical Technology the Ministry of Healthcare of the Russian Federation, St. Petersburg, Russian Federation

Relevance. Liver disease complicated by portal hypertension are associated with high mortality and morbidity.

Aim. to analyze the efficacy and safety of TIPS in patients with Child-Pugh "C" cirrhosis in the OLT waiting list who suffer from refractory ascites and/or recurrent variceal bleeding.

Materials and methods. Between 2001 and 2018, we performed 33 TIPS in 31 patients (17 men and 14 women, mean age 41 years). The etiology of cirrhosis included: chronic viral (n=20), toxic (n=7), autoimmune (n=2) or biliary (n=2) hepatitis. Indication for TIPS was extremely high risk of variceal bleeding in 24 and diuretic-resistant ascites in 7 patients. TIPS was performed according to a standard procedure using the TIPSS-200 (Cook, USA). Self-expanding metal stent S.M.A.R.T. Control (Cordis) in 16 cases, stent-graft VIATORR (Gore) in 14 cases, and stent-graft HANAROSTENT in 3 cases were implanted. Scleroembolization of gastroesophageal varices was made in 24 patients. Two patients underwent a second operation "stent-in-stent" at 1 and 6 months.

Results. Two complications appeared: infringement of a ventral hernia after the resolution of ascites (surgical treatment) and hemorrhagic staining of ascites (hemostatic therapy). In all cases after TIPS there was a distinct intensive blood flow through the shunt with disappearance of varices. The porto-systemic gradient decreased from 13-65 to 6-12 mm Hg. Eleven patients received successful OLT in 1 to 36 (median 4) months after TIPS. During this waiting period there was no increase in ascites or bleeding from varices. Doppler ultrasound control showed good function of the anastomosis. On OLT, all shunt were patent with no signs of stenosis or thrombosis; stents in some areas were covered with "neointima". Six patients are still on the waiting list during 3-40 months. In 2 patients, new encephalopathy developed and was successfully treated with lactulose. 14 patients have died including 3 from recurrent variceal bleeding. Ten patients died from hepatic failure progression without bleeding or ascites not awaiting the donor liver. The remaining patient died outside the clinic from dental sepsis.

Conclusions. In patients with severe portal hypertension of various genesis TIPS is safe and prolongs waiting time of OLT.

287

CRYODESTRUCTION IN THE TREATMENT OF PATIENTS WITH BENIGN CYSTIC TUMORS OF THE PANCREAS

S. Morozov, A. Lobakov, N. Degtyareva, V. Marahotov

Moscow regional clinical research Institute.

M. F. Vladimirovskogo, Moscow, Russia

Clinical medical-surgical centre, 2. Omsk, Russia

Urgency. Errors in surgical tactics in benign cystic tumors of the pancreas often lead to the development of malignant transformation. The implementation of the radical extent of the operation, it is not always possible in the presence of marked inflammatory component, especially in the proximal localization benign cystic tumors of the pancreas. In this situation promising, but little studied is the use of cryoablation on the wall benign cystic tumors of the pancreas. The aim of the study was to evaluate the effectiveness of cryoablation in the treatment of patients with benign cystic tumors of the pancreas.

Materials and methods. Since 1999. by 2017. operated 57 patients with benign cystic tumors of the pancreas. Group 1 (n=32) – patients who underwent resection of the pancreas with cystic tumor of different volume. Group 2 (n=25) – patients who have undergone resection of the pancreas with a cystic tumor in combination with cryodestruction (CD), were forced to abandoned "record" benign cystic tumors of the pancreas on unpaired vessels. Diagnosed on the basis of data of computer tomography with contrast, magnetic resonance imaging mode cholangiopancreatography, Andose, intraoperative macroscopic assessment of cystic masses, morphology. Histological characteristics of benign cystic tumors of the pancreas subjected to cryodestruction: borderline (with moderate dysplasia) – 2, MCA – 9, IPMN – 11, SCA - 3. The area of cryodestruction: hepatoduodenal bunch – 5, portal vein and maxillary vein – 13, aorta-1, celiac trunk-1, the line of resection of the pancreas-2, lower vena cava - 2, tumor beds-1. Cryodestruction was carried out by cryosurgical apparatus Cryoinee with a diameter of 10 mm cryoapplicator. The temperature on the surface of the cryoapplicator-170C. In the 21st case made krioapplikatsiya forced to abandoned "record" cystic tumors on unpaired vessels 3 critica 15 seconds with spontaneous thawing. In 4 cases, cryopreservation in combination with cryoapplication was performed, which makes it possible to fully freeze hard-to-reach areas of the cystic cavity extending to the hepatoduodenal ligament, near large unpaired vessels. Statistical processing of the data was carried out by computer processing in Statistica V 10. To determine the significance of differences between the groups studied, the values of the methods were taken into account: χ^2 with Yates correction, student's criterion. Differences were considered to be significant at $p < 0.05$.

Results. In group 1 (n=32) complications developed in 34.4% of cases (necrosis of the stump-2, tela-1, pancreatic fistula-2,

acute liquid accumulation-3, abscess of the stump-2, gastrostasis-1). In group 2 (n=25)-in 24% of cases (necrosis-1, pancreatic fistula-1, acute fluid accumulation-2, stump abscess-1, Open-1 with fatal outcome) (table. 2). There are no significant differences in the frequency of complications between the two groups ($\chi^2=1,587$, $p=0,811$). In group 1 complications developed in 18.75% of cases, in the second group-in 12%. This can be explained by a decrease in the number of resection interventions on the pancreas in group II by 28.8% (68%), compared with group I (96.8%), due to the forced use of cryomethod. Organ-preserving operations using cryodestruction were performed in group II in 56% of cases, which is 49.75% higher than in group I (6.25%). There were no deaths in group 1. In group 2, one patient died after pancreatoduodenal resection from hepatic renal failure against the background of chronic alcoholic hepatitis. The mortality rate was 4%. The average bed day in the hospital in the 1st group was 23.9+7.58 K / d, and corresponds to the average K/d in the 2nd group-25.6+12.03 ($p=0.641$). All patients with cryotherapy on the wall of the cystic tumor on unpaired vessels are observed for 8 months to 13 years, no signs of continued tumor growth were observed.

Summary. 1. Cryodestruction on the wall benign cystic tumors of the pancreas increases elastichnost and radicalism of the surgery. 2. Cryodestruction does not increase the number of complications in the early postoperative period and the duration of hospital stay.

288

LYMPHOEPITHELIAL CYST OF THE PANCREAS: A CASE REPORT AND SUMMARY ON IMAGING FEATURES OF PANCREATIC CYSTS

Yosuke Namba¹, Akihiko Oshita^{1,2}, Takashi Nishisaka³, Maiko Namba⁴, Tamito Sasaki⁴, Yasuhiro Matsugu¹, Toshiyuki Itamoto^{1,2}

¹*Department of Gastroenterological Surgery, Hiroshima Prefectural Hospital, Hiroshima, Japan*

²*Department of Gastroenterological and Transplant Surgery Applied Life Sciences, Institute of Biomedical and Health Sciences, Hiroshima University, Hiroshima, Japan*

³*Department of Pathology Clinical Laboratory, Hiroshima Prefectural Hospital, Hiroshima, Japan*

⁴*Department of Gastroenterology, Hiroshima Prefectural Hospital, Hiroshima, Japan*

Background: Preoperative diagnosis of pancreatic lymphoepithelial cyst (LEC) with imaging studies is quite difficult, although it is benign and rare.

Case Presentation: We present a 49-year-old man with the complaint of body weight loss and diarrhea. The serum levels of carcinoembryonic antigen and carbohydrate antigen 19-9 were slightly elevated to 6.7 ng/mL (reference

value; <5.0 ng/mL) and 45 U/mL (reference value; <37 U/mL), respectively. Enhanced abdominal computed tomography showed a large cystic mass with internal septa in the tail of the pancreas. Enhanced wall and septum of the cyst were observed while the contents of the cyst was not enhanced. Magnetic resonance imaging (MRI) demonstrated a multiple-ball-like lesions of a low-intensity signal on T1-weighted image and high-intensity signal on T2-weighted image. On diffusion-weighted image, MRI showed high-intensity signal in the central part and iso-intensity in the periphery in the cystic lesion. Enhanced MRI with Risovist showed high intensity in the wall and septum of the cysts, and low intensity in the contents of the cysts. Endoscopic ultrasonography showed a cyst with multiple high echoic lesion in the pancreatic tail. Endoscopic retrograde cholangiopancreatography (ERCP) showed a normal main pancreatic duct and no communication between the main pancreatic duct and the cystic lesion. Mucinous cystic neoplasm and branch-duct intraductal papillary mucinous carcinoma were considered. However, MCN was excluded because this was male patient. Additionally, IPMN was excluded as no communication was observed between the main pancreatic duct and the cystic lesion. Distal pancreatectomy with concomitant splenectomy and lymphadenectomy were performed for both, diagnostic and therapeutic purposes. The cut surface of the resected specimen revealed a multilocular cyst with solid nodules. The histopathological findings revealed that the cystic wall was lined by stratified squamous epithelium and many lymph follicles and some sebaceous glands were located in the cystic wall without hair follicles, resulting in the final diagnosis of the pancreatic LEC.

Conclusion: We report a rare case of pancreatic LEC which was difficult to be diagnosed preoperatively and summarize the imaging features of pancreatic cysts.

289

HUGE EXTRAGASTROINTESTINAL STROMAL TUMOR OF THE LESSER OMENTUM: A CASE REPORT

Naoyuki Kawai¹, Atsushi Kubo, Mitsushige Shibatoge², Kyoko Ando, Chisa Aoyama, Yasuyo Yokoi, Noritaka Nakamura, Hidetoshi Kondo, Tetsuo Maruyama, Hideyuki Kita, Hiroaki Onishi¹

¹*Department of clinical center for ultrasonography, Takamatsu Red Cross Hospital, Japan*

²*Department of gastroenterology, Takamatsu Red Cross Hospital, Japan*

Background. Gastro Intestinal Stromal Tumor (GIST) is the

most common mesenchymal tumor of the gastrointestinal tract (GI). GIST that arises primarily outside the GI tract is termed Extragastrointestinal Stromal Tumor (EGIST). To the best of our knowledge, few cases of EGIST of the lesser omentum were reported. Case; A 40 year-old Japanese woman presented to our department with symptoms of early satiety and epigastralgia. Physical examination revealed a mass in the central abdominal space from inferior margin of liver to iliopsoas muscle. The results of laboratory tests including complete blood count, amylase, liver function tests, and all tumor markers were within normal range. Ultrasonography, CT and MRI of her abdomen showed a large mass (maximum diameter 20 cms) that was confined between the left hepatic lobe, the stomach and the retroperitoneum. This tumor had a lot of cystic and blood compartments inside. We preoperatively suspected it is a huge stromal tumor. On exploratory laparotomy, after entering the lesser sac a large solid tumor was found located posterior to the gastric wall and anterior to the pancreas. There was a clear plane of dissection without invasion of either organ and a complete resection of the mass was performed with safety. It was assumed that the tumor originated from tissues of the lesser omentum. Neither metastatic liver lesions nor lymphadenopathy were observed. The postoperative course was uneventful and the patient was discharged after 7 days. The specimen measured 22 cms and weighed 610 grams. Histological examination revealed spindle cells with severe pleomorphism and high mitotic activity (mitotic count of 44 mitoses/50 high-power fields). Immunohistochemically, the tumor cells showed strong positivity for DOG-1 and p16. Immunostains for CD34 and CD117 (c-kit) were partially positive. Immunostains for desmin and SMA were negative. The expression of Ki67 protein was 18%. Considering tumor's size, its morphology and high mitotic index, the estimated risk of recurrence after surgery was high and subsequently the patient was referred to a medical oncologist for further management. Regular dosing of 400 mg imatinib mesylate was initiated. Discussion; EGISTs are extremely rare neoplasms, which account for less than 5% in large series of stromal tumors. Most of them originate from the intestinal mesentery and the omentum but there have been sporadic reports of EGISTs in other sites. It is strongly believed that EGISTs originate from cells, which have similar pathological characteristics and biological behavior as the intestinal cells of Cajal. But our case revealed immunostains for CD34 and CD117 were partially positive. Conclusion; EGISTs are very rare mesenchymal tumors. They originate from cells outside the gastrointestinal tract and tend to have a greater size, higher mitotic index and more aggressive biological behavior than their GI counterparts.

290

INTRA-GASTRIC BALLOON, AN AID FOR WIGHT REDUCTION IN OBESE PATIENT

Nashwan Qahtan Mahgoob

Department of surgery, College of medicine, University of Mosul, Iraq

Aim. Obesity is a medical condition in which excess body fat has accumulated to an extent that it may have an adverse effect on health and regarded is one of the leading preventable causes of death worldwide. Many conservative ways have been used to decrease body weight including diet regime, physical exercise, drugs and balloon insertion into the stomach. More advanced ways including surgical intervention to decrease stomach size or bypass small bowel. This study is to evaluate the safety and possible efficacy of intra gastric balloon for patients with. In this paper, we share our experience with medcell intragastric balloon in treating class one and two obesity: Its safety, tolerability, and its efficacy in weight reduction.

Methods: From January 2015 to January 2017, a total of 85 gastric balloons were inserted on patients at the endoscopy unit in CMC Hospital Erbil/ Iraq. All the patients had a body mass index between 30 to 39 kg/m² and were within the age range of 17-50 with a mean age of 29 years, there were 55 female 30 male patients. After using special criteria for their selection, the patients underwent consent, pre balloon insertion investigation tests and anesthesia evaluation. The balloon was inserted via upper endoscopy device after adequate diagnostic study then it was filled with 550-600 mls of stained saline. All patients' were given an analgesic and antiemetic for a week and antisecretory proton pump inhibitors for 6 months. Diet and the importance of the exercise were part of the program phase and protocol. The balloon was removed after 6 months. The patients were followed during the 6 months of insertion and 12 months after the removal. The weight reduction and complications were documented and reported.

Results: Satisfactory weight loss obtained in 85% of patients after six months of insertion and 78% and 66% after 6 months and 12 months of post removal respectively. One patient underwent early removal of balloon within the first 10 days of insertion; other patient had balloon leak and shrinkage which necessitate replacement of another one. Early post-operative pain and vomiting were universal but subsided in 90% during the first 10 days.

Conclusion: Intra gastric balloon for the treatment of obesity seem to reduce body weight under certain selection.

291

OPTIMAL TREATMENT STRATEGY FOR ACUTE CHOLECYSTITIS – RESULTS OF THE MULTICENTRIC RETROSPECTIVE STUDY

I. Natroshvili¹, M. Prudkov², A. Beburishvili³, A. Bykov³, I. Mikhin³, S. Shapoval'yants⁴, A. Shulutko⁵

¹*Municipal Hospital of Kislovodsk, Kislovodsk, Russia*

²*Ural State Medical Academy, Yekaterinburg, Russia*

³*Volgograd State Medical University, Volgograd, Russia*

⁴*Pirogov Russian National Research Medical University, Moscow, Russia*

⁵*Sechenov University, Moscow, Russia*

Acute cholecystitis (AC) is one of the most common surgical diagnoses in emergency setting. Despite its high incidence there remains a range of treatment approaches. This study aims to determine the best practice for the patients presenting with AC focused on patients characteristics, timing of surgery, disease severity and intra- and postoperative complications. A multicentric retrospective study was conducted and included 754 patients operated for acute cholecystitis at 8 hospitals in 4 cities of Russian Federation (Moscow, Yekaterinburg, Volgograd, Kislovodsk) during 1 year period. The heterogeneity in patient population was high. Mean age was from 53.4 to 65.8 years, ASA 3-4 scores had 19-52% of patients at different hospitals. Median time from symptoms onset to hospitalization varied from 15 to 72 hours, and median time spent at hospitals before operation was 9-71 hours. Choledocholithiasis was found in 1.6-20.9% of patients and its incidence was strongly associated with the use of intraoperative cholangiography. The timing of cholecystectomy is still controversial. We found that optimal time for cholecystectomy is 60 hours from the onset of symptoms in Grade I AC (TG13) and 36 hours for patients with Grade II of the disease. Delay of the operation beyond this time leads to more difficult cholecystectomies and higher complication rates. We compared results of the surgical treatment of AC in 2 groups of patients, operated in median 9 [4; 13] and 50 [29; 88] hours from admission using propensity score matching technique. Rate of Grade I AC in the 1st group was higher (59,8% vs 17,0%, p<0,001) and incidences of gangrenous cholecystitis (15,3% vs 34,1%, p<0,001) and difficult cholecystectomies (28,4% vs 41,5%, p=0,003) were lower. We developed an integral index of complication severity based on Clavien-Dindo and Accordion classifications that takes into account all intra- and post-operative complications and summarizes their respective severity thus allowing to compare outcomes of different procedures. Our study have shown that laparoscopic cholecystectomy was the safest method of treatment considering developed complications for the patients with the severity Grades I and II of AC when the operation, assessed by Cuschieri's scale, was easy. In cases of medium difficulty and difficult cholecystectomies small-incision procedures were safer. The open cholecystectomy should be used only in the

most difficult cases when laparoscopic or small-incision procedures are technically impossible or dangerous. The best treatment for AC is early laparoscopic or small-incision (in more difficult cases) cholecystectomy.

292

HAL-RAR METHOD FOR THE TREATMENT OF CHRONIC HEMORROID - POSSIBILITY OF USE ON AN OUTPATIENT BASIS

I. Nechai, N. Maltzev, E. Afanasjeva, I. Lakashia

SPbGU, Faculty of Graduate Medical Education, Department of coloproctology at the City Hospital No 40, Saint-Petersburg, Russia

Since 2014 we use Doppler-guided Hemorrhoidal Artery Ligation and Recto Anal Repair for the treatment of grade II-III hemorrhoids.

Objective. The purpose of the trial was to evaluate long-term results of HAL-RAR procedure and possibility of its use on an outpatient settings.

Materials and Methods. 65 patients with chronic hemorrhoids, who underwent HAL-RAR procedure, we included. We have a data collected from 63 patients. Surgery was performed with the use of "Angiodin-procto" equipment (Russia). The majority of patients were men - 55 (84,6%) and only 10 (15,3%) women aged 27-77 years old. Average age - 53 y.o. Grade II hemorrhoids was diagnosed in 10,7% of cases (6 patients); grade III - in 92,06% of cases (58 patients); grade IV - in 1,6% of cases (1 patient). Preoperative symptoms were hematochezia and hemorrhoidal prolapse. All the surgeries were performed on an outpatient basis under spinal anaesthesia. Under the Doppler control, the surgeon selectively ligate all hemorrhoidal arteries identified. The next step after dearterelization is mucopexy, which is performed using continuous sutures that include the redounding prolapsing mucosa and submucosa.

Results. All of the patients indicated mild postoperative period. A visual analog scale (VAS) was used to measure pain, and the latter was 4,3 on the first posoperative day and 2,4 on the third day, respectively. The majority of the patients noted easy defecation without hemorrhage or prolapse. Postoperative complications were seen in 5 patients (7,9%). 2 patients (3,2%) developed thrombosis of residual hemorrhoids. 2 patients (3,2%) were diagnosed with posoperative hemorrhage, resolved in the operating room. Acute urinary retention, which required catheterization, was observed in 1 patient (1,5%). Recurrence of the disease was seen in 4 patients (6,3%). All of those patients underwent conventional hemorrhoidectomy of a single node. For the investigation of long-term functional results specifically designed symptom questionnaire was developed, consisting of 9 questions. In total 63 patients filled out the questionnaire. In 58 (89,2%) of them HAL-RAR was performed more than 6 months ago. According to the questionnaire 85,7% of patients were fully

satisfied with the results; 7,9% of patients indicated hemorrhoidal prolapse and periodic gas incontinence. 6,3% noted episodic hematochezia. Blood flow in the anal canal and at the sites of mucopexy was investigated with the use of "Angiodin-procto" equipment and pencil transducer of 8 Mhz, mainly for the objective evaluation of long-term results of the treatment.

Conclusions. Doppler-guided hemorrhoidal artery ligation with rectoanal repair is safe, has low recurrence and complication rates and should be considered as an effective option for the treatment of grade II-III hemorrhoids on an outpatient settings.

293

TEO TECHNOLOGY IN LST AND EARLY STAGES OF RECTAL CANCER

I. Nechai, N. Maltzev

SPbGU, Faculty of Graduate Medical Education, Department of coloproctology at the City Hospital No 40, Saint-Petersburg, Russia

Introduction. Resection of early staged rectal cancer, LST and villous adenomas represents particular difficulties. These lesions can occupy a significant area of the rectal wall and have different level of invasion along the bowel wall. That's why resection of those tumors must be radical with low recurrence and complications rates and good functional results.

Materials and Methods. The trial included 70 patients with histologically proven villous adenomas, LST and adenocarcinomas Tis-T2, who underwent treatment at the department of coloproctology at the City Hospital № 40, Saint-Petersburg, Russia for a period from 2011 till april 2018 and at Pokrovskaya Hospital from 2008 to 2010, respectively. 38 women, 32 men aged 35-86 y.o. were included. Preoperatively, all candidates underwent meticulous investigation, including pelvic MRI or endorectal ultrasound in order to determine the depth of invasion. Neoplasms located in the lower part of ampulla were removed via transanal excision using Lone Star retractor. We used a rigid operating proctoscope Karl Storz and specialized instruments to remove lesions of the middle and upper ampulla under pneumorectum. All patients underwent full-thickness excision and subsequent wound closure with various techniques.

Results. In total 45 adenomas, 25 Tis-T2 staged adenocarcinomas were removed. Complications developed in 3 patients and disease recurrence in 5 patients. Long-term results were evaluated in 51 patients after 12 months post surgery.

Conclusions. TEO technology is an effective and safe method for local excision of large-sized villous adenomas, LST and early staged rectal cancer with low recurrence and complication rates and good functional results.

294

LAPAROSCOPIC EXCISION OF REMNANT GALLBLADDER AFTER SUBTOTAL CHOLECYSTECTOMY

M. Nigmatov, R. Izrailov, A. Belousov

The Loginov Moscow Clinical Scientific Center is State Institution funded by Moscow Health Department (The Loginov MCSC MHD), Russia

Actuality. The gallbladder remnant and the cystic duct stump calculi are uncommon causes of post-cholecystectomy syndrome. Re-exploration is usually needed in the cases where symptom persists. Very few case series and reports are available regarding laparoscopic re-exploration.

The aim. To assess the safety and feasibility of Laparoscopic re-exploration in the cases of gallbladder remnant leading to post-cholecystectomy syndromes.

Materials and methods. In this study, laparoscopic re-explorations was done in 4 patients with gallbladder remnant. The study considered parameters like the operative time, conversion rate, post-operative complications, post-operative hospital stay and mortality in these patients.

Results. The median operating time was 92 minutes (range 60 to 125 minutes). No one patient had conversion to open surgery. There was no major complication requiring further intervention and no mortality. Patients were discharged on median day 6 (range 5-7) after the surgery. Patients were followed up every 3 months for one year.

Conclusion. In expert hands laparoscopic re-exploration of the gallbladder remnant can be done with good result.

295

SIMULTANEOUS OPERATIONS IN A TREATMENT OF PATIENTS WITH CHANGES OF THE PROXIMAL PART OF A HIP COMPLICATED BY THROMBOSIS OF DEEP VEINS

A. Nikolaev, A. Kotayev, V. Zenin, A. Tokarev, I. Nikolsky, V. Alexeyev

FGAOU VO First Moscow State Medical University. THEM. Sechenov of the Russian Ministry of Health (SechenovUniversity). The department of hospital surgery, Moscow, Russia

Relevance. The frequency of deep vein thrombosis after proximal fractures of the hip in early terms after trauma is in the range from 13,7 to 42%. Thromboembolic complications are one of the main causes of the mortality after surgical intervention on proximal part of the hip and make up to 24% of all cases of venous thromboembolic complications with a lethal outcome.

Purpose. Surgical prevention of venous thromboembolism after proximal fracture of the hip complicated with deep

veins thrombosis.

Materials and methods. On the basis of city clinical hospital of S.S. Yudin of the Moscow Department of Healthcare 28 patients with the proximal fracture of the hip complicated with deep vein thrombosis of the lower extremity, from which 15 patients (53,6%) male and 13 patients (46,4%) female were operated. Middle age was 65+11,4 years. The term of trauma has averaged 6+3,3 days. To all patients simultaneous operations are executed: alloying or plication of the superficial femoral vein directly under the mouth of the deep femoral vein and thenosteosynthesis of the proximal femoral pin or endoprosthesis replacement of the coxofemoral joint. During hospitalization patients received heparins in medical doses with the subsequent appointment of new oral anticoagulants (rivaroxaban, dabigatran ethexylate) for not less than 6 months and compression knitwear. The control ultrasonic angioscanning was carried out in hospital discharge, in 1, 3 and 6 months after operation. Results. During the intraoperative period and at the time of hospital discharge episodes of pulmonary embolism (PE) or progressing of thrombosis proximal to the ligation/plication level wasn't detected. One month later occlusion of the superficial femoral vein was observed in 16 cases (57,1%), recanalization up to 50% was noted at 12 patients (42,9%). 3 months later occlusion was revealed at 1 patient (3,6%), restoration of a blood-groove up to 50% at 12 patients (42,9%), restoration of a blood-groove more than 50% at 15 patients (53,5%). 6 months later gleam recanalization of the thrombosed veins was noted at all patients: up to 50% it was defined at 6 patients (21,4%), 18 patients (64,3%) had more than 50% and the full recanalization was noted at 3 patients (10,7%). For the entire period of out-patient observation any case of PE or hemorrhagic complication against the background of intake of oral anticoagulants wasn't revealed. In 1 cases (3,6%) after 3 months occurred the rethrombosis in the background of termination of intake of anticoagulants.

Conclusions. The simultaneous operations proximal fracture of the hip complicated with deep veins thrombosis including ligation/plication of the superficial femoral vein and correction of the bone trauma are effective and safe as prevention of venous thromboembolic complications during intraoperative and postoperative period.

296

EMERGENCY CONDUCT FOR ACUTE HEMORRHAGE OF ESOPHAGEAL VARICES

Felix Valter Nilton, Yogi Ioshiaki, Silva Mateus Felipe Belo, Silva Gabriel Previero Elias, Goncalves Ayrton John Macedo, Dionysio Lucas Monteiro

Nucleus of General and Specialized Surgery, São Paulo, Brazil

Relevance: Terlipressin (triglycyl lysine vasopressin) is a

synthetic analogue of vasopressin, which has been used in the treatment of acute variceal hemorrhage. It can be administered as intermittent injections instead of continuous intravenous infusion with a safer adverse reactions profile.

Object: To determine if bolus injections of terlipressin are safe and improve results in acute esophageal variceal hemorrhage.

Material and Methods: Terlipressin was used in a bolus intravenous injection of 2 mg in 18 patients (all males, 52.16 ± 6.14 years old), known as cirrhotic patients Child Pugh B/C, after an acute esophageal variceal bleeding, being transported to hospital. They were received directly in ICU, where resuscitation was provided, with promotion of blood volume restitution to maintain hemoglobin at around 8 g/dL and plasma expanders to maintain systolic blood pressure bigger than 80 mmHg. Norfloxacin 400 mg twice was initiated immediately. Endoscopic band ligation was performed before 12h. Bolus intravenous injections of 2 mg of terlipressin were maintained each 4 h for the first 48 h, and then continued at a lower dose of 1 mg each 4 h, planned for up to five days.

Results: Seventeen patients had cessation of bleeding after endoscopic procedure. Only one presented a new massive bleeding, uncontrolled despite the use of Sengstaken tube, dying after cardiorespiratory arrest. Fourteen patients were discharged from ICU in four days, two had a prolonged stay due to hepato-renal syndrome and one died later due to cardio-respiratory complications. The use of red blood cells concentrates did not surpass 3.16 ± 0.98 units, excluding the case of new massive bleeding.

Conclusion: The use of bolus intravenous injections of terlipressin in cirrhotic Child Pugh B/C patients having an acute esophageal variceal bleeding seems safe and efficient to reduce blood transfusions and ICU stay.

297

SURGICAL TREATMENT OF ZENKER'S DIVERTICULUM

Felix Valter Nilton, Yogi Ioshiaki, Silva Mateus Felipe Belo, Silva Gabriel Previero Elias, Goncalvez Ayrton John Macedo, Dionysio Lucas Monteiro
Brazil

Relevance: Diverticulectomy, diverticulopexy, with or without myotomy, minimally invasive techniques (such as the transoral endoscopic approach) and myotomy alone are different surgical techniques that have been indicated for the management of Zenker's diverticulum (ZD).

Object: We prefer diverticulectomy with myotomy, and the aim of the study is to verify its real effect on dysphagia.

Material and Methods: We submitted ten consecutive dysphagic patients (eight men and two women, 65.9 ± 6.8 years old in average, classified as ASA II and III, with Zenker's diverticulum at radiological study and no other esophageal dis-

ease at endoscopic exam) to clinical inquiry and manometric studies preoperatively and one year after surgery. Surgical treatment began with left antero-lateral cervicotomy in all cases. We have resected the diverticular pouch, routinely performing esophageal myotomy, 3 cm proximal and 3 cm distal to the diverticular opening, regardless of the manometry findings or the intraoperative aspect of the muscular layer.

Results: No surgical complications were registered. ESE resting pressure dropped from 63.26 ± 8.23 mmHg (preoperative) to 7.87 ± 2.22 mmHg after surgery. Dysphagia was abolished in all patients. Visick score I (complaints resolved) was recorded by 100% of patients.

Conclusion: Diverticulectomy with myotomy seems the mainstream treatment option for ZD, an attitude that we consider good for improving dysphagia, preventing stasis complications and malignant transformation.

298

ECG PARAMETERS PREDICTING LONG-TERM OUTCOMES IN PATIENTS WITH COLORECTAL CANCER

Norihiro Yuasa, Eiji Takeuchi, Hideo Miyake, Hidemasa Nagai, Yuichiro Yoshioka, Kanji Miyata
Department of Surgery, Japanese Red Cross Nagoya First Hospital, Nagoya, Japan

Background. Reportedly, electrocardiogram (ECG) parameters are correlated not only with cardiovascular death but also with all-cause mortality. However, there have been a few studies investigating oncological significance of the ECG parameters. The aim of this study was to analyze the correlation between preoperative ECG parameters and long-term outcome in patients with colorectal cancer (CRC).

Methods. A total of 431 patients who underwent R0-resection for stage II or III CRC were analyzed. We assessed five parameters of preoperative ECG: heart rate, PR interval, QRS duration, QTc interval, LVH. Correlations between relapse-free survival (RFS) and clinicopathological factors (age, sex, tumour location, stage, postoperative chemotherapy (PAC), and ECG parameters) were investigated.

Results. There were 291 patients with stage II CRC and 212 with stage III CRC. Five-year RFS for patients with stage II and III was 85.2% and 61.1%, respectively. In the univariate analysis, RFS was significantly correlated with age, tumour location, stage, PAC, and ECG-LVH. In the multivariate analysis, RFS was significantly correlated with stage, ECG-QRS-duration, and ECG-LVH; QRS-duration and LVH were significant independent factors predicting worse RFS. The QRS duration more than 120 msec was associated with inferior RFS, compared with QRS duration 100-119 msec (HR: 2.19, 95%CI: 1.06-4.21, P=0.034). LVH (+) was associated with inferior RFS compared with LVH (-) (HR: 1.71, 95%CI: 1.03-2.71, P=0.038). RFS of patients with QRS-duration greater than 120 msec and/or LVH (+) were significantly lower than

those with QRS-duration less than 120 msec and LVH (-) in stage III (P=0.0476).

Conclusion. QRS-duration greater than 120 msec and LVH (+) in preoperative ECG were significant independent factors predicting worse RFS in patients with stage II/III CRC who underwent R0-resection.

299

OPTIONS OF LIVER ECHINOCOCCETOMY

S. Novikov, M. Rogal, P. Yartsev, K. Dzhaev, V. Boyarinov

State budgetary health care institution N.V. Sklifosovsky Research Institute of First Aid; Moscow, Russia

The detection of echinococcosis is increasing from year to year, the experience of minimally invasive methods of its surgical treatment is increasing, but at the same time controversial issues in the use of percutaneous interventions for various types of hepatic hydatids are still remaining. To improve the results of surgical treatment for patients with hydatid disease of liver by applying minimally invasive interventions. From 2008 to 2018, 71 patients with hydatid disease of liver were operated at different stages of the parasite's life. Minimally invasive methods of surgical treatment: percutaneous echinococectomy with ultrasound, PAI and PAIR technologies, laparoscopic echinococectomy. Upfront surgery: modified pericystectomy with cold-plasma argon-stimulated electrocoagulation, herni-hepatectomy. 48 (67%) patients were treated with minimally invasive percutaneous interventions under ultrasound. Two-stage surgical treatment, drainage with inactivation of the parasite and further open surgery was performed for 3 (4%) patients; and laparoscopically treatment was performed for 2 (3%) patients. Simultaneously, 19 (26%) were operated upfront. In our research we applied a modernized classification of ultrasound images of hydatid cysts, recommended by the WHO 2010 working party on echinococcosis, based on the classification of H.A. Gharbi (1981). All types of hydatid cysts (CL, CE1, CE2, CE3, CE4, CE5) were subjected to percutaneous interventions, including complicated and multiple ones. Cysts of all types were also subjected to upfront surgery. The results are followed up in periods from 2 to 10 years. Relapses were detected in two cases (4.2%) after percutaneous interventions and were followed up to cyst size of 2 cm and 3 cm and they were inactivated using PAI technology (96% ethyl alcohol). 1). Effective percutaneous interventions are available for all types of hydatid cysts, including complicated and multiple ones. 2). The choice of surgical intervention is based on personalized tactics. 3). After any type of echinococectomy, patients should be followed up for 10 years with ultrasound and CT control, determining the dynamics of IgG titer in the blood for the timely detection of relapse.

300

BARRETT'S ESOPHAGUS: CURRENT STATE OF THE ART

V. Novikov, A. Sandratskaya, E. Yakovleva, L. Vologzhanina

Perm Federal Clinical Center, Perm, Russia

Relevance. Pathological process, accompanied with cylindrical cell metaplasia of esophageal flat epithelium first time described by the English surgeon Norman Rupert Barrett in 1950. European society of gastrointestinal endoscopy (Endoscopic management of Barrett's esophagus: European Society of Gastrointestinal Endoscopy (ESGE) Position status, 2017) defines: Barrett's esophagus – lesion of esophagus, in which on area of more than 1 cm (of uvular form or form of circular segment) there is a replacement of the normal flat epithelium with glandular containing sites of the specialized intestinal epithelium, which is by histologically confirmed.

Object. To Improving treatment outcomes for patients with Barrett's esophagus.

Materials and methods. For the purpose of treatment optimization of patients with Barrett's esophagus depending on clinical and pathogenic features of the process we analyzed results of treatment of 63 patients. In 12 cases visual thickening of metaplastic mucous membrane with a lot of dysplastic foci were revealed, in 13 - moderate dysplastic changes, in 8 - severe dysplasia. Segment of metaplastic epithelium with spots of specialized intestinal sized 1-3 cm were found in 9 patients, 3-10 cm - in 47, more than 10 cm - in 7.

Results. In our opinion, complex treatment of patients with Barrett's esophagus should include following interventions: the fulguration in the air or argon plasma ablation of metaplastic mucous combined with its resection, conservative treatment with proton pump inhibitors during 1-2 month and anti-reflux operation after epithelium regeneration. Interventions are characterized by low traumaticity, short duration of hospital - 1-2 days.

Conclusions. Complex treatment of patients with Barrett's esophagus, in our opinion, should include the following stages of intervention: fulguration in air or argon – plasma ablation of metaplasia in combination with resection of the mucous membrane, conservative treatment with proton pump inhibitors within 1 - 2 months and after regeneration of squamous epithelium – antireflux operation.

301**AN EXPERIENCE OF 500 LIVER TRANSPLANTATIONS IN EMERGENCY SKLIFOSOVSKY INSTITUTE****M. Novruzbekov, K. Lutsyk, V. Guliaev, O. Olisov, R. Achmetshin, S. Juravel, A. Salienko, K. Magomedov, L. Donova, M. Khubutiya***Liver Transplant Center, Emergency Sklifosovsky Institute, Moscow, Russian Federation*

Background. T.E. Starzl first called the liver transplantation (LTx) “an alternative therapeutic approach” for patients with severe liver diseases. For present moment the LTx is a wide-spread procedure to treat these patients.

Purpose. The Moscow municipal Liver transplant program started in 1998 y., the separated department was resuscitated for it. The canine experimental model and morphological practical aspects were practiced. The first LTx performed in September 2000 y.

Materials and methods. 2000 y. – Desember 2017 y. 500 LTx from cadaveric donors were performed for adult pts. Age interval is 17 y. – 71 y. Average – 46.7 y. Sex: 61.8% male, and 38.2% - female. Blood group profile: O(I) 31 %, A(II) 36 %, B(III) 22 %, AB(IV) 11 %. Indications: Liver cirrhosis (LC) following viral hepatitis (VH) without HCC 37%. LC following VH with HCC 17%. LC following autoimmune diseases 17%. Alcoholic LC 7%. Cryptogenic LC 6%. LC Wilson disease 3%. Malignancy without VH 5%. Fulminant hepatic failure 3%. Others 5% (Budd-Chiari syndrome, hydatids, cystic disease).

Results. Early post-OP complications: intraabdominal bleeding 10.6%. Arterial thrombosis 2.6%. Portal thrombosis – 5%. Biliary complications – 10.2%. Severe acute pancreatitis – 1%. Acute renal failure required dialysis methods – 23.3%. Pneumonia – 21.4%. Hydrothorax – 10.2%. Mental disorders – 9.8%. Peripheral neuritis – 2.2%. Cerebrovascular accident – 0.2%. Cardio-vascular disorders – 9.6%. Acute rejection – 6.6%. CMV – 7.4%. Kaplan-Meier survival analysis (n=440): 1 y. – 93%, 3 y. – 87%, 5 y. – 83%, 10 y. – 74%, 15 y. – 65%, 17 y. – 65%. In groups with different pathology survival is variable. There are pts. with 17 y. survival. In one group 16 y. survival is 92%.

Conclusions. Liver transplantation for end-stage liver disease pts. is a correct, perhaps only effective procedure. Liver transplantation passed from unique procedure to routine for most cases. To follow for current guidelines is necessary include the chemotherapy, antiviral therapy administration. And high level survival results achievement is possible. The transplantology advances but graft organ deficiency is spread. The organ donation system developing is very important mission.

302**COMPARISON OF NON-VIRAL AND VIRAL HEPATOCELLULAR CARCINOMA PATIENTS WITH DIABETES****Kaoru Ogawa, Kazunori Nojiri, Masatoshi Mogaki, Hidenobu Masui, Kaoru Nagahori***Yokosuka Kyousai Hospital, Japan*

Object. The number of diabetes patients are increasing all over the world. In Japan the main cause of death for diabetes patients is said to be Hepatocellular carcinoma (HCC), which accounts for 8.6% of the whole number. Besides the progression of medical treatment against viral hepatitis, this number is growing gradually. The object of this study is to analyze the difference of non-viral and viral Hepatocellular carcinoma (HCC) patients with diabetes, clinically and pathologically.

Methods. From 3.2007 to 5.2018, 143 patients with HCC underwent liver resection in our hospital, consisted of 50 diabetes patients and 93 non-diabetes patients. 50 diabetes patients were divided in to further two groups. Non-viral etiology HCC patients (Group A) and Hepatitis B or C virus carrier HCC patients (Group B). Clinical and pathological character, surgical outcomes were compared between the two groups.

Results. The Group A and the Group B were consisted of 27 and 23 patients. From the social background, age, BMI showed no difference, though the ratio of female was larger in the Group A (P=0.046). Analyzing the laboratory data, no difference were seen in liver function. PIVKA was higher in the Group A (P=0.046) but AFP showed no difference. Clinically and pathologically, the group A showed a trend of larger tumor size (P=0.084) and a high ratio of portal vein invasion (P=0.002). Besides these data, post-operative complications and surgical forms did not change. Further more, the Stage, Overall survival rate (OS), Disease free survival rate (DFS) showed no difference either.

Conclusions. The Group A tend to have larger tumor size, and portal vein invasion, accompanied with elevated level of PIVKA. Although, no apparent difference were seen in the long time prognosis such as OS and DFS. Patients who do not have viral hepatitis are not followed up regularly. In other words, these patients may come to the hospital with a severe condition. However, since no apparent poor prognosis were seen between the 2 Groups from this data, liver resection against HCC with diabetes patients is effective.

303

PERCUTANEOUS TRANSHEPATIC BILIARY DRAINAGE PROCEDURES IN THE MANAGEMENT OF PROXIMAL MALIGNANT BILIARY STRICTURES

A. Ogneva, J. Kulesneva

*Loginov Moscow Clinical Scientific Center,
(State Health Institution), Moscow, Russia*

Background. The reasonability of percutaneous transhepatic biliary drainage (PTBD) procedures for proximal malignant biliary strictures as a palliative treatment is still under debate concerning the risk of possible complications, reduced quality of life and short life span.

Study aims. Evaluation of efficiency and rationality of PTBD in preoperative and palliative treatment for proximal malignant biliary strictures.

Materials and methods. Between 2014 and 2017, the records of 323 patients who underwent PTBD in our center due to malignant biliary obstruction were reviewed retrospectively. The causes of biliary obstruction were Klatskin's tumor (n = 135), colorectal metastases (n = 45), metastases of different genesis (n = 68), cholangiocellular carcinoma (n = 30), hepatocellular carcinoma (n = 10), gallbladder cancer (n = 35). The average age was from 25 to 90 years (62 ± 13). The average level of total bilirubin at admission was 6.5 to 806.4 µmol/L (255 ± 177 µmol/L). 247 (76%) underwent palliative PTBD, 79 (24%) underwent preoperative PTBD before hepatectomy. The external-internal prepapillary drainage was performed in 220 (68%) cases, the external-internal tranpapillary in 5 (1.5%), only external in 49 (15%). In the survival assessment study, inoperable patients with Klatskin tumors (n = 40) and colorectal metastases (n = 45) were included. Other patients were excluded due to inadequate statistical sampling.

Results. The technical success rate was 100%. The most common complication was the migration of drainage more often associated with external drainage (60%). The difference between left or right side approach did not reach statistical significance (right-sided - 58% and left-sided - 42%). Acute pancreatitis developed only when the drainage was performed transpapillary (n = 3, 0.9%) or in case of short common biliary and pancreatic ducts (n = 1, 0.3%). Acute cholangitis in case of pre-papillary performed drainage developed only when a contrast agent entered the undrained second-order bile ducts (n = 30, 9%). The number of hemorrhagic complications was 22, in 2 (1.1%) cases laparotomy was required due to intra-abdominal hemorrhage. In the group of patients who underwent chemotherapy due to Klatskin tumor, the median survival was 8 months, the one-year survival rate was 65%, the two-year survival rate was 15%. In the group of patients with Klatskin tumor who did not undergo chemotherapy, the median survival was 6.5 months, the one-year survival rate was 35%, the two-year survival was 15%. In the group of patients with colorectal metastases, everyone received chemotherapy.

Median survival in this group was 8 months, one-year survival rate - 45%, two-year survival - 25%.

Conclusion. PTBD procedures is a method of choice for proximal malignant biliary strictures and can significantly extend life expectancy of unrespectable patients.

304

A NOVEL SCORING SYSTEM COMBINING THE PRE-OPERATIVE CA19-9 AND PROGNOSTIC NUTRITIONAL INDEX ACCURATELY PREDICTS THE PRESENCE OF LYMPH NODE METASTASIS IN PATIENTS WITH INTRADUCTAL PAPILLARY MUCINOUS CARCINOMA

Okamura Yukiyasu¹, Sugiura Teiichi¹, Ito Takaaki¹, Yamamoto Yusuke¹, Ashida Ryo¹, Sasaki Keiko², Uesaka Katsuhiko¹

¹Division of Hepato-Biliary-Pancreatic Surgery, Shizuoka Cancer Center Hospital, Shizuoka, Japan

²Division of Diagnostic Pathology, Shizuoka Cancer Center Hospital, Shizuoka, Japan

Objective. To elucidate the roles of a systemic inflammation response and nutritional status indexes and to identify the prognostic factors of intraductal papillary mucinous carcinoma (IPMC).

Summary background data. The prognostic factors of IPMC may differ from those of conventional pancreatic ductal adenocarcinoma due to differences in the oncological behavior; however, detailed reports on this issue have not been published.

Methods. A pathological examination was performed in accordance with the 2010 World Health Organization criteria. We retrospectively reviewed 66 patients who underwent pancreatectomy to clarify the adverse prognostic factors for the disease-specific survival (DSS) of IPMC. The correlation between the clinical factors and several indexes of a systemic inflammation response and nutritional status was analyzed.

Results. A multivariate analysis showed that the presence of lymph node metastasis (LNM) (hazard ratio 12.0, 95% confidence interval [CI] 1.07–133.6, P = 0.004) was the only significant independent predictor of the DSS. Furthermore, the multivariate analysis showed that a prognostic nutritional index (PNI) <43.5 (odds ratio [OR] 16.1, 95% CI 1.88–138.5, P = 0.011) and a CA19-9 level >22.5 U/mL (OR 6.64, 95% CI 1.73–25.6, P = 0.006) were significant independent predictors of the presence of LNM. Our scoring system developed based on these two factors. Patients with a score of 0 had no LNM and zero disease-related death.

Conclusion. The presence of LNM is an independent prognostic factor, and CA19-9 and PNI are independent predictors of the presence of LNM in IPMC patients who undergo curative pancreatectomy.

305**ESOPHAGECTOMY FOR END-STAGE ACHALASIA****D. Okonskaya, D. Ruchkin***A.V. Vishnevsky Institute of Surgery, Moscow, Russia*

Actuality. Treatment for achalasia of cardia is multidirectional nowadays and depends on several factors such as patient's sex and age, type and stage of disease, co-morbidity and complications. However the treatment for end-stage achalasia is still controversial. Ones who advocate organ preservation surgery consider esophagectomy a last-ditch method. These authors conceive that esophagectomy is too traumatic for benign disease with low progression. Esophagectomy as a first approach for end-stage achalasia is recommended by others authors who believe that progredient course of disease (nonreversible strongly dilated and atonic esophagus), debilitating dysphagia, regurgitation, aspiration syndrome and ineffective intervention in cardia make the extirpation of the esophagus necessary. Persistent degeneration of life quality and high possibility of such devastating symptoms as aspartation and esophageal cancer alongside with unacceptable results of myotomy raise questions on the effectiveness of the organ preservation surgery for end-stage achalasia.

Aim. Examine our own experience of esophagectomies in the management of end-stage achalasia.

Materials and methods. A retrospective analysis of 50 patients with end-stage achalasia who underwent esophagectomy in the A. V. Vishnevsky Institute of surgery from February 2012 till March 2018. There were 27 female (54%) and 23 male (46%) patients ranging in age from 23 to 69 years (average age, 47.2 years). The duration of the symptoms ranged from 1 to 36 years and averaged 13.5 years. Clinical symptoms include dysphagia to solids-50 (100%) and liquids 39 (78%), epigastric and retrosternal chest pain - 27 (54%), regurgitation - 27 (54%), night cough - 17 (34%), weigh loss - 17 (34%), vomiting - 10 (20%). Complications include aspiration pneumonia - 6 (12%), alimentary cachexia (BMI less than 18,5%) - 6 (12%), erosive esophagitis with bleeding - 4 (8%). Thirty one (62%) patients had previously undergone one or more esophageal procedures. Esophageal dilations in 17 (34%), esophagomyotomy with partial fundoplication in 18 (36%), redo myotomy in 3 (6%), esophageal stenting in 3 (6%), injection of botulinum toxin in 2 (4%), bougienage in 1 (2%) of patients. Every patient underwent barium esophagram, multispiral computed tomography, esophagogastroduodenoscopy and therapeutic bronchoscopy if it was necessary. An esophagectomy through a transhiatal approach with forming an isoperistaltic graft from the stomach was performed for all patients.

Results. Excellent or good results were achieved in 43 (86%) of patients. Early postoperative complications developed in 7 (14%) of patients: mediastinal haematoma - 1 (2%); haemothorax - 1 (2%); myoglobinaemia, acute renal failure RIFLE-I - 1 (2%); haematoma of subphrenic space - 1 (2%); cervical anastomotic leak - 1 (2%); eventration - 1 (2%); mesenteric thrombosis - 1 (2%). Three (6%) patients had strictures at the esophagogastric anastomosis, bougie dilation was performed. Mortality was 2%. The reason was an acute thrombosis of the celiac trunk and superior mesenteric artery. This caused total gastric graft necrosis and it's perforation; liver, colon and jejunal necrosis.

Conclusion. Esophagectomy for end-stage achalasia is safe and effective with low level of mortality if case of its performace in dedicated department. Organ preservation surgery is associated with low success rate because of high risk of aspiration pneumonia, erosive esophagitis with bleeding and disease recurrence. Based on the results of this study esophagectomy should be performed for this group of patients.

306**EDUCATION OF SURGICAL RESIDENTS IN BOSNIA AND HERZEGOVINA****Omerović M, Pašić F, Rifatbegović Z, Tursunović A**

Research of surgical resident education in Bosnia and Herzegovina was performed throw 16 hospitalas and it was included 20 residents. The target was to have a real number of operations during the five year education. Than we compared numbers with Plan of education of National regulation protocol for surgical resident's education. The plan says that resident have to provide at least 60% of operations as operator, and about 40% as first assistant. In our research, only 50% of residents was perform their education to the end, and had numbers of operation correct or more, as predicted numbers of operation in National plan. The most common operations in regular surgical program was laparoscopic cholecystectomy and inguinal hernioplasty, and only 35% residents performed predicted number of National plan's operation. The most common operation in emergency protocol was laparoscopic cholecystectomy and appendectomy, and only 10% residents performed predicted number of National plan's operation. Residents performed open surgery rather than laparoscopic in relation about 75%-25%.

307

WARSHAW AND KIMURA TECHNIQUES FOR SPLEEN-PRESERVING DISTAL PANCREATECTOMY: BOTH VIABLE STRATEGIES TO PRESERVE THE SPLEEN! MULTICENTER RETROSPECTIVE COHORT WITH LONG-TERM FOLLOW-UP

Pan Teresa Lucia¹, Paiella Salvatore¹, Korrel Maarten², De Pastena Matteo¹, Besselink Marc², Butturini Giovanni³, Busch Olivier, Esposito Alessandro¹, Giardino Alessandro³, Nessi Chiara¹, Landoni Luca¹, Bassi Claudio¹, Salvia Roberto¹

¹General and Pancreatic Surgery Unit, Pancreas Institute, University of Verona Hospital, Verona Italy; ²Department of Surgery, Cancer Center Amsterdam, Amsterdam UMC, University of Amsterdam, The Netherlands; ³Pancreatic Surgery Unit, Ospedale Pederzoli, Peschiera del Garda, Verona, Italy

Relevance. The Warshaw (WT) and Kimura (KT) techniques are both used for spleen-preserving distal pancreatectomy (SPDP) although some surgeons have concerns about increased rate of complications after WT.

Objective. We aimed to compare short- and long-term post-operative outcomes including quality of life (QoL) after WT and KT.

Methods. Patients who underwent SPDP at three high-volume institutions (2000-2016) were included from prospectively maintained databases. Surviving patients received QLQ-C30 and EQ-5D questionnaires to assess QoL.

Results. In total, 164 patients were included, 55(33.5%) underwent WT and 109 underwent KT(66.5%). Overall mean age was 51(±16) years. Mean operation time was 199(WT) and 225(KT)minutes, respectively ($p < 0.05$). Delayed gastric emptying (DGE) occurred more frequently in the WT group (9.1% vs. 1.8%, $p < 0.05$). No differences were found in terms of other postoperative complications. Mortality was nil. After a mean follow-up of 58 months(±52), 128 patients (78%) with at least 1 postoperative cross-sectional imaging were identified. Eighteen (14%) SPDP-related consequences were found, the most frequently being perigastric varices ($n=11$, 8.5%), although none of them had a clinical impact. No differences in the other long-term complications (splenomegaly, splenic infarction, splenic rupture, need for antiplatelets for thrombocytosis) were found. Most of the event developed within 12 months from surgery. QoL after SPDP was satisfactory, with an overall QLQ-C30 global health status of 75 and an overall EQ-5D VAS of 77.

Conclusions. Both WT and KT are viable techniques for SPDP. In terms of postoperative complications, WT showed a higher rate of DGE. Based on the similar rate of short- and long-term complications and the satisfactory long-term QoL results, SPDP should be recommended whenever possible in benign or low-malignant diseases.

Keywords. Distal pancreatectomy; spleen-preserving distal pancreatectomy; quality of life post-pancreatectomy; post-operative pancreatic fistula.

308

IRREVERSIBLE ELECTROPORATION FOR LOCALLY ADVANCED PANCREATIC CANCER

D. Panchenkov, D. Astakhov, Yu. Ivanov, O. Shablovsky, A. Kedrova, N. Soloviev, A. Nechunayev, A. Zlobin, D. Lebedev

*A.I. Evdokimov Moscow State University of Medicine and Dentistry
Moscow State University of Technology «STANKIN», Russia*

Aim. Locally advanced unresectable pancreatic cancer is characterized by low survival rates in spite of chemotherapy and standard radiation therapy. The aim of this study was to assess overall survival and time to progression in patients with locally advanced pancreatic cancer who underwent irreversible electroporation of the tumor in combination with chemotherapy compared with the standard chemotherapy group.

Materials and methods. This prospective study analysed the overall survival and time to progression of 23 patients who underwent irreversible electroporation of unresectable pancreatic cancer during the period from May 2012 to March 2017 compared with 35 patients with stage III of pancreatic cancer who received standard chemotherapy alone.

Results. All of 23 patients (mean age 61 years, ranging from 45 to 80 years) with locally advanced pancreatic cancer who underwent irreversible electroporation underwent the procedure successfully. Fifteen patients had pancreatic head cancer, 8 had cancer of the body of pancreas. Twenty (86.9%) of the patients received an average of 4 months of chemotherapy before the electroporation procedure. Seventeen (73%) patients underwent chemotherapy after the electroporation procedure. 90 days mortality in the electroporation group was 1 patient (4.3%). When comparing the groups of patients undergoing electroporation with those receiving standard therapy, we noted an improvement in local progression-free survival (12 and 6 months, respectively, $p = 0.01$), and distant progression-free survival (15 and 8 months, respectively, $p = 0.03$). The overall survival was 18 and 11 months, respectively ($p = 0.03$).

Conclusion. The irreversible electroporation of locally advanced pancreatic cancer is safe. Patients who undergo standard induction therapy for at least 4 months can lead to a good local response and potentially improve overall survival compared to the group of patients receiving chemotherapy treatment. The results will be validated in the planned multicenter study.

309**LAPAROSCOPIC POSTOPERATIVE VENTRAL HERNIA REPAIR WITH NANOSTRUCTURED. POLYMERIC MESH****D. Panchenkov, Yu. Ivanov, N. Matveev, P. Kudryavtsev, Yu. Stepanova, N. Soloviev, A. Zlobin, M. Zinovskiy, A. Avdeev***A.I. Evdokimov Moscow State University of Medicine and Dentistry**Moscow State University of Technology «STANKIN», Russia*

The high cost of surgical meshes for intraperitoneal laparoscopic postoperative ventral hernia repair limits __ their use, especially in developing countries. This is the reason for the search of an adequate low-cost alternative. Aim: to estimate the clinical and economic effect of using the low-cost polymer_ mesh_ produced of nanotechnological component, in patients undergoing laparoscopic postoperative ventral hernia repair.

Methods: we have the first experience of treatment of 36 patients with postoperative ventral hernias, who underwent intraperitoneal laparoscopic ventral hernia repair with new low-cost nanostructured polymer mesh with an anti-adhesive cover. All the patients had abdominal adhesions, consequently all the operations have started with adhesiolysis. The technique of mesh implantation and fixation was standard and had no difference from techniques utilized for other meshes implantation.

Results. There were no complications in early postoperative period. The average time of hospital stay was 5,5 days (3-8 days). All the patients were receiving an antibacterial therapy with cephalosporin during 5 days. All the patients underwent US and CT investigation in 3-5 months after the procedure. There were no mesh migrations and recurrent hernias. According to CT scans the mesh integration with abdominal wall has been observed in all cases. The quality of life was estimated according to SF-36 questionnaire. The control group consisted of 78 patients, who had undergone the same procedure using well-known meshes.

Conclusion. The results of the study have shown the same clinical results in both groups with significantly better economic effect in the group with nanostructured polymer low-cost mesh.

310**MULTIFUNCTIONAL OPEN ROBOT-ASSISTED SURGICAL PLATFORM****D. Panchenkov, A. Nechunaev, A. Vorotnikov, D. Klimov, Yu. Poduraev, E. Bazikyan, A. Chunikhin, A. Grin, O. Levchenko, V. Krylov, O. Yanushevich***A.I. Evdokimov Moscow State University of Medicine and Dentistry**Moscow State University of Technology «STANKIN», Russia*

Aim. The creature of multifunctional open sensitive robot-assisted surgical platform. To achieve this aim the following points has been formulated: working-out unique robot-assisted surgical technologies for manipulating in different parts of human body (orofaringeal area, brain, spine, abdomen, pelvis); the design of robot-assisted manual surgical manipulator, semi-mobile hanger with microtransmissions and "store" of removable instruments; elaboration of visual navigation medical system of planning and performing robot-assisted surgery with the elements of augmented reality.

Materials and methods. In basic equipment robot-assisted surgical platform of first generation consists of manual manipulator, semi-mobile hanger, set of removable instruments for different manipulations (high-precision incision, biopsy of objects in the abdominal cavity, installation of supporting systems in vertebrae, intallation of the electrodes in the brain, medullar biopsy), system of navigation and visualization in digital 3D models, based on CT MRT and other medical images.

Conclusion. The created multifunctional robot-assisted surgical platform will allow to increase efficiency and quality of minimally invasive interventions by means of precision steering and hitting into the targeted structures. The manipulator of robot-assisted surgical platform permit to avoid affecting of fuctionally significant zones and keep the precision of effect in variable anatomy, what can become a real breakthrough in robot-assisted surgery.

311**THE 3D MODELING IN ABDOMINAL SURGERY FOR DIAGNOSIS, PLANNING AND SURGICAL TACTICS****D. Panchenkov, A. Kolsanov, Yu. Ivanov, A. Baranov, D. Astakhov, S. Chaplygin, P. Zelter, A. Zlobin, K. Tupikin***A.I. Evdokimov Moscow State University of Medicine and Dentistry**Moscow State University of Technology «STANKIN», Russia*

The aim of the study was to show the possibilities of pre-operative 3D modeling and intraoperative navigation by usage of "Avtoplan" system in HPB surgery.

Materials and methods. We have an experience of treatment of 34 patients who underwent MRSCT with following pre-operative 3D modeling of HPB area. We use the original program of computer modeling with "Avtoplan" system. The stages of 3D modeling were the following: introducing data in DICOM format in "Avtoplan" system; parenchymal organs segmentation; vessels segmentation; receiving volume polygonal 3D model and its analysis; introducing the model into navigation module.

Results and conclusion. The usage of 3D modeling permitted to increase surgical precision and radicalism; to reduce tissue

damaging, blood loss and time of surgery; to have detailed plan of procedure with optimal approach and volume; to improve communication between physicians in multi-discipline cases; to have the possibility of pre-operative "simulated surgery".

312

OUR EXPERIENCE IN ENDOVASCULAR TREATMENT OF PORTAL HYPERTENSION

A. Pankov, N. Zakaryan, A. Shelesko, E. Molokhoev, A. Davtyan, V. Kirakosyan, K. Tadevosyan

Clinical Hospital No 1 of Department of President's Affairs, Moscow, Russian Federation

Objective. One of the complications of liver cirrhosis is the development of portal hypertension syndrome, characterized by increased pressure in the portal vein system. 90% of patients with liver cirrhosis develop varicose veins of the esophagus, stomach and/or intestines. In 30% of cases it is complicated by bleeding. Despite progress in therapy, mortality after the first episode of bleeding from esophageal varices is 30-50%.

Aim. To evaluate the effectiveness and safety of endovascular treatment of portal hypertension and its complications.

Materials and methods. From December 2012 to May 2018 in our hospital endovascular interventions for portal hypertension were performed in 51 patients. The age of patients ranged from 29 to 67 years, men were 32 (62.7%), women – 19 (37.3%). 40 (78.4%) patients has bleeding from varicose esophageal veins in the past (from 1 to 4 episodes), and another 11 (21.6%) the intervention was performed about ascites, refractory to medical therapy. When analyzing the degree of liver failure in Child-Pugh, it was noted that class B was observed in 37 (72.5%), class C – in 7 (27.5) patients. According to esophagogastroduodenoscopy, varicose veins of the esophagus and/or stomach were found in 48 (94.1%) patients. Concomitant splenomegaly was detected in 43 (84.3%) patients. There were performed 32 operations TIPS (transjugular intrahepatic portosystemic shunting), 14 embolization of the splenic artery, 3 percutaneous transhepatic embolization of the veins of the esophagus and stomach, as well as 2 operations BRTO (balloon-assisted retrograde embolization of the veins of the stomach).

Results. In the immediate postoperative period, a serious complication developed in 1 (2%) patient - there is repeated bleeding from the esophageal varicose veins a few days after the intervention with stent occlusion as a result of subacute thrombosis. This patient was performed percutaneous transhepatic embolization of varicose veins of the esophagus and stomach with a good clinical result. Also in 3 (6%) patients there was an increase in the degree of hepatic encephalopathy (due to the presence of a working shunt); this problem has been successfully corrected by diet and

drug therapy. In the long-term period from 6 to 20 months, 33 (64.7%) patients were examined. 3 patients died from repeated bleeding, without waiting for liver transplantation). The remaining 30 patients had no recurrent esophageal bleeding. In 2 (6%) patients a year after the intervention again began to increase ascites. All these 30 patients underwent control Doppler ultrasound of stented segments. According to the it, 28 (93%) stents were patent. In 1 (3.3%) case, critical stent restenosis was detected, which caused a repeated increase of ascites in patient; the patient underwent balloon angioplasty of restenosis with a good result. In 1 patient with occluded stent, it was decided to perform percutaneous embolization of the stomach and esophagus veins. At the time of the examination, 19 (63.3%) of the 30 patients were waiting for liver transplantation, the rest refused transplantation due to the absence of complaints. Liver transplantation was performed only in 4 (13.3%) patients with good clinical results.

Conclusion. Transjugular intrahepatic portosystemic stenting (TIPS) and various methods of embolization of the esophagus and stomach veins are effective and relatively safe methods of treatment of portal hypertension and its complications.

313

INITIAL EXPERIENCE WITH THE FIRST 50 CASES ROBOTIC ASSISTED RECTAL SURGERY – IT IS SOMEWHAT HARDER THAN IT SEEMS AT FIRST GLANCE

Paral Jiri^{1,2}, Dusek Tomas^{1,2}, Örhalmi Julius², Sotona Otakar^{1,2}

¹Faculty of Military Health Sciences, Department of Military Surgery, University of Defence, Trebesska 1575, Hradec Kralove, Czech Republic

²University Hospital Hradec Kralove, Department of Surgery, Sokolska 581, Hradec Kralove, Czech Republic

The aim of poster presentation is to show our initial experiences with the 53 cases of robotic assisted rectal surgery.

Material and methods: Fifty-three patients with rectal or sigmoid cancer underwent robotic assisted procedures in the year 2017/2018 with the use of da Vinci Xi Robotic System (Intuitive Surgical Inc., Sunnyvale, CA)

Results: In total we performed 47 low anterior resections, 2 sigmoidectomy and 4 abdomino-perineal resection. There were 34 males and 19 females. The mean age was 66 (range, 39-81), mean BMI was 28, 2 (min 19, 3, max 39, 1, median 28, 1). The 41 patients underwent preoperative neoadjuvant chemoradiotherapy, 12 patients was indicated for primary resection of rectum. The mean operative time (skin to skin) was 224 ± 47 min for a low anterior resection, 195 ± 43 min for sigmoidectomy and 265 ± 42 min for abdominoperineal resection. There were 3 anastomotic leaks, 2 postoperative hemoperitoneum with necessity of postoperative abdominal revision. Somewhat rare complication was one case of

strangulated inguinal hernia week after robotic surgery. The mean lymph node yield was 21.9 (median 22, min 4, max 51). The resection margin was negative in 46 cases; there was R1 resection in 4 cases and R2 resection in 3 cases.

Conclusion: According to our first experience the robotic surgery brings many advantages in pelvic dissections. Robotic rectal surgery is feasible and safe. One of the major barriers to overcome is the steep learning curve. In order to facilitate safe acquisition of robotic total mesorectal excision skills, surgeons should begin with female patients, sigmoidectomy and less advanced rectal cancer. With growing experience can the robotic surgery brings substantial advantages over traditional laparoscopy, which make the whole procedure more user-friendly.

314

EXTRAANATOMIC ARTERIAL RECONSTRUCTION USING GREAT SAPHENOUS VEIN

Eun-Kyu Park, Yang-Seok Koh

South Korean

Background: Hepatic arterial reconstruction is crucial to successful liver transplantation. With inadequate hepatic arterial inflow, extra-anatomic vascular reconstruction may be challenged. Here the authors report successful jumping graft from hepatic artery to right extra-iliac artery using great saphenous vein.

Method & Results: A 54-year-old man had undergone living-donor liver transplantation for end-stage liver cirrhosis due to hepatitis B with hepatocellular carcinoma. On operation, recipient hepatic artery was found to be thrombosed up to celiac axis and gastroduodenal artery. Several attempt to Fogarty catheterization were not successful. So Gortex jumping grafting in a side-to-end fashion to right external iliac artery was performed eventually which lasting five days. Elevated AST/ALT up to 1600/1526 U/L were noted. Emergent reoperation to replace occluded Gortex graft was performed on 5th postoperative day. Harvesting autologous great saphenous vein was used as a new conduit. The patient was well thereafter and LFT began to decrease to normal range. Seven month after great saphenous vein grafting, favorable arterial flow has been confirmed.

Conclusion: Here we report successful extra-anatomic jumping graft using great saphenous vein. When hepatic arterial anastomosis cannot be achieved, great saphenous vein can be an acceptable alternative for vascular reconstruction in LT.

315

ABO INCOMPATIBLE LIVER TRANSPLANTATION USING PLASMA EXCHANGE AND ANTI-CD20 MONOCLONAL ANTIBODY

Eun-Kyu Park, Yang-Seok Koh

South Korea

Background: ABO incompatible liver transplantation (ABOi LT) has been recommended only for emergency case because of the risk of antibody-mediated rejection (AMR). However, various managements for prevention of AMR have improved the complication rate and survival outcomes. Herein, we introduce our first ABOi LT case although the patient has been into nadir.

Methods: At June 2013, first ABOi LDLT was performed in our center and more six case was done . Our institution protocol for ABOi LDLT was planned using rituximab at pre-operative 2 weeks, several plasma exchanges (PE, target level: isoagglutinin titer \leq 1:8), basiliximab during operation and postoperative 4 day, and routine intravenous immunoglobulin (IVIG) at postoperative 1 to 5 days with splenectomy.

Results: The seven patients were admitted due to liver cirrhosis with viral hepatitis B (HBV) 2 case, viral hepatitis C (HCV) 2 case and alcoholic cirrhosis 3 case. ABO blood type of the recipient was Rh+ O (O+) 5case and Rh+ A (A+) 2 case. All patients received the right lobe of liver from a related young male donor with incompatible blood type. One patient initial isoagglutinin titier were 1:16, two patient initial isoagglutinin titier were 1:32 and others initial isoagglutinin titier were 1:128 . Recipient received rituximab at 2 weeks before LDLT, followed by total 6 times of PE. The recipient received the modified Rt lobe (MRL) transplantation. Only one patient was performed with the splenectomy. First ABOi LDLT patient was a postoperative hemorrhage with coagulopathy and a re-exploration for hemostasis of it and other patients were no other complication. Long term follow up complication, identified only one patient was biliary stenosis.

Conclusions: The new ABOi-LDLT protocol using rituximab, PE, basiliximab, and IVIG is the pivotal and safe strategies. However, the frequent PE for predetermined low ABO titer level is considered to result in the peri- and post-operative hemorrhage following the coagulopathy in our first case.

316

OUTCOME PREDICTION BY 7TH AND 8TH EDITION OF THE AJC TNM STAGING SYSTEM FOR PAPILLARY THYROID CANCER

Jin-Woo Park

Purpose: Clinical implication of minimal extrathyroidal exten-

sion(mETE) in papillary thyroid carcinoma(PTC) has been controversial. Recently AJCC TNM classification was revised to 8th edition. Two major changes were made in age grouping and T3b definition. T3b in new edition refers to a tumor of any size with gross ETE invading only strap muscles. Age cutoff changed from 45 years to 55 years. The aim of present study is to evaluate whether 8th AJCC TNM classification is better than previous version in prognostication in PTC.

Patients and methods: We retrospectively evaluated a total of 239 PTC patients who underwent primary surgery for PTC at our hospital from Jan. 2007 to Dec, 2008. We reviewed medical records and interviewed patients by phone call. We used IBM SPSS Statistics 24 for statistical analysis. Disease free survival (DFS) rate and overall survival(OS) rate were evaluated by Kaplan Meier method.

Results: There were 203 females and 36 males; 235 total thyroidectomy and 4 lobectomy cases; maximum tumor size of 1.3 ± 1.0 cm (131 microscopic PTCs); multiplicity in 80 patients and bilaterality in 44 patients; ETE(+) in 100 patients; lymph node metastasis (+) in 74 patients and Lateral neck dissection in 11patients. Postoperative radioiodine ablation was done in 200 patients. Duration of a median follow-up was 113.4 months (101.9 ± 31.1 months). By 8th edition compared to 7th, TNM stages migrate downward in 81 patients (33.9%); 5 patients from stage II to I; 51 patients from stage III to I; 17 patients from stage III to II; 4 patients from stage IV to I; 1 patients from stage IV to II; 3 patients from stage IV to III. A 10-year disease-free survival (DFS) rate was 97.0% for stage I, 100% for stage II, 97.0% for stage III, and 64.8% for stage IV by 7th edition while that was 96.9% for stage I, 88.9% for stage II, and 66.7% for stage III by 8th edition of the AJCC/TNM staging system, respectively. There were 3 mortality cases, not related with PTC.

Conclusions: Because of limitations in present study including a small sample size, we could not evaluate mortality rates according to different staging systems. Compared to previous edition, however, 8th edition of the AJCC/TNM staging system differentiated more patients who have a low-risk of recurrence (down-staging).

317

NUTRITIONAL SUPPORT AS A COMPONENT OF FAST TRACK SURGERY

I. Pasechnik

Central state medical academy of department of presidential affairs, Russia

Introduction. Nutritional support (NS) is one of the components of the fast recovery program of surgical patients, so-called fast track surgery. The reason why close attention is paid to the problem of NS is that the results of surgical treatment depend on the initial nutritional status of the

patient and on the timeliness and adequacy of delivery of energy and basic nutrients in the postoperative period. Screening the condition of patients at the time of hospitalization shows that nutritional insufficiency occurs in 20-45% surgical patients and in 50-70% of patients with malignant diseases of the gastrointestinal tract. Inadequate NS leads to aggravation of initial disorders, postoperative complications, prolongation of hospitalization, increases the number of readmissions and mortality.

Purpose. To assess the status of the problem and methods of correction of nutritional insufficiency in surgical patients from the standpoint of fast track surgery.

Materials and methods. Analysis of scientific articles, clinical recommendations, the results of their own studies on the implementation of NS in surgical patients in the perioperative period.

Results. Before the surgical treatment, the surgeon and anesthesiologist should assess the nutritional status of the patient, the most convenient for this purpose is the NRS-2002 screening method for nutritional risk, designed by the European Society for Clinical Nutrition and Metabolism (ESCNM) to assess the presence or risk of developing nutritional insufficiency in adults. Three or more points on the NRS-2002 scale are an indication for the NP. The optimal method of NS for preparing patients for surgery is the method of sipping - oral intake of a special formula for enteral nutrition in small sips or through a tube. The appointment of oral supplementary feeding before the operation to patients with nutritional insufficiency decreases the number of postoperative complications. The best results of surgical interventions in patients with cancer of the gastrointestinal tract were obtained by using oral nutritional mixtures enriched with a number of immunomodulating substrates in the preoperative period. Fasting before surgical intervention and operational stress are accompanied by a pronounced metabolic response of the patient's body. In this regard, it is advisable to use a carbohydrate beverage overnight and 2 hours before the planned surgical interventions. In the postoperative period, according to fast track surgery, the early onset of enteral feeding is recommended. The use of immunomodulating nutrient products can reduce the number of infections due to surgical intervention.

Conclusions. It is important to consider NS as a component of fast track surgery, because effective rehabilitation of surgical patients is impossible without it. The NS should be individualized within the framework of the fast track surgery. It is necessary to screen patient's nutritional status and manage it if needed before the surgical treatment. To prevent insulin resistance and catabolism a carbohydrate drink is used before the surgery. In the postoperative period early enteral nutrition should be performed. Implementation of the NS is effective only when taking into account the individual characteristics of the patient and with well-coordinated teamwork of specialists.

318

SURGICAL MANAGEMENT AFTER ILEOCOECAL RESECTION IN CROHN'S DISEASE

A. Paszt, L. Szabó, A. Ottlakán, L. András, S. Ábrahám, Z. Simonka, T. Molnár, G. Lázár

¹University of Szeged, Department of Surgery

²University of Szeged, Department of Anaesthesiology and Intensive Therapy, Hungary

Aims. In this study, we present our experience with redo surgery for recurrent Crohn's disease with small bowel involvement. Short- and long-term results of surgical and gastroenterological therapy were analysed.

Materials and methods. Between 1st January 2005 and 31st December 2016, 23 patients (eleven males and twelve females) were examined at our Department with recurrent Crohn's disease. The mean age was 31,6 years (21-64) at the time of second surgical intervention. Patients underwent complex gastroenterological check-up examinations in our IBD centre. The localization of the disease was the following: jejunum (1/23), terminal ileum (15/23), terminal ileum and colon 25% (7/23). Disease behaviour were rather stenotising (15/23) than fistulising (8/23). In 17 cases colonoscopy was performed prior second surgery with the result of inflammation in 10 cases and chronic stenosis in 7 cases. Redo surgical managements were carried out in 23 cases. Results from surgical, gastroenterological treatments, histopathology reports, the timing of recurrent complaints, the interval between the surgeries and the factors regarding recurrence and the chance of redo surgery were evaluated.

Results. Patients were presented after wide deviation of months with complaints following the first surgery. The average interval between the surgeries was 72,7 months (5-168). In 10 cases, small bowel resection, in 1 case ileo-coecum resection, in 4 cases completion right hemicolectomy, in one case colon resection, in 6 cases multiple resection (small bowel and colon) and in one case stricturoplasty were performed. 13 % of the patients underwent laparoscopic surgery, conversion rate was 57 %. Hand-sewn anastomosis was preferred in 70 % of the cases. We observed inter-intestinal abscess formation in 5 cases. No intraoperative complication was detected without mortality.

Conclusion. The long-term, complex treatment of patients with Crohn's disease requires much experience and its management in IBD centres. The rate of open surgeries is high with the same conversion rate. The second laparoscopic surgery in the treatment of IBD is also effective and safe options with low morbidity and mortality.

319

CHOLANGIOCARCINOMA - SURGICAL AND COMBINED TREATMENT

Yu. Patyutko, A. Polyakov, A. Syiskova, D. Podluzhnyiy, I. Sagaydak, M. Narimanov, I. Pokataev, I. Bazin, M. Magomedov

Federal State Budgetary Institution "N.N. Blokhin National Medical Research Center of Oncology» of the Ministry of Health of the Russian Federation, Moscow, Russian Federation

The aim. To improve the results of surgical and combined treatment of patients with cholangiocarcinoma.

Methods. From 1998 to 2017 a total of 263 patients with bile duct cancer underwent surgery in FSBI "N.N. Blokhin National Medical Research Center of Oncology». A total of 128 liver resections were performed for patients with intrahepatic cholangiocarcinoma, 101 of them were extensive (78.9%) and 27 were economical (21.1%). Resection of extrahepatic bile ducts was performed in 11 patients (8.6%), vascular resection in 6 cases (4.7%), 19 patients underwent resection of other organs (14.8%). All patients with distal bile duct cancer (n=77) underwent pancreaticoduodenal resection, portal vein was resected in 8 patients (10.4%). There were 58 patients with hilar cholangiocarcinoma, the most of them (n=52) underwent liver resection with extrahepatic bile ducts resection. The bile duct resections alone were performed in 6 cases. Portal vein resection was required in 16 patients. Among all patients with extra- and intrahepatic cancer 90 patients received postoperative chemotherapy (34.2%).

Results. The postoperative complications occurred in 172 cases (65.4%), postoperative mortality rate was 7,2% (n=19). Median overall survival was 30 months. Five- and ten-year survival rates were 36.6% and 17.7% respectively. Long-term results were significantly better in R0-resection group than in an R1-R2 group (the median overall survival was 37 months and 20 months respectively, p=0.01). The median overall survival in the group with lymph node metastasis was 26 month, compared with 46 months in the group with negative lymph nodes (p=0.016). Adjuvant chemotherapy improved long-term results in R0 resection group: the median overall survival in a branch with postoperative chemotherapy was 46 month, the median survival in surgery along branch was 30 months (p=0.02), 5-year survival rates were 49.6% and 33% respectively. Multiple lesions (p=0.22) and jaundice (p=0.4) did not show adverse prognostic value in the group of patients with intrahepatic cholangiocarcinoma.

Conclusions. It is important to strive to perform a radical operation with sufficient lymph node dissection and, if necessary, with resection of nearby involved structures. Adjuvant chemotherapy significantly improves long-term outcomes. In case of intrahepatic cholangiocarcinoma, multiple liver lesions and extrahepatic bile ducts involvement are not contraindications to operation.

320

EXPERIENCE OF IRREVERSIBLE ELECTROPORATION OF LOCALLY ADVANCED UNRESECTABLE PANCREATIC CANCER

Yu. Patyutko, A. Polyakov, N. Kudashkin, D. Podluzhnyiy, I. Sagaydak, M. Magomedov, A. Syiskova, I. Pokataev, I. Bazin

Federal State Budgetary Institution "N.N. Blokhin National Medical Research Center of Oncology» of the Ministry of Health of the Russian Federation, Moscow, Russian Federation

Aim. To improve the results of treatment of patients with locally advanced pancreatic cancer

Methods. From February 2015 till February 2017 in FSBI "N.N. Blokhin National Medical Research Center of Oncology» 8 irreversible electroporations of unresectable pancreatic cancers were performed, one of which was combined with palliative gastropancreatoduodenectomy. In one case the procedure was performed twice because of local recurrence. The median tumor size was 35.6 mm (range from 15 to 65 mm). The median quantity of treated areas was 2.6 (1-5). Perioperative treatment was routinely used.

Results. Two patients had complications (28.6%). One died on the 21st day due to the pancreonecrosis. Autopsy showed no evidence of tumor cells in the site of previous electroporation. In the other case several foci of destruction around the area of electroporation were revealed. It required drainage under the endoscopic US-guidance. The median of observation was 13 months. The median of time to progression was 7 months. The median overall survival was not reached.

Conclusion. Irreversible electroporation is the effective local treatment method for the patients with unresectable non-metastatic pancreatic cancer. To increase treatment results it is recommended to combine electroporation with chemoradiotherapy.

Methods. From 1998 to 2017 in FSBI "N.N. Blokhin National Medical Research Center of Oncology» of the Ministry of Health of the Russian Federation 77 pancreatoduodenectomies were performed for patients with distal bile duct cancer. Age ranged from 23 to 79 years with a median of 57 years. Jaundice was presented in 69 patients (89.6%). Preoperative morphological confirmation was obtained in 23.4% (n=18). Portal vein resection was required in 8 patients (11.7%). Regional lymph node involvement was detected in 16 patients (20.8%). Radical operation was performed in 64 patients (83.1%). Pancreaticogastro anastomosis was performed in 41 patients (53.3%), pancreaticojejunum – in 23 patients (29.9%), pancreatojejunum anastomosis – in 8 patients (10.4%). Other variants of anastomosis were performed in 5 cases (6.5%). Single-row hepaticojejunum anastomosis was carried out in all cases. Adjuvant chemotherapy was performed in 31 patients (40.4%), gemcitabine-based regimens were the most common (n=24).

Results. Postoperative complications were revealed in 53 patients (68.8%). The most common complication was postoperative pancreatic fistula – 29.9% (n=23). There was no correlation of the complication rate and the variant of pancreatodigestive anastomosis. Also biliodigestive fistula was found in 12 patients (15.6%), gastrostasis in 11 cases (14.3%). Postoperative mortality rate was 5.2%. Median overall survival was 25 months. Five-year survival rate achieved 33.4%. In the group with lymph node metastasis the median of overall survival was 11 month, compared to 49 months in the group without lymph node involvement (p=0.016). Five-year survival in N0 group was 46%, in N1 group 5-year survival rate was not achieved. The median survival among operated patients who received adjuvant chemotherapy was 41 months, compared with 25 months in the surgical group alone (p=0,6).

Conclusions. Surgical treatment provides good long-term results. Lymph nodes metastases are major negative prognostic factor. Adjuvant chemotherapy improves the results of treatment, but the data are not reliable. Further trials of combined treatment of patients with the distal bile duct cancer are required.

321

SURGICAL AND COMBINED TREATMENT OF PATIENTS WITH COMMON BILE DUCT CANCER

Yu. Patyutko, A. Polyakov, D. Podluzhnyiy, A. Syiskova, I. Sagaydak, M. Narimanov, I. Pokataev, I. Bazin, M. Magomedov

Federal State Budgetary Institution "N.N. Blokhin National Medical Research Center of Oncology» of the Ministry of Health of the Russian Federation, Moscow, Russian Federation

The aim. Improve the results of surgical and combined treatment of patients with distal extrahepatic cholangiocarcinoma.

322

SURGICAL TREATMENT OF PATIENTS WITH STAGE B HEPATOCELLULAR CARCINOMA ACCORDING TO BCLC

Yu. Patyutko, N. Kudashkin, D. Podluznj, A. Poljakov, Z. Dudaev, E. Gluhov

Russian Cancer Research Center named of N.N. Blokhin, Russia

Introduction. Only treatment of choice for patients with intermediate-stage B hepatocellular carcinoma according to BCLC (Barcelona Clinic Liver Cancer) is transarterial chemoembolization of hepatic arteries, with median overall

survival of 20 months. Analysis of literature concludes that implementation of this approach needs rethinking and that treatment of choice for this group of patients should be resection of liver.

Objective. To improve results of treating patients with hepatocellular carcinoma BCLC B.

Materials and methods. 316 cases of patients that underwent surgical treatment for hepatocellular carcinoma from year 1991 to 2018. 302 patients underwent different extents of liver resection. R0 resections were performed in 272 cases (90.1%). 57 patients had stage B according to BCLC. Patients with Child-Pugh class B were dismissed from the analysis, due to the fact that they are not suitable candidates for liver resection. Hepatitis B was diagnosed in 17 (29,8%) cases and Hepatitis C in 6 (10,5%) cases. Major liver resections (>4 segments) performed in 44 (77,2%) cases. Quantity of postoperative complications, lethality and overall long-term survival rates were analyzed.

Results. Frequency of postoperative complications after liver resection 43,9%, lethality 5,3%, 5-year overall survival and mean: 49% and 37 months, respectively. Worth mentioning, that analysis of patients that underwent liver resection with more than 3 hepatocellular carcinoma tumor nodules includes only 3 year overall survival of 40% and mean of 17 months.

Conclusions. Liver resection in patients with BCLC stage B hepatocellular carcinoma can be performed with acceptable levels of postoperative complications and lethality. Implementation of surgical method of treatment significantly improves overall long-term survival rates. Number of hepatocellular carcinoma tumor nodules more than 3 can be viewed as one of the arguments for using transarterial chemoembolization as treatment of choice.

323

CONFORMAL RADIATION THERAPY FOR LOCO-REGIONAL RECURRENCE OF COLORECTAL CANCER

J. Peganova, A. Meshechkin, R. Zhabina

Federal State Budgetary Institution Russian Scientific Center for Radiology and Surgical Technology, SPb, Russia

The incidence of cancer of the rectum is growing steadily. So, every year in Europe, up to 100 thousand newly detected patients with rectal cancer are registered, in the USA about 40 thousand. In the Russian Federation in 2017, registered more than 26 thousand new cases of colorectal cancer, 2 thousand more patients compared with 2013, and mortality in the first year after diagnosis is 23%. The most common cause of unsatisfactory results with the use of surgical treatment of RPC is the occurrence of local recurrences, whose frequency according to different authors is between 5-50% and occurring within the next 2-3 years after surgery. Recurrence of colorectal cancer is the main cause of death.

Evaluation of the effectiveness of conformal radiation therapy in the treatment of locoregional recurrence of colorectal cancer. In the Russian scientific center of radiology and surgical technologies since January 2015. and until April 2018. 15 patients underwent conformal radiation therapy for the region of locoregional recurrence of rectal cancer after surgical treatment (pT2-4bn0M0). in 14 patients a moderately differentiated adenocarcinoma, in one patient a low-grade adenocarcinoma. Treatment was given to 9 men and 6 women aged 50 to 80 years. The median age was 69 years. Operative treatment was performed in the volume of rectal resection (10 patients) or abdominal perineal extirpation (5 patients). The earliest recurrence of the disease was diagnosed one month after the operation, the latest one - in 13 years, on average relapses occurred in 3 years. Conformal radiation therapy was carried out on a linear accelerator 10 MeV through fields of complex configuration in the region of recurrence in the small pelvis in the usual (9 patients) regimens to TFD46-50 Gy or dynamic fractionation (6 patients) to TFD45 Gy (TFDeq56Gr). As a result of treatment, radiation reactions were observed in two patients - radiation cystitis 1-2st(UF) and radiation rectost 1-2st(UF). Of the whole group, one patient died after 10 months after radiotherapy, and the time until the recurrence of the disease was 6 months(DF). Repeated operations were carried out by two patients, in one patient 10 months after radiotherapy(DF), a Hartmann-type operation was performed. In the second patient, 3 years after the treatment we performed(UF), we performed an operation in the volume - revision of the pelvic organs, removal of the formation. In two patients progression is noted, in one patient, a solitary metastasis to the liver was diagnosed 12 months later after radiation therapy(UF), 2 courses of chemotherapy with capecitabine were received and 1 second after 1.5 years after radiotherapy(DF), secondary changes in the lungs were noted and chemotherapy was received. In 10 patients, according to the control study of pelvic organs, stabilization of the disease was noted. Relapse-free survival at DF an average of 9 months, at UF -14 months. Modern methods of conformal radiation therapy are an effective type of treatment.

324

SIMULTANEOUS CHOLECYSTECTOMY: ANYTHING NEW?

D. Perlin, I. Dymkov, V. Zipunnikov, A. Smanev

GBUZ "Volgograd regional urology and nephrology center", Volzhskiy, Russia

Medical statistics point out presence of comorbidities in 20% of patients. Simultaneous operations offer one-stage treatment for several diseases. Laparoscopic technique allows for simultaneous procedures in different abdominal regions avoiding major skin incisions and sometimes requiring

placement of additional working trocars.

Material and method. In 2012-2017, we performed 32 simultaneous operations including cholecystectomy. The surgical intervention was initially aimed to treat diseases of retroperitoneal organs, requiring total or partial nephrectomy; 17 procedures were performed through laparoscopic transperitoneal and 15 through retroperitoneal access. Cholecystectomy was carried out after main procedure. In the group of patients who underwent laparoscopic transperitoneal procedures the mean age equaled 54±3 years, BMI 27±2, hospital stay 9±3 days, duration of surgery 187±10 min., blood loss 100 ±15 cc, narcotic analgesics and duration of peridural anesthesia 1±1 and 2±1 days respectively. In the group of patients who underwent laparoscopic retroperitoneal procedures the mean age equaled 55±2 years, BMI 32±2, hospital stay 10±3 days, duration of surgery 205±12 min, blood loss 110 ±10 cc, narcotic analgesics and duration of peridural anesthesia 0 and 1±1 days respectively. Twelve patients had previously undergone abdominal surgery and were at risk of abdominal adhesions.

Results. Post-operative complications included 2 cases of dynamic ileus following laparoscopic transperitoneal access and one case of retroperitoneal hematoma after a retroperitoneoscopic procedure. All of the complications were resolved without further surgical intervention. Retroperitoneoscopic surgery for the diseases of the kidney has a number of advantages over traditional laparoscopic transperitoneal technique. The working space created artificially in the retroperitoneum has a limited volume resulting in smaller elevation of intra-abdominal pressure and is consequently associated with smaller risk of cardiovascular and respiratory complications. This is especially important for patients with cardiovascular and pulmonary comorbidities. In addition, creation of laparoscopic retroperitoneal access almost completely rules out the possibility of injury to abdominal organs, which is vital for patients who had previously undergone major or repeated abdominal surgery.

Conclusion. Our experience proves safety and efficiency of laparoscopic procedures on kidney or adrenals with simultaneous cholecystectomy through retroperitoneal approach even in patients with abdominal adhesions. There were seen lower complication rate and milder post-operative.

325

EXTENDED OPERATIONS (MULTI ORGAN RESECTIONS) FOR EXTENDED COLON CANCERS

Christian Petkov

First Surgical Department, Fifth General Hospital, Sofia, Bulgaria

The standard colorectal surgery is for standard sized colorectal cancers. In modern series the colorectal cancers under interest and discussion in regard to management and

surgery are either the very big cancers that spread to the adjacent organs; or the very small cancers that are confined to the mucosa and submucosa. The lecture regards the very big colon cancers- the extended colon cancers - these are ones that extend and infiltrate the adjacent organs. What are the most common localizations of extend colon cancers? And the extended colon cancers might be grouped as commonly extended and far extended, involving a long list of organs. What are the common and the rare patterns of extended growth of these tumors – how many organs might be involved? And what are the common and the rare patterns of extended surgery for these extended colon cancers – how many organs might be included in the multi organ resection? What is the complex therapy for the extended colon cancers?

326

COMPLICATIONS AFTER EXENTERATIVE PELVIC SURGERY

Petkov Christian¹, Zarkov Kostadin¹, Grancharova Silvia², Bekir Sabrie¹, Assenov Assen¹, Mochurova Maya¹, Velinov Peter¹; Yusef Hani¹; Penev Lubomir¹

¹First Surgical Department, Fifth General Hospital, Sofia, Bulgaria

²Clinique of Abdominal Surgery. Military Medical Academy, Sofia, Bulgaria

Background. Pelvic exenterations (PE) are prominent with complications that widely range from 23% to 78% in different authors.

Aims. We assess the postoperative complications of our patients with extended abdominal and pelvic surgery - related to urinary and gastrointestinal system and pelvic floor. Measures to avoid complications. Management of complications. Survival.

Methods. This is a retrospective analysis of 181 patients with advanced pelvic malignancies, comparing two periods 2004-2009 (Ist group) and 2010-2014 (IInd group). For the 181 advanced primary or relapse rectal, urological and genital carcinomas we performed pelvic exenterations (PE) – 57 total, 69 posterior, 47 anterior; 8 median. We compare complications and survival for 122 radical, 59 palliative PE and 47 palliation.

Results. Complications after PE – are early and late - and might be classified for Ist/IInd group as: Urinary – 48%/38% (pyelonephritis – 30%/ 24%, pyonephrosis – 1%/ 1%; hydronephrosis – 3%/ 2%, necrosis of distal ureter forming urostomy – 4%/ 2%; ureteral stricture – 10%/ 8%); Gastrointestinal – 18%/ 14% (ileus – 2%/ 1%, radiation colitis – 1%, stercoral fistula - 10%/ 7%, rectal anastomosis leakage - 4%/ 3%); Pelvic floor – 65%/ 26% (pelvic cavity infection – 63%/ 24% - discharge about 65 days, leakage of implanted pelvic mesh – 2% / 0%). Postoperative mortality –

6%. Conservative treatment resolves 80-84% of the complications. Operative treatment comprises: percutaneous nephrostomy – 3%, ureterostomy reinsertion – 4%, nephrectomy – 1%, colostomy correction – 1%, bowel suture 1% or resection 2%, transversostomy - 4%, re-repair of pelvic floor 2%. Survival: Radical PE: 12 months – 59; 18 months – 41; 2 years – 39; 5 years – 27 patients. Palliative PE – 18 months. Palliations – 6 months. For T4 colorectal cancers: 3-years – 78%; 5-years – 45%.

Discussion. The most common complications in the 1st group are pelvic cavity infection and in the 2nd group - Urinary infection. In the second period the complications level is significantly decreased (urinary; GI and pelvic floor complications) and 5-years survival survival rates are significantly increased - from 16,5% to 22%.

Conclusions. Despite extended and exenterative surgery has high morbidity, it increases survival, being only radical treatment of extended tumors. Complications are factor determining survival. Knowing complications contributes to avoid them.

327

EFFICIENCY OF MINIINVASIVE TREATMENT OF PATIENTS WITH ESOPHAGEAL VARICES BLEEDING

V. Petrushenko, D. Grebeniuk, Ia. Radoga, V. Koval, M. Melnychuk, S. Khytruk

National Pirogov Memorial Medical University, Vinnytsya, Ukraine, Department of Endoscopic and Cardiovascular Surgery, Ukraine

Introduction. Acute variceal bleeding could be a fatal complication in patients with liver cirrhosis. Therefore, timely endoscopic hemostasis and prevention of relapse of bleeding are most important.

Aim of the work. The aim of our study was to decrease of mortality rates and improve the outcome of treatment in patients with esophageal varices bleeding.

Methods. The study is based on the prospective analysis of treatment results of 242 patients with esophageal varices bleeding, who were on inpatient treatment in the Vinnitsa regional center of the gastrointestinal bleeding in 2014–2018. Total number of men – 137 (56.61%), women – 105 (43.39%). The average age of patients was 56,8±3,6 years. The source of bleeding was established during endoscopy. All patients received drug therapy – hemostatic, antisecretory, infusion, symptomatic. In 2014–2016 patients (group 1, n=195) received just drug therapy. From the second half of 2016 we began to perform minimally invasive endoscopic surgical interventions such as ligation of bleeding esophageal varices (group 2, n=47). After endoscopic band ligation reliable hemostasis was achieved in all cases. According to protocol and in the absence of contraindications to decrease portal pressure all patients received non-selective

beta-blockers. Subsequently, to reduce portal hypertension and on purpose to prevent new varices emergence the splenic artery embolization was performed.

Results. In group 1 total number of men was 105 (53.8%), women – 90 (46.2%). The average age of patients was 56.0±4.2 years. Using just drug therapy we have stopped bleeding in 152 (77.95%) cases. In all cases at the end of treatment we received improvement of clinical and laboratory indices. 43 patients (22.05%) were died. Duration of treatment was 10.2±2.1 days. In group 2 total number of men was 32 (68.09%), women – 15 (31.91%). The average age of patients was 55.1±5.4 years. Performing of endoscopic band ligation and splenic artery embolization we have stopped bleeding in 41 (87.23%) cases. In all cases at the end of treatment we received improvement of clinical and laboratory indices. 6 patients (12.77%) were died. Duration of treatment was 6.4±2.8 days.

Conclusion. Under the condition of esophageal varices bleeding treatment by performing of combination of endoscopic band ligation and splenic artery embolization in comparison with drug therapy we can see the improvement of patient's condition, decreasing of mortality and duration of treatment.

328

THE ROLE OF THE GENETIC BACKGROUND IN THE SEVERITY OF ACUTE PANCREATITIS

V. Petrushenko, D. Grebeniuk, A. Levanchuk, N. Liakhovchenko, K. Pankiv

National Pirogov Memorial Medical University, Vinnytsya, Ukraine, Department of Endoscopic and Cardiovascular Surgery, Ukraine

Introduction. Acute pancreatitis continues to be an actual problem both in surgery and in intensive medicine. Progress made in identifying the genetic susceptibility underlying acute pancreatitis could benefit the clinicians in understanding the pathogenesis of the disease in a better way. The PRSS1 gene provides instructions for making an enzyme – cationic trypsinogen. Cytogenetic location: 7q34, which is the long (q) arm of chromosome 7 at position 34. Molecular location: base pairs 142,740,235 to 142,753,076 on chromosome 7 (Homo sapiens Annotation Release 108, GRCh38.p7).

Aim of the work. The aim of our study was to determine the effect of mutation in the cationic trypsinogen gene (PRSS1) on the severity of acute pancreatitis.

Methods. The study included 54 patients with confirmed diagnosis of necrotising pancreatitis (n=34; 62.9%) and interstitial oedematous pancreatitis (n=20; 37.1%). The mean age in the investigated contingent was 41.8 ± 12.9 years. Genomic DNA was extracted from peripheral blood mononuclear cells using the GeneJet Whole Blood Genomic DNA Purification Mini Kit (ThermoScientific, USA). For

identification of Arg122His polymorphic alleles of the PRSS1 gene amplification of the corresponding gene site on the iCycler IQ5 device (BioRad, USA) was performed. Amplification mode: 93°C, 1 min; 35 cycles: 93°C, 10 seconds; 64°C, 10 seconds; 72°C, 20 seconds.

Results. Polymorphic allele Arg122His of the PRSS1 gene was detected in 46.3% of patients with necrotising pancreatitis. There was a strong statistically significant association between the mutation in the PRSS1 gene and the formation of pancreatic necrosis ($r=0.651$). The chance of pancreatic necrosis in patients with mutations in the PRSS1 gene was 11.11 times higher than in patients without this mutation [95%, 2.93-42.2]. The relative risk indicator demonstrated that there was a direct relationship between the mutation of the PRSS1 gene and the pancreatic necrosis. In patients with mutation in the PRSS1 gene, the pancreatic necrosis was observed 2.4 times more often than without it [95%, 1.4-4.12].

Conclusion. The presence of mutation in the gene of cationic trypsinogen (PRSS1) significantly increases the risk of severe forms of acute pancreatitis.

329

THORACOSCOPIC TRANSDIAPHRAGMAL ACCESS FOR UPPER-POSTERIOR SEGMENTS OF SOLITARY LIVER METASTASIS

D. Podluzhny, E. Glukhov, M. Davydov, A. Allakhverdiev, Z. Dudaev

FSBI "N.N. Blokhin National Medical Oncology Research Center" Ministry of Health of Russia

Introduction. Introduction of new access in surgery of upper-posterior segments for solitary liver metastasis. Evaluation of the necessity of application of thoracoscopic transdiaphragmatic access with solitary metastases of the upper-posterior segments of the liver.

Materials and methods. In 2017, the technique was applied in two patients who underwent resection of segment VIII of liver, one of them for solitary metastasis of laryngeal cancer, the other – solitary metastasis of colorectal cancer, 3 cm in size. Patient is positioned on the left side, a video telescope is installed in VI intercostal space of middle armpit line, working thoracoport is installed in the VI intercostal space at the anterior axillary line in the seventh and eighth intercostal space along the back axillary line. The right pulmonary ligament is dissected. The diaphragm is cut by the Harmonic device. Step by step, according to the planned line of resection, the intersection of the liver parenchyma is performed, the vessels and bile ducts are subject to clipping. Resection of the VIII segment of liver is performed. The abdominal cavity is drained by silicone tube installed in resected area of liver under control of videothoracoscopy and taken through counterincision in the right hypochondrium. The defect of

the diaphragm is sutured. Right pleural sinus is drained by silicone tube and taken through counterincision. Port aperture is sutured.

Results. The duration of the operation in 1 case was 125 minutes, in the second – 140 minutes. Intraoperative blood loss in 1 case-1900 ml, in the second – 850 ml. Postoperative complications were not observed. The length of stay of patients in hospital after surgery-5 days.

Conclusions. Based on our experience in the application of this technique of operating on patients with tumor localization of no more than 3 cm in the upper-posterior segments of liver, we see advantages compared to open surgery.

330

EXTENSIVE LIVER RESECTION IN TERMS OF INTRA-OPERATIVE INFUSION CONTRAST OF THE BILE DUCTS

E. Podolskiy, V. Shutov, I. Minaev, A. Marikyan, D. Shkurin, A. Kukhta

Federal State-Funded Budgetary Public Health Facility

«West-Siberian Medical Center of FMBA of Russia», Omsk city

Relevance. At performance of extensive resections of a liver a considerable quantity of biliary complications remains. Purposes of research. To study the frequency and severity of bile leakage after extensive liver resection in the postoperative period. To find the optimal way of preventing bile leakage.

Material and methods. For the period since 2006 to 2017 183 extensive liver resections (ELR) were performed. There were 92(53%) women and 81(47%) men. Average age of patients was 49 ± 13.9 years old. Exclusionary criteria from the study were emergency and simultaneous surgical interventions, surgeries with angioplasty and biliary ducts reconstruction. As a result, 122 patients were selected for the analysis; all of them were divided into 4 groups. In the first group ($n=32$), infusion contrast of bile ducts (ICBD) was performed. The essence of the method consisted in putting a thin catheter into the choledoch through the stump of the cystic duct and constant infusion of the original coloring solution into the bile duct system throughout the entire liver resection. In the 2 group ($n=31$) "White test" was performed. In the 3 group ($n=29$) external drainage of the bile ducts was performed proactively. In the 4 group ($n=30$, control) there was no prophylaxis at all. Assessment was conducted according to the classifications Nagano 2003 and ISGLS. For data processing program Statistica 8.0 was used. The minimum number of patients allowed for the study was calculated by the formula Lopez-Jimenez. Reliability was assessed using Students test with accurate Yates correction, Manna-Whitney criterion.

Results. In group 1 only single bile leakage of D type was

recorded, which stopped independently after 7 days. In group 2, 4 cases of bile leakage (2–A type, 2–B type) were noted. The average duration of bile leakage was 20 ± 9.4 days. In group 3 there were 6 cases of bile leakage (3–A type, 2–B type, 1–D type). The average duration of bile leak was 19.6 ± 8.6 days. In group 4 there were 9 cases (1–C type, 1–D type, 4–B type, 3–A type). The average duration of bile leakage was 34.9 ± 14.3 days. There were no differences in the duration and severity of bile leakage between 2, 3, 4 groups ($p=0.256$, $\chi^2=2.62$). In group 1 there were significantly less cases of bile leakage in the postoperative period ($p=0.0057$). The test-sensitivity of the ICBD method was 96%, WT-87%.

Conclusions. ICBD lets significantly reduce the frequency of bile leakage after ELR which offers the possibility of using this method for the prevention of bile leakage in the postoperative period. WT reduces the frequency and severity of bile leakage, but is not reliable – a significantly larger sample of patients is required. External drainage of the bile ducts does not affect the number of bile leakage in the postoperative period.

331

PUNCTURE DRAINAGE AND SCLEROSING UNDER ULTRASOUND-CONTROL AS AN EFFECTIVE AND SAFE TREATMENT MODE OF LARGE-SIZED NONPARASITIC HEPATIC CYSTS

E. Podolskiy, V. Shutov, A. Marikian, D. Shkurin, A. Kukhta, I. Minaev, T. Krivonogova
Federal State-Funded Budgetary Public Health Facility «West-Siberian Medical Center of FMBA of Russia», Omsk city

Relevance. Despite certain successes, there are not resolved questions in treatment nonparasitic hepatic cyst of the big size.

Purposes of research. To optimize management of patients with large-sized nonparasitic hepatic cysts.

Material and methods. Since 2006 to 2017, 224(83.6%) women and 44(16.4%) men with large-sized nonparasitic hepatic cysts with a diameter greater than 50 mm were treated. 165(61.6%) patients underwent puncture drainage and sclerosis of hepatic cysts under ultrasound control, 81(30.2%) – laparoscopic resections and cyst fenestrations. In 22(8.2%) cases traditional hepatic resections were performed in anatomical or atypical variants. In 9 cases there were rehospitalizations: 6 cases after puncture treatment, and 3 cases after laparoscopic resection (fenestration). All cases of recurrence were treated by the puncture method. The main method of diagnosis was ultrasound of the abdominal cavity. Criteria for selecting patients for puncture treatment of nonparasitic cysts were: age of the patient, severe concomitant pathology, relapse of cysts after laparo-

scopic resection, relapse after puncture treatment, adhesive process of the abdominal cavity, exclusion of parasitic process. For installation of a drainage catheter, a device for drainage of cavity formations DDCF-1 with a direct catheter 12Ch or a set of a needle-catheter with a catheter 9Ch of the "Pigtail" type was used. Percutaneous puncture interventions were carried out under the control of the "Pro Focus UltraView" apparatus. After removing of the cystic fluid, the centesis was terminated by the administration of a sclerosing drug. As a sclerosant 96% ethanol introduced in the volume of $\frac{1}{4}$ of the amount of the removed liquid with exposure up to 60 minutes was used. In individual cases prolonged and repeated "sclerosing" therapy was required. Indications for the removal of the drainage catheter were: no more than 10 ml of drainage for two days, ultrasound data (complete absence of a liquid component, or a minimum volume (up to 20%) of the residual cavity of the cyst).

Results. There were no postoperative complications. The average length of stay (bed-days) in the hospital was 5.6 ± 1.5 , versus 11.8 ± 1.8 for laparoscopic operations and 15.7 ± 3.1 for traditional resections (the differences are reliable). There was a short (up to 3 min.) pain syndrome during drainage, and unpleasant sensations in the right supraclavicular area with the introduction of sclerosant (up to 5 min.). All manipulations were supported by the introduction of non-narcotic analgesics before manipulation and prolongation of analgesic therapy for 2-3 days. Patients were discharged from the hospital immediately after removal of the catheter with mandatory ultrasound monitoring in 3 months. Through a single intervention a full recovery was achieved in 74% of patients.

Conclusions. The use of puncture drainage and sclerotherapy under ultrasound control is the method of choice at intraparenchymal location of hepatic cysts with aged patients with severe concomitant pathology, when other types of treatment are not feasible. The effectiveness, safety and absence of complications of puncture drainage and sclerosis is an alternative to surgery. The method is economically advantageous, since it leads to a reduction of the duration of the patient's stay in the hospital with a minimum cost of medicines and consumables.

332

INGUINAL ENDOHERNIOPLASTY: SIZE MATTERS

A. Polyakov, I. Mikhin, O. Kosivtsov, L. Ryaskov
The Volgograd State Medical University, Volgograd, Russia

Laparoscopic plasty of inguinal hernias appeared more than 25 years ago. It is known, that the concept of back access for inguinal hernioplasty is the most pathogenetically justified. Endosurgery combines the basic principles of herniology today: "tension-free" technology, due to the use of a mesh and a back access, which is fundamentally the only one,

differing only in the way of "organization" of the preperitoneal space (transabdominal or extraperitoneal). The aim of our study is to improve the results of treatment of patients with inguinal hernia. Since 2015, we performed 180 endoscopic inguinal hernioplasty with transabdominal 144 (80%) and extraperitoneally 36 (20%) operations in 143 patients. The age of the patients was between 18 and 90 years. There were 37 (25.9%) bilateral inguinal hernias: 15 - bilateral direct, 11 - bilateral oblique, 5 - bilateral combined, 4 - pantaloon and oblique, 2 - pantaloon and direct. Occult hernias were found in 2 (1.4%) patients during surgery: in 1 case, femoral and contralateral oblique and in the other obturator hernias. There were 134 men (93.7%) and 9 (6.3%) women. The feature of our interventions, besides of lateral dissection, is the accurate separation of Retzius space, including foramen obturatum, and the application of 15x12cm a minimum size of a mesh implant. We would like to note that the parietalization of the lower peritoneal flap is not used to place the implant as low as possible, but to exclude its rolling when the "technical" opening of the peritoneum is closed, with the mesh is placed in the middle of the existing abdominal wall defect, both vertically and horizontally, thus with direct hernias, its positioning of the implant is more medial. The dimension of the mesh prosthesis are fundamental for the prevention of recurrence of hernias. In order to reduce the pressure per square centimeter, in cases of combined, recurrent, bilateral hernias, the minimum implant size is 17x13cm, and for defects more than 3.5-4cm (M3, L3) we use prolene grille suture, superimposed on the edges of the defect, thereby observing the non-stretching principle of hernioplasty. The maximum size of the implant we installed was 20x15 cm in a 87-year-old patient with a giant pantaloon hernia, without increasing the fixation points. At the same time, the mesh was fixed at 3 points, as with a small hernia. The positioning of the mesh with a herniostepler is performed according to the reduced scheme with the maximum amount of fixation in 3 points along the medial-upper contour. The patients were activated in the first hours after the operation, they were all ready for discharge on the next day. There were no lethal outcomes, early relapses, chronic pain syndrome. We suggest that prosthesis for endo-laparoscopic hernia repair with an initial size of 12x15 sm should be used to ensure adequate coverage of the hernia defect and a subsequent increase of the overlapping area depending on the extent of the muscular aponeurotic system defect, with the implant stabilized and integrated into the abdominal wall using grille polypropylene sutures and without increasing the number of invasive fixation points, thus preventing the development of chronic pain syndrome.

333

LIVER TRANSPLANTATION FOR UNRESECTABLE HEPATOCELLULAR CARCINOMA IN A NORMAL LIVER

I. Porshennikov

*State Novosibirsk Regional Clinical Hospital,
Novosibirsk, Russian Federation*

Background. Hepatocellular carcinoma in a normal liver (HCC-NL) without cirrhosis and viral infections is a rare malignancy. The incidence of HCC-NL is between 10-12% of cases. HCC-NL may result from androgens or estrogens use and from malignant transformation of hepatocellular adenoma. Probably, hepatocellular carcinoma in cirrhotic liver and HCC-NL are different tumors because they have different etiology and pathogenesis. Therefore, criteria such as Milan, UCSF, BCLC staging system are not applicable for this malignancy. The number of publications related to liver transplantation (LTx) for HCC-NL is very small. The aim of this investigation was to present our experience of LTx for HCC-NL.

Methods. The retrospective study included 4 patients primary transplanted for HCC-NL during the period May 2014 to December 2016. There were 3 men and 1 women. The mean age was 43±17,9 years (from 26 to 63 years, median 42). The mean alpha-fetoprotein level was 161±175,1 ng/mL (from 5 to 400 ng/mL, median 120). The mean tumor size was 22±4,2 cm (from 16 to 26 cm, median 23). TNM staging was T4T0M0 (AJCC 8 ed.) in 3 cases and T1N0M0 in 1 case. The preoperative diagnosis was based on contrast-enhanced computed tomography and magnetic resonance imaging. Preoperative needle tumor biopsy was needed in 2 patients and was avoided in 2 other patients due to risk of tumor cells seeding. The final decision of LTx possibility was taken intraoperatively after frozen section of lymph nodes. LTx from deceased donor was performed in 3 cases (classical technique – 2 and piggy back – 1), living donor LTx with inferior vena cava replacement in 1 case. We did not use any bridging or downstaging therapy in this series. Immunosuppression in all recipients was based on everolimus, 2 of them received adjuvant therapy with sorafenib.

Results. In-hospital mortality was absent. There were no vascular and biliary complications. Macrovascular invasion was identified in 3 cases. Follow-up: 1) the first patient died after 6 months because of sepsis, at autopsy revealed no progression of the tumor; 2) the second patient 45 months following LTx alive without tumor; 3) the third patient developed recurrence 6 months and died 13 months after LTx; 4) the fourth patient 20 months following LTx alive without tumor.

Conclusion. Liver resection is the treatment of choice for HCC-NL. LTx may be considered as a treatment option for unresectable HCC-NL, especially because many of these patients are young and healthy individuals.

334

OPTIMIZATION OF LAPAROSCOPIC ACCESSES FOR REDUCTION OF POSTOPERATIVE WOUND COMPLICATIONS

E. Prazdnikov¹, G. Baranov², T. Bahmetov¹

¹*A.I. Yevdokimov MSUMD, Moscow, Russian Federation*

²*City Clinical Hospital named after the brothers Bakhrushin, Moscow, Russian Federation*

Purpose of the study. To identify surgical accesses for laparoscopic cholecystectomy which are associated with less risk of postoperative wound complications.

Materials and methods. The performed analysis of 180 clinical cases of the wound healing process after laparoscopic cholecystectomy showed that there are certain areas on the abdominal wall which are safer in terms of the development of complications. The anatomical features of epigastric and paraumbilical regions which are most commonly used for trocar accesses differ. One of the significant differences is the density of lymphatic vessels in these anatomical zones. Infiltrates and suppuration, and subsequently postoperative hernias are more often observed in paraumbilical region.

Results and discussion. Analysis of infectious complications in the field of surgical interventions showed that suppuration occurred in 11.7% patients (n=11) who underwent perianopic access for laparoscopic cholecystectomy in a container (total 94 patients), and only in 4,7% patients (n=4) after epigastric laparoscopic accesses (total 86 patients).

Conclusion. The epigastric region is anatomically more preferable for laparoscopic surgical access in terms of lower risk of postoperative wound complications.

335

COMPREHENSIVE TREATMENT OF PATIENTS WITH BARRETT'S ESOPHAGUS

N. Prikhno, A. Ostrovskaya

Panacea Clinic, Moscow, Russia

10-14% patient with gastro-esophageal reflux (GER) develop BE – complications, when only long lasting treatment with proton pump inhibitors (PPI), special diet and healthy life style may provide the patient with the hope to avoid an increased risk of esophageal adenocarcinoma development. We have 20 years treatment's experience with more than 1500 patients with GER, 5% of whom have diagnosed with BE. A standard treatment protocol with PPI and gastro-intestinal motility prokinetics has got a limited effect. The main question is the choice of an alternative possibility of intestinal metaplasia treatment besides the surgery. Searching for clinically effective treatment for patients with gastric and

intestinal metaplasia of the esophagus, the following factors were taken into account: PPI is a highly effective medication for therapy of various forms of GER. An 8-week PPI-use leads to restoration of the gap between cells in 85% of GER-patients. A long-lasting PPI-therapy (Pariet® (Rabeprazole) 20mg) reduces the risk of esophageal adenocarcinoma. However PPI-monotherapy has a variety of specific effects on pathophysiological mechanism and an insufficient control of acid production may occur. Prokinetics use does not change the esophageal motility and does not decrease the bile reflux intensity. Rebamipid (REBAGIT) demonstrates a cytoprotective and prosta-glandinsynthetic activity, which improves the blood microcirculation and regeneration of cells. The possible effects of Rebagit- are: 1) pre-epithelial protection, which includes the products of salivary glands and esophageal submucosal lining secretion (mucin, nonmucin protein, bicarbonates; prostaglandin T-2; epidermal growth factor); 2) Epithelial esophageal protection – normalization of the esophageal mucousal membrane regeneration; 3) post epithelial protection; Nine male patients with an average age of 34.2 y.o. took Rebagit 100 mg 3 times daily during 2 months with a 2 month break, 50 mg of ITOPRID hydrochloride before night continuously, and 20 mg of Pariet per day. One of the patients (23 years of age), has no endoscopic signs of BE after 3.5 years of treatment. Other patients, who have been taking a complex of 3 medications during the period from 8 month to 2 years, have had a significant clinical and endoscopic improvement.

Conclusion. The use of a 3-component scheme consisting of Pariet, Itoprid, Rebagit for EB treatment allows a much faster clinical and local endoscopic improvement to be achieved.

336

POSTERIOR COMPONENT SEPARATION IN TREATMENT OF BIG AND GIANT POSTOPERATIVE VENTRAL HERNIAS

M. Prudkov¹, Yu. Mansurov¹, S. Tsap², A. Sharipov¹

¹*Sverdlovsk Region Clinical Hospital No1, Ekaterinburg, Russia*

²*Medical Center "UMMC - Health", Ekaterinburg, Russia*

Background. Reconstructive methods are the most perspective variants of surgical treatments for patients with large abdominal wall defects. Using these methods allows us to increase the intra-abdominal pressure and repair abdominis muscle functions. In 2012 Novitsky Y.W. et al. designed TAR (transversus abdominis muscle release) method, which has become a great advance in treatment of this patients. But this innovation technique has some disadvantages, for example, incising of transversus abdominis muscle impairs "corset" function of ventral abdominal wall and causes so-called "barrel-shaped" abdomen. Research objective. Improving TAR method.

Methods. Between August 2013 and December 2017 we

used the TAR in 158 patients with incisional ventral hernias. There were 3 (1.6%) – W2, 42 (26.8%) – W3 and 113 (71.5%) – W4, also there were 47 patients (29.7%) with R hernias (J. P. Chevrel and A. M. Rath, 1999). Main analgesia method for patients with giant hernias was combined anesthesia (inhalation + epidural), with catheterization of the epidural space Th6 - Th7. We have changed our surgical technique in 2015. We did posterior component separation by dividing all the muscles of the ventral abdominal wall. Then, we fixed medial sides of internal oblique muscles to the synthetic mesh, creating a new fixing point. If there were an increasing of intra-abdominal pressure, we have incised transversus muscle partially or completely. Incised transversus muscle we fix to the synthetic mesh in the same way.

Results. 102 patients have been operated since 2015. We didn't divide transversus abdominis muscle in 75 (73.8%) patients, in 15 (14.7%) patients we used partially dividing and in 12 (11.8%) patients transversus muscle divided completely. In 7 (4.4%) patients after all layers of the anterior abdominal wall separation and complete transversus abdominal muscle dividing, we used elements of Ramirez method. In 6 (3.8%) patients after all surgical manipulations we couldn't completely repair anterior rectus sheath, there was defect less, than 6x8 cm in the epigastric region. In 2 (1.3%) patients with tissue defects, due to the absence of a part of the ventral abdominal wall, we used inlay method and tried to repair and restore anterior abdominal wall muscles function. Postoperative wound complications occurred in 23 (14.6%) patients. There was 1 (0.6%) death, which was caused by pulmonary embolism.

Conclusions. Using of our modification Novitsky Y.W. method allows in 73.8% completely maintain function of transversus abdominal muscle, in 26.2% retain the function of transversus abdominal muscle partially.

disease progression were analyzed. Patients with non-epithelial (n=3) and neuroendocrine (n=3) malignancies were excluded. We found records about 135 patients (80 (59.3%) men, 55 (40.7%) women, male-to female ratio 1,45 in accordance with higher frequency of GC in men). Mean age at diagnosis was 65.9±11.34 years (range 36 – 89 years) and didn't differ significantly in men and women. Histologic examination showed adenocarcinoma in 83 (61.5%) cases, signet ring cell carcinoma in 26 (19.3%), undifferentiated carcinoma in 8 (5.9%), adenosquamous and squamous carcinomas were present in single (n=1, 0.74%) cases, in 16 (11.9%) patients diagnosis was verified by cytology only. In most cases distant metastases were found in liver (n=57, 42.2%, in 25 (43.9%) of them – isolated), non-regional lymph nodes (n=52 (38.5%), including 23 in retroperitoneal, 10 in paraaortic, 3 in parapancreatic, 6 in left supraclavicular – Virchows metastases, 2 in mediastinal), peritoneal carcinomatosis was seen in 50 (37.0%) cases (including 2 in mesentery and mesocolon, in 25 (18.5%) cases ascites as a sign of carcinomatosis was described. Other locations of metastases included lungs (n=11, 8.1%), ovaries (n=11, 8.1%), bones (n=6, 4.4%), adrenals (n=5, 3.7%), kidneys (n=2, 1.5%), fat (n=2, 1.5%), malignant pleuritis (n=2, 1.5%), brain (n=1, 0.75%). The proportion of signet ring cell carcinoma was significantly higher in cases with peritoneal metastases (32.0%) than in those with liver involvement (7.0%), while adenocarcinoma was more prevalent in cases with liver metastases (54% vs. 68.4%) ($\chi^2=9.38$, $p=0.002$). 130 (96.3%) patients died of the disease or from other causes, with median survival time 100 days. Median follow up of alive patients was 30 (from 2 to 36) months. In stage IV GC metastases are mostly found in liver, non-regional lymph nodes and peritoneum, but relatively rare locations are also seen in some patients. Signet ring cell carcinoma preferentially metastasized to peritoneum. The prognosis of patients was poor with median survival a bit more than 3 months.

337

PATTERNS OF METASTATIC SPREAD IN STAGE IV GASTRIC CANCER

M. Puchinskaya¹, E. Basarab², V. Zhelezinskaia²

¹Minsk City Clinical Oncologic Dispensary, Minsk, Belarus

²Belarusian State Medical University, Minsk, Belarus

Gastric cancer (GC) is one of the leading causes of cancer-related deaths in Belarus. In many cases it is due to the diagnosis in advanced stages. About 30% of GC patients in Belarus are diagnosed in stage IV and half of patients die within one year after diagnosis. To evaluate patterns of metastatic spread in stage IV GC. Data of Belarusian cancer registry for Minsk city were obtained by automated search performed by terms "diagnosis: C16", "date of diagnosis: 2015", "stage: 4" and retrospectively analyzed. No review of medical histories was performed. Only metastases present at diagnosis, but not those that developed later as a sign of

338

PRIMARY PANCREATIC DIFFUSE LARGE B-CELL LYMPHOMA – A RARE CASE DESCRIPTION

M. Puchinskaya, S. Skers, Ya. Baranau

Minsk City Clinical Oncologic Dispensary, Minsk, Belarus

Diffuse large B-cell lymphoma (DLBCL) is the most frequent type of non-Hodgkin lymphomas. Pancreatic involvement can be seen in some cases of widespread disease, but DLBCL primarily and mostly affecting pancreas, is rare. Only about 200 cases of pancreatic non-Hodgkin lymphomas were described in English literature. Treatment strategies for such extranodal involvement are generally recommended to be the same as for nodal disease, but no randomized controlled trials were performed. To describe a case of primary pancreatic DLBCL. We describe a patient with pancreatic

DLBCL treated in our Dispensary. A hypoechoic tumor of the head of the pancreas was first found in a 66-year old woman during ultrasound examination. She admits no symptoms at that time. Contrast-enhanced computed tomography (CT) confirmed the presence of a tumor with delayed enhancement in the head of the pancreas and regional lymph nodes. The patient was admitted to another hospital where an ultrasound-guided core needle biopsy was performed, giving the diagnosis of adenocarcinoma. It was followed by pancreaticoduodenal resection, and on fresh frozen sections a tumor composed of cells with large nuclei not forming any special structures was diagnosed as undifferentiated malignant tumor. After histologic evaluation of formalin-fixed paraffin embedded sections of postoperative material the diagnosis of DLBCL was made and further confirmed by immunohistochemistry (CD20+++, LCA+++, CK-, EMA-). Positron-emission tomography (PET)-CT scan showed no signs of other sites involvement. The final diagnosis was DLBCL involving the head of the pancreas and lymph nodes of hepatoduodenal ligament, stage IIE, low international prognostic index score. The patient was then admitted to our hospital and 6 cycles of R-CHOP chemotherapy were used according to international recommendations. During follow up the enlargement of one mesenteric lymph node and a single focus in the liver were found, but on control PET-CT both of them were PET-negative and smaller in size, so they were not considered metastases, but further follow up was recommended. The patient now stays disease free for 14 months after the diagnosis. Primary pancreatic involvement by DLBCL is very rare and difficult to diagnose, as symptoms and visualization findings are non-specific and similar to those of pancreatic adenocarcinoma. The diagnosis relies mostly on histologic examination, but if made preoperatively can lead to avoidance of unnecessary surgery as chemotherapy gives good results. Awareness of both clinicians and pathologists is needed to make a correct diagnosis.

339

CARCINOSARCOMAS OF THE DIGESTIVE SYSTEM: A COUNTRY-WIDE EXPERIENCE

M. Puchinskaya¹, L. Levin²

¹Minsk City Clinical Oncologic Dispensary, Minsk, Belarus

²N. N. Alexandrov National Cancer Centre, Minsk, Belarus

Carcinosarcomas (CS) are rare biphasic tumors composed of both malignant epithelial and mesenchymal components. They are most frequent in uterus and ovaries, but were described in virtually all organs. In most cases both tumor components were shown to be monoclonal by various techniques. Epithelial-mesenchymal (EMT) transition is considered to be one of the possible mechanisms of CS formation as sarcomatous component is thought to arise

from a carcinomatous one. The aim of the work was to analyze the cases of CS of the digestive system. An automated search in the Belarusian cancer registry was performed by a morphology code 8980/3 and 8981/3. Only the data present in the registry were analyzed, no further review of histologic slides or medical histories was performed. The search returned 514 records, of which only 8 (1.56%) cases were CS of the digestive system. They included 2 CS of the liver, 2 pharyngeal, 2 colonic (cecum and ascending colon), 1 gallbladder and 1 of the abdominal cavity. There were 3 men and 5 women. Mean age at diagnosis was 64.5 years (range 29 – 85 years). The disease was diagnosed in stage II in 1 case, stage III in 3 and stage IV in 4. All diagnoses were histologically verified. Data on histologic types of carcinomatous and sarcomatous components were lacking in the records. Tumor directly invaded the adjacent organs in 3 cases, distant metastases were present also in 3. Radical or palliative surgical treatment was possible in 4 patients (in 1 case followed by chemotherapy). Chemoradiotherapy was used in 2 patients (with pharyngeal CS). Only symptomatic treatment after explorative laparotomy and tumor spread evaluation was possible in 2 cases. 7 (87.5%) patients died of the disease (mean survival time 4.4 months, range 1 – 13 months), one patient was alive at the time of data collection with follow up of only 4 days. CS of organs of the digestive system are extremely rare tumors, but very aggressive. In half of all cases they were diagnosed in stage IV. Treatment procedures used in CS were generally the same as for pure carcinomas of the same site, but the treatment results were poor, as mean survival time was 4.4 months and 75% of patients died in less than 6 months after the diagnosis despite any kinds of treatment. This poses the necessity of further studies of biology of CS and mechanisms of their formation (including the role of EMT and its signaling pathways) to provide novel therapeutic strategies.

340

ASSESSMENT OF RESULTS OF A RESECTION OF A LIVER

B. Rakhimov, V. Kolesnikov

GBUZ SO TGKB No 5 Togliatti, Russia

The lethality after a resection of a liver remains within 4 – 6% and is very far from zero.

Purpose. Assessment of short-term results of a resection of a liver.

Material and methods. For 2014 – 2017 years 72 patients concerning various diseases of a liver of 3 and more segments which demanded excision are operated. A man was – 43, women – 29. Age from 41 to 79 years. On average 58±6 years. Malignant diseases – 55; benign disease – 17 patients. It is executed a right-side hemihepatectomy – 36 (including, with a resection and reconstruction of vessels –

2), left-side – 32 (including with a resection of vessels – 1, a stomach resection – 1); The resection of S IV-V-VIII of segments – 4 patients. Serious associated diseases had – 17 patients. Two patients were after 9 and 11 courses of a chemotherapy respectively. The serious fibrosis and a steatosis of a liver had 21 patients. Operative measure time – 210 min. An occlusion of a hepatoduodenal ligament at – 60 patients. An average hemorrhage – 200,0 ±110,0 ml.

Results. Complications after operation – 23(31,9%). An acute liver failure – 1 (1); postoperative bleeding – 1(1), a sepsis – 1(1). Nonspecific complications had at 18 patients and specific at five from which three died.

Conclusion. The complication and lethality after a resection remains appreciable. The number of patients of advanced age which needs a liver resection is enlarged. Prophylaxis of serious postoperative complications requires strict observance of the anatomic principles of a resection.

341

RESULTS OF SURGICAL TREATMENT OF CHRONIC PSEUDO-TUMOR-LIKE PANCREATITIS

B. Rakhimov, V. Kolesnikov, I. Galkin

GBUZ CO "TGCB No 5" G. O. Togliatti

Chronic pancreatitis is an inflammatory disease characterized by progressive and irreversible transformation (rebirth) of the pancreatic parenchyma into fibrous tissue. The incidence in Russia varies from 25 – 35 people per 100,000 of the population. In Togliatti annually registers approximately 50 to 55 patients with chronic pancreatitis.

Purpose. Introduction of organ-preserving pancreatic surgery in chronic pancreatitis based on morphological changes in the clinical practice of the departments.

Material and methods. The results of surgical treatment of 36 patients with chronic "pseudotumorous" pancreatitis for the period from 2006 to 2012 were studied. There were 30 men, 6 women, the age ranged from 39 to 65 years. Only four patients categorically refused to take alcohol in history, 30 patients had the main etiological factor of CP alcohol abuse, the cause of CP in 2 patients remained unknown. One patient was excluded from the analysis, in whom adenocarcinoma was detected during the planned histological examination of the removed drug. The patient underwent standard pancreatoduodenal resection. The main complaint upon admission in the vast majority of patients was pain. Mechanical jaundice with a level of direct bilirubin 89-156 μmol / l was found in 4 patients. Two patients had a duodenal obstruction clinic with characteristic complaints and an x-ray picture. 8 patients in the medical history revealed prior surgical intervention for chronic pancreatitis: pancreatojejunostomy on a loop of the small intestine with an anastomosis according to Braun, a biopsy of the

pancreatic head in 1 patient, external drainage of festering cysts – in 3 patients. Diabetes mellitus as a complication of chronic pancreatitis was in 17 patients. Diagnosis was based on history, clinical picture, laboratory data, including tumor markers, in particular CA 19-9, the study of ultrasound (ultrasound) and spiral computed tomography (CT). Three patients additionally carried out adenomalacia resonance imaging (MRI), five patients also endoscopic retrograde cholangiopancreatography (ERCP). In the study of the data of the SCT, the studies were focused on the revealed morphological changes: the head of the pancreas, the common bile duct, the main duct of the pancreas, and the pancreas parenchyma. The following parameters were used as a norm: the head of the pancreas is 2.5 – 4 cm; the main duct of the pancreas is 3 – 4mm; the common bile duct is 7 mm; the pancreas parenchyma is the presence of calcinates, pseudocyst, fibrosis. When orienting to the above indicators in the analyzed group of patients, the following data were obtained: an increase in the head of pancreas more than 5 cm-4 people, 4-5 cm-29 people, less than 4 cm-2 people; the main duct of the pancreas more than 4 mm-in 27 patients, 3-4 mm-in 6 patients, less than 3 mm-in 2; the common bile duct more than 1.5 cm-7 patients; changes in the pancreatic parenchyma in the form of calcification-in 12 patients, pseudocysts-in 4 fibrous changes of one degree or another in 30 patients. Multiple changes occurred in 24 patients: increase in the head of pancreas + expansion of the main pancreatic duct or common bile duct + changes in the parenchyma of the gland; 12 patients had only one detected pathological change. Carried out the following interventions: the original Beger procedure – 4, Berne variant of Beger, s operation – 2 Operation Freya – 29, standard pancreatoduodenal resection – 1. The average time of operation-138 min (126 – 318); intraoperative blood loss – 500 ml (100 – 1500).

Result. Early complications: duodenal fistula-2, suppuration of the wound-4, abscess of the abdominal cavity-1. Relaparotomy-3: two patients after the operation of the Beger had duodenal fistula, one was operated on on the 5th day after the primary operation-disabling 12PC with gastroenterostomy-recovery, the other was operated on the 10th day-death. The patient with the operation of Freya and giant cyst of the tail (the V-8 gallons) there was an abscess in the pelvis which required relaparotomy and installing more drainage – recovery. After 1.5 years, the patient was re-operated after a complicated operation of the Beger (duodenal fistula) with the clinic of mechanical jaundice and cholangitis – the removal of the previously imposed GAA, the restoration of duodenal patency with duodenodenostomy and the imposition of hepaticoenterostomy on the diverting loop. Pain syndrome at the time of discharge was eliminated in all patients.

Conclusion. The use of organ-preserving surgery in chronic pancreatitis based on the elimination of morphological changes of the body gives quite satisfactory results.

342**TUMORS OF THE SMALL INTESTINE. DIAGNOSIS AND TREATMENT****B. Rakhimov, A. Kirsanov, V. Kolesnikov**
GBUZ CO "TGCB No 5" Togliatti, Russia

The aim of the work is to improve the diagnosis of small bowel tumors with the help of original enterography.

Material and methods. Analyzed the experience of diagnosis and treatment of 23 patients treated in the clinic in 2005 - 2017, All patients were hospitalized and examined for a tumor of the small intestine occurring under the guise of various diseases of the abdominal cavity. There were 6 men and 17 women. Age of patients ranged from 32 to 75 years. From the anamnesis the patients were admitted to the therapeutic clinic of the hospital repeatedly over an indefinite complaints. Two clinical syndromes prevailed: anemia - 7 patients and partial intestinal obstruction - 16 patients. Palpable tumor in the mesogastric region was found in 2 patients, body weight loss was observed in 7 people from the group with intestinal obstruction and 2 people from the group with predominance of symptoms of blood loss. 19 patients noted pain of a cramping nature, especially after eating. Laboratory parameters, probe enterography, ultrasound examination of the abdominal cavity, spiral computed tomography were used for diagnosis. Patients were examined using the original technology of enterography. All patients were operated on. The diagnosis was confirmed by a morphological study of the remote drug.

Results. Three patients were operated on urgently for profuse bleeding from a small intestine tumor, the rest were operated on in a delayed order for partial small bowel obstruction. By localization of the tumor in 5 cases were located in the jejunum, in 18 patients in the thin. In three cases, the tumor was localized on the mesentery of the intestine. In all other cases, the tumor was located in the lumen. The operation consisted in resection of the small intestine with adherence to oncological principles. There were no complications or deaths.

Conclusion. Tumors of the small intestine is difficult to diagnose. The possibilities of routine contrast radiography are limited. The largest amount of information can be obtained by using the proposed original method of probe enterography in combination with spiral computed tomography.

343**COMBINED MODIFIED BLUMGART AND DUNKING TECHNIQUE FOR PANCREATICOJEJUNOSTOMY IN TOTAL LAPAROSCOPIC PANCREATODUODENECTOMY****Rapheephat Tanompetsanga, Nuengruetai Orannapalai, Chairat Bunchaliew, Rawisak Chanwat**
National Cancer Institution, Thailand

Object. Pancreatoduodenectomy (PD) was the complex procedure include resection phase and reconstruction phase for treat periampullary lesion. Laparoscopic approach was new and challenging for surgeons that have to understand in pancreatic anatomy and have high minimally invasive surgery skill such as suturing and dissecting with laparoscopic device Postoperative pancreatic fistula is the most terrible complications of PD that cause abdominal abscess, intra-abdominal hemorrhage and death Modified Blumgart technique was eliminate tangential tension and shear force between fragile pancreas and jejunum in pancreaticojejunostomy(PJ) For the small pancreatic duct, PJ anastomosis by dunking technique was recommended for reduce post operative pancreatic fistula.

Materials and methods. This video was demonstration how to perform total laparoscopic PD with PJ anastomosis by modified Blumgart and dunking technique in patient with distal CBD lesion.

Results. Patient was good recovery with operative time 8 hr, estimated blood loss 100 cc with no complication patient was discharge at postoperative day 10.

Conclusions. Total laparoscopic PD was safe and feasible SMA and SMV were identified and dissection by medial uncinata approach For Soft pancreatic parenchyma and small pancreatic duct, pancreaticojejunostomy was safe to performed by Modified Blumgart and invagination technique.

344**LONG TERM SINGLE INSTITUTION RESULTS OF ADJUVANT CHEMORADIOTHERAPY IN CARCINOMA OF GALLBLADDER****Neeraj Rastogi¹, V K Kapoor², Shaleen Kumar¹, Rajan Saxena²***¹Department of Radiotherapy, ²Department of Surgical Gastroenterology, Sanjay Gandhi Post Graduate Institute of Medical Sciences, Raebareli Road, Lucknow, India*

Background & Purpose. Carcinoma of gallbladder is difficult disease to control due to advanced disease at presentation, poor resectability and high loco-regional recurrence even after radical surgery. As role of adjuvant therapy is not well defined, an attempt has been made to evaluate the role of adjuvant chemoradiotherapy following simple/radical chole-

cystectomy in the management of gallbladder carcinoma.

Materials and methods. One hundred ninety one patients of carcinoma of the gallbladder were inducted into the prospective non- randomized study. Age ranged from 28-75 years (median = 50 years; females -142, males -49). One hundred nineteen underwent simple cholecystectomy and 72 underwent radical cholecystectomy. The patients were staged according to AJCC/TNM staging (I=18, II=74, III=94, IVA= 5). All received postoperative external beam radiotherapy (45-50.4Gy/25-28 fractions/5-5½ weeks). Patients with transmural infiltration or positive drainage lymph nodes on histology, were given chemotherapy (5-Fluorouracil 350 mg/m² IV weekly x 12 cycles or D1-5 monthly x6 cycle) or Tab. Capecitabine 1650 mg/m² during radiation therapy 5 days a week and as adjuvant for 4 cycles.

Results. Follow up ranged from 5-22 (median= 10) years. At the time of evaluation 46/191(24%) patients were alive with no evidence of disease. Median survival was 18 months. Overall survival rate at 10-years was 22%(Simple Cholecystectomy =19%, Radical cholecystectomy =24%). 10-year survival rate in stages I, II, and III were 25%, 23.7% and 19% respectively. Among 145 patients who succumbed to death, 58% had loco-regional recurrence and 37% had distant metastases including liver, neck node and peritoneal deposits (ascitis) and 5% lost to follow-up were also considered dead for analysis. In multivariate analysis T stage was found to be the only factor of prognostic significance for overall survival.

Conclusions. Adjuvant chemoradiotherapy following cholecystectomy is feasible, effective and can provide an improvement in the loco-regional control and prolong overall survival in carcinoma of the gallbladder. Large prospective randomized trial needed for definitive conclusions.

345

LIVING LIVER DONOR EVALUATION AND ACCEPTANCE AT A NEWLY ESTABLISHED LIVER TRANSPLANT CENTRE

Raut Vikram, Ingule Amol, Parmar Tushar, Panchwagh Amaya, Sawant Amreen, Nagral Abha, Billa Geeta, Deshmukh Sharad, Vasanth Suresh, Bagde Abhijet, Ambekar Aasawari, Yawale Vijay, Mirza Darius
Apollo Institute of Liver disease and transplantation, Apollo Hospital Mumbai, India

Outline. Live donor liver transplantation (LDLT) is a crucial source of donor livers in societies where deceased donor liver transplantation (DDLT) activity is low. We report outcomes of evaluation of potential living donors at a newly established transplant unit in a new 550 bedded multi-specialty hospital in Mumbai.

Aim. The aim of this study was to identify reasons for donor acceptance and rejection; and study outcomes of recipients

when living liver-donors were rejected during the assessment process.

Methods. Between May 2017 and May 2018, a total of 50 living donors were evaluated for liver donation at Apollo Hospitals Mumbai. Donor evaluation is divided into 4 phases:1st- liver quality assessment, 2nd- assessment of liver volumes and anatomy, 3rd-cardiopulmonary evaluation, 4th-consultations and meeting with the independent donor advocate.

Results. Overall 50 donors were evaluated for 42 recipients (32 adults, 10 children), 35 recipients had 1 donor, 6 recipients had 2 donors, 1 recipient had 3 donors evaluated. The median age of the donor was 35.5 yr (19-56 years), 28 were females and 22 males. A total of 17 donors were children of adult recipients, 12 were parents, 6 were siblings, 6 were spouses, and 13 were second degree relatives. Out of 50 donors evaluated, 26 donors donated part of their livers, and 24 were rejected. The causes for rejection of donors was steatosis (n=8, Phase-1), anatomy and volumes (n=5, Phase-2), withdrawal of donor consent (n=5), and recipient related causes (n=6). Of the 19 recipients whose donors were rejected, 7 died, 4 are awaiting DDLT, 3 had DDLT, 3 had LDLT with a second donor, and the recipients condition improved such that patients were delisted or suspended in two. A total of 26 patients underwent LDLT - 17 had right lobe, 8 had left lateral, 1 left lobe donation. Mean ICU stay in donors was 1 day and, hospital stay was 5-8 days. Recipient and graft survival at 90 days in this cohort was 92.3%.

Conclusions. Some 48% of evaluated donors were rejected during evaluation. The most common cause of donor rejection was liver steatosis. A total of 36% recipients whose potential LDLT donors were rejected died during the waiting period. LDLT remains an essential source of donor livers when DDLT activity is low.

346

ACUTE PARAPROCTITIS IN PATIENTS WITH LEUCOSIS

Ravich L.D., Khmylov L.M
GKB them. S.P. Botkin, Russia

Relevance: Acute paraproctitis is one of the septic complications of chemotherapy. According to different authors septic complications in patients undergoing chemotherapy occur as frequently as 75% and are among the main causes of death. These complications include pneumonia, infections of the digestive tract, skin and adipose. Dissemination is a distinctive feature of septic processes which occur along with acute leukemia. Granulocytopenia caused by tumor growth and cytostatics are the main pathological mechanisms of these septic complications. One of them is acute paraproctitis which occurs, according to different sources, in 3,5% to 10,8% of cases. Another complication is bacteremia, which occurs in 22% of patients. Morbidity caused by septic

complications of chemotherapy reaches up to 30%.

Materials and methods: A retrospective study of 1102 patients with acute leucosis who underwent treatment at the Botkin Hospital, Moscow from 2007 to 2017 was performed by our department. 853 patients were diagnosed with acute myeloblastic leukemia, 249 – with acute lymphoblastic leukemia. 6,9% (59) of patients with myeloblastic leukemia and 6%(15) of patients with acute lymphoblastic leukemia developed acute paraproctitis. Thus a total of 74 patients, 57 men and 17 women 18 to 80 years of age (average 43) were included in the study. 94,6% (70) of patients developed acute paraproctitis as a complication of chemotherapy, but in 5.4% (5) of cases acute paraproctitis preceded leukemia manifestation. Chronic diseases of the anal canal such as anal fissures and incomplete internal fistulas were the source of pararectal infection in 56 (75.6%) patients. Paraproctitis presented in forms of abscess in 16% (12) of patients, inflammation and tissue infiltration in 68% (50) , single or multiple rectum wall ulcers in 16% (12). 87,8% of patients had neutropenia. Only 12.2% (9) of patients with pararectal abscesses had a normal hemogram. Patients with pararectal infiltration and rectal ulcers had various stages of neutropenia. 33.8%(25) of patients with neutropenia developed bacteremia. Monocultures of bacteria were discovered in 17 cases and polybacterial communities in 8 cases. Patients with rectal ulcers which epithelized between courses of chemotherapy were treated conservatively. Patients with granulocytopenia were also treated conservatively with antibiotics. Surgery was performed in patients with abscesses with a fluctuating cavity. Pararectal infiltration was successfully reversed with conservative treatment in 80% of cases.

Results: 40 out of 50 (80%) patients with pararectal infiltrates were successfully treated conservatively. In 8 (10.8%) patients paraproctitis reoccurred after treatment. All of them had neutropenia along with chronic diseases of the rectum. 7 (9.5%) patients died. 4 died of sepsis, 1 of pseudomembranous colitis, 1 of stroke and 1 of acute gastrointestinal bleeding.

Conclusions: 1. Acute paraproctitis occurs in 6,9% (59) of patients with myeloblastic leukemia and 6%(15) of patients with acute lymphoblastic leukemia. 2. Form of pararectal inflammation is determined by granulocytopenia. 3. Treatment choice must be based on the clinical form. Rectum ulcers and pararectal infiltration should be treated conservatively with antibiotics. Abscesses require surgical intervention.

347

SPONTANEOUS RUPTURES OF THE ESOPHAGUS: DIAGNOSIS AND TREATMENT

Rayhan All, V. Bulynin, D. Bulynin, Yu. Parkhisenko, I. Urgelas, R. Frolov

*Voronezh State Medical University named after N.N. Burdenko, Hospital Surgery Chair
Voronezh regional clinical hospital no.1*

Relevance. Spontaneous rupture of the esophagus is relatively rare, ranging from 2-3% of all cases of damage of the esophagus. According to the majority of authors, from 82% to 95% it is located in its lower third on the left (Harma R. A. et al., 1968; Gupta N.M. et al., 2004; Kumar P.K. et al., 2004). Today, there is no categorical opinion about the effectiveness of different methods of treatment among surgeons, there are no unified algorithms for diagnosis and treatment. Spontaneous rupture of the esophagus - mortality is up to 75% in the prehospital period and more than 90% in the postoperative period, and depends on the time interval between rupture of the esophagus wall and the time of operation, as well as complications (purulent mediastinitis, sepsis, bilateral focal purulent pneumonia, multiple organ failure).

Purpose. To improve the results of surgical treatment of patients with spontaneous rupture of the esophagus by offering a new method of surgical treatment.

Material and methods. From 1998 to 2017 in the Voronezh regional clinical hospital №1 was treated 10 patients with spontaneous rupture of the esophagus by the method proposed in the clinic – thoracotomy in the 6th intercostal space on the left, the allocation of the esophagus, perforated hole is not sutured, and it is formed a cuff from the fundus of the stomach, covering the perforation, the pleural cavity is drained. Other methods were used to treat 12 patients.

Results. In the diagnosis of disease fibrogastroduodenoscopy allowed the correct diagnosis in 64%, X-ray with contrast of esophagus makes possible to diagnose spontaneous rupture of the esophagus only in half of the cases (50%). CT with water-soluble contrast, according to our data, allowed to diagnose this disease in 100% of cases. Among the patients whose perforating hole was not sutured, and formed the cuff from the fundus of the stomach, covering perforation, mortality was 2 (20%) patients. Insolvency of stiches of the cuff did not occur. Among the patients operated with other methods the mortality rate is much higher – 66.6%.

Conclusions. The most effective method of diagnosis is CT scan with contrast of esophagus. Treatment is the restoration of the ruptured esophagus without suturing the wound, and the formation of the cuff from the bottom of the stomach, covering perforation (fundoplication by Chernousov). Drainage of the pleural cavity and nutrition through the nasogastric tube.

348

UROLOGICAL COMPLICATIONS IN HERNIA SURGERY

A. Reznichenko*City Hospital No 5, Sochi, Russia*

Patients with hernias of the anterior abdominal wall account for 8-18% of the total number of patients in surgical hospitals. With relatively simple and sufficiently delicate surgical interventions performed for hernias of the anterior abdominal wall, intraoperative operations often occur, and after the operation, early and late postoperative complications occur. Many of the hernias involve the organs of the genitourinary system in the pathological process. and numerous literature data show that the urological complications after numerous types of hernioplasty are either underestimated or, in general, not taken into account. The aim of the study is to improve the results of treatment of ventral hernias with concomitant or acquired urological pathology.

Materials and methods: All patients entering the surgical department for surgical treatment of the hernia, in addition to general clinical examination, conducted a detailed study of the genitourinary organs, and during the collection of the anamnesis, additional questionnaires were also distributed for the evaluation of the International Classification of Prostate Symptom Scores (IPSS) and the Quality of Life Evaluation Index (QoL). In addition, all patients under 60 years of age were given a questionnaire to determine the Index of Erectile Function (ICEF). All the male patients underwent digital rectal examination (PRI), and from the laboratory studies a venous blood sample was taken to determine the prostate-specific antigen (PSA). From the methods of functional diagnosis, ultrasound of the urogenital system was performed, as well as uroflowmetry (UFM).

Results: When conducting hernioplasty taking into account the state of the lower urinary tract and its possible correction, the results of surgical interventions are significantly improved.

Conclusion: 1. For patients with hernias of the anterior abdominal wall it is necessary to perform ultrasound of the organs of the genitourinary system in order to establish or exclude them as a component of hernia contents. 2. Patients with hernias of the anterior abdominal wall should undergo a comprehensive urodynamic examination in order to prevent possible pathological changes in the act of urination and their timely correction. 3. The treatment of possible complications in the immediate postoperative period should be performed with a dynamic ultrasound of the urinary tract and the area of the postoperative wound.

349

SUCCESSFUL SURGICAL TREATMENT OF INTESTINAL LYMPHANGIECTASIA-CASE REPORT

Zijah Rifatbegović¹, Jasminka Mujkanović²,**Osman Muratović²**¹*University Clinical Center Tuzla, Clinic of surgery Tuzla, Bosnia and Herzegovina*²*The University of Tuzla, Faculty of medicine Tuzla, Bosnia and Herzegovina*

Objective: To report an uncommon method of managing lymphangiectasia.

Clinical presentation and intervention: A 45-year-old woman was admitted with abdominal pain, nausea, vomitus and abdominal swelling. Five months before admission, she had undergone laparoscopic surgery on the Clinic of gynecology, surgical procedure on the Clinic of surgery, and few more abdominal punctions on the Department of cardiology, and the Department of gastroenterology. Computed tomography scanning (CT) revealed large amount of abdominal ascites, abdominal fluid collections and fluid collections in retroperitoneum. Blood tests showed low blood proteins, lymphocytopenia and low count of the red blood cells. She had undergone surgical procedure, and in the early post-operative period fluid collections disappeared, she had no more abdominal pain and results of blood tests showed improvement of her condition.

Conclusion: In this case, surgical resection for localized secondary intestinal lymphangiectasia was a successful option of management lymphangiectasia.

350

PREVENTION OF ANASTOMOSIS COMPLICATIONS AFTER LAPAROSCOPIC TOTAL MESORECTUMECTOMY

Rodimov S.V*National Research Center for Preventive Medicine of the Ministry of Healthcare of the Russian Federation*

Relevance: To date the rate of an anastomotic leak (AL) at the anterior rectal resection varies between 3.2% and 36%. The formation of low colorectal anastomosis increases the rate of AL by two times. Studies carried out in the world literature do not contain sufficient grounds that would allow reliably determining the dependence of the development of AL from any factors, and do not suggest ways to influence them.

Aim: To improve immediate results of performing laparoscopic TME by developing and implementing the complex of measures to prevent complications of a hardware anastomosis.

Materials and method: From 2013 to 2017, the retrospec-

tive-prospective study of patients who underwent laparoscopic TME was performed at the coloproctological department of the Ryazan Region General Hospital. On the first stage of the study, the retrospective analysis of 52 patients (Group 1) was performed. The following factors with significant influence on postoperative complications were revealed using the multivariate and correlation analysis: narrow pelvis and lower ampullar localization of carcinoma in the rectum, stitching the distal part of the rectum with a linear stapler more than 3 times, the rectal wall thickness is more than 5 mm. On the second stage, the medical-tactical conception to prevent complications was created. It included transanal TME for patients with the narrow pelvis and lower ampullar localization of carcinoma in the rectum; the use of cassette stapler for the superdense tissue if the rectal wall thickness is more than 5 mm; the method of two-stage compression for circular and linear staplers. The conception was prospectively applied for 52 patients (Group 2), after that the comparative analysis of the results was undertaken.

Results: The comparative analysis revealed that there were less clinically significant complications from the hardware anastomosis in the Group 2 (3.8% vs. 15.4%, $p < 0.05$). According to the results of multivariate analysis, the influence of all risk factors for complications of the hardware anastomosis discovered in the Group 1 was managed to eliminate in the Group 2 ($p < 0.05$). When analyzing the patients with transanal TME, there were no significant differences in the incidence of complications in intra- and postoperative periods. However, when analyzing the results of the Group 1 in patients with similar characteristics (the narrow pelvis and lower ampullar localization of carcinoma in the rectum), postoperative complications were less frequent in patients of the Group 2 (22.2% vs. 85.7%, $p < 0.05$).

Conclusions: As a result of the implementation of the developed medical-tactical conception, 4 times more cases of clinically significant complications from colorectal anastomosis were achieved (3.8% vs. 15.4%, $p < 0.05$). The method of transanal TME is a safe method of treatment, which reduces the number of complications of 3.9 times in complex patients with the narrow pelvis and lower ampullar localization of carcinoma in the rectum.

351

RE-RECONSTRUCTION OF THE DIGESTIVE TRACT IN SURGERY OF RECURRENCE GASTRIC CANCER

Ruchkin Dmitry Valerievich, Kozlov Valentin Alexandrovich, Bessonova Svetlana Alexandrovna
Institute of surgery A. V. Vishnevsky, Moscow

Actuality. Despite the continuous improvement of treatment methods of gastric cancer, long-term results are still not comforting. Gastric cancer recurrences, which occur in

about 20-60 % patients after radical surgery, are still a major cause of high mortality. In 11-13% cases, they are the only manifestation of gastric cancer. The question of the expediency of surgical treatment for recurrent gastric cancer has long been resolved. However, there arises the question of the quality of life of operated patients, which directly depends on the digestive tract reconstruction technique. Emerging digestive disorders, especially after combined surgeries, overshadow the success of surgical treatment and often exceed the suffering caused by the primary disease. Consequently, this lays a premise for further improvement of the methodology of repeated surgeries, taking into account the technical peculiarities of resection and reconstruction.

Aim. To search for the most physiological digestive tract reconstruction technique ("re-reconstruction") in operated patients with recurrent gastric cancer.

Materials and methods. From 2012 to 2017, 25 patients with recurrent gastric cancer underwent operations at the A.V. Vishnevsky Institute of Surgery. The study group was made up of 15 (60%) men and 10 (40%) women, with an average age of 58 years. In 11(44%) cases, the recurrence was at the zone of anastomosis, in 7 of them after gastrectomy, in 4 after distal and proximal gastric resection. Recurrence in the gastric stump was detected in 8 (32%) patients after distal resection, and in 3 (12%) after proximal resection. Locoregional recurrence was identified in 3 (12 %) patients after gastrectomy 2 , and in 1 case after proximal resection. Repeated operations were performed in all 25 patients.

Results. R0 surgical treatment was performed in 24 (96 %) patients, R1 in 1 patient (4 %), R2 in none. In the early postoperative period, complications occurred in 3 (12 %) patients: 1 (4%) had partial esophagojejunal anastomotic leakage, and 1 case of postoperative wound suppuration. Both cases were resolved with conservative therapy, by adequate ultrasound-guided drainage and vacuum aspiration. Only 1 (4%) patient needed a relaparotomy on post-op day 9, due to the necrosis of the colonic graft, which was resected with subsequent formation of nutritional colo and esophagostomy. There were no cases of mortality. A significant criterion in the evaluation of successful "re-reconstruction" was its completion, which was achieved in 92% of the cases. Long-term outcomes of the reconstructive surgeries were evaluated using a 3-point modified Visick scale, taking into account the patient's health, the dynamics of his nutritional status and the presence of certain digestive disorders. In the long-term, 20 (80%) patients out of 25 were under observation. On examination, 9 patients (45%) had a "good" outcome, 6 patients (30%) a "satisfactory" result post-op and only 5 patients (25%) reported no relief after reoperation. A median survival of 3 years was recorded.

Conclusion. Evaluation of the results shows a significant reduction in the severity postgastrectomy syndromes. This fact speaks to the advisability of repeated operations on the stomach with its reconstruction and restoration of duodenal food passage.

352

IMAGE-GUIDED HIGH DOSE RATE BRACHYTHERAPY OF UNRESECTABLE COLORECTAL LIVER METASTASES (AN INITIAL EXPERIENCE)

G. Rukhadze, A. Kaprin, S. Ivanov, I. Gulidov, N. Borisheva, D. Sanin, L. Petrov, N. Silantieva, O. Navoian, P. Sokoolov

A.Tsyb Medical Radiological Research Center – branch of the National Medical Research Radiological Center of the Ministry of Health of the Russian Federation (A. Tsyb MRRC)

Background. High Dose Rate Brachytherapy (HDRBT) is one of the new treatment options for unresectable colorectal liver metastases, which allows to achieve one-year local tumor control at 90-100%. HDRBT has no limitations with regard to the size of the treated tumors or may be used in the vicinity of the vessels and other sensitive structures. The therapeutic effect of HDRBT is not dependent on movement of the patient or respiratory excursion.

Purpose. To adopt HDRBT for treatment of unresectable colorectal liver metastases.

Material and methods. Our initial experience includes 8 patients with colorectal liver metastasis treated by computed tomography (CT)-guided High Dose Rate Brachytherapy (HDRBT). All cases were morphologically verified. The number of metastases varied from 1 to 5. The size of the metastases was from 2 to 8cm. The dose of radiation was delivered by 2 - 8 catheters with exposure times in the range of 42 to 112min. All patients underwent computed tomography before treatment, in the first six weeks after its completion, and then every three months. CT studies were conducted with bolus contrast enhancement. The criteria Recist 1.1 and Choi were used to assess response of the treatment.

Results. All patients achieved regression of liver metastases. In one case complete morphological response was confirmed in 3 months period after HDRBT. After the procedure I-II degree of gastrointestinal toxicity were observed. One patient after removal of the introducers developed intrapleural bleeding, requiring thoracoscopy and drain of the pleural cavity.

Conclusion. HDRBT of the colorectal liver metastases is well tolerated by patients and is easily reproducible. The method allows to achieve the local control of the tumor and may convert unresectable metastases to resectable.

353

THERAPEUTIC OUTCOMES AND PROGNOSTIC FACTORS IN UNRESECTABLE GALLBLADDER CANCER TREATED WITH GEMCITABINE PLUS CISPLATIN

Ji Kon Ryu, Min su You, Young Hoon Choi, Woo Hyun Paik, Sang Hyub Lee, Yong-Tae Kim

Department of Internal Medicine and Liver Research Institute, Seoul National University College of Medicine, Seoul National University Hospital, Seoul, Korea

Gallbladder cancer (GBC), the most common cancer of the biliary system, shows very poor prognosis. Gemcitabine plus cisplatin has been widely used for advanced GBC. This study was designed to investigate the efficacy of gemcitabine and cisplatin combination and prognostic factors in unresectable GBC. Patients with GBC treated with gemcitabine and cisplatin from January 2008 to June 2017 were included. All GBCs were confirmed by pathologic findings. To determine factors affecting prognosis, Kaplan-Meier survival analysis and log rank test were used. A total of 135 patients received 6.0 (3.0-8.0) cycles of gemcitabine in combination with cisplatin during 4.0 (1.8-6.3) months. Most of the patients (95.6%) were in stage IVB and the most common site of metastasis was the liver (38.5%). Clinical benefit rate was 80.7%; 2 (1.4%) patients with complete response, 27 (18.5%) with partial response and 80 (54.8%) with stable disease. Overall survival (OS) and progression-free survival were 9.9 (95% confidence interval (CI), 8.0-10.9) and 5.6 (95% CI, 4.5-6.7) months, respectively. Multivariable regression model indicated invasion to liver (hazard ratio (HR) 2.13, $p=0.010$), metastasis to liver (HR 1.77, $p=0.018$), neutrophil-to-lymphocyte ratio (NLR) ≥ 3.0 (HR 2.32, $p<0.001$), CA19-9 ≥ 300 (HR 2.08, $p=0.003$) and decrease of CA 19-9 by 50% (HR 0.51, $p=0.009$) were significantly associated with OS. Combination of gemcitabine with cisplatin demonstrated high disease control rate in patients with unresectable GBC. Factors related to OS were invasion and metastasis to liver, NLR ≥ 3.0 , CA19-9 ≥ 300 , decrease of CA 19-9 by 50% during follow-up.

354

CONDITIONED MEDIUM FROM TONSIL-DERIVED MESENCHYMAL STEM CELLS AMELIORATES CCL4-INDUCED LIVER FIBROSIS IN MICE

Kyung-Ha Ryu, Yu-Hee Kim¹, Kyung-Ah Cho¹, So-Youn Woo¹, Joo-Won Park²

Department of Pediatrics, College of Medicine, Ewha Womans University, Yangcheon-Gu, Seoul, Korea

Actuality. Liver is an organ with a remarkable regeneration capacity, although once the chronic fibrosis takes place liver

failure follows with high mortality and morbidity rates. At the same time, a continuous exposure to proinflammatory stimuli exaggerates pathological process of liver failure thus the immune modulation could be considered as one of the strategies to treat liver fibrosis. Mesenchymal stem cells (MSCs) with tissue regenerative and immunomodulatory potentials may support a development of the therapeutics for liver fibrosis. Previously, we reported that tonsil-derived MSCs (T-MSCs) migrate to injured organ and differentiate into hepatocytes.

The aim. Here we aimed at a dissociation of the paracrine effects from self-differentiation using T-MSC conditioned medium (T-MSC CM) as the mechanisms of action of T-MSCs in a treatment of liver fibrosis.

Materials and methods. In order to investigate that we induced a hepatic injury in mice by injection of carbon tetrachloride (CCl₄) for 3 weeks and treated the mice with T-MSC CM. We used recombinant human IL-1ra in parallel which we previously shown that is secreted exclusively from T-MSCs and resolve fibrogenic activation of myoblasts. Hepatic inflammation and fibrosis was determined by the histological analyses using H&E and Picro-Sirius red staining. Histological scores of inflammation and necrosis were evaluated by examination of H&E stained tissue sections and collagen deposition was quantified by calculating pixel densities of digital images.

Results. Results demonstrated that T-MSC CM treatment significantly reduced inflammation as well as fibrosis of CCl₄-injured mouse liver to the levels similar to the normal control group of mice. IL-1ra injection showed the effects comparable to T-MSC CM treatment suggesting T-MSC CM may exhibit anti-inflammatory and anti-fibrotic effects, in part, by an endogenous production of IL-1ra. Expression of genes involved in fibrosis was evaluated and results showed a significant induction of COL1A1, TGF- β , and TIMP1 by CCl₄ injection whereas T-MSC CM or IL-1ra downregulates the expression.

Conclusion. Taken together, these data support the therapeutic potential of T-MSC CM and/or IL-1ra for the alleviation of the liver fibrosis. Furthermore, this could be considered as a model to treat various diseases involving organ fibrosis.

355

THE PREDICTIVE POWER OF PREOPERATIVE BILIRUBIN FOR THE OUTCOMES FOLLOWING PANCREATODUODENECTOMY

Sara Saeidi Shahri, Mohsen Aliakbarian, Lida Jarahi
Surgical oncology research center, Mashhad University of Medical Sciences, Mashhad, IR Iran

Relevance: Periampullary tumors usually present with obstructive jaundice; this high level of bilirubin in turn, may

increase morbidity or mortality after curative surgery.

Object: We aimed to assess the impact of preoperative bilirubin on the outcomes following pancreaticoduodenectomy (PD).

Materials and methods: In this retrospective study data were analyzed from a total of 80 patients with periampullary tumors underwent PD between 2013 and 2017. Regarding the preoperative bilirubin levels, we opted 20mg/dl for cut-off point to divide patients into two groups to be subjected for analysis.

Results: 80 patients underwent PD with the mean age of 54.90 \pm 14.33 (22-82). Of them, 40(50%) were male. 9(11.3%) patients died within 30 days of operation and early morbidity rate was 37.5%. The median preoperative bilirubin was 4.7mg/dl and majority of cases (88.8%) had bilirubin<20mg/dl. However there was a tendency for postoperative mortality to be higher in patients with bilirubin \geq 20mg/dl (22% vs. 9% for bilirubin<20mg/dl), the relationship was not statistically significant (P=0.266). In contrast, in both univariate and multivariate analyses, preoperative bilirubin was observed to be the only independent variable affecting 30-day postoperative morbidity status; In the way that bilirubin \geq 20mg/dl remarkably increased the morbidity (P=0.012, Odds ratio=3.04). 57.5% of our cases underwent preoperative biliary drainage (PBD) which did not impact the mortality and morbidity (P>0.05).

Conclusions: In this study, however preoperative bilirubin affected overall morbidity status; it could not predict the mortality accurately. Also, since PBD did not show benefits for patients with periampullary tumors, our study suggested that PBD should not be part of the routine medical approach to surgical candidates unless for cases with high bilirubin levels (\geq 20 mg/dl) or expected delayed surgery.

356

A NOVEL INTRAOPERATIVE NAVIGATION SYSTEM FOR LAPAROSCOPIC LIVER RESECTION USING REAL-TIME VIRTUAL SONOGRAPHY

Sakata Koichiro¹, Kijim Taiki², Arai Osamu³

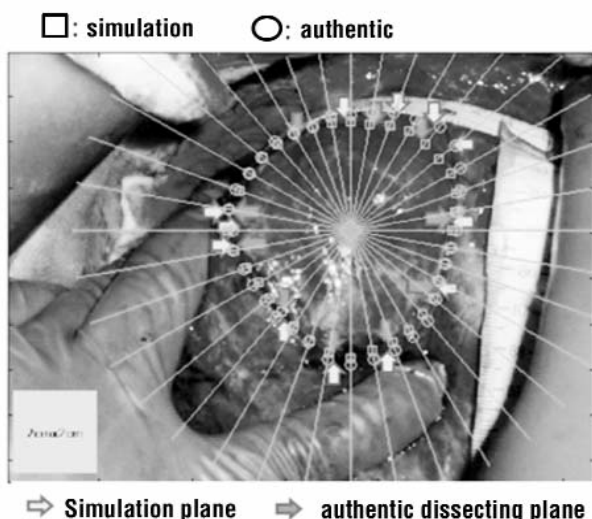
¹Japan Seafares Relief Association Ekisaikai Moji Hospital, Kitakyushu, Japan

²JCHO Shimonoseki Medical Center, Shimonoseki, Japan

³Hitachi Co. Ltd., Tokyo, Japan

Object: Recent progress of intraoperative navigation revealed problems about non-rigid registration of liver deformation and respiratory movement for hepatic surgery with laparotomy. Popularization of laparoscopic liver surgery, a new laparoscopic navigation system are expected.

Materials and Methods: In vitro demonstration 3-dimensional (3D) printer model (Sony Global Manufacturing & Operations Corporation), and in vivo 4 patients with hepatic malignancies were involved in this study. Ultrasonography



(HI VISION Ascendus; HITACHI) with position detecting unit (EZU-RV3S; HITACHI) attached to the tip of the electrocautery devise was employed to mark the dissecting plane. 1. In vitro examination with a SONY's 3D liver model, EZU-RV3S attached 33cm and 13cm distance conditions from the tip of the electrocautery examined 8 times at two points respectively. 2. In vivo, The differences between the simulation plane and the authentic dissecting plane were conventionally investigated. Indices as to operative time, amounts of bleeding, and harmful events were investigated. **Results:** 1. In vitro, the errors of 33cm and 13cm distance model revealed 7.8 +/- 3.5mm (mean +/- SD), and 3.3 +/- 1.0 mm, respectively. 2. System could be used uneventfully in each operation. The mean differences of the dissection plane between the simulation and authentic procedures were within 10mm ranged from 0 to 22 mm. Patients were discharged without major complications. **Conclusion:** The feasibility and safety of the novel navigation system for laparoscopic hepatic surgery were confirmed.

357

A NOVEL RISK SCORE FOR PREDICTING POST-OPERATIVE OUTCOMES IN PATIENTS UNDERGOING WHIPPLE'S PANCREATODUODENECTOMY BASED ON PRE-OPERATIVE VARIABLES

Samrat Ray, Subhashish Das, Vivek Mangla, Shailendra Lalwani, Siddharth Mehrotra, Amitabh Yadav, Naimish Mehta, Samiran Nundy
Department of Surgical Gastroenterology and Liver Transplantation Sir Ganga Ram Hospital, New Delhi, India

Relevance: Morbidity following Whipple's pancreatoduodenectomy remains high despite advancement in post-operative care strategies. However, there is a lack of a

definitive objective pre-operative tool, based only on clinical and biochemical parameters to predict the outcome following pancreatoduodenectomy that could be implemented on an outpatient basis.

Object: To study the pre-operative risk factors affecting the surgical outcome in patients undergoing pancreatoduodenectomy and develop a simple risk scoring model.

Materials and methods: The relevant pre-operative (demographic, clinical and biochemical) and post-operative data of all consecutive patients who underwent Whipple's pancreatoduodenectomy between 2006 and 2016 was retrieved from the electronic database. The patient population was divided into two groups based on the Clavien-Dindo (CD) grading and post-operative length of stay (LOS) as favourable (CD≤II and LOS ≤10 days) and unfavourable (CD>II and/or LOS >10 days). Using a multivariate regression model, the significant predictors of post-operative outcome were identified, and a risk score developed by binary logistic regression method. This was validated in a set of prospective patients using double blinding by the investigators. The model's predictive accuracy and discriminative ability were assessed using the receiver operating characteristics (ROC) analysis and Hosmer-Lemeshow goodness of fit tests respectively.

Results: Of the total 442 patients in the retrospective cohort, 177 had an unfavourable outcome (40%). On multivariate analysis, the significant predictors of post-operative outcome were identified as peak bilirubin levels, pre-operative stenting and diagnosis (benign/malignant). A risk score was derived and validated on the prospective cohort (n=51) [Table 1]. The mean risk for an unfavourable outcome was 24% for a score of 7 or less, 44% for a score between 8 and 14 and 70% for a score of 15 and above. This was further tested on the validation cohort for the individual risk scores (AUC=0.614) and the scores categorised (AUC=0.608).

Conclusion: The risk score showed a moderately fair accuracy in predicting post-operative morbidity in patients undergoing pancreatoduodenectomy. Therefore, this can be proposed to be used as a quick aid to predict the operative outcome in patients posted for pancreatoduodenectomy on an outpatient basis using simple pre-operative clinical and laboratory variables. Further validation is however required in a larger cohort of patients to determine its discriminative ability on a long run.

Table 1 - Pre-operative risk scoring model

Variable	Categories	β coefficient	P value	Risk score
Peak Bilirubin	< 2 mg/dl	0.006	0.001	0
	2-5 mg/dl			1
	5-10 mg/dl			3
	10-20 mg/dl			7
	>20 mg/dl			11
Stenting	Unstented	1.143	<0.001	0
	Stented			9
Diagnosis	Benign	0.661	<0.001	0
	Malignant			5
				Σ= 25 (max)

*Peak bilirubin <2 mg/dl, unstented with a benign aetiology considered as the reference base.

358

DIAGNOSIS AND SURGICAL TREATMENT OF LIVER ECHINOCOCCOSIS COMPLICATED BY CYSTIBILIARY FISTULAS

D. Sapaev, R. Ruzibaev, P. Ruzmatov, F. Yakubov

Department of General Surgery, Traumatology and Orthopedics, Urgench Branch of Tashkent Medical Academy, Ministry of Health of the Republic of Uzbekistan, 220100, Urgench city

Actuality. One of the specific problems of liver echinococcosis is the problem of cystobiliary fistulas, which is, most often, the result of intrabiliary breakthrough of cysts. Currently, cystobiliary fistulas are found in about 10 - 25% (Prousalidis J., co-authored., 2009). Postoperative complications are associated with the presence of cystobiliary fistulas, unnoticed or not hermetically eliminated during surgery. External biliary fistulas and bile ducts are the most common postoperative complications in patients with cystobiliary fistulas. If the bile from the residual cavity continues for 10 days or more, it is defined as a bile fistula (Kayaalp C. co-authored., 2002). Therefore, during the operation, the main point is the elimination of bile fistula.

The purpose of the study. Optimization of diagnosis and surgical treatment of cystobiliary fistulas and its prophylaxis in the postoperative period in patients with liver echinococcosis.

Materials and methods: During the period from 2010 to 2017, 231 patients underwent surgical treatment for liver echinococcosis in the department of the abdominal surgery of Khorezm regional multiprofile centre, which is the clinical base of the general surgery department of Urgench branch of Tashkent Medical Academy. In 28 patients with liver echinococcosis, fistula are identified. Cystobiliary fistulas (CBM) can be explicit (more than 5 mm) or occult (less than 5 mm) (Yildirgan M.I., co-authored., 2003). Studied patients were divided into two groups according to the Yildirgan M.I. classification (co-authored., 2003) The first group consisted of 20 patients who had a fistulous opening in a fibrous capsule up to 5 mm in diameter (occult). The second group consisted of 8 patients who had a fistula diameter of more than 5 mm (apparent). In patients of the first group during surgery at the bottom of the cavity, a CBM with a diameter of up to 5 mm was found. From them, primary echinococcosis was in 16 (80%) patients, relapsing - in 4 (20%) patients. A single liver cyst was detected in 13 (65%) patients, multiple cysts - in 7 (35%) patients. One patient had a CBM fluctuation from 1 to 5 pcs. In 16 patients, based on the data of ultrasound, CT, as well as laboratory studies before the operation, it was not possible to detect the presence of a bile fistula was not revealed. The presence of internal fistulas in these patients was determined only intraoperatively, after treatment of the fibrous capsule with a solution of furacillin. The mouth of the bile fistula was sutured with hermetic atraumatic suture materials No. 4,0 -5,0. Devastation measures in the residual cavity were carried out with 5% solutions of iodine and 96%

alcohol. In 13 patients, closed echinococcectomy was performed, 6 of them underwent partial cystpercystectomy, and in 3 cases a semi-closed echinococcectomy was carried out. In 4 patients of the first group, were associated complications in which suppuration and bile fistula were observed, in one of them in addition, a breakthrough into the pleural cavity was revealed. In patients with combined complications in the preoperative period, general weakness, malaise, subicticity, an increase in temperature to 38.5 ° C were observed, besides, one patient had chest pain and a dry cough. Leukocytosis was - up to 13000. In 2 patients with combined complication, closed echinococcectomy was performed, in 2 patients - half-closed echinococcectomy. The residual cavity was treated with 5% iodine solution and 96% alcohol. In the second (8) group of patients during the operation at the bottom of the cavity, a CBM with a diameter greater than 5 mm was found. Three patients were previously operated with liver echinococcosis. Of them - 1 patient was diagnosed with a bile-bronchial fistula, which broke into the right pleural cavity. The patient was operated on twice for this pathology. A patient with a bile-bronchial fistula complained of dull pain in the right hypochondrium, nausea, vomiting, shortness of breath while walking, dry mouth and general weakness. During auscultation - in the lungs weakening of breathing, with percussion - on the right, starting with IV-V intercostals space and dullness were revealed. Diagnosis before surgery showed echinococcal cyst of the right lobe of the liver (S-VIII) and reactive pleurisy on the right side. The operation on the antero-lateral thoracotomy on the right, right sided lower lobectomy, elimination of the bile fistula, echinococemia of the liver through the defect of the diaphragm in a semi-closed way and drainage of the right pleural cavity was performed. In 2 patients, an erupted echinococcal cyst was detected in the intrahepatic passages, and one patient had a relapsing cysts with a diameter of 0.8 to 1.0 cm, from which the echinococcal fluid is released and enters into the bile holes. The fistula is located on the projection of the bed of the gallbladder and VII-VIII segments. These patients on admission complained of jaundice of the skin, redness of urine, pain in the right subcostal area, decreased appetite, general weakness. Biochemical blood test showed total bilirubin - 112.8 - 342.4 mmol / l, bound - 80.6 - 212.8 μmol / l, free - 32.2 - 129.6 μmol / l, ALT - 0.82 - 1,7 units / l, AST - 50 units / l, sugar - 7.02 - 11.33 mmol / l. The general analysis of the blood: leukocytes - 7500 - 8700, ESR - 32-40 mm / h, Hb - 75 - 102 g / l, eosinophil - 10. Diagnosis before surgery is echinococcal cyst of the right lobe of the liver, complicated by mechanical jaundice, diabetes mellitus type II. A simulant operation was performed for the elimination of the biliary fistula using a patch made of a fibrous capsule, closed echinococcectomy with partial pericystectomy, cholecystectomy and external choledochostomy. On the remaining 5 patients with SBM in a diameter of 0.6 to 0.7 mm were carried out closed echinococcectomy, elimination of the biliary fistula using a patch made of a fibrous capsule. All the patients who made semi-closed echinococcectomy, residual cavity was washed

through drainage tubes with decassane solution. In addition, all patients received antibacterial, detoxification therapy and hepatoprotectors to improve liver function.

Results. In the first group of patients, the postoperative period proceeded smoothly. In 15 patients, the temperature of the body was increased up to 38 OC for the first 3 days after the operation. Leukocyte and ESR amount were normalized. In control ultrasound research in the first group of patients (20 patients), pathology was not detected. In 5 patients who underwent half-closed echinococectomy, no free fluid was found in the residual cavity. From the drainage tube for 5 ± 1 days there were discharges serous-hemorrhagic character. Operating wounds healed with the initial tension. The average stay of patients in the hospital was 9 ± 1 days. Postoperative complications were noted in 2 (7.1%) observations: suppuration of the residual cavity in 1 (3.55%) of the patient, bleeding from the spike in the abdominal cavity in 1 (3.55%) of the patient. All these complications were eliminated by surgical interventions. In the second group of patients, the postoperative period proceeded relatively smoothly. Leukocyte and ESR findings were normalized within 3 days. In biochemical analysis after 2-3 days the amount of bilirubin, ALT and AST was gradually decreased and normalized on the day 5. In control ultrasound diagnoses, a moderate accumulation of fluid in a volume of 10-15 ml was detected in the residual cavity in the second group of patients (8 patients). One patient had serous-hemorrhagic character discharge from the drainage tube within 7 ± 1 days. Operating wounds healed with the initial tension. The average stay of patients in the hospital was 12 ± 1 days. In patients of both groups, bile leakage from the drainage tube was not observed. Drainage tubes from the residual cavity were removed one month after the ultrasound examination. After the operation, all patients underwent adjuvant chemotherapy. After discharge from the hospital, patients underwent ultrasound of the liver 6-12 months after the operation. Only one patient had a relapse after 3 years.

Conclusion: In the case of gallbladder fistulas less than 5 mm "occult", after suturing with atraumatic sutures, the residual cavity can be completely eliminated. Fistula with a diameter of more than 5 mm is evident, fibrotic capsules in the form of a patch were used to eliminate and fully seal the fistula, which gives a good effect in relapse of the bile fistula. In our experience, all operations in which a fibrous patch was used were with a favorable outcome. At the same time, decompression of choledoch is mandatory. These interventions in the postoperative period allow achieving full recovery of patients.

359

SIGNIFICANT PROGNOSTIC BIOMARKERS OF DISEASE-FREE SURVIVAL OF PATIENTS WITH COLORECTAL CANCER

Eiji Sasaki

Japan

Relevance: colorectal cancer, prognostic biomarker, Onodera's prognostic nutritional index

Object: To clarify significant prognostic biomarkers for patients with Stage I, II, and III colorectal cancer (CRC).

Methods: A total of 166 patients with Stage I, II, and III CRC who underwent R0 resection were included. We investigated the relationship between the preoperative routine blood data, and disease free survival (DFS) using univariate and multivariate analysis.

Results: Univariate analyses showed that pathological lymph node metastasis (pN), serum albumin level, lymphocyte count, the neutrophil-to-lymphocyte ratio (NLR), Onodera's prognostic nutritional index (PNI), modified Glasgow prognostic score (mGPS) were significantly correlated with DFS. The multivariate analysis revealed that pN and Onodera's PNI were significant factors for DFS ($p=0.0120$ and $p=0.020$, respectively).

Conclusions: Onodera's PNI was a significant long-term prognostic factor for patients with who underwent R0 resection for Stage I/II/III CRC.

360

MONITORING IN REAL-TIME MODE OF DYNAMICS OF RESISTANCE AND LANDSCAPE OF MICROFLORA FOR THE RATIONALIZATION OF ANTIBACTERIAL THERAPY IN A MULTIDISCIPLIC CLINICAL HOSPITAL

D. Seliverstov^{1,2}, D. Khubezov^{1,2}, E. Lezhneva¹, V. Yudin^{1,2}, T. Bystrova¹, V. Biryukov³, I. Savkin^{1,2}

¹Ryazan State Regional Clinical Hospital, Ryazan, Russia

²Ryazan State Medical University, Ryazan, Russia

³Ryazan State Clinical Diagnostic Center, Ryazan, Russia

Relevance. The problem of increasing the resistance of hospital and "introduced" microflora to used antibacterial drugs (ABD) remains unresolved in all clinics around the world, so the acute issue is the development of clinical information automation systems (CIAS) that allow real-time changes microflora, microbial landscape and rationalize antibacterial therapy (AT).

Aim. Develop a clinico-automated system that allows monitoring in real time dynamics of changes in resistance of microflora and microbial landscape and rationalize antibacterial therapy in a multidisciplinary clinical hospital

Materials and methods. Since 2013, the program and the database "Microflora" have been created and effectively

used by the RSRCH. Microsoft Visual Foxpro 9.0 was chosen as the development environment for the program and the database, SQL queries are used for analysis, the reports are uploaded to the Microsoft Excell format. The initial data of the program are the forms of specific analyzes of the microflora of patients, indicating the specific pathogens and their sensitivity to the list of ABD. The program uses 4 main directories with the possibility of editing by the user (1-bio-materials; 2-diagnoses; 3-pathogens; 4-ABDs). Based on the data entered, the following types of analysis are performed: 1. Determination of the number of studies carried out in the context of the biomaterial taken. 2. Determination of the isolated microflora with the number of positive analyzes for each pathogen. The sensitivity of the selected microflora to the list of ABDs with the calculation of the percent of sensitive tests. 4. Selection of the optimal ABT in the MDCH, taking into account the revealed sensitivity to ABD (in the section of the departments, nosological forms).

Results. In just 5 years, 15310 microbiological studies of various biological materials were performed. The analysis of the nature and sensitivity of a clinically significant microflora made it possible to divide the ABD groups used in the MDCH into 5 groups: 1- ABDs for starting empirical therapy before obtaining the results of microbiological studies (this is an ABDs with a sensitivity of microflora from 70 to 100%); 2- ADDs of the 1th row (are applied at inefficiency of ABDs 1st group); 3- ABDs of the 2nd row (used when changing the microbial landscape and the need to change the ABT, the sensitivity of the microflora should be from 70% and higher), 4 - ABDs of the reserve group (sensitivity of the microflora from 70 to 100%), 5 "Forbidden" to the use of ABDs, sensitivity to which is 30% or less). ABDs of the 5 th group are transferred to the 2nd or 3rd group when the sensitivity of the microflora is restored to them more than 70%, in the 1st group - from 70 to 100 %.

Conclusions. The developed system of SIAS with the appropriate software allows: - prevent the development of pan-resistance to ABDs in the MDCH; - rationally plan the purchases of ABDs by MDCH for the next year; - to reduce the costs of the MDCH for the purchase of ABDs by 30-35%; -to reduce the average duration of the completed clinical case in the by 22-26%.

361

EFFECT OF PALLIATIVE GASTRECTOMY (PGE) IN METASTATIC GASTRIC CANCER ON SURVIVAL

N. Semenov, M. Tsarev, K. Dalgatov, D. Kuzmicheva, D. Koshelev, A. Kurskov

N.I. Pirogov First City Clinical Hospital, Moscow, Russia

Introduction: Indications for palliative gastrectomy in metastatic gastric cancer are still contradictory. The parameters of overall survival, time to disease control in pts.

with metastatic gastric cancer, were analyzed. Arm A included pts. with PGE after effective chemotherapy, and was compared with a group of pts. (Arm B) with metachronous metastases, or for which PGE was not performed for various reasons, with the tumor growth control on chemotherapy > 3 months.

Materials and methods: In Arm A with PGE was included 10 pts., in Arm B - 17 pts. (8 with metachronous metastases). Male/female - 18/9, the average age is 62 years, the ECOG is 0-1. At baseline metastases in the liver - 11 (5/6) pts., peritoneum/pleura - 10 (5/5), lymph nodes - 3 (0/3) pts., brain 1 (0/1) pts, local recidive - 2 (0/2) pts, ovaries 1 (1/0) pts., bones -1(0/1) pts. At baseline 1 metastatic zone - 9 pts. (all Arm B), 2 metastatic zone - 16 pts. (9/7), 3 metastatic zone - 2 pts (1/1). I line regimens: platinum/fluoropyrimidines - 19 pts, FOLFIRINOX - 2 pts, FLOT - 1 pt, FOLFIRI/XELIRI - 3 pts., Paclitaxel + Capecitabine - 1 patient. Chemotherapy in II line received 14 pts.: Arm A 70%, Arm B 41.2%. Regimens: Cisplatin/Capecitabine - 3 pts., XELIRI - 6 pts., Paclitaxel/Capecitabine - 5 pts.. Also 6 pts. received Bevacizumab.

Results: with a median follow-up of 26 months, the time to progression in the I line was 8,1 (CI 2.7-13,5) months in Arm A and 4,1 (CI 3,9-4,3) months in Arm B ($p = 0,052$), the time to progression of I and II lines was 14,8 (CI 13,5-16,0) months and 6,3 (5,0-13,0) months, respectively ($p = 0,004$). Overall survival was 21,1 (CI 13,5-28,7) months and only 7,1 (0,3-13,8) months, respectively ($p = 0,009$, RR 0,46).

Conclusions: The obtained results demonstrated a significant increase in overall survival in pts. who received palliative gastrectomy after effective chemotherapy. Investigation of influence of palliative gastrectomy on survival will be continued.

362

HEPARIN-INDUCED THROMBOCYTOPENIA IN MULTI-DISCIPLINARY HOSPITAL: THE ORIGINAL DIAGNOSTIC "RULE" AND NEW TREATMENT ALGORITHM IS ABLE TO REDUCE MORTALITY RATE (A 3-YEAR STUDY)

N. Semigolovski¹, S. Semigolovski²

¹Sokolov' Hospital No122 of Federal Medical and Biological Agency, ²Sankt-Petersburg State University

Introduction. Heparins are one of the most frequently prescribed drugs in the world due to PE prophylaxis and treatment, just as heparin prevention "bridge" often used perioperatively in those constantly receiving oral anticoagulants. Heparin-induced thrombocytopenia (HIT) is an immune-mediated life-threatening complication, accompanied by paradoxical thrombosis and high mortality rate (up to 30%). Immunodiagnosics of HIT is rather expensive. Existing scales of probability of HIT (for coronary shunting; expert Scale HEP and Scale "4-x T") are too difficult, have

low specificity and lead to overdiagnosis. Our aim was to determine the incidence of HIT in multidisciplinary hospital before and after implementation of the original diagnostic "Rule" - "100-5-100" (that means "decrease in platelet counts less than $100 \times 10^9/L$ on the 5-th day of Heparins use or within 100 days of their previous use") and new Algorithm of HIT treatment (including Fondaparinux sodium as alternative anticoagulant).

Patients, materials and methods. At the beginning of 2014 the stuff have been informed in original "Rule" (see above) and Algorithm. Patients were studied by electronic medical Records before the implementation of the "Rule" and Algorithm ("control group" hospitalized from 01.01.2013 to 31.01.2013) and after its implementation ("comparison group" - those hospitalized from 01.01.2014 to 31.12.2015). In some cases HIT diagnosis was confirmed by a method of immunoturbidimetry (ACL TOP 700).

Results. We identified severe thrombocytopenia in 5018 blood samples obtained in 950 patients (1.3% of admissions). 382 of them received Heparins (40.2%). The implementation of "Rule" and Algorithm was accompanied by a decrease in the HIT incidence in 2014-2015 about 2 times compared to 2013. That was particularly noticeable in the departments of cardiac surgery, traumatology, urology and vascular surgery, as well as in intensive care units (ICU). There was a significant decrease in mortality rates in ICU patients from 26.1% in 2013 to 9.8% in 2014 ($p < 0.05$) and 7.5% in 2015 ($p < 0.05$). No noticeable dynamics in patients with "non-heparin" thrombocytopenia was observed.

Conclusion. The use of the original "Rule" of HIT diagnostics and treatment Algorithm contributed to a decrease in the HIT incidence and the frequency of complicated HIT, which was manifested by a significant decrease in the number of such cases in the ICU with a statistically meaningful reduction in mortality rates. Sodium fondaparinux is an affordable, effective and safe drug of choice in the treatment of HIT.

363

ROBOT-ASSISTED TRANSMEDIASTINAL (NON-TRANSTHORACIC) RADICAL ESOPHAGECTOMY FOR ESOPHAGEAL CANCER

Yasuyuki Seto

Japan

Background: Surgical treatment is still main stream for esophageal cancer. In radical esophagectomy, three fields' lymph node dissection, cervical, mediastinal, and abdominal regions, is standard procedure. Frequent complications after radical esophagectomy are well known. Japanese nationwide database (National Clinical Database) shows that 1/3 patients underwent the esophagectomy by MIE (minimally invasive esophagectomy), while the conventional open pro-

cedures were done among 2/3 patients. According to those results, the morbidity was significantly less in open group than MIE group. MIE was shown to fail to decrease the morbidity. Therefore, the prevention of post-operative complications, especially pneumonia, is most important issue yet.

Methods: With the aim of achieving lymph node dissection equivalent to the conventional procedure (open or VATS) and decreasing the development of post-operative pulmonary complications simultaneously, we developed the novel procedure, non-transsthoracic radical esophagectomy by using da Vinci. It is the combination of transhiatal robotic manipulation for the middle and lower mediastinum and a video-assisted transcervical procedure for the upper mediastinum.

Results: That procedure has been performed in 88 cases with esophageal cancer, to date. Among them, the post-operative pneumonia occurred in 1 case and the number of harvested mediastinal lymph nodes was equal to the conventional open surgery. Furthermore, the QOLs after surgery were observed to be better as compared to the conventional groups.

Conclusions: robot-assisted transmediastinal radical esophagectomy offers a new radical procedure for esophageal cancer.

364

RESULTS OF CORRECTION OF NEPHROPTOSIS WITH THE USE OF DIFFERENT TYPES OF IMPLANTS. CLINICAL AND EXPERIMENTAL RESEARCH

L. Sevastyanov, N. Abatov, Y. Assamidanov,

G. Essenbaeva

Karaganda State Medical University, Kazakhstan

For the correction of nephroptosis, most often use synthetic implants. A number of problems associated with the implantation of synthetic material in the human body remains unresolved, namely: the reaction of rejection of a foreign body with the formation of infiltrates, weak resistance to infection, the impossibility of intraperitoneal use due to the massive adhesive process and the risk of erosion of the walls of hollow organs. The need to select the optimal synthetic implant and search for alternative materials that would minimize the risks of complications without decreasing the functionality and, consequently, improve the quality of life of the patient after the operation, justify further research in this direction. The goal of the study was to study the results of the correction of nephroptosis with the use of various types of implants in a clinical and experimental study. The experimental study was performed on rats. In the first group, the decellularized matrix of the xenogeneic peritoneum was used, in the second group a polypropylene mesh, the third partially resorbable "UltraPro" mesh, and the fourth one - its own peritoneal fascial flap. In the clinical part of the work: in the

first group of patients for nephropexy, we used our own peritoneal fascial flap (n = 15), in the second group, the partially-resorbable "UltraPro" mesh (n = 10), in the third-polypropylene implant (n = 41). The peritoneal-fascial flap, the matrix of decellularized xenoperitoneum, and the "UltraPro" mesh are biocompatible and do not generate manifest forms of hyperergic immune reaction in the rat tissue, as indicated by a significant step-specific decrease in granulocytes. In all cases of fixation with a decellularized xenoperitoneum shape and size of the kidneys do not change, the kidney remains soft elastic, the color of the kidney tissue and architectonics remain the same, connective tissue bands was soft, adhesive process was not expressive, the mobility of the kidney is preserved. Polypropylene mesh leads to more pronounced inflammation and to formation of a more "rough" scar. After the operation revealed that the mobility of the kidney when fixing "UltraPro" and peritoneal-fascial flap corresponds to the mobility of the organ on the healthy side, the density of paranephric fiber and renal parenchyma, in the implant zone is much lower than in the group of patients with polypropylene mesh. After 6 months in all patients with the use of "UltraPro", the latter according to ultrasound and CT was not determined; in patients operated with a polypropylene mesh, the presence of it was confirmed in 44.4 percent of cases. The quality of life tended to increase with the increase in the postoperative period and was comparable in all groups. Thus, the combined mesh "UltraPro" and peritoneal-fascial flap are the optimal variants of kidney fixation in nephroptosis. The use of a matrix of decellularized xenoperitoneum is of interest and requires further study.

365

COLORECTAL STENTING AS A METHOD FOR TREATMENT OF ACUTE LARGE-BOWEL OBSTRUCTION OF NON-NEOPLASTIC GENESIS

A. Shabunin, Z. Bagatelia, D. Grekov, I. Korzeva, A. Gugnin

Botkin Hospital, Moscow, Russia

Goal: to improve the results of treatment of patients with bowel obstruction in the setting of non-neoplastic stricture of large-bowel through the application of stenting of stenosis area.

Methods and materials. The results of clinical observation of 7 patients with acute bowel obstruction were estimated during the retrospective study analysis. The patients received medical treatment in the surgical clinic of S.P. Botkin City Clinical Hospital from 2010 till 2017. The patients were distributed according to the severity of large-bowel obstruction: subcompensated form – 3 (42,9%), decompensated form – 4 (51,7%). Colorectal stenting of non-neoplastic stricture of enteroenteroanastomosis was carried out in 4 cases, in 3 cases on patients in the setting of diverticular

disease of sigmoid colon. Carrying out of endoscopic interference was necessary because it allowed to reconstruct lumen of the organ and to ensure evacuation of bowel before the surgery. 7 nitinol self-expanding colorectal stents with the diameter of 20-22 mm. were installed: «HANAROS-TENT, M.I.Tech», (4) and «TaeWoong Medical», (3) (South Korean manufacture).

Results. Technical success was achieved in all 7 cases with colorectal stenting. The result of installation of colorectal stents was the restoration of bowel patency in all 7 (100%) patients. The results of treatment of patients: average amount of days in the hospital - 6,5+/-1,2. In 1 case (14,3%) there was a dislocation of colorectal stent, which was later by means of the endoscopy. There were no fatal cases after the application of the described method.

Conclusion. On the basis of the received results of treatment of patients it was concluded that endoscopic stenting is followed by the small amount of postoperative complications and lack of fatal cases. Endoscopic stenting allows to shorten the length of in-hospital stay. The method of installation of self-expanding colorectal stents is an effective and low-trauma method of elimination of large-bowel obstruction, which can improve the quality of patients' life. The application of colorectal stenting is a perspective method. It helps to obtain good results.

366

MINIMALLY INVASIVE TECHNOLOGIES IN THE TREATMENT OF PATIENTS WITH GASTROINTESTINAL BLEEDING

A. Shabunin, V. Tsurkan, A. Arablinskiy, V. Bedin, Parfenov Igor' Pavlovich, Z. Bagateliya

Botkin Hospital, Moscow, Russia

Relevance: Gastrointestinal (GI) bleeding is one of the most frequent causes of emergency hospitalization. There is a tendency to increase the frequency of this pathology. Bleeding from the upper gastrointestinal tract reaches 85% of all GI bleeding. Despite the success of medicine, lethality in the conservative therapy group reaches 14-20%, and in the operated patients group exceeds 20%. In this regard, the wideness use of minimally invasive interventional treatment seems promising.

Purpose: To evaluate the safety and efficacy of endovascular occlusion in patients with GI bleeding.

Materials and methods: From January 2015 to May 2018, 35 pts with GI bleeding (17 men and 18 women) were enrolled in the study, the age ranged from 22 to 87 years (median age 57 years [54, 64]). The causes of bleeding were malignant neoplasm of the pancreas (n = 9), malignant gastric neoplasm (n = 8), peptic ulcer (n = 13), malignant neoplasm of colon (n = 1), malignant neoplasm of rectum (n = 1), benign disease of hepatopancreatoduodenal zone (n =

3). All 35 patients underwent conservative therapy and endoscopic hemostasis. 16 pts had a high risk of recurrence of GI bleeding, despite the effectiveness of conservative therapy, 19 pts had symptoms of acute GI bleeding. Diagnostic visceral angiography was performed to verify vascular anatomy, detect bleeding symptoms and the possibility of endovascular occlusion (n = 35).

Results: At the diagnostic stage, the intervention was completed in 16 pts due to the absence of angiographic signs of bleeding (n = 9) or the technical impossibility of catheterization of the afferent vessel (n = 7). 19 pts showed signs of continuing bleeding: extravasation of contrast medium (n = 6), indirect signs of bleeding (n = 13). 21 endovascular interventions were performed: left gastric artery embolization (n = 12), gastroduodenal artery embolization (n = 3), embolization of the branches of the superior mesenteric artery (n = 3), embolization of the branches of the inferior mesenteric artery (n = 1), splenic artery embolization (n = 1), right gastric artery embolization (n = 1), as an embolizing material: polyvinyl alcohol (PVA) particles (n = 8), coils (n = 3), a combination of PVA particles and coils (n = 10) were used. Technical success was achieved in all 19 patients with angiographic signs of acute GI bleeding. No complications of endovascular procedure were observed. In the postoperative period there was no signs of GI bleeding. All patients were discharged within 5 to 8 days with improvement.

Conclusion: Interventional treatment of acute GI bleeding is minimally invasive, safe, effective and low-traumatic procedure in patients with a high risk of recurrence of GI bleeding or ongoing acute GI bleeding.

endoscopy.

Materials and methods. 61 patients with the various locations esophageal diverticulum underwent surgery in the Esophagus and Stomach Surgery Department of Petrovsky National Centre of Surgery in 2014-2018. The patients were divided into two groups: with the intraoperative intraluminal endoscopic assistance (IIEA) (n=18) and without (n=43). The same specialist performed pre- and intraoperative endoscopy of the esophageal diverticulum. IIEA aimed to define diverticulum location, size, wall and mucous membrane state by insufflation and transillumination. Diverticulectomy was performed by linear stapler under endoscopic control and provided visual inspection of its completeness and absence of esophageal mucous membrane deformation.

Results and discussion. Results of the Research Control X-ray studies with a water-soluble contrast took place on the second-third day after the surgery. In the group with the IIEA there were detected neither leakages, constrictions of the esophagus lumens nor recess and other deformations of the esophagus wall. In the control group leakage was identified in 2 cases in the early postoperative period and was eliminated by conservative treatment. Recurrent diverticulum occurred after six months follow up in two patients of the control group.

Conclusion. The combination of the intraoperative intraluminal endoscopy with surgery makes it possible to reduce the operation time due to the faster diverticulum detection and its visualization, to avoid any deformation of the esophagus lumen, to minimize potential complications, which provides better results of the surgical treatment.

367

EXPERIENCE OF SURGICAL TREATMENT OF PATIENTS WITH ESOPHAGEAL DIVERTICULUM OF VARIOUS LOCATIONS IN CONJUNCTION WITH INTRAOPERATIVE INTRALUMINAL ENDOSCOPIC ASSISTANCE

M. Shakhbanov¹, I. Boeva¹, T. Bitarov¹, A. Tskhovrebov¹, I. Tarasova^{1,2}, I. Bulganina¹, D. Shatveryan¹, A. Shestakov^{1,2}

¹*Petrovsky National Centre of Surgery, Moscow, Russia*

Introduction. Esophageal diverticulum is 0,5 - 7,7% of esophagus diseases and, as a rule, requires surgical treatment. While such interventions may be technically difficult and be associated with development of complications and postoperative recurrences. Intraoperative intraluminal endoscopic assistance should be considered as the way of improving treatment of patients with esophageal diverticulum.

Research Objective. To improve the results of esophageal diverticulum surgery by intraoperative intraluminal

368

VERIFICATION OF THE DIAGNOSIS IN ACUTE PAIN IN THE HIP JOINT IN CHILDREN

A. Shamsiev, J. Shamsiev, Z. Makhmudov, M. Burgutov, S. Igamova

Samarkand State Medical Institute, 2-nd Clinic of Samarkand State Medical Institute, Samarkand, Uzbekistan

Among nosology forms of acute surgical infection severity difficulty of diagnosis and adverse outcomes of a dominant position belongs acute osteomyelitis of the hip joint. The purpose of our work was to develop objective criteria for the early diagnosis of acute osteomyelitis of the hip joint in children

Materials and methods. To solve this problem, we carried out a survey of 61 children with osteomyelitis of the hip joint aged 4 to 15 years who were hospitalized in the department of purulent surgery of the 2-nd Clinic of Samarkand state medical institute for the period from 2004 to 2016. For the differential diagnosis with other inflammatory diseases of the hip, examined 32 patients with acute reactive children

coxitis. All patients received complaints of pain and restriction of movement in the hip joint.

Results. In carrying out our work into account the following data: Toxicity index of blood. The principle of the method consists in determining the period of the death of paramecium (*Paramecium caudatum*), placed in the test serum. Leukocyte index of intoxication. Highest leukocyte index of intoxication observed in patients with osteomyelitis of the hip, a group of patients with reactive coxitis this indicator was the lowest. In the early stages of forty-one patients received complaints of severe pain in the hip, for differential diagnosis used computer tomography. The primary focus of osteomyelitis in 21 children is localized in the bones forming the hip joint, and 20 children osteomyelitis was excluded and diagnosed reactive coxitis.

Conclusion. Introduction to complex clinical and laboratory methods for diagnosis of acute osteomyelitis of the hip bones in children the toxicity index of blood, leukocyte index of intoxication and the use of computed tomography increases the possibility of differential diagnosis of purulent bone disease of the hip joint in the early stages of the disease. Thus, to choose the right tactics treatment and thereby decrease the terrible orthopedic complications.

369

EVALUATION OF THE RESULTS OF PHLEBECTOMY WITHOUT LIGATION OF INCOMPETENT PERFORATING VEINS IN PATIENTS WITH PRIMARY VARICOSE VEINS OF THE LOWER EXTREMITIES (5-YEAR FOLLOW UP PERIOD)

I. Shanaev

Ryazan Regional Clinical Cardiology Dispensary, Ryazan, Russia

Introduction: Current approach to operative treatment of varicose veins of lower extremities does not consider simultaneous interventions on perforating veins due to the fact that they restore their function following the surgery in majority of cases.

Aim of the work: to present results of 5-year follow-up study after phlebectomy without ligation of perforating calf veins in patients with C2-C3 class of varicose disease.

Material and methods: the surgical treatment was given to 101 patients with varicose disease presenting with CEAP clinical class: C2 n – 58, C3 n - 43. Localization and extent of venous reflux was evaluated with duplex scanning. Main characteristic of an incompetent perforating vein is presence of retrograde blood flow of more than 0.5 seconds. All patients underwent complete stripping and phlebectomy of saphenous veins for varicosity without ligation of incompetent perforants. Ultrasound duplex scans were used to confirm the condition of perforating veins after surgery during 5-year follow up period.

Results: Varicose tributaries of incompetent perforating veins were preoperatively marked and removed using Muller’s hooks in zone not more than 1 cm from perforating vein. Postoperative duplex scanning showed 1/3 of all perforating veins (surgery mainly resulted in Cockett ligation of perforating veins above muscular fascia). Visual signs of varicose disease weren’t noted at examination in most of the patients while duplex scanning showed retrograde blood flow on perforating veins during proximal compression was kept in 45,1 % cases.

Conclusions: 1. Shin perforating veins can restore their function after stripping and phlebectomy of saphenous veins for varicosity. 2. The main reasons that prevented the restoration of the perforant’s function were: large diameter and the presence of segmental reflux in the deep veins at the level of confluence of incompetent perforants.

370

POSSIBILITIES OF THE USE STANDART ULTRASOUND DUPLEX ANGIOSCANNING DEVICES IN THE DIAGNOSTICS OF MICROCIRCULATORY DISORDERS IN PATIENTS WITH VARICOSE DISEASE

I. Shanaev

Ryazan Regional Clinical Cardiology Dispensary, Ryazan, Russia

Introduction: Duplex ultrasound scanning (US) is a standard of examining patients with varicose disease (VD). With the help of US, the condition of superficial, deep, perforating (PV) can be assessed. However, modern examination can’t exist without an objective assessment of microcirculation (MCR), because it is the final link in the pathogenesis of trophic disorders. For evaluation of the MCR, the following can be used: vital capillaroscopy, percutaneous oximetry, laser dopplerography. In addition, the devices of the US of the latest generation have the possibility of mapping the microvascular bed (SMI mode). This regime allows to assess the level of the MCR with a high probability, but still indirectly. However, all these methods require additional equipment. Data on the state of the MCR in the field of trophic changes can be obtained with the help of a standard US device. According to the anatomy of the PV of the distal part of the medial surface of the lower leg are the main drainage vessels of the cover tissues of this region. Next to them there is an arterial branch (PA), which feeds the vascular wall of the PV on the epifascial level, fascia, hypodermis and dermis in this region: altogether these vessels form the microvascular bed. Therefore, the calculation of hemodynamic parameters of perforating vessels can provide information about the condition of the MCR.

Aim: to provide information about the condition of the MCR with common US device.

Materials and methods: the study included patients

presenting with CEAP clinical class of VD: 78-class C2, 39-C3, 52-C4, 26-C5/6. The study was performed on a Medison SonoaceX8. The state of superficial, deep, PV was determined. The blood flow along the PA was also analyzed: the spectrum was analyzed, systolic, diastolic velocities and RI were calculated.

Results: In the course of the study, the most frequently encountered were PV of the Cockett's group. When analyzing the blood flow along the PA, low RI numbers with an unchanged systolic peak and high diastolic velocities speeds have attracted our attention. In addition, pseudo-pulsating flow was detected in 50% of PV. According to the US standards, these are direct signs of arteriolo-venular shunting (AVS). Statistical analysis showed significant differences in this feature between classes C2 and C3 (1,0 and 0,9±0,1), C3 and C4 (0,9±0,1 and 0,83±0,1) and between classes C4 and C5/6, despite the fact that the figures varied (C4-0.83±0,1, C5/6-0.81±0,1), there was no statistically significant difference (P<0.05).

Conclusion: Using standard US devices, it is possible to obtain information on the state of the MCR in the zone of trophic changes.

371

DUPLEX ULTRASOUND ANGIOSCANNING DEVICES IN THE DIAGNOSIS OF MICROCIRCULATORY DISORDERS IN PATIENTS WITH VARICOSE DISEASE

I. Shanaev

Ryazan Regional Clinical Cardiology Dispensary, Ryazan, Russia

Introduction: Duplex ultrasound scanning (US) is a standard of examining patients with varicose disease (VD). With the help of US, the condition of superficial, deep, perforating (PV) can be assessed. However, modern examination can't exist without an objective assessment of microcirculation (MCR), because it is the final link in the pathogenesis of trophic disorders. For evaluation of the MCR, the following can be used: vital capillaroscopy, percutaneous oximetry, laser dopplerography. In addition, the devices of the US of the latest generation have the possibility of mapping the microvascular bed (SMI mode). This regime allows to assess the level of the MCR with a high probability, but still indirectly. However, all these methods require additional equipment. Data on the state of the MCR in the field of trophic changes can be obtained with the help of a standard US device. According to the anatomy of the PV of the distal part of the medial surface of the lower leg are the main drainage vessels of the cover tissues of this region. Next to them there is an arterial branch (PA), which feeds the vascular wall of the PV on the epiphascic level, fascia, hypoderma and dermis in this region: altogether these vessels form the microvascular bed. Therefore, the calculation of hemo-

dynamic parameters of perforating vessels can provide information about the condition of the MCR.

Aim: to provide information about the condition of the MCR with common US device.

Materials and methods: the study included patients presenting with CEAP clinical class of VD: 78-class C2, 39-C3, 52-C4, 26-C5/6. The study was performed on a Medison SonoaceX8. The state of superficial, deep, PV was determined. The blood flow along the PA was also analyzed: the spectrum was analyzed, systolic, diastolic velocities and RI were calculated.

Results: In the course of the study, the most frequently encountered were PV of the Cockett's group. When analyzing the blood flow along the PA, low RI numbers with an unchanged systolic peak and high diastolic velocities speeds have attracted attention. In addition, pseudo-pulsating flow was detected in 50% of PV. According to the US standards, these are direct signs of arteriolo-venular shunting (AVS). Statistical analysis showed significant differences in this feature between classes C2 and C3 (1,0 and 0,9±0,1), C3 and C4 (0,9±0,1 and 0,83±0,1) and between classes C4 and C5/6, despite the fact that the figures varied (C4-0.83±0,1, C5/6-0.81±0,1), there was no statistically significant difference (P<0.05).

Conclusion: Using standard US devices, it is possible to obtain information on the state of the MCR in the zone of trophic changes.

372

EVALUATION OF THE CLINICAL ANATOMY OF THE MOST IMPORTANT PERFORATING VEINS OF THE LOWER EXTREMITIES BY ANATOMICAL DISSECTION AND DUPLEX ULTRASONOGRAPHY

I. Shanaev

Ryazan Regional Clinical Cardiology Dispensary, Ryazan, Russia

Introduction: precise knowledge of venous anatomy is essential in phlebology.

Aim: to clarify the clinical anatomy of the perforating (PV) of the lower extremities.

Materials and methods: 70 amputated lower extremities were subjected to anatomical dissection and 2800 patients underwent ultrasonography (US).

Results: On the medial surface of the foot were found from 4 to 6 PV. They directly connected the medial boundary of the medial marginal vein and vv. plantaris medialis, located along the medial intermuscular septum. On the lateral surface of the foot were found from 2 to 3 PV. They connected directly, the inflow of the lateral marginal vein (which together with the main trunk of the lateral marginal vein forms small saphenous vein) and vv. plantaris lateralis. Topographically PVs passed behind the lateral muscle group of the foot along

the lateral intermuscular septa. Moreover both PVs had inflows which drained the subcutaneous tissue of the lateral and medial surfaces of the foot. The presence of muscle-venous pump of the lower leg complicates the structure of the PVs, among them are the direct, indirect, mixed. In the course of anatomical dissections, the most constant were the PVs located at the distance of 7-10 cm and 11-16 cm from the lower edge of the medial ankle. All of them were the main draining vessels subcutaneous adipose tissue of the medial ankle region. Each PV of the calf (direct and indirect) and of the foot was accompanied by arterial twig and it was often able to identify a twig from a nearby nerve. In most cases PV at the subfascial area were 2, located on the sides of the artery. Rare incidence of PV popliteal region (according to the US 0.4% and no case during preparation), combined with the lack of typical saphenopopliteal anastomosis can be attributed to atypical PV. PV fell into the popliteal vein at the lateral side, while the small saphenous vein fell into the upper 3rd of the tibia in the great saphenous vein (GSV) or fell into a vein Giacomini. In all cases, arterial twig was visualized near PV. During US examination the typical areas of localization of PV of the thigh were: middle third of the thigh – PV fell into the femoral vein at the level of the adductor canal, 83% - connects GSV and femoral vein; lower third of the thigh – PV fell into the popliteal vein, below the adductor canal, 74% connects GSV and popliteal vein. All PV passed along the medial intermuscular septa and were accompanied by an arterial branch from the femoral artery. The angle of confluence to the deep veins ~ 45°, subfascial course - 5 - 7 sm. Such features limit lower frequency of incompetence in patients with varicose veins but create higher risks of getting Babcock's probe in to the deep veins during performing phlebectomy in the antegrade introduction.

Conclusions: 1. PV mostly constitute the neurovascular bundles. 2. PV are primarily located along the intermuscular septa.

373

STRATEGY FOR THE TREATMENT OF ITBL AFTER LIVER TRANSPLANTATION

A. Shcherba, D. Fedaruk, D. Urlevich, D. Efimov, A. Fedaruk, S. Korotkov, A. Sauchenka, M. Katsin, A. Minou, O. Rummo

RSP Center for Organ and Tissue Transplantation, Minsk, Belarus

Biliary complications are a major surgical problem after liver transplantation, which occurs in 10-30% of patients.

Aim. To evaluate the results of different approaches for the treatment of ITBL after liver transplantation

Patients and methods. Between 2008 and March 2018, 539 liver transplantations were performed. The total number of

ITBL after LT was 3.9% (21/539): type I - 4, type II - 14, type III - 3. In 85.7% of cases the end-to-end anastomosis was applied, and in 14,2% - Roux-en-Y hepaticoentero-anastomosis was performed. In 38% of cases the biliary stent was placed to the site of anastomosis.

Results. The median age of the patients was 47 [31; 59] years; women-8 patients, men-13. The median time for occurrence of ITBL was 300 [180; 510] days after liver transplantation. In 14.2% of cases, ITBL was associated with hepatic artery thrombosis. The mean time of total ischemia was 480 [420; 495] minutes. Infectious complications were detected in 47.6% of these patients. Early formation of ITBL is significantly associated with the incidence of infectious complications (p = 0.05). There was no difference in the cholestatic tests in different ITBL subgroups, according to the Hintze et al. classification. The following methods were used for ITBL treatment: balloon dilatation of the anastomosis with or without stenting in 47.6% (10/21) of patients, percutaneous drainage - in 9.5% (2/21), conservative therapy - in 14.3% (3/21), the reconstruction of the anastomosis was performed in 4.7% of cases. Re- transplantation was required in 19% of patients. The overall survival of patients with ischemic type biliary complications was 71.5%.

Conclusion. Endoscopic and percutaneous minimally invasive operations are the main methods of treatment of ITBL after LT. They allow you to extend the time to reconstructive surgery and re-transplantation or completely avoid them.

374

REVASCULARIZATION TECHNIQUES IN LIVER TRANSPLANTATION FOR PORTAL VEIN THROMBOSIS AND STENOSIS: SINGLE CENTER EXPERIENCE

A. Shcherba, D. Urlevich, D. Fedaruk, D. Efimov, A. Fedaruk, S. Korotkov, A. Dzyadzko, M. Katsin, A. Minou, O. Rummo

RSP Center for Organ and Tissue Transplantation, Minsk, Belarus

Background: Liver transplantation is the only option for treatment of end-stage liver disease. Portal vein thrombosis (PVT) is a well-recognized complication of liver cirrhosis with reported incidence up to 24% - 32%. In patients with cirrhosis without PVT entering the LT waiting list, the 1-year reported de novo PVT is 7.4-8.4%. However, the incidence of LT performed in PVT patients ranges from 1.2% to 6.6%. The real impact of PVT on post-operative evolution is still under debate. Several approaches were proposed for LT in patients with PV thrombosis or stenosis: thrombectomy and eversion technique, vein transposition (reno-portal, cava-portal), interposition and jump graft, venoplasty and modification for atretic PV, shunt-to-portal anastomosis.

Materials and Methods: 508 liver transplantations had been performed in 2008–Nov. 2017. The overall rate of LT

for PVT was 6.1% (31/508). 2 groups of patients were formed: group 1- patients with PV reconstruction& thrombectomy and group 2 – patients with standard PV anastomosis.

Results: In PV reconstruction& thrombectomy group in adults median age was 56 vs 50 in group2 ($p=0.08$); median blood loss was 2000 vs 1200 [700; 1700] ($p = 0.06$), acute kidney injury occurred in 20% cases in group 1 vs 15,7% in group 2 ($p = 0.7$). Early allograft dysfunction was identified in 10% cases in group 1 vs 24.5% in group 2 ($p = 0.3$). Post-LT PV thrombosis occurred in 10% in group 1 vs 0,7% in group2 ($p = 0.07$). Post-LT PV stenosis was not verified in patient from group 1, while in group 2 its rate was 4.8%. Post-LT PV stenting in groups 1 and 2 was performed in 10% and 1,15%, respectively ($p = 0.04$). 1-year survival rate was 85% vs 93% ($p=0.2$), respectively. In pediatric patients median blood loss didn't differ in both groups; intra – and post-LT PV thrombosis occurred in 10% in group 1 vs 11.3% in group2 ($p =1$). Post-LT PV stenting in groups 1 and 2 was performed in 18% and 13,6%, respectively($p =0.6$). Acute kidney injury occurred in 9% cases in group 1 vs 18,2% in group 2 ($p =1.0$). Early allograft dysfunction was identified in 27.3%cases in group 1 vs 37,2% in group 2 ($p =1.0$). 1-year survival rate was 90% vs 86.4% ($p=0.9$), respectively.

Conclusion: PV reconstruction is still demanding procedure in LT and associated with higher rate of complications in adults. The results of LT in patients with PVT are comparable to patients without PVT when the procedure is thoroughly planned. The kind of PV reconstruction/thrombectomy must be adapted to the PVT grade, age, and presence of suitable shunts.

375

TENSOMETRIC CONCEPTION IN THE SURGICAL TREATMENT OF HERNIAS

Yu. Sheptunov¹, P. Vnukov²

¹*Voronezh State Medical University named after N.N. Burdenko, Voronezh, Russian Federation*

²*Elets city hospital No 2, Elets, Russian Federation*

Actuality. Tension is one of the most important phenomena in hernia surgery. This is one of the criteria in the classification of methods of surgical treatment. A large number of methods for reducing tension in the aponeurotic wound are proposed. However, it is impossible to completely avoid the tension of aponeurosis both during the operation and in the postoperative period. Tension is the functional value of aponeurotic tissue. Therefore, tension control, its prediction is an important and relevant problem of modern herniology.

Purpose. To study the effect of tension of the aponeurosis on the healing of aponeurotic suture in the experiment and on the basis of the received data to perform intraoperative tensometric evaluation of umbilical hernias.

Material and methods. The first part of the study is experimental. On 20 experimental animals (rabbits) the influence of tension on the healing of aponeurotic tissue was evaluated. In aponeurosis were formed holes of different sizes. Accordingly, when their suturing there was a certain tension. Further, on the 30th day of the experiment, macro and microscopic (hematoxylin-eosin) assessment of aponeurotic tissue healing was performed. A pincer device and a digital dynamometer were used to measure the tension in the wound. The study was carried out in accordance with the international rules of handling laboratory animals. In the second part of the study, intraoperative tension assessment in the aponeurotic layer of the anterior abdominal wall was performed in 25 patients with umbilical hernias. The width of the hernia gate was from 15 to 50 mm. To measure the tension, a piston-type device was used, which was calibrated on the Instron installation.

Results. In the course of the experimental study it was found that the excess of the aponeurosis tension in 0.4 MPa in experimental animals caused a failure of aponeurosis healing. It was found full or partial eruption of seams. The direction of the stitch did not affect the critical tension value. Microscopically, there were signs of alterative inflammation. Was performed intraoperatively register the tension in edge of the aponeurotic wound, the rate of which depended on the size of the defect in aponeurosis and the direction of the seam. The indicator tension ranged from 0.15 MPa to 0.74 MPa when the thickness of the aponeurosis from 0.8 to 1.2 mm. Thus, in 72% of the patients the tension index exceeded the threshold when reducing aponeurosis in the longitudinal direction and in 32% - in the transverse direction. And taking into account the patient's verticalization, the strain increases by an average of 0.15 MPa (calculated mathematically based on the 3D model), depending on the configuration of the abdomen. That is, in a third of patients to suture aponeurosis not exceeding the experimentally established critical level was impossible (both in the longitudinal and transverse direction).

Summary. 1. In the surgical treatment of all patients with umbilical hernias, the use of alloplasty is biomechanically justified. 2. When suturing of the fascia during the surgical intervention more justified transverse seams. 3. It is possible to use a piston device for wound tensometric assessment, which allows to obtain sufficiently accurate indicators. 4. It is necessary further strain and clinical studies to evaluate the possibility of using in practice obtained experimentally critical values of the tension of the aponeurosis.

376

OUTCOMES OF LIVING DONOR LIVER TRANSPLANTATION FOR PATIENTS WITH PREOPERATIVE PORTAL VEIN PROBLEMS

A. Shehta, M. Abdel Wahab, M. Elshoubary, T. Salah, O. Fathy, A. Sultan, A. Nabieh Elghawalby, M. Ali, M. Eldesoky, A. Monier, R. Said

Liver Transplantation Unit, Gastrointestinal Surgery Center Department of Surgery, College of Medicine, Mansoura University, Egypt

Relevance. Portal vein thrombosis (PVT) is a common complication for patients with end-stage liver disease. The presence of PVT used to be a contraindication to LDLT. This is related to the technical difficulties of PV reconstruction, increased blood loss, and the risk for postoperative PV complications.

Object. To review our center experience of LDLT and analyze the influence of preoperative PVT on perioperative and long-term outcomes of the recipients.

Materials and Methods. We reviewed the data of LDLT patients at Liver Transplantation Unit, Mansoura University, Egypt during the period between May 2004 till March 2017. Patients were divided into three groups. Group I: patients without PVT, Group II: attenuated PV patients (PV diameter <8 mm), and Group III PVT patients.

Results. During the study period, 500 cases underwent LDLT. Group I included 446 patients (89.2%), Group II included 26 patients (5.2%), and Group III included 28 patients (5.6%). Higher incidence of hematemesis and encephalopathy was detected in Group III. Longer anhepatic phase duration was found in Group III. There were no significant differences regarding operation time, blood loss, and transfusion requirements. Higher incidence of postoperative vascular complications was found in Group III. The median OS was 33 months (4-169). The 1-, 3-, and 5-years OS survival rates of Group I were 80.5%, 77.7%, and 75%, while for Group II were 84.6%, 79.6%, and 73.5%, and for Group III were 88.3%, 64.4%, and 64.4% respectively (Figure). There was no significant difference between the groups regarding OS rates (Log-Rank: 0.793).

Conclusions. Preoperative PVT increases the complexity of LDLT operation and the operative trauma to the patient, but it does not reduce the OS rates.

377

MINIMALLY INVASIVE RECONSTRUCTIVE SURGERIES FOR BENIGN ESOPHAGEAL STRICTURES

A. Shestakov^{1,2}, T. Petrosyan², A. Tskhovrebov², I. Boeva², A. Yurasov², A. Bezaltinnih²

²Petrovsky National Research center of Surgery, Moscow, Russia

Background. Reconstructive esophageal surgery remains one of the most challenging procedures. A number of benign esophageal strictures require partial resection or total removal of esophagus. These are difficult and technically challenging procedures associated with a high risk of complications. Minimally invasive approach allows to reduce intraoperative blood loss, lower the number of postoperative complications and shorten the length of hospital stay.

Methods. We reviewed our experience on 9 patients with benign esophageal strictures that had been treated in Petrovsky National Research Centre of Surgery using minimally invasive techniques over the period of 2016-2018. Three of the nine patients were operated for megaesophagus, three – for long caustic strictures, two – for long peptic strictures and one for long cicatricial stricture of esophagus. The age varied between 22 and 67 years.

Results. All patients undergone three-stage thoracoscopic esophagoplasty with cervical esophago-gastric anastomosis. The average length of the surgeries was 574 min (529 - 681 min). The maximum intraoperative blood loss volume was 800 ml, minimum – 100 ml. The duration of intensive care unit stay varied between 8 hours and 4.5 days and the duration of hospital stay – between 11 to 30 days with no perioperative mortality. Four patients showed evidence of anastomotic leak. Among other complications there were: wound suppuration (n=1) and hydrothorax (n=1). None of the complications required surgical intervention and were treated conservatively.

Conclusions. Minimally invasive surgery is an acceptable, technically available method of benign esophageal strictures treatment. Such surgeries do not lead to an increase in the rates of postoperative complications and mortality, with proven decrease of pulmonary, cardiac and infectious complications, which leads to early activation and recovery of patients and therefore, reduction of duration of hospital stay.

378

ENDOSCOPIC PAPILLECTOMY IN TREATMENT OF PATIENTS WITH AMPULLARY NEOPLASMS

K Shishin, I. Nedoluzhko, N. Kurushikina, L. Shumkina

A.S. Loginov Moscow Clinical Scientific Centre, Moscow, Russia

Background. Benign tumors of the ampulla of Vater occur in 0.4% -0.12% of all tumors of the gastrointestinal tract (GI tract). However, malignant transformation occurs in 60-65% of cases, so the common tactic of treatment is their removal. Regardless of the pathohistological structure of the tumor, endoscopic papillectomy is considered reasonably safe and most effective method compared to a more radical interventions such as pancreatoduodenal resection (PDR), transduodenal resection.

Aim. To evaluate the safety and outcome of endoscopic papillectomy.

Materials and methods. 37 endoscopic papillectomies were performed at the Moscow Clinical Scientific Center from April 2014 to January 2018. In most cases, the tumor was detected during a routine examination for other diseases. The preoperative examination protocol included duodenoscopy with biopsy, endosonography, CT or MRI, which excluded the presence of malignant lesions and the intraductal spread of the adenoma more than 1 cm. The sizes of the adenomas ranged from 1 cm to 5 cm. The aim of the study was to evaluate the effectiveness of endoscopic papillectomy in the treatment of patients with neoplasm of the ampulla of Vater.

Results. 37 patients underwent endoscopic papillectomy, including 16 men and 21 women. Median age: 54 years (26-73). The average time of surgery was 85 minutes. In 26 cases, the removal of the adenoma was performed "en bloc" (59.5%). In 11 cases, due to the presence of lateral spread of the tumor, fragmentation was performed (40.5%). Pancreatic stenting was successful in 31 patients (83.7%). Stenting of the common bile duct in 9 patients (24.3%). In all cases there was R0 resection. Morbidity included bleeding in 8 patients (21.6%), 2 cases of intraoperative perforation (5.4%), one of them was conservatively treatment. The other was operated in volume: laparotomy, suturing a perforation, drainage of the abdominal cavity. In 2 patients, the postoperative period was complicated by cicatricial stenosis of the bile duct opening (5.4%). The ERCP with the stenting of the common bile duct was performed. No death occurred.

Conclusion. Endoscopic papillectomy is characterized by lower morbidity and mortality and a shorter period of hospitalization. Compared with surgery, endoscopic ampullectomy appears to be a preferred treatment modality for small benign ampullary tumors with high success rate of tumor eradication.

379

SURGICAL TREATMENT OF GASTRIC CANCER COMPLICATED BY BLEEDING

B. Sigua¹, S. Petrov², I. Gubkov², A. Danilov², I. Mavidi², E. Zakharov¹, D. Sakhno¹, A. Kurkov¹

¹North-Western State Medical University named after I. I. Mechnikov, Saint-Petersburg, Russia

²Saint Elizabeth's Hospital, Saint-Petersburg, Russia

Actuality. Gastric cancer is one of the most common malignant neoplasms of the gastrointestinal tract. However, it's diagnosis still remains at an unsatisfactory level. About 75% of patients enter various hospitals in the advanced (III-IV) stages of the oncological process. In 40% of cases, gastric cancer has a complicated course, and the most frequent and severe complication is bleeding.

The purpose of the study. To improve the results of treatment of patients with gastric bleeding of tumor origin.

Materials and methods: In the period from 1996 to 2015, 142 patients with gastric cancer with complicated bleeding were treated at the Saint Elizabeth's Hospital of St. Petersburg. All patients are divided into two groups: Group I - patients who were on treatment from 1996 to 2006 - 72 people, including men 47 (65.3%), women 25 (34.7%); the second group included patients who were treated from 2007 to 2015. - 70 people, including 46 (65.7%) men, 24 women (34.3%). In the treatment of patients of group II, an individual treatment and diagnostic tactic was used, taking into account the degree of endoscopic hemostasis, the severity of blood loss, the patient's condition and the risk of bleeding recurrence.

Results. In the structure of complications of stomach cancer bleeding was observed in 76.3% (55) cases in group I and 82.9% (58) in group II. Structure of patients on stages of oncological process: stage I-II was noted in 20,8% (15) and 21,4% (15) patients in I and II groups respectively; stage III in 28 (38,9%) people in I group and 27 (38,6%) in II; and stage IV in 29 (40,3%) patients in I group and 32 (45,7%) patients in II group. It should be noted that 48 (66.7%) patients in group I and 40 (57.1%) were operated on in group II, and 24 (33.3%) and 30 (42.9%) patients in groups I and II respectively were conservatively treated. The following surgical interventions were performed: gastrectomy was performed in 29.2% (14) of patients in group I and 37.5% (15) cases in group II, subtotal stomach resection 12 (25%) in group I and 20 (50%) in group II, symptomatic operations in 7 (14,6%) cases in group I and 3 (7,5%) in group II, gastrectomy with pancreas resection in 1 (2,1%) patient of group I and 2 (5,0%) cases in group II; and only in the I group were performed: resection of 2/3 of the stomach 10 (20,8%), extirpation of the stomach stump 3 (6,2%) and cardia resection in 1 (2,1%) case. 31 (64.6%) patients underwent emergency surgery in group I and 11 (27.5%) in group II. In the postoperative period complications were observed in 45,8% (22) cases among group I patients and in 9 (22,5%) patients in group II

($p < 0,05$). Postoperative mortality was 35.4% (17) in group I and 5.0% (2) in group II ($p < 0,001$).

Conclusion: The individual therapeutic and diagnostic approach to the treatment of patients with gastric bleeding of the tumor genesis allows to significantly reduce the frequency of complications by 2 times and postoperative mortality by 7 times.

380

LAPAROSCOPIC TECHNOLOGIES IN THE MANAGEMENT OF STRANGULATED INGUINAL HERNIAS

B. Sigua¹, S. Petrov², G. Rutenburg², A. Kozobin², A. Suprun²

¹NWSMU named after I.I. Mechnikov, Saint-Petersburg, Russia

²SPb GBUZ "Elizabeth hospital", Saint-Petersburg, Russia

Despite the development and success of herniology in elective cases, the incidence of strangulated inguinal hernia has not changed over the recent years. In addition, there is a high level of postoperative complications and mortality. The introduction of laparoscopy for diagnosis and treatment of strangulated inguinal hernias is supposed to be a major contributor in further advances in this field. The aim of this study was to improve outcomes of strangulated inguinal hernia repair.

Materials and methods. 136 patients was diagnosed with strangulated inguinal hernias after admission to the Elizabeth hospital, St. Petersburg over the period from 2011 to 2016. The research group comprised of 52 patients, who were treated during the period from 2015 to 2016. 84 patients, admitted from 2011 to 2014, were included into the control group. The vast majority of patients in both groups were males. The mean age in study groups was 61.7 ± 19.1 years (range from 20 to 92).

Results. Patients of the control group was managed using traditional approach for diagnosis and treatment of strangulated inguinal hernias, without laparoscopy. Analysis of the outcomes in this group have shown undiscernable access in decision making as well as unacceptably high percentage of post operative complications and mortality. The aforementioned facts triggered the development and introduction of a brand new surgical tactic in the research group. For diagnostic purposes, especially in complicated cases, the ultrasound examination of the inguinal region and abdominal organs, computed tomography and laparoscopy were used. The key factor in the decision making for the research group was the duration of strangulation and the severity of comorbidities. There for in 25 (48.0%) cases with no contraindications for the carboxyperitoneum and strangulation up to 8 hours was performed transabdominal preperitoneal hernioplasty (TAPP). In cases of strangulation over than 8 hours or contraindications to the laparoscopy, open

procedures was the method of choice to repair inguinal hernia: if the affected organ was found to be viable, prosthetic hernioplasty (Lichtenstein procedure) was used, which was performed in 18 (34.6%) patients. In cases of necrosis of a strangulated organ, plastic of the posterior wall of the inguinal canal was performed using Bassini method (9 patients (17.3%)).

Conclusion. The commencement of a new surgical tactic, based on the extensive use of laparoscopy in the treatment of strangulated inguinal hernias, has led to a significant decrease in general postoperative complications from 25.0% to 1.9% ($p < 0,05$), local complications from 29.8% to 5.7% ($p < 0,05$), as well as the mortality rate from 8.3% to 0% ($p < 0,05$).

381

HEPATIC METASTASIS OF THYROID MEDULLARY CARCINOMA - SURGERY AS A CURATIVE TREATMENT

Silva Patrícia Araújo^{1,2}, Viana Charlene¹, Pereira Ricardo¹, Cristino, Humberto³, Falcão Joaquim¹, Vilaça Sónia¹

¹General Surgery at Braga Hospital, Braga, Portugal

²Life and Health Sciences Research Institute (ICVS), School of Health Sciences, University of Minho, Campus de Gualtar, 4710-057 Braga, Portugal

³General Surgery at Centro Hospitalar São João, Porto, Portugal

Thyroid Medullary Carcinoma (CMT) is a rare endocrine tumor that accounts for 5-10% of thyroid tumors. Distant metastasis are rare and may occur in the liver, lung, and bone. Liver metastasis are, in most cases, a sign of disseminated disease and are difficult to diagnose by imaging techniques since they are often small and multiple. Surgery is the only treatment with curative potential however, given the usual spread of the disease at the time of its diagnosis, systemic treatment is often necessary. We describe here a case report of a patient with hepatic metastasis of thyroid medullary carcinoma in order to discuss the appropriate management. A 59-year-old male patient with diagnosed of CMT, underwent a total thyroidectomy with left central radical emptying (T3N0M0). Five years after surgery, three hepatic nodules were detected in follow-up CT. Biopsy of the hepatic nodules was performed and revealed metastasis of CMT. In multidisciplinary consultation it was decided surgical treatment. It was performed a subsegmentectomy of the segment 6 and a metastasectomy of the segments 5 and 2. Definitive histology confirmed metastasis of CMT. Given the excellent general condition of the patient and the absence of other distant metastasis, surgery allowed the treatment of hepatic metastasis of CMT with curative intent.

382

HEPATOCELLULAR CARCINOMA IN A PATIENT WITH ABERNETHY MALFORMATION - A SURGICAL CASE REPORT OF A RARE ASSOCIATION

Silva Patrícia Araújo^{1,2}, Branco Cláudio³, Vilaça Sónia¹, Falcão Joaquim¹

¹General Surgery at Braga Hospital, Braga, Portugal

²Life and Health Sciences Research Institute (ICVS), School of Health Sciences, University of Minho, Campus de Gualtar, 4710-057 Braga, Portugal

³General Surgery at Centro Hospitalar do Porto, Porto, Portugal

Abernethy malformation (AM) is a rare congenital abnormality described by John Abernethy in 1793. It is characterized by the total or partial agenesis of the portal vein, creating a portosystemic shunt in the absence of portal hypertension or liver disease. In Abernethy malformation, the liver is bypassed and the unpurified blood passes directly into the systemic circulation via the inferior vena cava. Two types of Abernethy malformation have been described: type I, more common in female, corresponding to a congenital absence of the portal vein, and type II, in which blood supply to the portal vein is partly preserved and displays a slight male predominance. Both types are commonly complicated by liver nodules, hepatocellular carcinoma and hepatic encephalopathy in adults, and may even lead to discovery of the malformation. Liver transplantation appears to be the most effective treatment. We describe here the management of a large hepatocellular carcinoma associated with Abernethy malformation. A 34-year-old male patient was referred to the consultation with the ultrasonographic diagnosis of bilobar hepatic nodules. He was asymptomatic and there were no evidence of alteration on physical examination. The analytical study revealed hepatic cytolysis and cholestasis, negative tumor markers and negative serologies. An imaging study with CT and MRI revealed multiple nodular formations throughout the parenchyma, with approximately 2 to 2.8 cm, compatible with nodular regenerative hyperplasia. In the left lobe it was found a large heterogeneous nodular formation, measuring about 15 cm, corresponding to a hepatocarcinoma. Additionally it was observed porto-cava shunt, with direct communication of the inferior vena cava with the portal vein, relatively voluminous. It was performed a liver biopsy whose histology was compatible with hepatocellular carcinoma. After a multidisciplinary discussion, the patient underwent a left lobectomy. Postoperative course was uneventful and no additional therapy was administered. The anatomic pathology results revealed well differentiated hepatocellular carcinoma and absence of vascular invasion images (pT3aG1N0M0R0). At the follow-up visit, progressive encephalopathy with hyperammonemia was observed, with functional worsening of the porto-cava shunt and imaging findings with nodules with degenerative potential. He was

then submitted to liver transplantation, which happened without complications, and is currently asymptomatic. In conclusion, patients with portal vein agenesis may develop liver tumors due to increased blood flow, namely hepatocellular carcinoma, which the most effective treatment is liver transplantation with portal vein reconstruction.

383

PANCREATIC ACINAR CELL CARCINOMA A RARE PANCREATIC TUMOR

Silva Patrícia Araújo^{1,2}, Branco, Cláudio³, Veiga, Carlos¹, Vilaça Sónia¹, Falcão Joaquim¹

¹General Surgery at Braga Hospital, Braga, Portugal

²Life and Health Sciences Research Institute (ICVS), School of Health Sciences, University of Minho, Campus de Gualtar, 4710-057 Braga, Portugal

³General Surgery at Centro Hospitalar do Porto, Porto, Portugal

Pancreatic acinar cell carcinoma is a rare tumour, accounting for 1% of all pancreatic tumors. It may arise in any portion of the pancreas but it is slightly more common in the head. Most patients are male within the seventh decade of life with only a small minority concerning children (6%). Acinar cell carcinoma is a malignant epithelial neoplasm composed of cells with morphological resemblance to acinar cells and with evidence of exocrine enzyme production by the neoplastic cells. These tumors present with non-specific symptoms such as weight loss, abdominal pain, nausea, vomiting, melena, weakness, anorexia or diarrhoea. Sometimes, they may be an incidental finding on microscopic examination. Surgical resection is the treatment of choice for patients with early-stage acinar cell carcinoma. However, most acinar cell carcinomas are quite large at presentation, with low resectability, high recurrence rates and frequent metastases. In the cases of an unresectable tumor, neoadjuvant or adjuvant chemoradiation therapy has been used, but the benefits remain unproven. Nevertheless, the long-term survival for patients with acinar cell carcinoma is significantly better than the long-term survival of patients with pancreatic adenocarcinoma. We describe here a case report of a patient with a pancreatic acinar cell carcinoma in order to discuss the appropriate management and the relevance of this rare entity. A 59-year-old male patient was referred to the consultation with epigastric pain in the previous 2 months. Imagiologic study demonstrated enlargement of the pancreas, with a pancreatic mass with 5.3cm, heterogeneous, at the transition from the body to the pancreatic tail. It was discussed at a multidisciplinary consultation and it was proposed for surgery. It was performed a corporaudo splenopancreatotomy without intercurrents. The anatomic pathology revealed a pancreatic acinar cell carcinoma (T3N0). Postoperative course was uneventful and the patient is

currently under adjuvant chemotherapy. In conclusion, pancreatic acinar cell carcinoma is a rare entity on which accurate pathological diagnosis plays an important role in patients' treatment and evaluation of prognosis.

384

SIGNIFICANCE OF GLYCOLYTIC METABOLISM-RELATED PROTEIN EXPRESSION IN HEPATIC METASTASIS OF COLORECTAL CANCER

Silva Patrícia Araújo^{1,2}, Martins Sandra Fernandes^{1,2,3}, Amorim Ricardo^{2,3}, Vilaça Sónia¹, Falcão Joaquim¹, Longatto-Filho Adhemar^{2,3,4,5}, Baltazar Fátima^{2,3}

¹General Surgery at Braga Hospital, Braga, Portugal

²Life and Health Sciences Research Institute (ICVS), School of Health Sciences, University of Minho, Campus de Gualtar, 4710-057 Braga, Portugal

³ICVS/3B's - PT Government Associate Laboratory, Braga/Guimarães, Portugal

⁴Molecular Oncology Research Center, Barretos Cancer Hospital, Barretos, São Paulo, Brazil

⁵Laboratory of Medical Investigation (LIM) 14, Faculty of Medicine, University of São Paulo, São Paulo, Brazil

Colorectal cancer (CRC) is the third most common cancer and represents the fourth most frequent cause of death worldwide. During the course of this disease, 50% of the patients develop hepatic metastasis and more than 66% have hepatic disease in the moment of death. Most patients die due to the dissemination of the disease and so it is essential to understand the molecular interactions involved in tumour progression. Most cancer cells display high rates of glycolysis with production of lactic acid, which is then exported to the microenvironment by monocarboxylate transporters (MCTs). The aim of this study was to describe the immunohistochemical expression of MCT1, MCT4, GLUT1, CD147 and CD44 in hepatic metastasis and adjacent normal tissue of 45 patients with histological diagnosis of metastasis from CRC. We also sought to evaluate the association between MCTs and the remaining proteins and to establish possible correlations between their expression in tumor tissue and clinical and pathological data of the patients. All proteins were overexpressed in hepatic metastasis of CRC, when compared with non-neoplastic tissue. MCT4 expression was associated with CD147 and GLUT1 in hepatic metastasis of CRC. CD147 was associated with clinical pathological features, suggesting the role of this metabolism-related protein in tumor progression and in the metastatic process. These findings provide additional evidence for role of MCTs in metastatic CRC maintenance and progression, and support the use of MCTs as biomarkers and potential therapeutic targets.

385

SOLID PSEUDOPAPILLARY NEOPLASM A RARE PANCREATIC TUMOR

Silva Patrícia Araújo^{1,2}, Branco Cláudio³, Vilaça Sónia¹, Falcão Joaquim¹

¹General Surgery at Braga Hospital, Braga, Portugal

²Life and Health Sciences Research Institute (ICVS), School of Health Sciences, University of Minho, Campus de Gualtar, 4710-057 Braga, Portugal

³General Surgery at Centro Hospitalar do Porto, Porto, Portugal

Solid pseudopapillary neoplasm (SPN) is a rare disease, accounting for 0,2 to 2,7% of all pancreatic tumors. Most patients are female within the second or third decade of life with only a small minority concerning children. Frequently an incidental finding, they present as a slowly growing abdominal mass with nonspecific symptoms, such as abdominal pain. Considered to be a low-grade malignant tumor, with a reported incidence of malignant transformation of around 15%, surgical resection is the treatment of choice with an excellent long-term prognosis. We describe here a case report of a patient with a solid pseudopapillary neoplasm in order to discuss the appropriate management and the relevance of this rare entity. A 17-year-old female patient was admitted to our department with vomiting and abdominal pain localized to the right upper quadrant. On physical exam a mass was present on the right hypochondriac region. Computed tomography and MRI scans showed the presence of a well-defined tumor arising from the pancreatic head with 14 cm of greater diameter, heterogeneous and with solid and cystic component. No evidence was found of pancreatic insufficiency, abnormal liver function, cholestasis or elevated pancreatic enzymes. Tumor markers carcinoembryonic antigen, carbohydrate antigen, and alpha-fetoprotein were all within the normal range. Pylorus-preserving pancreatoduodenectomy was performed. Histopathology confirmed a SPN with complete resection and no evidence of malignancy. Immunohistochemistry profile revealed positivity for vimentin, CD-10, progesterone receptor and neuron-specific enolase. Focal positivity was found for α -1 antitrypsin, chromogranin A and oestrogen receptor. Postoperative course was uneventful and no additional therapy was administered. A follow-up of 5 years showed neither signs of tumor recurrence nor endocrine and exocrine insufficiency of the pancreas. Solid pseudopapillary tumors of the pancreas are extremely rare and usually have an excellent long-term prognosis after surgical resection.

386

SOLITARY FIBROUS TUMOR FROM LESSER OMENTUM: A CASE REPORT

Silva Patrícia Araújo^{1,2}, Ribas Sónia¹, Vilaça Sónia¹, Falcão, Joaquim¹

¹General Surgery at Braga Hospital, Braga, Portugal

²Life and Health Sciences Research Institute (ICVS), School of Health Sciences, University of Minho, Campus de Gualtar, 4710-057 Braga, Portugal

The solitary fibrous tumor (SFT) is a mesenchymal tumor of the fibroblastic type that can affect almost any region of the body, developing mainly in the pleura. These tumors occur predominantly in middle-aged adults without any differences in gender distribution. While SFTs are more frequently asymptomatic at presentation some patients may exhibit symptoms associated with a local compressive effect on surrounding structures. Most tumors present as well defined, slow growing masses, for which surgery presents as a possible curative strategy. Between 10-20% of SFTs, have a more aggressive behavior, with local recurrence and distant metastasis for which systemic therapy is recommended. Given the wide range of histological features, it is often difficult to determine if SFTs should be treated as a benign or malignant entity, but tumor size above 15 cm, positive surgical margins, tumor site and high mitotic count are the most useful indicators for malignancy. We describe here a case report of a patient with a solitary fibrous tumor in order to discuss the appropriate management and the relevance of this pathology. A 64-year-old female patient was referred to the consultation with the ultrasonographic diagnosis of hepatic nodule. The patient was asymptomatic and presents a previous use of oral contraceptive during 15 years. The abdominal examination reveals a palpable left sided hepatic lobe. Analytical study without changes. The imagiological study, with ultrasonography, CT and MRI demonstrated a vascular nodule of 12cm in contiguity with the left lobe of the liver and adjacent to the stomach, suggestive of adenoma. In multidisciplinary discussion the patient was proposed for surgery. It was performed excision of the tumor with the need of atypical gastrectomy since it is inseparable from the stomach. Postoperative course was uneventful. The anatomic pathology results revealed a solitary fibrous tumor. Patient evolved favorably and at 10 years of follow-up, there was no evidence of relapse.

In conclusion, SFT arising from lesser omentum is a rare entity and it should be considered as a differential diagnosis in liver lesions. Complete surgical excision appears as the recommended procedure since it confirms diagnosis and predicts aggressiveness based on histological features. It is essential long-term follow-up of these patients as the tumor biology remains unknown.

387

SIMULTANEOUS TREATMENT OF PROLAPSI POSTERIOR AND CENTRAL PELVIC ORGANS

Silva Patrícia Araújo^{1,2}, Goulart André^{1,2}, Nogueira Fernanda¹, Leão Pedro^{1,2}, Martins Sandra^{1,2}, Pereira Joaquim Costa¹

¹General Surgery at Braga Hospital, Braga, Portugal

²Life and Health Sciences Research Institute (ICVS), School of Health Sciences, University of Minho, Campus de Gualtar, 4710-057 Braga, Portugal

Introduction: Patients with obstructed defecation caused by more than only rectocele need a more extensive surgical correction of pelvic organs prolapse (POP). Associated conditions such as enterocele, apical prolapse, perineal descent and internal rectal prolapse, mucous rectal prolapse can be corrected by a combinations of ventral rectopexy (VP) and an anterolateral hysteropexy.

Materials: The authors report a vídeo demonstrating of Laparoscopic Simultaneous Treatment of Rectocele and Apical Prolapse (LAPSTAR)

Methods: The patient is positioned in a Lloyd-Davies modified position, a pneumoperitoneum is created to a pressure of 12 mmHg. Four ports are introduced: umbilical, right and left lower quadrants' transition and midline below the umbilicus. The uterus is elevated using transvaginal manipulation. The rectovaginal space is dissected down to the pelvic floor. A biologic collagen prosthesis is fixed to the anterior wall of the extraperitoneal rectum with separate points of PDS 2/0 and to the sacred promontory with tackers; a second collagen prosthesis is introduced into the abdomen the central part of the prosthesis is fixated to the uterine isthmus. Two abdominal incisions are made in the abdominal wall superiorly and medially to the anterosuperior iliac spine with dissection of the subcutaneous tissue and opening of the external oblique fascia. A long grasper is introduced in the incision passing the muscle plane up to the peritoneal space where it will be advanced in subperitoneally to the rectovaginal space. Then the superior parts of the prosthesis are grasped and brought all the way to the fascia where they will be fixated. The traction of the prosthesis repositions the uterus or vagina. The peritoneum is closed.

Results: Discharge to the 1st postoperative day, with oral analgesia. Resolution of the symptoms of defective obstruction and perineal pain.

Conclusion: In the majority of cases of pelvic floor dysfunction there is a multicompartamental POP, being necessary the simultaneous correction of posterior and central compartments. RV and LAPSTAR are techniques with minimal surgical expression, presenting lower rates of intra- and postoperative complications, with excellent clinical results.

388

RANDOMIZE CONTROL TRIAL COMPARATIVE MANAGEMENT RADIATION PROCTOCOLITIS VIA SUCRALFATE INSTILLATION VIA COLONOSCOPY WITH ARGON PLASMA COAGULATION

Siripong Sirikurnpiboon

Rajavithi hospital, College of Medicine, Rangsit university, Bangkok, Thailand

Introduction. The one sequel after radiotherapy for pelvic cancer is radiation proctocolitis. Bleeding is common clinical presentation with wide range of severity. Radiation effect cause of DNA , protein and lipid damage lead to mucosal friability and neovascular telangiectasias. This study compare a result in local management and evaluation factor to in failure in Sucralfate instillation under colonoscopy and Argon plasma coagulator under colonoscopy.

Method. The study was conducted from 2013-2016 AC. Inclusion criteria were 1 patient was diagnosis radiation proctocolitis from clinical with colonoscopy and pathology, 2 age from 18 to 80 years. Exclusion criteria were 1 patient denied to underwent treatment, 2 patient with severe co-morbidities, 3 patient unable to follow up. The patients was randomize into 2 group. Data was collected in patient demographic data, previous cancer disease , onset of clinical bleeding per rectum after last radiotherapy session and hematocrit level before and during treatment.

Result. Overall patient was 130 patients, 54 patients into sucralfate group and 70 patients in APC group. The mean age of sucralfate group was 62.15 ±10.00 and in APC group was 62.27±8.07. Time to presentation after last radiotherapy session was 7.16±4.97 and 6.15±4.18. The first hematocrit before treatment was 34.86±4.6 and 32.17±6.5. The failure rate in treatment of Sucralfate was 5.6 % and APC was 15.8% (p = 0.96). The factor relate to failure of both treatment were age ≥ 60 years, female, Hct at presentation ≤ 30 mg%, extension of disease above rectum, full circumferential involvement and ulceration.

Conclusion. The sucralfate instillation for treatment of radiation proctocolitis is not inferior to APC. The factor of failure in management was relation to severity and extension of disease.

389

RETROSPECTIVE REVIEW KRAS MUTATION EFFECT ON PROGNOSIS IN NON-NEOADJUVANT LOCALLY ADVANCE RECTAL CANCER

Siripong Sirikurnpiboon, Burin Awapittaya

Rajavithi hospital, College of Medicine, Rangsit university, Bangkok, Thailand

Introduction. The KRAS mutation is common in colorectal

cancer with controversial role in prognosis. The neoadjuvant in management of locally advance rectum by AJCC staging T3 and above, and lymph node involvement possible to affect to tissue interpretation. This study demonstrate prognosis in non-neoadjuvant patients and factors associated with recurrence and metastasis include KRAS mutation.

Method. The study was collect from 2006-2016, AC including patients demographic data, pre-operative stage, KRAS status ,type of operation, adjuvant chemo-radiation, compliance of adjuvant, recurrence disease with time to recurrence, metastasis with site of metastasis and time to metastasis, and survival data.

Result. Overall patients 277 patients (male 145 and female 132) with average age 60.55 years (32-88 years). The cancer diagnosis at middle rectum 135 and lower rectum 142 patients. KRAS mutation on codon12 was 31.7%, codon13 was 54%, and both were 61.3%. The two years survival 93.6% and five year survival 63.2%. Local recurrence 8.3% and distant metastasis 26%. The factors associated with local recurrence were positive CRM, young age and poor compliance to adjuvant chemo-radiation (p < 0.001). The factors associated with metastasis were positive CRM, positive lateral pelvic node, and poor compliance to adjuvant chemo-radiation (p < 0.001).

Conclusion. The management of locally advance rectal cancer in non-neoadjuvant, CRM positive is risk factor but lateral node involvement is risk distant metastasis. Moreover, the poor compliance in adjuvant management is risk in local and distant metastasis rather than nodal stage and KRAS mutation status.

390

ENHANCED RECOVERY PATHWAY FOR PATIENTS UNDERGOING EMERGENCY COLON SURGERY (A RANDOMIZED CONTROLLED CLINICAL TRIAL)

N. Sizonenko¹, D. Surov¹, I. Soloviev¹, A. Demko², G. Martynova², A. Sviatnenko^{1,2}, P. Lukianiuk¹, A. Osipov^{1,2}

¹S.M. Kirov Military Medical Academy, Saint Petersburg, Russia

²Saint Petersburg I.I. Dzhanelidze research institute of emergency medicine, Saint Petersburg, Russia

Background. Currently, there are many publications in the world literature about the successful implementation of enhanced recovery after surgery (ERAS) concept in various areas of elective surgery, with extremely limited implementation of this approach in urgent surgery.

Objective: To study applicability, safety, and efficiency of the ERAS program in the surgical treatment of patients with acute obstructive colon cancer.

Materials and methods. Since 2016, the study participation of 95 patients. Did not include patients with widespread

peritonitis, multiple organ dysfunctions, associated complications of neoplasm and tumor localization in the rectum. The ERAS group consisted of 48 patients (median age 71 (54-94)), for 47 patients traditional surgical approaches were applied (the control group, median age 69 (43-91)). In addition to the well known components of the ERAS we also during the operation performed decompression of the colon and small (under indications) intestine, the small intestine lavage with polyelectrolyte solutions and antihypoxant, embryology oriented surgery and D3-lymphadenectomy, rectus sheath catheterization. Compared the post-operative pain syndrome level (NRS), terms of enteral insufficiency events relief terms, the occurrence of postoperative complications and mortality, duration of the post-operative period. Results: The ERAS group: the post-operative pain syndrome was 4 (3,5;4,0) in the first day, with regression up to 1 (1,0;2,0) by the fourth day. Patients no needs in opioid analgesics. 42 patients (87,5%) had no nausea and vomiting; they began to receive enteral feeding in 24-36 h after the surgery; intestinal peristalsis appeared within 12-24 h, gases discharge – in 24-36 h and stool discharge in 36-48 h after the surgery. 9 patients (18,6%) had postoperative complications (by Clavien-Dindo I-IIIa – 7, IIIb-IV – 2), 5 patients died (10,4%). The postoperative period was 8 (5,5;12,75) days. The control group: the pain syndrome was 6 (5,0;6,0) in the early postoperative period, which required the use of opioid analgesics (14 cases, 29,8%). 26 patients (55,3%) had nausea and vomiting after the surgery, events of postoperative intestinal paralysis were eliminated by the 4-5th day. 15 cases (31,9%) of postoperative complications were recorded (I-IIIa – 9, IIIb-IV – 6). 4 patients (8,5%) underwent relaparotomy. 11 patients died (23,4%). The post-operative period was 13 (10,5;17) days.

Conclusion: Application of the ERAS concept is safe and effective due to improving the immediate results of surgical treatment of patients with acute obstructive colon cancer. The success of this approach is determined by timely and effective adjustment of the pain syndrome, embryology oriented surgery, adequate correction enteral insufficiency that causes intra- and extra-abdominal complications and multiorgan dysfunction in general.

391

INNOVATIVE METHOD OF COMBINED TREATMENT OF THE CHRONIC ANAL FISSURE WITH BIOTECHNOLOGY APPLICATION

A. Solomka¹, A. Ulyanov², P. Pletner³, E. Achkasov⁴

¹Moscow city center of coloproctology, the State Clinical Hospital "City Clinical Hospital No. 24 of the Moscow City Health Department", Moscow, Russia

²Central Literary Fund Clinic, Moscow, Russia

³FGBU of Health Central Clinical Hospital of the Russian Academy of Sciences

⁴Sechenov First Moscow State Medical University (Sechenov University), Moscow, Russia

Relevance. The anal fissure takes the third place in the structure of diseases of the colon, which is about 5.3-11.7%. More than 30% are patients of working age. Women suffer more often (60% or more according to different sources) [1,2].

Goal. The aim of the study was to develop a method for accelerating the healing of a postoperative wound, and also reducing the likelihood of complications after surgical treatment of a chronic anal fissure.

Materials and methods. An original method of combined treatment of anal fissure was introduced into practice (RU patent for invention No. 2639039 dated 19.12.17). The method consists in excision of a chronic anal fissure within a healthy tissue together with a fibrous polyp and a guard tubercle without performing a sphincterotomy. Then a platelet-rich autoplasm is inserted into the walls and bottom of the postoperative wound, and then impose a film of platelet-rich autoplasm on the wound. At the end stage the botulinum toxin A is inserted into the internal sphincter by the method introduced earlier at three points for its relaxation. This method was used in 17 patients in the main group by the technique described above. A fissure excision with a sphincterotomy was performed in the comparison group (32 patients). All patients in the postoperative period were assessed the intensity of the pain syndrome according to the VAS, as well as the sphincterometry before and 6 months after the operation.

Results. A decrease in the pain syndrome was observed on average by 30% in patients in the main group, starting from the first day after the operation, in comparison with the control group. The healing time for the postoperative wound was 3-4 weeks in the main group, and 4-6 weeks in the control group. At the control examination (2-3 months after the operation), patients in both groups do not present complaints. According to the control sphincterometry in the main group, the pressure is both at rest and at a contraction within the physiological norm. At inspection in 3 months after operation no defects of mucous are found.

Conclusion. The developed method allows to abandon the intraoperative sphincterotomy after excision of the anal fissure, which leads to faster healing of the postoperative wound, to lower the operational trauma and minimizes the likelihood of postoperative complications such as anal incontinence, development of abscesses and hematomas in the sphincterotomy region, fistula formation [3, 4]. The use of platelet-rich autoplasm also allows accelerating reparative processes [5].

392

TREATMENT OF EXTERNAL PANCREATIC FISTULA

E. Stepan, M. Rogal, P. Yartsev, P. Ivanov, M. Tlibekova
Russia

External pancreatic fistula (EPF) is a complication of pancreatic necrosis, pancreatic trauma or surgical procedures on the pancreas. It is formed in 9.5-87% of the cases. EPF impair the treatment results because of pancreatic juice loss and its peptic effect on skin. Nowadays there is no commonly accepted protocol for EPF treatment and it causes relevance of the problem. Improvement of treatment outcomes was the aim of our study. 98 patients with EPF were treated in the years of 1998-2016. EPF was a complication of acute pancreatitis and pancreatic trauma in 2.3% of the cases. 74 (75.5%) of the patients were men and 24 (24.5%) were women. The mean age was 43 (30; 50) years. Surgical procedures were performed previously to fistula formation in all the cases. Laparotomies were carried out in 35 patients. Pancreatic resection was performed during the laparotomies in 5 cases, omental bursa drainage – in 15, suturing of pancreatic wound – in 3, sequestrectomy in 12. Lumbotomy for sequestrectomy was fulfilled in 3 patients. Pseudocyst and liquid collection drainages were performed in 60 patients; US control was used during the procedures in 31 of them. EPF appeared in the period of 1 to 5 days after the operations. Pancreatic juice outflow ranged from 15 to 1100 mL/daily with an average volume of 260 mL/daily. Connection between Wirsung's duct (WD) and EPF was detected during fistulography in 44 patients. Diet, external drainage with lavage and suction, spasmolytic therapy were included in conservative treatment of EPF in all the patients. Pancreatic secretion inhibition (octreotide) was used in 50 patients at the dose of 900 mg daily during 3-15 days. Conservative treatment was effective in 70 (71.4%) patients. The duration of EPF function was 23 (9; 51) days in the group of patients who received octreotide in contrast with 41 (31; 62) days in the group without octreotide. Endoscopic papillosphincterotomy (EPST) was performed in 10 (10.2%) patients with papillary stenosis, and endoscopic transduodenal pancreatic stenting (ETDPS) - in 9 (9.2%) patients with stenosis of proximal part of WD. EPF was closed in 14 (11; 38) days after EPST and in 8 (6; 11) days after ETDPS. EPF was formed after drainage of pseudocyst with thick walls in 1 (1.0%) patient. The patient was effectively treated by endoscopic cystogastrostomy. WD tear was the reason of ineffective conservative treatment in 8 (8.2%) patients. Surgical anastomosis between the distal part of the pancreas and the small intestine was formed in the cases. Complex conservative treatment allows closing EPF in 71.4% of the patients. Octreotide therapy is an important part of the treatment. EPST is effective tool in the patients with papillary stenosis, while ETDPS is a valuable method in the cases of proximal part stenosis of WD. Inefficient conserva-

tive therapy caused by WD tear is an indication for surgery procedures.

393

SURGICAL TREATMENT OF PHARYNGOESOPHAGEAL DIVERTICULA

S. Stolyarov

BU "Republican clinical hospital", Cheboksary, Russia

Urgency. Pharyngeal-esophageal or cencer diverticula (DC) are rare diseases and make up 3 to 5% of all diseases of the esophagus. At the same time, they are the most common cause of dysfunction of the pharyngeal-esophageal junction.

Purpose of work. To study the results of surgical treatment of patients with DC.

Materials and methods. During the period from 1984 to 2017, 25 patients with DC at the age of 34 to 79 years were treated in BC "RKB". There were 14 men and 11 women. Dysphagia was observed in 16 (64%), belching in combination with food regurgitation was observed in 10 (40%), hoarseness of voice in 3, bad breath in 8. Cough was noted in 4 patients, body weight deficit in 3. In 7 patients on the left neck tumor-like formation with "splash"noise was determined. The duration of clinical manifestations is from 5 months to 6 years. The examination included radiography of the lungs, x-rays of the esophagus and fibroezofagogastro-duodenoscopy (FAGS). 3 diverticula were up to 3 cm in size, 11 (47.8%) with a diameter of 3-4 cm, 8(34.8%) – with a diameter of 4-8 cm, 2 (8.9%) – with a diameter of more than 8 cm.all diverticula were localized on the left. FAGS allowed to assess the localization of the mouth of the diverticulum, the state of its mucous, the presence or absence of foreign bodies in the diverticulum lumen, the degree of patency of the esophagus below the mouth of the diverticulum. 13 patients had complications of the disease: bleeding-1; perforation of the diverticulum with the development of phlegmon of neck – 1; tracheoesophageal fistula – 1; diverticulitis – 8, stenosis of the esophagus distal to the mouth of the diverticulum – 2. Complicated forms of the disease and giant diverticula (more than 8 cm in diameter) were observed in patients with a long history (one year or more). All patients were operated on. DC stood out from the left-hand cervical access. After extramucosal of esophagomyotomy with the obligatory crossing perscription part of the lower constrictor of the pharynx was performed diverticulectomy with the subsequent plasticity of the muscle membrane. In 18 cases, the neck of the diverticulum is treated with a manual seam, in 4 cases the US-30 is applied, in one – Echelon Flex-40. In subsequent audited sealing seam of the esophagus. The neck wound was drained by Redon. In one case, the plastic of the membranous part of the trachea was carried out (in the presence of a fistula between the

lumen of the diverticulum and the trachea).

Results. The average length of hospital stay was 9.5 ± 0.7 days. In one case, postoperative dysphagia required repeated surgery. Long-term results were traced in 17 patients after 5 years, all achieved a complete clinical recovery.

Summary. 1) DC tend to progress with the development of such severe complications as diverticulitis, perforation with the development of purulent mediastinitis, bleeding, esophageal-respiratory fistulas, metaplasia of the mucosa with malignancy, so they are indicated for surgical treatment..2) surgical Volume – diverticulectomy cervical access.

394

SERRATED DYSPLASIA AND IBD

Girgina Stoyanova

Fifth City Hospital - Sofia, Bulgaria

Relevance. The study examines the pathogenic link between serrated dysplasia and chronic inflammatory bowel disease. Object- Pathological mechanisms of cell degeneration and inflammation as a pathway of precancerous development.

Materials and methods. Clinical, endoscopic and histological materials for a period of five years.

Results. Mechanisms of tissue damage to the intestinal cells in the direction of inflammation - dysplasia – neoplasia.

Conclusion. Adequate opportunities for a timely therapeutic approach and follow-up.

395

PHOTODYNAMIC THERAPY IN THE TREATMENT OF VATER'S PAPILLA AND EXTRAHEPATIC BILE DUCTS CANCER

E. Stranadko¹, A. Lobakov², V. Morokhotov², M. Riabov¹, V. Duvansky¹

¹State Research Center for Laser Medicine of FMBA, Moscow Russia

²MONIKI Clinical Institute, Moscow, Russia

Introduction. Cancers of Vater's papilla and extrahepatic bile ducts (BDC) are hardly accessible tumor localizations characterized by extensive tumor growth and, generally, poor prognosis. Surgical resection provides only limited success with rather high recurrence rate. Adjuvant treatments (radio- and chemotherapy) have no significant impact on survival rate. In a certain number of cases surgery cannot be performed due to local tumor spread and/or concomitant diseases of age. Photodynamic therapy (PDT) is a new technique, providing both, adequate tumor destruc-

tion and minimal damage to surrounding tissue. Despite the success of PDT application for treatment of superficial and some internal malignant tumors, application of this promising technique to bile duct carcinomas is rarely reported. The aim of this study was the development of PDT technique for the treatment of both Vater's papilla and extrahepatic bile duct cancer in inoperable patients for improvement of their quality of life and increase of their survival time.

Materials and methods. PDT has been performed in 28 patients. The average age was 68.5 years. In all cases adenocarcinoma was revealed. Cancer of Vater's papilla was diagnosed in 20 patients, cancer of the common bile duct in 3 patients, cancer of the liver port in 1 patient, and cancer of the gall bladder in 4 patients. Photoditazine (a chlorin-e6 derivative) was used as photosensitizer, diode laser was used for irradiation via either endoscopic or transhepatic route. Patients were divided into several groups. Outcomes were assessed by determining the median survival by Kaplan–Meyer methods.

Results. The treatment was well-tolerated by the patients. The median survival time was 18 months (minimum –12.5 months, maximum – 24 months. There were no lethal outcomes. In patients who had only one PDT session during the year, the median survival was 12.5 months (95% CI: 10, 15); in patients who had two or more PDT sessions, the median survival was 23 months (95% CI: 18, 28).

Conclusion. Results of PDT treatment for cancer of this localization are quite comparable with the results of radical surgeries and are better than palliative surgeries. Decrease of tumor growth rate and longer survival period in patients with residual tumor after PDT treatment are determined by vascular mechanisms produced by PDT which lead to vascular thrombosis and impaired tumor blood supply, these factors provide long-term process stabilization. Repeated PDT courses significantly improve treatment results.

396

ABDOMINAL AORTA, ILIAC VESSELS AND VENA CAVA INFERIOR ANGIOPLASTY IN RETROPERITONEAL SARCOMA PATIENTS

I. Styliidi, M. Nikulin, M. Abgaryan

N.N.Blokhin Russian Cancer Research Center, Russia

Actuality: The treatment of patients with retroperitoneal sarcomas is a difficult sphere of surgery. Tumor invasion in main blood vessels (aorta, vena cava inferior, iliac vessels) usually is the main reason for surgery refusal. On the other hand tumor resection "en block" with vessel gives a chance for a long survival.

The aim of the study: Evaluation of surgery treatment in retroperitoneal sarcoma patients with main blood vessels involvement.

Methods: It was a retrospective study. Since 2006 till 2017 14 patients with main blood vessels involvement have been operated in abdomen department. Men - 4, women -10, mean age 52 (26-75). Liposarcoma has been diagnosed in 9 pts, shvannoma – 2, leiomyosarcoma – 2, malignant glomus tumor -1. Aorta plasty has been performed in 3 pts, iliac artery – 11cases, vena cava inferior – 1 patient.

Results: There were no “vessels” complications (thrombosis, hemorrhage) and mortality after surgery. 7 pts died in different periods of time. 4 pts have been operated repeatedly. Median survival in liposarcoma pts was 87 months, which was better than in “nonliposarcomas” pts (p=0,003).

Conclusions: Main blood vessel (aorta, iliac vessels, vena cava inferior) resection in retroperitoneal sarcoma patients can be performed in specialized oncology centers with low morbidity and good results. Notably, angioplasty is reasonable in retroperitoneal liposarcomas.

397

**POST PANCREATECTOMY HAEMORRHAGE:
A RETROSPECTIVE ANALYSIS OF INCIDENCE,
RISK FACTORS AND OUTCOME**

Das Subhashish, Ray Samrat, Mangla Vivek, Mehrotra Siddharth, Lalwani Shailendra, Mehta Naimish, Yadav Amitabh, Nundy Samiran

Sir Gangaram Hospital, New Delhi, India

Relevance: The operative mortality after pancreaticoduodenectomy (PD) has declined over the past two decades, but the morbidity still remains largely unchanged. Haemorrhage following pancreatectomy(PPH) is reported in 3-13% of patients and is still regarded as one of its most dreaded complications. There is also a recent grading system of PPH (without therapeutic consensus), which has been proposed by the International Study Group of Pancreatic Surgery.

Object: We examined the incidence and outcome of our patients with PPH to determine the risk factors associated with the complication and its effect on hospital stay.

Materials and Methods: We retrospectively analysed, from a prospectively maintained database, all patients who had undergone PD in our unit between January 2007 to May 2018.

Results: There were 340 such procedures performed, 291 for malignant and 49 for benign conditions. PPH occurred in 39 patients (11.5%). There was early haemorrhage (<24 hours) in 8 (20.5%) patients, and late haemorrhage (>24 hours) in 31 (79.5%) patients. According to the ISGPS grading 5 (12.8%) patients had Grade A, 22 (56.4%) patients had Grade B and 12 (30.8%) patients had Grade C PPH. 21(53.8%) were managed conservatively and 18(46.2%) required intervention, namely endoscopic management (3), angioembolisation (5) and re-exploration (10). 6(15.4%) of

the 39 patients with PPH died against an overall mortality in the study population of 16 out of 340 patients (4.7%). The independent risk factors for PPH on univariate and subsequent multivariate analysis were a high pre-operative bilirubin (mean 4.7 vs 7.4, p=0.010) and INR (mean 1.20 vs 1.72, p=0.021), closely followed, but not significantly associated with pre-operative biliary stent placement. Pancreaticojejunostomy (PJ) leak (41% vs 21.7%, p=0.008) also appears to be an independent risk factor associated with PPH. PPH also resulted in a longer post-operative hospital stay (mean 14 vs 11 days, p=0.024). All of ISGPS Grade A and 68% of Grade B patients were managed conservatively, whereas all Grade C patients required some sort of intervention. Mortality according to ISGPS grades was highest seen in Grade C (33%) followed by Grade A (20%) and Grade B (4.5%).

Conclusions: In our experience haemorrhage following PD occurred in 11.5% of patients and resulted in a mortality 4 times greater than those without a PPH. It occurred more frequently in patients with a high pre-operative serum bilirubin (mean 7.4), INR (mean 1.72), biliary stenting or those with a PJ leak. It also resulted in a longer hospital stay.

398

**THIRD-GENERATION CEPHALOSPORIN FOR
ANTIMICROBIAL PROPHYLAXIS IN PANCREATO-
DUODENECTOMY IN PATIENTS WITH INTERNAL
PREOPERATIVE BILIARY DRAINAGE**

Sugiura Teiichi, Sano Shusei, Okamura Yukiyasu, Ito Takaaki, Yamamoto Yusuke, Ashida Ryo, Ohgi Katsuhisa, Uesaka Katsuhiko

Division of Hepato-Biliary-Pancreatic Surgery, Shizuoka Cancer Center, Shizuoka, Japan

Actuality. When a patient undergoes external preoperative biliary drainage (PBD), a prophylactic antibiotic can be selected based on the susceptibility of biliary microorganisms sampled through the external conduit before surgery, which reduces the incidence of postoperative infectious complications after PD. However, it is impossible to obtain bile cultures before surgery in patients who have undergone internal PBD.

The aim. The aim of the present study was to investigate whether the incidence of surgical site infection (SSI) following pancreatoduodenectomy (PD) decreased after changing the prophylactic antibiotic to a third-generation cephalosporin in patients with unknown preoperative bile culture results after biliary drainage.

Materials and methods. In a retrospective study of 138 PD patients who underwent endoscopic biliary stenting and for whom recent preoperative bile culture results were unavailable, cefazolin sodium hydrate (CEZ) was administered as perioperative prophylactic antibiotic therapy during

from 2010 to 2014 (n = 69), whereas ceftriaxone (CTRX) was administered from 2014 to 2017 (n = 69) based on the results of institutional culture surveillance. The incidence of SSI was compared between two groups and the risk factor of SSI was also evaluated.

Results. The incidence of overall SSI in the CTRX group was significantly lower than that in the CEZ group for both Clavien-Dindo (C-D) grade \geq II (28% vs 52%, $p=0.005$) and C-D grade \geq IIIa (20% vs 41%, $p=0.016$). A multivariate analysis revealed that the prophylactic administration of CEZ was an independent risk factor for SSI both C-D grade \geq II and C-D grade \geq IIIa (odds ratio [OR] 2.56; $p=0.019$, OR 3.03; $p=0.020$, respectively). In the CEZ group, most of the patients with positive perioperative cultures had enterobacteriaceae which were intrinsically resistant to CEZ, and most were susceptible to CTRX.

Conclusion. The prophylactic administration of third-generation cephalosporin reduced the incidence of SSI following PD in patients who underwent preoperative endoscopic biliary stenting.

399

SYSTEMATIC REVIEW OF SPONTANEOUS INTRAHEPATIC BILE DUCT PERFORATIONS

Fatih Sumer, Cuneyt Kayaalp

Inonu University, Department of Surgery, Malatya, Turkey

Aim: Our objective was to lead the clinicians about the non-traumatic intrahepatic bile duct (IHBD) perforations.

Methods: PubMed/Medline and Google-Scholar databases were searched for IHBD perforations. Patients with traumatic, post-surgical or interventional IHBD perforations, perforations from gallbladder, extrahepatic bile ducts, gastrointestinal tract or from an obvious liver pathology were excluded. No restrictions were made on age, gender, region, race, language, country or journal.

Results: Total 62 cases were found. There was no gender difference (47% male, 53% female). The median age was 74 (ranged 45-92). Clinical presentation was a generalized biliary peritonitis (61%) or a perihepatic bilioma (39%). Mostly (96.3%) there was an underlying bile duct obstruction that was away from the perforated IHBD. Distal obstruction was stones (62.9%), parasites (18.5%) or tumors (11.2%). Surgeons frequently (65.5%) reported a difficulty to find out the origin of biliary peritonitis or bilioma during surgical explorations. IHBD leaks were mainly from the left liver (83.9%), particularly near from ligamentum Teres hepatis. Overall mortality was 27.3% and the mortality decreased with elimination of peritonitis, resolving the distal common bile duct obstruction and avoiding the liver resections to the perforation area.

Conclusion: IHBD perforation due to an extrahepatic bile obstruction is an emergency setting usually in aged people and carries a high mortality risk. Elimination of the underlying

biliary obstruction and treatment of the bile peritonitis is enough for the treatment. Avoiding hepatic resection including the perforation area can decrease the mortality.

400

PATTERNS OF INTERSTITIAL GRAFT GLUCOSE METABOLISM AFTER DECEASED DONOR LIVER TRANSPLANTATION IN THE CASES OF PRIMARY NON-FUNCTION, EARLY ALLOGRAFT DYSFUNCTION, HEPATIC ARTERY THROMBOSIS AND NORMAL POSTOPERATIVE COURSE

A. Sushkov, V. Rudakov, D. Svetlakova, K. Gubarev, A. Artemiev, S. Voskanyan

State Research Center Burnazyan FMBC of the FMBA of Russia, Moscow, Russia

Background. The incidence of early allograft dysfunction (EAD) after deceased donor liver transplantation (LT) varies between 23% and 56%. An irreversible form of EAD (primary non-function graft, PNF) is observed in 2% - 8% of cases. The standard blood biochemistry and coagulation tests have relatively low sensitivity and specificity as well as significant delay in EAD diagnosis. Since the poor initial graft function is the leading cause (up to 50%) of early post-transplant mortality, a simple and reliable method for determining the graft function is still required.

Object. To identify the association between graft interstitial glucose (iGLU), lactate (iLAC), pyruvate (iPYR) concentrations, initial graft function and clinical outcomes during the first week after LT.

Materials and Methods. "Prospective non-randomized observational clinical study of glucose metabolism patterns in the liver graft for early diagnosis of its dysfunction after transplantation" was started in March 2018. After graft reperfusion hepatic microdialysis catheter (M Dialysis AB, Sweden) was inserted in parenchyma. The samples of interstitial fluid were collected continuously during the first post-transplant week and iGLU, iLAC, iPYR concentrations were measured every 2-3 hours (ISCUS Clinical Microdialysis Analyzer, M Dialysis AB, Sweden). EAD and PNF were diagnosed with K. Olthoff, 2010 Criteria and UNOS Criteria, respectively. Three different cases of post-transplant course were identified: normal graft function, EAD with hepatic artery thrombosis (EAD+HAT) and PNF and presented below. Results. Full liver grafts from standard criteria brain-dead donors were used for transplantation. Organs were preserved in histidine-tryptophan-ketoglutarate solution with cold ischemia time 8H (N), 9H (EAD+HAT) and 11H (PNF). The degree of macrovesicular hepatic steatosis was below 10% for all grafts. Recipients were males aged 51 ye (N), 45 ye (EAD+HAT) and 41 (PNF) with liver cirrhosis and pre-transplant MELD scores 13, 16 and 17, respectively. The normal pattern of intra-graft glucose metabolism

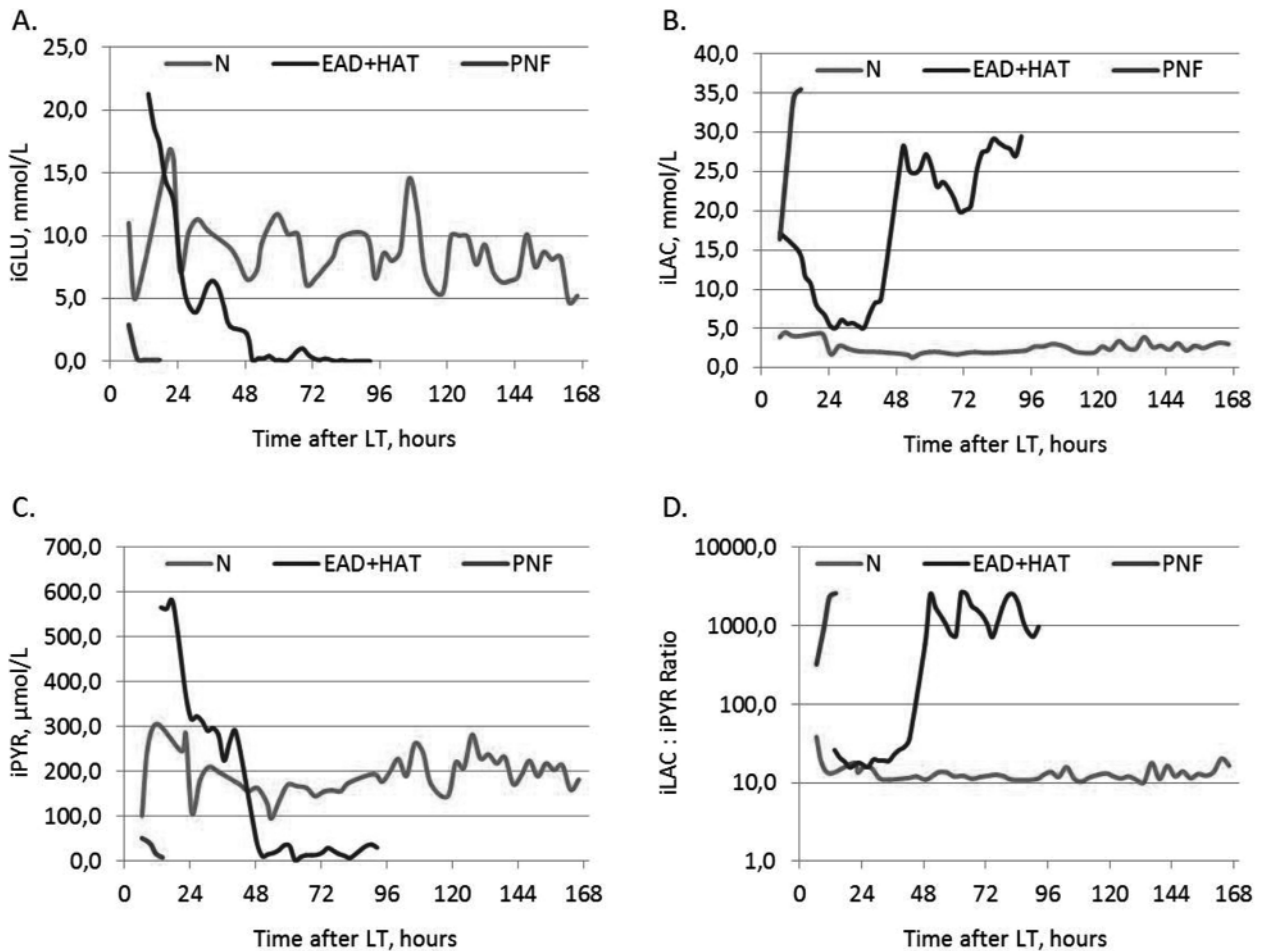


Figure 1. Different patterns of intra-graft glucose metabolism early post liver transplantation. (A) Glucose. (B) Lactate. (C) Pyruvate. (D) Lactate : Pyruvate Ratio (Log –scale). N – normal initial graft function; EAD+HAT – early allograft dysfunction complicated with hepatic artery thrombosis (36-h after procedure); PNF – primary non-function.

(Fig.1 - green) is characterized by stable level of iGLU (5,0 – 20,0 mmol/L), iLAC rapid decline below 5,0 mmol/L, iPYR concentrations in the range 100 – 300 µmol/L and 10 - 30 iLAC : iPYR Ratio. Initial high values of iGLU (> 20 mmol/L), iLAC (> 15 mmol/L) and iPYR (> 500 µmol/L) with iLAC : iPYR Ratio < 50 and trend to decline within 24H were observed in the case of EAD (Fig 1 – dark-blue). After 36H post-transplant the HAT was diagnosed (ultrasound, computed tomography), which was followed by iGLU and iPYR decrease to 0, iLAC and iLAC : iPYR Ratio increase over 25 mmol/L and 1000, respectively. Despite the attempt of endovascular thrombosis correction, recipient died on the 5th post-transplant day. The absence of available donor organ is not

allowed to perform retransplantation. PNF graft (Fig. 1 – red) demonstrated initial low iGLU (< 5 mmol/L) and iPYR (< 50 µmol/L) levels and very fast growth of iLAC (> 30 mmol/L) and iLAC : iPYR Ratio (> 1000). Severe multiorgan failure progression made the patient not suitable for repeat LT and lead to death in 14H after surgery.

Conclusion. Monitoring interstitial glucose and its metabolites concentrations is a powerful method for initial graft function assessment and vascular complications diagnosis early after LT.

Disclosure. This study was supported by the Russian Science Foundation (grant #17-75-10010).

401**SAFETY AND EFFICACY OF DIRECT ANTIVIRAL AGENTS IN TREATMENT OF HCV RECURRENCE AFTER LIVER TRANSPLANTATION: A RUSSIAN MULTICENTER EXPERIENCE****V. Syutkin, E. Bessonova, M. Davydenko***State Budgetary Health Care Institution "Institute for Emergency Medicine named after N.V. Sklifosovsky", Moscow, Russia*

Actuality. By now many DAAs are approved for treatment HCV in liver transplant recipients (LTR), and the guidelines are changing very fast. Therefore, the analysis of the routine practice results from any parts of the world becomes especially important.

The purpose of the study. To determine the efficacy of DDA in LTR in routine clinical practice in Russia transplant centers To determine the efficacy of DDA in LTR in routine clinical practice in Russia transplant centers.

Materials and methods: We analyzed the results of antiviral treatment (AVT) with DAAs (\pm RIBA) of 89 LTR in 3 Russian transplantation Centers. All pts had HCV RNA at liver transplantation and follow-up after AVT at least 12 weeks (Me 14 Mo.) Two LTR were treated twice. Six DAAs combinations were assessed: 1) ritonavir-boosted paritaprevir, ombitasvir, dasabuvir (PrOD); 2) daclatasvir (Dac)+asunaprevir (Asuna); 3) sofosbuvir (Sof)+RIBA; 4) Sof and simeprevir (Sim); 5) Sof/ledipasvir (Led); 6) Sof/Dac.

Results. 82 (92%) LTR achieved sustained virologic response at week 12 FU (SVR12). Seven LTR with genotype 1b relapsed (Table). Several patients developed anemia associated with RIBA, with preliminary AVT cessation in one case. Two LTR receiving sof/dac and PrOD showed a significant transient increase of ALT, despite virologic response was achieved. ALT normalization was not obtained in 3 LTR with steatohepatitis and in 2 LTR with biliary complication, but all these patients achieved SVR12. HCC recurrence occurred in 1 case during AVT and another one after AVT resulting in death. On AVT reactivation of HBV observed in 3 patients.

Conclusion: SVR12 in HCV hepatitis recurrence after liver transplantation could be achieved in 92% of 12 weeks AVT. These results correlate with data of other transplantation centers studies. The effectiveness of AVT does not depend on the HCV genotype and fibrosis stage. The feasibility of ribavirin adding to the DAAs is controversial. Further research required to determine AVT influence on transient ALT elevation, the rate of HBV reactivation and the incidence of HCC progression.

402**EVOLUTION OF SURGICAL TACTICS IN THE TREATMENT OF SYNCHRONOUS COLON AND KIDNEY NEOPLASMS****I. Takorov, Ts. Trichkov, R. Kostadinov, M. Iakova, I. Vasilevski, V. Mihaylov, Ts. Lukanova, E. Odisseeva, N. Vladov***Military Medical Academy, Sofia, Bulgaria*

Objectives. Synchronous tumors are rare and may relate to a certain syndrome manifested by a combination of neoplasms. In most cases, these tumors are found accidentally in the process of primary tumor staging. The detection rate of synchronous blastomas has increased over the past decades due to the advance and more frequent use of imaging technologies. A number of cases of colorectal carcinoma and concurrent incidental renal tumors have been reported in the recent years, with their incidence rates varying as reported by different authors (0.043-4.85%).

Methods. Four cases diagnosed with synchronous colorectal and renal neoplasms who underwent surgical treatment between 2009 and 2017 are presented. The average age of our patients was 52.5 years (43 ÷ 63), and the female/male ratio was 1:1. Colorectal carcinoma was the initial diagnosis, and renal tumors were accidentally detected by CT scan in the staging process.

Results. All patients underwent one-stage surgical procedures: two patients underwent open and two laparoscopic procedures. Three of the patients had combination of rectal and left kidney cancer, and one patient had ascending colon cancer and right kidney cancer.

Conclusion. Due to the increased frequency of synchronous colorectal and renal tumors, the diagnosis of either neoplasm always requires the use of imaging techniques. Additionally, the resections should be one-stage procedures, laparoscopic if possible, and performed by experienced surgeons. Due to the low incidence rate of these neoplasms, additional studies are needed to provide clarity on both their etiology and therapeutic methods.

403**SINGLE INCISION TRANS UMBILICAL APPENDECTOMY: PRONS AND CONS****Tamer Moahamed Said Abdel Abky Salama¹, Soliman Mohamed soliman², Karim fahmy³**¹*In ain shams university,* ²*Air force specialized hospital*³*Ain shams specialized hospital*

Introduction. Acute appendicitis is one of the most commonly encountered surgical problems in everyday practice. In the era of cosmetic awareness, trans umbilical appendectomy appear as an attempt to remove appendix in

acute appendicitis with avoid scarring through the natural orifices (NOTES), however the safety of this new technique, although scar-less, is as yet unknown. In this study we try to investigate safety and feasibility of removal of the appendix through trans umbilical incision in acute appendicitis. Patient and methods. From August 2016 to March 2018, 45 patients were operated by this method in general surgery department in Ain shams university hospital and Air force specialized hospital. Out of them, 18 were males and 27 females. Mean age was 28.6 years (range, 14-51). Mean body mass index was 22.3 kg/m² (range, 15.8-30). All patients were complaining from symptoms of acute appendicitis not more than 24 hour. Preoperative, intraoperative and postoperative data were collected.

Results. Attempts to deliver the appendix through the umbilicus were successful in 40 cases. 5 unsuccessful case were converted to standard laparoscopic appendectomy due to advanced inflammation which made the appendix adherent to the lateral pelvic wall. None of patients needed conversion to an open approach Mean operative time was 43 min (range, 28-85) with 1.8% conversion-rate to conventional laparoscopy. Average blood-loss was 15 ml (range, 10-25). We had one caecal injury, which was managed intraoperative, one patient developed wound infection which was treated with regular dressings and antibiotics. Patients were discharged after an average 1.2 days (range, 1-3) and all patients returned to work within 7 days. The scars had impeded in the umbilicus giving scar less abdomen appearance 4 weeks after the operation.

Conclusion. From our initial experience with a small number of cases we believe trans-umbilical appendectomy is safe procedure with excellent cosmetic results. However more research study with large number of cases is recommended to put an accurate guidelines for this technique.

404

THE TECHNIQUE OF RADICAL EN BLOC LYMPH NODE DISSECTION FOR HILAR CHOLANGIOCARCINOMA

Tan Xianglong, Liu Rong, Zhangxuan, Song Dongda, Wang Fei

Background: The radical en-bloc lymph nodes dissection for hilar cholangiocarcinoma was considered as an essential part of treatment. The efficiency of robotic surgery to achieve radical resection for hilar cholangiocarcinoma remains controversial. We aim to evaluate robotic approach for lymph nodes dissection in hilar cholangiocarcinoma.

Methodology: All the cases of hilar cholangiocarcinoma underwent radical resection. We concluded a series of methods for the radical en bloc lymph node dissection. 1. We dissected the lesser omentum from the middle to the right along with lesser curvature of stomach and liver lower edge. 2. We dissected the hepatic artery from the No. 8

lymph nodes to the No. 9 lymph nodes to exposition of celiac trunk. 3. Dissection of the lymph nodes from celiac trunk to inferior vena cava. 4. We dissected the hepato-duodenum ligament to clear the soft tissue around the common bile duct, hepatic artery and portal vein. 5. We performed the Kocher maneuver and then dissected the No.13,16 lymph nodes.

Results: Radical lymph nodes dissection are completed. In the early stage, the en bloc dissection is difficult. but after we had performed 10 cases of operation, we can complete dissection easily.

Conclusions: Robotic operation can achieve the goal of radical en bloc lymph nodes dissection for hilar cholangiocarcinoma

405

USING OF A NON-INVASIVE METHOD OF ASSESSMENT OF THE FUNCTIONAL STATE OF RESIDUAL LIVER PARENCHYMA IN SURGICAL TREATMENT OF THE PATIENTS WITH FOCAL LIVER FORMATIONS

S. Tarasenko, U. Juchkova, A. Kopeykin, T. Rachmaev, I. Baconina

Ryazan State Medical University, Ambulance hospital, Ryazan, Russian Federation

Relevance. Acute hepatic failure – one of the most seriously complication in hepatobiliary surgery, occupying a leading position in the structure of mortality after extensive hepatic resection. The aim of the study was a determination the effectiveness of a non-invasive preoperative assessment to evaluate the functional state of residual liver parenchyma in order to prevent the development of acute hepatic failure.

Materials and methods. Was conducted a prospective cohort study. Were examined 76 patients with focal liver formation. The patients were included in the study by forming a representative sample according to inclusion and exclusion criteria, adopted for the needs of this study. In the first group was included 46 patients, who were examined using the method of a non-invasive preoperative assessment of the functional state of residual liver parenchyma, which developed by the authors. The definition of the "resectional index" (IR) was made using the following formula: $IR = V_{int} / TP (U)$, where V_{int} - the volume of intact liver parenchyma (cm³); TP - total protein of blood serum (g /l). The main method for determining the volume was selected ultrasound diagnostic. A standard technique was used to determine the size of the lobes of the liver. The second group consisted of 30 patients, whose results of surgical treatment were analyzed retrospectively, based on "statistical card of the patient leaving hospital". The present sample was representative; studied groups were comparable in all indicators.

Results. Major hepatic resections were performed in 26

(56.52%) patients in the primary and 20 (66.67%) in the control group. The volume of residual parenchyma (M + sd) in the main group of patients was 648,158 + 227.3 cm³ (52.226 + 25.342%). The volume of intraoperative blood loss was 1137.609 + 701.45 ml and 1173.667 + 786.9 ml in the main and control respectively, was not statistically significant ($p = 0, 8352$). The complications were distributed according to the Dindo-Clavien classification scale: life-threatening complication rate was 8.7% and 26.67%, severe postoperative hepatic-cell insufficiency was detected in 2.17% and 16.67% of patients in the main and control group. The differences were statistically significant ($p < 0, 03$). Was defined value of the "resectional index" (more than 20 U), that statistically significantly increased the risk of severe postoperative complications, in particular an acute hepatic failure (exact two-sided Fisher test, $p = 0, 0171$).

Conclusions. Was shown a high efficiency of a non-invasive preoperative assessment to evaluate the functional state of residual liver parenchyma in order to prevent the development of acute hepatic failure. Was defined value of the "resectional index" the exceeding of which statistically significantly increased the risk of severe postoperative complications. The application of the "resectional index" may be recommended in order to forecast development of acute hepatic failure when planning treatment of patients with focal liver formation.

406

COMBINED LAPAROSCOPIC APPROACH FOR THE TREATMENT OF STRANGULATED INGUINAL AND FEMORAL HERNIA

E. Tarasov¹, A. Salemianov¹, E. Nishnevich²

¹MAU GKB 40, Russia, ²UGMU, Russia

Combined laparoscopic approach for the treatment of strangulated inguinal and femoral hernia. Using the traditional open approach to strangulated inguinal and femoral hernia has several problems, such as difficulty of evaluation viability of strangulated bowel, high risk of contamination of the mesh, complexity of differentiation tissues if hernia is recurrent. Assessment possibility of using laparoscopic approach for the treatment of strangulated inguinal and femoral hernia. Since 2017 combined laparoscopic approach for the treatment of strangulated inguinal and femoral hernia is used in our clinic and 7 patients underwent laparoscopic exploration for strangulated inguinal and femoral hernia followed by TEP repair. All the operations were performed with the patient under general anesthesia. The first stage was performed by a standard diagnostic video-laparoscopy. A 10-mm trocar for the camera was introduced intraperitoneally below the umbilicus by open technique, and the abdomen was insufflated with carbon dioxide (CO₂) at a pressure of 12 mmHg. Second 5-mm trocars was placed

at the level of the umbilicus on the side of strangulation. If needed the third 5-mm trocar can be placed opposite the second one. The strangulated organ was gently retracted into the abdominal cavity and inspected. In some cases, manual compression from the outside was required. If no bowel resection was needed, the peritoneal cavity was desufflated, the all trocars removed. 11-mm balloon-tip port is then inserted into the preperitoneal space and inflated. A 10-mm, 0°-angle laparoscope is inserted and used to dissect the tissues in the preperitoneal space. After that balloon-tip port was removed and Hasson trocar was placed. The preperitoneal space was insufflated with CO₂ at a pressure of 12 mmHg. Two additional 5-mm trocars were placed in the lower midline into the preperitoneal space. A 10x15-cm polypropylene mesh was used for the repair as we practice routinely in TEP hernia repair. Of the 7 patients, 3 had strangulated inguinal hernia and 4 had strangulated femoral hernia and included 3 male and 4 female. Reduction of the strangulated organ was straightforward, and no bowel resection was needed. The mean operative time was 80 min, and the hospital length of stay was 4 days in all cases. None of the patients needed opioid analgesics. No major complications or wound or mesh infections occurred. Combined laparoscopic repair can be used instead traditional open techniques and has advantages such as such as low risk of contamination of the mesh, possibility to evaluate viability of strangulated bowel, lower postoperative pain, early discharge.

407

ENHANCED RECOVERY AFTER SURGERY PROTOCOL FOR THE HIGH-RISK PATIENT IN RECONSTRUCTIVE ESOPHAGEAL SURGERY

I. Tarasova¹, A. Tskhovrebov², T. Bitarov², I. Boeva², V. Nikoda², A. Shestakov^{1,2}

²Petrovsky National Research Center of Surgery, Moscow, Russia

H. Kehlet introduced the concept of enhanced recovery after surgery (ERAS) to colorectal surgical practice in 1990's and firstly applied it for low or medium surgical risk patients. Nowadays this perioperative rehabilitation protocol has been successfully applied to different surgical fields, including high-risk surgical procedures such as esophagectomy, pancreatoduodenal and liver resections. Currently, a lot of patients in esophageal surgery are elderly with significant co-morbidity, have compromised nutritional status, so they are considered as a high-risk patients. This study aimed to investigate the safety and feasibility of ERAS protocol application in esophageal reconstructive surgery for a high-risk patients.

Materials and methods. Between 2014 and 2018 years in the Surgical Department I of Petrovsky Research Center of Surgery 62 patients with different esophageal diseases (esophageal strictures, end-stage achalasia, esophageal

cancer II-III stage) after reconstructive operations (thoracoscopic and open esophagectomy, retrosternal colonic esophagoplasty) in combination with ERAS protocol were observed. The patients were divided into two groups: with the low/medium risk (n = 19, the group I) or the high risk (n = 43, group II). The high-risk criteria had been identified as ASA 3 or 4 class or co-morbidity Charlson's index higher 3. The length of postoperative stay (LOS), the length of intensive care unit stay (LOS-ICU), protocol realization rate (LOS lower 12 days and LOS-ICU lower two days), morbidity and mortality were compared in two groups.

Results. The average age was lower in group I (40,7± 10,1 vs 51,5±15,4 years, p = 0,007), but body mass index (19,8±2,7 vs 21,5±5 kg/m², p = 0,164) and operation time (410±110 vs 443±125 minutes, p = 0,338) were similar. Total LOS was 13 (10,8;23) days in group I and 14 (11;20) days in group II, p = 0,912. LOS-ICU was significantly shorter in the low/medium risk patients, 2 (1,5;3,5) vs. 3,5 (2;4) days, p = 0,041. ERAS protocol realization rate for LOS (<12 days) was 53% in both groups, p = 0,951. LOS-ICU <2 days was achieved in 58% in group I and in 33% in group II, p = 0,063. The postoperative complications rate (Clavien-Dindo class II and III, anastomosis leaks) was similar in both groups. Mortality was 0% in both groups. ERAS protocol can be safely implemented in high-risk patients during esophageal reconstructive surgery without the increasing morbidity. The high-risk patients likely need for longer ICU caring, but postoperative morbidity determines the total LOS both in the low and high-risk groups.

Keywords: reconstructive esophageal surgery, esophagoplasty, ERAS, rehabilitation, high operative risk, postoperative ICU.

408

PREDICTIVE ROLE OF NEUTROPHIL-TO-LYMPHOCYTE, MONOCYTE-TO-LYMPHOCYTE AND PLATELET-TO-LYMPHOCYTE RATIOS IN PATIENTS WITH LOCALLY ADVANCED RECTAL CANCER RECEIVING NEOADJUVANT CHEMORADIATION

Timudom Kitinut¹, Akaraviputh Thawatchai¹, Chinswangwatanakul Vitoon¹, Pongpaibul Ananya², Korpraphong Pornpim³, Petsuksiri Janjira³, Ithimakin Suthinee⁴, Trakarnsanga Atthaphorn¹

¹Department of Surgery, ²Department of Pathology,

³Department of Radiology, ⁴Department of Medicine,

Faculty of Medicine, Siriraj Hospital, Mahidol University, Bangkok, Thailand

Background: Locally advanced rectal cancer was treated by neoadjuvant chemoradiation (nCRT), followed by total mesorectal excision (TME). Tumor regression and pathological posttreatment stage were prognostic for oncological outcomes. Recently, there are several studies reported correlation between cancer-related inflammation, including Neutrophil-to-lymphocyte, Monocyte-to-lymphocyte and

Platelet-to-lymphocyte ratios and unfavorable oncological outcomes. However, the predictive role of these markers to effect of chemoradiation is still unclear.

Materials and methods: One hundred eleven patients with locally advanced rectal cancer who underwent nCRT followed by TME at Siriraj hospital between June 2012 and January 2018 were retrospectively analyzed. Posttreatment pathological stages and ratio of inflammatory markers (Neutrophil-to-lymphocyte, Monocyte-to-lymphocyte and Platelet-to-lymphocyte ratios) were compared.

Results: The entire ratios of inflammatory markers were not significantly different between each posttreatment pathological stage. The ratio of Neutrophil-to-lymphocyte in ypT0, ypT1, ypT2 and ypT3 are 0.24, 2.42, 2.83 and 3.07, respectively (p = 0.54). Monocyte-to-lymphocyte ratio are 0.24, 0.27, 0.28 and 0.36 in ypT0, ypT1, ypT2 and ypT3, respectively (p=0.40) and Platelet-to-lymphocyte ratios in ypT0, ypT1, ypT2 and ypT3 are 101.55, 132.78, 142.02, and 155.68, respectively (p=0.18).

Conclusions: In this dataset of locally advanced rectal cancer treated with nCRT followed by TME, Neutrophil-to-lymphocyte, Monocyte-to-lymphocyte and Platelet-to-lymphocyte ratios are higher in advanced pathological stage, but not reach to statistical significant. Further study in larger population should be done to identify the predictive role of these inflammatory markers.

409

MODERN MANAGEMENT OF OBSTRUCTIVE JAUNDICE SYNDROME OF VARIOUS ETIOLOGIES

D. Toksanbayev^{1,2}, N. Sadykov^{1,2}, N. Sarmanov¹, M. Duisebekov^{1,2}, A. Baizhanov², S. Yakyarova², A. Zhantay²

¹Asphendiyarov Kazakh National Medical University

²MEDITERRA Modern Medicine Center

Almaty, Republic of Kazakhstan

Background. Early identification of jaundice etiology helps to distinguish correct tactics of surgical treatment and symptomatic therapy. The most important component of management of these patients is to clarify the etiology of obstruction of biliary tract, and its decompression. This strategy allows to reduce postoperative complications and mortality, improving the general treatment outcomes.

Aim. To improve the results of treatment of patients with obstructive jaundice of various etiologies, using the minimally invasive methods of decompression of bile ducts.

Materials and methods. The present study demonstrates the results of treatment of 75 patients with persistent or remitting obstructive jaundice of various etiologies, treated from June 2016 to May 2018, in the department of Hepatopancreatobiliary Surgery and Gastroenterology. Depending on the etiology, patients distributed as follows: a tumor of the head of the

pancreas – 20(27,7%); tumor of terminal part of choledochus – 2(2,7%); tumor of the gallbladder – 2(2,7%); tumor of extrahepatic bile ducts – 7(9,4%); tumor of the large duodenal papilla – 4(5,4%); metastatic liver tumors with compression of the bile ducts – 15(20,0%); cicatricial stricture of hepaticocolocholeochus – 8(9,4%); stricture of the terminal part of choledochus, choledocholithiasis 17(22,7%). All patients underwent for 92 interventions. Percutaneous transhepatic cholangiostomy performed in 42 cases: combined external-internal drainage (13), antegrade biliary stenting by a self-expanding nitinol stent (6). Endoscopic retrograde stenting of the bile ducts performed in 36 cases, by plastic (15) or self-expanding (21) stents; in one case, we used the Rendezvous technique. In 14 cases, for patients with choledocholithiasis, performed ERCP with choledocholithoextraction.

Results. Minimally invasive intervention was final palliative procedure for 53(70,7%) patients. Other 22(29,3%) patients, after stabilizing, underwent for the second step of treatment, as: Whipple operation - 1; Expanded right hemihepatectomy -1; Roux-en-Y hepatocojejunostomy - 4; open choledocholithotomy and papillotomy - 9 and laparoscopic cholecystectomy - 7 patients. Dislocation of percutaneous stent observed in 3(4,0%) cases, of endobiliary stent – in 2(2,7%) case. One patient (1,3%) died in postoperative period, because of advanced stage of the disease.

Conclusion. Obstructive jaundice of any etiology should be resolved as quick as possible, to prevent cholangitis, sepsis or progression of liver failure. The method of decompression of the biliary tract depends on the clinical situation and the nature of the pathological process, as well as the experience of specialists and the technical equipment of the hospital.

410

PERFECTION OF DIAGNOSTICS AND TREATMENT OF PATIENTS WITH END-STAGE LIVER DISEASES

D. Toksanbayev, A. Baimakhanov, N. Sadykov, M. Duisebekov, S. Yakyarova, A. Zhantay
Asphendiyarov Kazakh National Medical University, Almaty, Kazakhstan

Background. Despite a lot of solved problems in gastroenterology and hepatobiliary surgery, the problems of diagnostics and treatment of patients with end-stage liver diseases stays significant in modern medicine.

Aim. To optimize diagnostics and treatment methods for patients with end-stage liver diseases (EDSL).

Materials and methods. Between August 2016 and May 2018, in department of Hepatopancreatobiliary surgery and Gastroenterology treated 50 patients with EDSL. Among them, 17 (34%) male patients, and 33 (66%) female patients, in the age between 31 and 80. The indications for hospitalization were: advanced general condition of patient, unclear etiology of liver disease, necessity of prophylaxis of compli-

cations or providing of any surgical actions. Patient's investigation was done according the national protocol of diagnostics and treatment; some additional checkup could be recommended, if necessary. The EDSL patients were presented as a following: liver cirrhosis (LC) patients without hepatocellular carcinoma (HCC) – 29 (58%), and patients with HCC – 21 (42%). The etiology of the disease of patients without HCC: LC/HBV – 2 cases; LC/HBV+HDV – 5 cases; LC/HCV – 16 cases; cryptogenic LC – 6 cases. HCC patients: HCC/LC/HBV – 7; HCC/LC/HCV – 7, HCC/LC/non-viral hepatitis – 2 cases and HCC without LC – 5 cases. 45 (90%) patients had significant complications, as portal hypertension syndrome, presented with ascites, esophageal varices, hypersplenism and hepatic encephalopathy. Patient's condition ranged according Child-Turcotte-Pugh score and MELD score, as most common prognostic scores worldwide. CTP A class was in 16 (35,5%), B class – 14 (31,2%); C class – 15 (33,3%) patients. MELD higher 15 was in 16 (35,5%) patients.

Results. All patients were received the treatment according their complications. 18 (36%) of patients underwent some surgical interventions, as the following. 7 patients – endoscopic ligation of esophageal varices, 3 patients – splenic artery embolization and 8 patients – TACE or liver resection for HCC. No any significant complications or mortality were noted. After general stabilizing of patients and clarifying of diagnosis, 8 (11%) patients were sent to transplant center for including in “waiting list” for the radical treatment.

Conclusion. In the absence of the possibility of radical treatment of patients with EDSL, the strategy to improve the duration and quality of life of patients is most important. In specialized hepatological departments shall follow such patients, with clarifying the etiology of the disease, manage complications, determine contraindications, and finally help patients to achieve the transplant centers for the radical treatment.

411

FETAL LIVER REGENERATION ACTIVITY AFTER LIVER RESECTION

D. Tophuria, M. Matoshvili, Z. Orjonikidze
Tbilisi State Medical University, Tbilisi, Georgia

Backgrounds: The process of liver regeneration is very complex and is dependent on the etiology and extent of liver damage and the genetic background. Liver regeneration is still not fully understood. The liver is a unique organ, and first in line, the hepatocytes encounter the potential to proliferate during cell mass loss. This phenomenon is tightly controlled and resembles in some way the embryonic co-inhabitant cell lineage of the liver, the embryonic hematopoietic system.

Methodology: The experimental research was conducted

on white lab rats. The animals were divided in two groups. First group consists of fetal rats (two weeks old), second group – 5 month age mature female rats. In both of groups was done 25% resection of liver tissue. After 24, 48 and 72 hours was investigated time of maximal activity of DNA, mitochondria synthesis and hepatocytes proliferation.

Results: Laboratory investigations were shown, that after 24 hours in 1-st group was significant increase of mitochondria synthesis. After 48 hours in 1-st group of experimental animals was not changes of hepatocyte size, while in 2-nd group were seen hepatocyte enlargement and temporary increase in numbers of lysosomes, autophagosomes, and micro bodies.

Conclusion: There was the different commencement of DNA synthesis and mitosis in the hepatocytes of 1-st with later extension in the hepatocytes of 2-nd group. Thus, the time of maximal activity was indicated in 1-st group much more earlier than in 2-nd group of experimental animals.

412

LIVER REGENERATION AND CELL-BASED THERAPIES OF LIVER DISEASES

D. Tophuria, M. Matoshvili, I. Amiranashvili, L. Benashvili

Tbilisi State Medical University, Tbilisi, Georgia

Backgrounds: The process of liver regeneration is very complex and is dependent on the etiology and extent of liver damage and the genetic background. Liver regeneration is still not fully understood. The liver is a unique organ, and first in line, the hepatocytes encounter the potential to proliferate during cell mass loss. This phenomenon is tightly controlled and resembles in some way the embryonic co-inhabitant cell lineage of the liver, the embryonic hematopoietic system. The ultimate scientific foundation of both cell therapy of liver diseases and liver tissue and organ engineering is delivered by the in-depth studies of the cellular and molecular mechanisms of liver regeneration. The cellular mechanisms of the homeostatic and injury-induced liver regeneration are unique. Restoration of the mass of liver parenchyma is achieved by compensatory hypertrophy and hyperplasia of the differentiated parenchymal cells, hepatocytes, while expansion and differentiation of the resident stem/progenitor cells play a minor or negligible role. Participation of blood-borne cells of the bone marrow origin in liver parenchyma regeneration has been proven but does not exceed 1-2% of newly formed hepatocytes. Liver regeneration is activated spontaneously after injury and can be further stimulated by cell therapy with hepatocytes, hematopoietic stem cells, or mesenchymal stem cells.

Results: Further studies aimed at improving the outcomes of cell therapy of liver diseases are underway. In case of liver failure, transplantation of engineered liver can become the best option in the foreseeable future.

Conclusion: Engineering of a transplantable liver or its major part is an enormous challenge, but rapid progress in induced pluripotency, tissue engineering, and bioprinting research shows that it may be doable.

413

MULTIPOTENT STROMAL CELLS ROLE IN STIMULATION OF LIVER REGENERATION

D. Tophuria, M. Matoshvili, B. Samkharadze, D. Delibashvili, I Topuria

Tbilisi State Medical University, Tbilisi, Georgia

Aim: To Study the influence of the umbilical cord-derived multipotent stromal cells (MSCs) on recovery of the liver after the subtotal resection, that is, removal of 80% of the organ mass, a renowned model of the small-for-size liver remnant syndrome.

Methods: The MSCs were obtained from the intervacular tissues of umbilical cords, dissected from rat fetuses, by the explant culture technique. The vital labeling of MSCs with PKH26 was carried out on the 3rd passage. The subtotal resection was performed on male Sprague-Dawley rats. The experimental group animals received a transplant 106 MSCs infused into the spleen. Hepatocyte proliferation was assessed by counting of either mitotic figures or Ki67-positive cells in microscopic images. MSC differentiation was assessed with antibodies to hepatocyte-specific marker cytokeratin 18 (CK18), cholangiocyte-specific protein CK19, smooth muscle cell-specific protein α -SMA, the endothelial cell marker CD31, or the active fibroblast marker FAP α . Total macrophages of the liver were selectively stained in cryosections incubated with anti-CD68 antibodies (1:100, Abcam), while the M2a and M2c macrophage populations were selectively stained with anti-CD206 antibodies. Expression of interleukin and growth factor genes was evaluated with PCR-RT.

Results: Intrasplenic allogeneic transplantation of the umbilical cord-derived multipotent stromal cells stimulates reparative processes within the residual liver tissue after subtotal resection (removal of 80% of the organ mass), as indicated by increased rates of hepatocyte proliferation and accelerated organ mass recovery. These effects may result from paracrine influence of the transplanted cells on the resident macrophage population of the liver. The transplantation favors polarization of macrophages to M2 phenotype (the M2-polarized macrophages specifically express CD206; they are known to suppress inflammation and support tissue repair). No differentiation of the transplanted cells into any of the liver cell types have been observed in the study.

Conclusion: We found no direct evidence for the paracrine effect of MSCs on liver regeneration after the subtotal liver resection in rats. However, the paracrine mechanism of the therapeutic activity of transplanted MSC is indirectly

indicated by a decrease in the total number of CD68 + macrophages and an increase in the proportion of M2 pro-repair macrophages in the regenerating liver as compared to animals in which the transplantation was only mimicked.

414

STEM CELL THERAPY DURING HEPATIC PATHOLOGIES

D. Tophuria, M. Matoshvili, R. Khetsuriani, A. Shukakidze, M. Arabuli

Tbilisi State Medical University, Tbilisi, Georgia

Background: Hepatic transplantation is the primary treatment for various end-stage hepatic diseases but is hindered by the lack of donor organs and by complications associated with rejection and immunosuppression. There is increasing evidence to suggest the bone marrow is a transplantable source of hepatic progenitors. We previously reported that multipotent bone marrow-derived mesenchymal stem cells differentiate into functional hepatocyte-like cells with almost 100% induction frequency under defined conditions, suggesting the potential for clinical applications. The aim of this study was to critically analyze the various parameters governing the success of bone marrow-derived mesenchymal stem cell-based therapy for treatment of liver diseases.

Methods: Fulminant hepatic failure with lethal outcome in nonobese diabetic severe combined immunodeficient mice was induced by carbon tetrachloride gavage. Mesenchymal stem cell-derived hepatocytes and mesenchymal stem cells were then intrasplenically or intravenously transplanted at different doses.

Results: Both mesenchymal stem cell-derived hepatocytes and mesenchymal stem cells, transplanted by either intrasplenic or intravenous route, engrafted recipient liver, differentiated into functional hepatocytes, and rescued liver failure. Intravenous transplantation was more effective in rescuing liver failure than intrasplenic transplantation. Moreover, mesenchymal stem cells were more resistant to reactive oxygen species in vitro, reduced oxidative stress in recipient mice, and accelerated repopulation of hepatocytes after liver damage, suggesting a possible role for paracrine effects.

Conclusions: Bone marrow-derived mesenchymal stem cells can effectively rescue experimental liver failure and contribute to liver regeneration and offer a potentially alternative therapy to organ transplantation for treatment of liver diseases.

415

THE HEPATIC STELLATE (ITO) CELL: ITS ROLE IN HUMAN LIVER DISEASE

D. Tophuria, M. Matoshvili, Z. Orjonikidze

Tbilisi State Medical University, Tbilisi, Georgia

Backgrounds: The hepatic stellate (Ito) cell lies within the space of Disse and has a variety of functions. Stellate cells store vitamin A in characteristic lipid droplets. In the normal human liver, the cells can be identified by the presence of these lipid droplets; in addition, many stellate cells in the normal liver express α -smooth muscle actin. In acute liver injury, there is an expansion of the stellate cell population with increased α -smooth muscle actin expression; stellate cells appear to play a role in extracellular matrix remodelling after recovery from injury.

Methodology: In chronic liver injury, the stellate cell differentiates into a myofibroblast-like cell with marked expression of α -smooth muscle actin and occasional expression of desmin. Myofibroblast-like cells have a high fibrogenic capacity in the chronically diseased liver and are also involved in matrix degradation. In vitamin A intoxication, hypertrophy and proliferation of the stellate and myofibroblast-like cells may lead to non-cirrhotic portal hypertension, fibrosis and cirrhosis. In liver tumours, myofibroblast-like cells are involved in the capsule formation around the tumour and in the production of extracellular matrix within it.

Results: The transition of stellate cells into myofibroblast-like cells is regulated by an intricate network of intercellular communication between stellate cells and activated Kupffer cells, damaged hepatocytes, platelets, endothelial and inflammatory cells, involving cytokines and nonpeptide mediators such as reactive oxygen species, eicosanoids and acetaldehyde.

Conclusion: The findings suggest that the stellate cell plays an active role in a number of human liver diseases, with a particular reactivity pattern in fibrotic liver disorders.

Hepatic stellate cell Ito cell Fat-storing cell Lipocyte Fibrosis

416**ANALYSIS OF THE RESULTS OF COMBINED TREATMENT OF PATIENTS WITH COLORECTAL CANCER WITH LIVER METASTASES****M. Trandofilov, E. Prazdnikov, L. Petrov, V. Givotov, N. Vorobyova, S. Kostirev, A. Prohorov, A. Sisova, V. Svetashov**

State budget educational universiti of higher professional education Evdokimov Moscow State University of Medicine and Dentistry under the Ministry of Healthcare of the Russian, Moscow, Russia Federation. Budgetary public health facility Pletneva Municipal Clinical Hospital under the Department of healthcare for Moscow city, Moscow, Russia

Relevance: In the structure of oncological diseases to 90% of liver tumors are metastatic. The most common source is the colorectal cancer - up to 70% due to anatomic-physiological features of the body. The resectability according to the different authors does not exceed 10-25%. The average life expectancy of patients with liver metastases of colon cancer is less than 2 years. In the absence of treatment, the average life expectancy of patients with stage IV less than 1 year. Systemic chemotherapy increases life expectancy to an average of 18 months. Currently, surgical treatment of colorectal cancer metastases in the liver are liver resection and local destruction methods that minimize the number of postoperative complications and volume of damaged tissue.

Object: To increase the effectiveness of treatment of patients with colorectal cancer with metastatic liver lesion.

Materials and methods: This study included 361 patients with colorectal cancer and metastatic liver lesion of I, II, and stage III (Gennari) in treatment for the period from 2002 to april, 2018. All patients received combined treatment. 124 patients were performed liver resection. Right-sided hemihepatectomy – 13, extended right-sided hemihepatectomy – 7, left-sided hemihepatectomy – 10, trisegmentectomy – 38, bisegmentectomy – 35, segmentectomy – 21 cases. In 121 patients was performed radiofrequency ablation of liver metastases. For radio frequency destruction was used by apparatus Cool tip power of 200 Watts. 74 patients were performed the microwave destruction of the tumor of the liver unit AveCure MWG881 with the power of 34 Watts. In 20 patients was performed laser ablation of liver metastases. 53 patients underwent transarterial (52) and portal (2) chemoembolization of liver tumors with drug doxorubicin, Geosphere 150-250 ng.

Results: At the time of resection of the liver life expectancy annual made – 84.2% to a two-year – 74,3 %, three-year – 61,5 %, five-year to 23.7 %. When performing RFA of liver metastases life expectancy annual 73.5 %, a two-year – 53.3 %, three-year to 32.1 %, five-year to 21.5 %. When performing MVA liver metastases life expectancy annual amounted to 78.5 %, two-year – 63,3 %, three years – 58.3 %.

Conclusions: Use in complex treatment of patients with colorectal cancer and liver metastases chemotherapy combined with targeted therapy, radiofrequency and microwave ablation allows to increase the resectability of patients to 35-40%. The use of radiofrequency and microwave ablation in somatically burdened patients reduces the risk of surgical intervention due to miniinvasive and littletraumaticity.

417**THE USE OF LASER ABLATION IN THE COMPLEX TREATMENT OF METASTATIC LIVER DAMAGE****M. Trandofilov, E. Prazdnikov, L. Petrov, V. Givotov, N. Vorobyova, S. Kostirev, A. Prohorov, A. Sisova, V. Svetashov**

State budget educational universiti of higher professional education Evdokimov Moscow State University of Medicine and Dentistry under the Ministry of Healthcare of the Russian, Moscow, Russia Federation. Budgetary public health facility Pletneva Municipal Clinical Hospital under the Department of healthcare for Moscow city, Moscow, Russia

Relevance: In the structure of oncological diseases to 90% of liver tumors are metastatic. The most common source is the colorectal cancer - up to 70% due to anatomic-physiological features of the body. The resectability according to the different authors does not exceed 10-25%. The average life expectancy of patients with liver metastases of colon cancer is less than 2 years. In the absence of treatment, the average life expectancy of patients with stage IV less than 1 year. Systemic chemotherapy increases life expectancy to an average of 18 months. Currently, surgical treatment of colorectal cancer metastases in the liver are liver resection and local destruction methods that minimize the number of postoperative complications and volume of damaged tissue.

Object: To increase the effectiveness of treatment of patients with colorectal cancer with metastatic liver lesion.

Materials and methods: The results of treatment of 28 patients with metastatic liver damage and using laser ablation technique for the period from March 2017 to April 2018, women 17, men 11, average age was 61 ± 2.7 years, the size of formations was from 10- 40mm, the number is from 1 to 2 knots. All patients in the preoperative stage performed removal of the primary focus in the volume of R0 and lymphadenectomy D1, D2 and are at different stages of chemotherapy. Dynamic observation revealed metastatic liver damage, followed by histological confirmation. Laser ablation of liver formations was performed percutaneously transhepatic, under the control of ultrasonic scanning in real time. The introduction of optical fibers was carried out using the technique of "free hand" or with the help of an adapter. For laser ablation, ECHO LASER, manufactured in Italy, was used, a 4-channel multiple source with a complex ultra-

sound system, using laser radiation with a wavelength of 1064 nm. For each session, the fixed power output was 5.0 W. Single exposure for one fiber lasts 360 seconds, the amount of radiated energy is 1800 J per fiber. Depending on the volume of formation, from 1 to 4 light guides were used. During the procedure, with the formations > 3 cm, the reverse effect technique was used. Control of the effectiveness of the effect was carried out by ultrasound, MRI and CT with intravenous bolus enhancement in dynamics.

Results: In the early postoperative period pain syndrome was noted, within 3 days, stopped with the use of analgesics, biochemical analyzes (ALT, AST, AP) were observed for 10 days. In the early postoperative period, formation under the capsular hematoma, in the area of the light guide, was not required, which did not require surgical intervention. In 4 patients, at 6 months, progression of the disease was noted, followed by liver resection. Morphological examination of the ablation zone shows pathomorphosis of the fourth degree (according to Lukoshevich). The average bed-day was 5 days.

Conclusions: The use of laser ablation allows several nodes to act simultaneously. Due to low traumatism and minimally invasive, it is possible to perform surgical intervention in somatically burdened patients who can not perform liver resection, as well as possible use in the presence of a pace-maker.

418

MINIMALLY INVASIVE SURGERY (ESOPHAGECTOMY) IN PATIENTS WITH END-STAGE ACHALASIA

A. Tskhovrebov^{1,2}, **A. Shestakov**^{1,2}, **I. Tarasova**², **T. Bitarov**¹, **I. Boeva**¹, **T. Petrosyan**¹, **O. Rykov**¹, **I. Selivanova**¹

¹*Petrovsky National Research Centre of Surgery, Moscow, Russia*

Actuality. The rising interest to the surgical treatment of the end-stage achalasia is explained by high postoperative complication rates as well as by the absence of standard approaches to the treatment strategy in these patients. Video-assisted esophageal surgery using minimally invasive total esophagectomy (with thoracoscopic and laparoscopic approaches) in the treatment of the end-stage achalasia is uncommon because of several technical aspects, including esophagus and mediastinum anatomy distinctions and limited manipulation in the right pleural cavity filled with megaesophagus with hypertrophic edematous wall.

The aim. To investigate the possibilities of the minimally invasive surgical interventions in the treatment of the end-stage achalasia.

Materials and methods. Four patients with 10-year history of end-stage achalasia were treated in the Surgical Department I (Esophageal and Gastric Surgery) of Petrovsky National

Research Centre of Surgery in 2016-2017 years. One patient with gastrostomy had the critical stricture of the low esophagus with stage IV dysphagia after Heller's myotomy. Three patients had an inefficient dilatations background.

Results. All patients underwent thoracoscopic subtotal esophageal resection with laparoscopic-assisted gastric tube esophagoplasty. Thoracoscopic mobilization of the esophagus in the prone-position using three ports was performed in three patients, fourth port was insert in one case. The reconstructive stage was conducted by laparoscopic stomach mobilization with gastric tube formation through 4 cm minilaparotomy and further cervical esophagogastric «end-to-end» hand-sewing anastomosis. Microjejunostomy for early postoperative enteral nutrition was formed in all cases. Average operation time was 566 minutes, blood loss – 200 ml. Average ICU length of stay (LOS) was less than 24 hours, average postoperative LOS – 12 days. In one case postoperative LOS was 31 days because of the anastomosis leak development, which was successfully treated conservatively without any surgical intervention. Mortality rate was 0%.

Conclusion: Thoracoscopy provided good intraoperative visualization during thoracic esophagus mobilization, high-quality hemostasis and decreased the risk of the intraoperative complications, especially intrathoracic organs damage. The thoracoscopic esophageal mobilization with laparoscopy-assisted esophagoplasty is safe and can be considered a "procedure of choice" in the surgical treatment of the end-stage achalasia in specialized centers with experienced surgeons.

419

THE STAGE PREPARATION AND RECONSTRUCTION AFTER BILIARY TRACT INJURY

D. Tsoi
Australia

Actuality: The problem of biliary tract injury after introduction of minimally invasive surgeries acquires an additional urgency.

Goals: The aim of this study was to improve the results of treatment and quality of life of patients with biliary tract injury that occurred in the general network of unspecialized surgical hospitals.

Materials and methods: In case of biliary tract injury in the region's general surgical network physicians of hepatopancreatobiliary surgery department consulted of management on site or provide transfer to a specialized department to our hospital. In the second stage, during 4-6 months by the controlled biliary hyperpression, patient is pre-prepared for a planned reconstructive surgery according to the indications. The third stage in the conditions of our regional clinic, after a detailed study of the anatomy of the liver (MSCT,

MRI, 3D modeling), perform a reconstructive surgery - Roux-en-Y hepaticojejunostomy. The loop of the jejunum 60 - 100 cm long. In all cases, achieving tightness, a precision anastomosis was formed on the half-closed stents, the outer ends of which were taken out to the skin through the blind end of the Roux-en-Y jejunum loop. From 2008 to the present, 178 Roux-en-Y hepaticojejunostomy in our clinic were performed for iatrogenic strictures of the bile ducts. In 30% of patients, anastomosis was required to include 2 to 5 segmental ducts. For optimal detection of biliary ducts, part of the patients had to perform a resection of the parenchyma of the gates of the liver with the Cavitron Ultrasonic Surgical Aspirator (CUSA). In 12 patients (6.7%), biliary reconstruction was accompanied by resection of segments or a fraction of the liver due to the presence of secondary biliary cirrhosis and (or) cho-langiogenic abscesses. In 10 patients (5.6%), an atypical resection of the IV b segment was performed to form hepatitis yunoanastomosis for access to confluence and lobar ducts. Thus, the completion of the operation by through transhepatic drainage and the need for an extra long (1.5-2 year) formation of anastomoses on them was not required. Results: Bile leakage from the anastomosis developed in 16 (8.9%) patients and required relapo-rotomy in 2 cases. The stricture of Roux-en-Y hepaticojejunostomy developed in 20 patients (11.2%) during the observation period from 1 to 7 years. Ten patients underwent percutaneous transhepatic cholangiostomy with subsequent successful balloon dilation of the anastomosis. 10 patients (5.6%) underwent to a second reconstructive operation. Reflux-cholangitis in the long-term was diagnosed in 8 patients (4.5%).

Conclusions: The stage surgical preparation and delayed biliary reconstruction in a specialized clinic is an effective way of treatment patients with iatrogenic bile duct injury.

420

MINIMALLY INVASIVE TECHNOLOGIES IN THE TREATMENT OF OBSTRUCTIVE COLONIC OBSTRUCTION

B. Tsuleiskiri, P. Yartsev, M. Rogal

Russia

Introduction. In the structure of cancer incidence, colon cancer ranks second in women, second only to breast cancer, and 3 in men, with a complicated course of 80% according to the literature. Due to the fact that most patients admit to the hospital with acute bowel obstruction, performing radical surgery with the formation of primary

intestinal anastomosis is associated with a high risk of postoperative complications. In this case, colon cancer is the main cause of the development of obstructive intestinal obstruction, the incidence of obstruction is 75-80% of cases. High rates of postoperative complications in 40-80% of cases and lethality of 23-52% remain, which is associated, including the risk of formation of interintestinal anastomosis in conditions of intestinal obstruction.

Purpose of the study. To improve the results of surgical treatment and the quality of life of patients with colon cancer complicated by intestinal obstruction.

Materials and methods: Between 2010 and 2018, 249 patients were treated with obstructive colonic obstruction. Of these, men were 134 (53.8%), and women 115 (46.2%), respectively. The average age is 64 ± 3.4 years. All patients who received a clinical picture of colonic obstruction were urgently carried out x-ray examination, ultrasound of the abdominal cavity organs, contrast enema or colonoscopy. In 54 (21.7%) patients, a two-stage procedure was used: in the first stage, an endoscopic probe was performed proximal to tumor stenosis or a self-expanding stent, and a second stage performed video laparoscopic resection of the intestinal tract.

Results. Endoscopic colonic drainage of the colon proximal to the tumor was performed in 51 patients (94.4%); The stenting technique was successfully performed in 3 (5.6%) patients. An unsuccessful attempt to use a two-stage procedure in 21 (28%) patients, the cause of which was complete obturation with a tumor of the lumen of the intestine, which was an indication for emergency surgical treatment. During the endoscopic stage, there was one complication (2.04%) - a suprastenotic rupture of the colon above the tumor narrowing. Laparoscopic resection of the colon was performed after resolution of obstructive intestinal obstruction after 6-8 days. Resection of the sigmoid colon in 30 patients (55.6%), left-sided hemicolectomy in 9 patients (16.7%), right-sided hemicolectomy in 13 patients (24%), transrectumectomy in 2 patients (3.7%). All patients developed primary inter-intestinal anastomosis with staplers in 39 patients (72.2%), manual seam - 15 patients (27.8%). Postoperative complications were in 7 patients (12.9%): interstitial anastomosis failure was 2 (3.7%) (IIIb by Clavien-Dindo), pulmonary embolism - 2 (3.7%) (IVa by Clavien-Dindo), suppuration of the postoperative wound - 5 (9,3%) (I according to Clavien-Dindo). There were no lethal outcomes.

Conclusion: Two-stage method of treatment of patients with complicated colon cancer allowed a number of patients to perform a minimally invasive operation with the formation of a primary anastomosis during the period of a single hospitalization.

421

PREDICTION OF POST-HEPATECTOMY LIVER FAILURE AFTER MAJOR HEPATIC RESECTIONS

**K. Tupikin¹, V. Vishnevsky², M. Baydarova²,
D. Panchenkov¹**

¹*Moscow State University of Medicine and Dentistry
named after A.I. Evdokimov, Moscow, Russia*

²*A.V. Vishnevsky National Medical Research Center of
Surgery Moscow, Russia*

Despite the introduction of tissue-preserving technologies, large resections (≥ 3 segments of the liver) still remain the most radical way of surgical treatment for patients with primary and secondary liver tumors. Nevertheless, only 10-30% of patients can be subjected to surgical treatment because the increased risk of developing post-hepatectomy liver failure (PHLF). Unfortunately, at present there are no optimal methods for assessing the risk of PHLF following major liver resections.

The aim of the study was to define the possibility of risk prediction for development of PHLF by using multifactorial prognosis scales.

Materials and methods. Overall, 286 major liver resections were performed between January 2009 and December 2015 in A.V. Vishnevsky National Medical Research Center of Surgery. The median age was 56.6 years (range 16-80). The majority of patients - 128 (44.7%) were operated for metastatic liver lesion (colorectal metastases - 95 (33.2%); primary liver tumors - 88 (30.7%), hepatocellular carcinoma - 39 (13.6%), cholangiocellular carcinoma - 28 (9.8%). 70 (24.6%) patients - for benign tumors and non-tumor liver lesion. Various types of liver resections were performed for these 286 patients - right hepatectomy: $n = 99$ (34.6%), left hepatectomy $n = 59$ (20.6%), extended left hepatectomy $n = 33$ (11.5%), extended right hepatectomy $n = 56$ (19.6%), resection of 3 segments of the liver $n = 39$ (13.6%). On 1, 3, 5, 7 postoperative days were evaluated the next clinical characteristics: the level of ALT, AST, total bilirubin, albumin, creatinine, international normalized ratio (INR), blood lactate, prothrombin ratio (PR) was determined. The time of operation and the volume of blood loss were estimated intraoperatively. To assess the severity of PHLF, the ISGLS classification was used. Statistical analysis was performed using Student's t-test, χ^2 -test, logistic regression equation.

Results. The overall PHLF rate was 20.3% (58/286 patients). Grade A liver failure occurred in 35 patients (12.2%), grade B in 17 (5.9%), and grade C in 6 patients (2%). Mortality rate was 3.1% (9 patients). The analysis revealed statistically significant indicators: operation blood loss, operation time, lactate concentration during the first 4-6 hours after the operation, total bilirubin level, PR at day 1 after operation. When the threshold value was exceeded, each factor was assigned 1 point, with a normal value - 0 points. Then the points were summed up. At the sum of points 0 the probability of PHLF was 0%, 1 - grade A - 7.7%, grade B and C

- 0%, 2 - grade A - 18.1%, grade B and C - 0%, 3 - grade A - 41.0%, grade B and C 12.8%, 4-5 - 100% probability of PHLF grade B and C. The sensitivity of the scale was 89.6%, specificity 88.1%. In a comparative analysis of patients groups with and without PHLF, were identified the next statistically significant risk factors: body mass index < 20 kg/m², presence of liver cirrhosis, baseline level of PR and level of PR on the 1st day after surgery, baseline levels of total bilirubin and albumin, remnant liver volume, operation blood loss, operation time, blood lactate 2 hours after surgery. Depending on the degree of significance of the risk factors, they were given a score, the maximum value of the factor was 50. The sum of points of all factors in the division by the percentage of the remaining liver parenchyma gave the value of the coefficient. When the coefficient was the range of 2 - 3, the risk of development grade B PHLF was significantly increased; when the coefficient was >3 - PHLF grade C. When calculating before surgery, the probability of developing grade B PHLF was increased at values of 1 - 1.9, for values > 1.9 for grade C. The sensitivity of the system when it was applied before surgery it was 72%, after operation 78.9%.

Conclusion: At present, there is a growing need to create a clear algorithm for selecting patients for surgical treatment and their subsequent management. Based on the proposed and improved forecasting systems, it is possible to approach its creation and determine in advance the tactics of pre-operative selection and treatment of a patient after surgery.

422

INTRALUMINAL TREATMENT OF ESOPHAGEAL STENOSIS IN CHILDREN WITH EPIDERMOLYSIS BULLOSA

**A. Tupylenko¹, M. Lokhmatov^{1,2}, N. Murashkin^{1,2},
E. Diakonova¹, V. Oldakovskii¹, S. Maksimova¹,
E. Petrov¹, I. Surkova¹**

¹*National Medical Research Center of Children's Health
Of the Ministry of Health of the Russian Federation,
Moscow, Russia*

²*I.M. Sechenov First Moscow State Medical University
of the Ministry of Health of the Russian Federation
(Sechenov University), Moscow, Russia*

Relevance. The most common complication in children with epidermolysis bullosa is the formation of esophageal stricture, which leads to the appearance of symptoms of dysphagia and a violation of nutritional status.

Purpose of the study. To assess the effectiveness and safety of balloon dilatation in the treatment of esophageal strictures in children with epidermolysis bullosa.

Patients and methods. Between June 2015 and March 2018, 34 patients with esophageal strictures and symptoms of dysphagia (16 boys and 18 girls aged 2 to 17 years, 92.03

± 40.5 months [mean ± SD]) performed a balloon dilatation (BD) of esophageal strictures under endoscopic and fluoroscopic assisting. The effectiveness of procedure was assessed on the basis of an assessment of the change in the level of dysphagia (Bown scale), stricture index (SI), THINC scale, the number of repeated interventions and the presence of complications.

Results. Strictures of the esophagus, accompanied by symptoms of dysphagia, were revealed: with recessive-dystrophic form 97% [33/34], dominant-dystrophic form 3% [1/34]. Number of narrowing: single strictures in 91.2% [31/34], multiple (2 or more) in 8.8% [3/34] children. The total number of strictures was 48. Localization of strictures: in the upper third 56.2% [27/48], in the middle third 39.6% [19/48], 4.2% [2/48] stricture in the lower third. Characteristics of strictures: the length was 21.35 mm ± 21.93 [mean ± SD], the diameter of the esophagus in the constriction zone was 2.92 ± 1.08 [mean ± SD]. The level of dysphagia after a BD of 0.37 ± 0.49 [mean ± SD] became significantly lower relative to the baseline level of 2.9 ± 0.61 [mean ± SD]. After the BD, the SI also fell below 0.23 ± 0.15 [mean ± SD], relative to the baseline level of 0.74 ± 0.13 [mean ± SD]. The percentage of repeated interventions (relapses) was 29.4% [10/34]. The interval between repeated BD was 12.1 ± 4.1 months [mean ± SD]. Significant complications, such as perforation or bleeding did not occur. Six months after a BD, the degree of malnutrition (on the THINC scale in 25 patients) was below 48.8 ± 17.5 [mean ± SD] - moderate degree, relative to the baseline level 63.8 ± 18.7 [mean ± SD] – severe degree.

The conclusion. Balloon dilatation is an effective and safe method of treatment of esophageal stenosis, which allows to eliminate the symptoms of dysphagia without the occurrence of serious complications, and in the shortest time to return patients the possibility of adequate oral feeding, with a gradual restoration of malnutrition.

423

SURGICAL TREATMENT OF INGUINAL AND FEMORAL HERNIAS

A. Tursunovic, Z. Rifatbegovic, M. Omerovic, M. Kovacevic

Department of surgery, University Clinical Center Tuzla, Bosnia and Herzegovina

Introduction: In the inguinal region may occur inguinal and femoral hernia, depending on whether the protrusion of the contents of the abdominal cavity is realized in the transverse

fascia above the inguinal ligament, or below, the femoral canal. Repair of hernia inguinal canal is one of the most frequently performed operation in general surgery.

Objective: To show the frequency of the hernia inguinal region and the application of different principles of anesthesia in their repair, in a one year period.

Patients and methods: Analysis includes data obtained from surgical protocol and operational history of the disease of patients undergoing elective or emergency inguinal region hernia surgery at Department of Surgery, University Clinical Center Tuzla, from 01. 01. 2017th to 31st 12th 2017. Pearson's χ^2 -test was used for statistical analysis of data.

Results: 572 patients (540 males, 32 females), mean age 48.18 years, 550 (94.96%) patients with inguinal and 22 (5.04%) patients with femoral hernia were operated. Inguinal hernias were more common in males (547 males, 20 females), while femoral hernias were not statistically significant among men (10 males, 12 females). In the case of 547 men (97.94%) were operated inguinal hernia and at 10 (2.06%) femoral hernia. Twenty (67.57%) women were operated because of inguinal hernia, and in 12 cases (32.43%) femoral hernia. A total of 572 hernioplasty were performed, 550 (95.10%) inguinal and 22 (4.90%) femoral. In 530 (96.93%) patients, one-side inguinal hernioplasty was performed (380 right side and 150 left side), and in 20 (3.07%) both side inguinal hernioplasty. Primary inguinal hernias were 510 (94.04%) and recurrences 40 (5.26%). Free (without incarceration) inguinal hernias were 535 (96.48%), and incarcerated were 15 (3.52%). Direct inguinal hernias were 170 (34.42%), indirect 340 (54.47%) and direct-indirect 40 (11.11%). In 15 (78.95%) patients, femoral hernia surgery was performed on the right side and 7 (21.05%) patients on the left side. All femoral hernias were primary. Free femoral hernias were 13 (68.42%), and incarcerated 9 (31.58%). Statistically, significantly more frequent incarcerated femoral hernias were reported. 530 (92.05%) patients were operated under local anesthesia conditions and 42 patients under general anesthesia conditions (7.36%). The most commonly used mesh was polypropylene 6cm x 11cm. The bowel resection was performed at 3 of 15 patients (7.69%) with incarcerated inguinal and at 5 of 9 (50.0%) femoral hernias.

Conclusion: The inguinal region hernias are more frequent in males. In both sexes, inguinal hernias are more frequent than femoral. Inguinal and femoral hernias are more frequent on the right side and the most common are indirect inguinal hernias. The operations were performed in local anesthesia in most of cases. For the plastic of inguinal canal we used synthetic mesh size 6cm x 11cm, and we performed Lichtenstein method. The incarcerated inguinal hernias are rare, while femoral are more frequent and more often bowel resection has to be performed.

424

INDIVIDUALIZED STAGE MINIMALLY INVASIVE SURGICAL TACTICS WITH MECHANICAL JAUNDICE

U. Usmonov

Andijan State Medical Institute, Andijan, Uzbekistan

Relevance. Mechanical jaundice is a serious complication of diseases of the hepatopancreatoduodenal zone and to this day remains one of the topical problems of abdominal surgery.

Purpose of investigation. To improve the results of surgical treatment of patients with mechanical jaundice by developing and applying an individualized terminal minimally invasive surgical tactic.

Material and methods of investigation. The results of examination and surgical treatment of 68 patients with mechanical jaundice, who were on inpatient treatment on the basis of the Department of Surgery and Urology, were analyzed. The main group consisted of 37 (54.4%) patients. Of these, 25 (67.5%) are women and 12 (32.5%) are men. The average age of patients was 49.8 ± 3.4 years. This group used individualized surgical tactics, which consisted of the following: a differentiated approach to the selection of medical and diagnostic measures, operational access and postoperative management, taking into account biliary decompression, the nature of the course of mechanical jaundice and cholangitis. In the control group (31 patients - 45.6%) traditional surgical tactics of treatment of patients were used.

Results of the researching. The analysis of the results of the complex therapy carried out showed that the level of total bilirubin decreased significantly by 70.1% in the patients of the main group already 2-3 days after the operation with respect to the initial data. The level of alkaline phosphatase was normalized in this group on days 4-5 after surgery. The level of transaminases in patients of the main group by this time significantly decreased by 35.9% / 32.6%, respectively, and the level of creatinine decreased by 36.7%. In the main group, the level of leukocytosis normalized on the 2nd day after the operation by 29.6% relative to the baseline data. The dynamics of the index level of endogenous intoxication convincingly shows that the use of endobiliary lavage and mini-access due to a positive effect on endogenous intoxication significantly increased the effectiveness of detoxification therapy. The level of severity of multi-organ failure on the SOFA scale in the study groups of patients at admission was increased to 6.1 ± 0.3 points, which corresponded to the probability of a lethal outcome from 27% to 38%. As a result of the complex therapy, the severity of multiple organ failure in the main group was significantly decreased by 22.3% in the first day after the operation, relative to the baseline data. At 7 days after the operation, this difference was 71.5%, which is 4.4 times less than at admission, and 1.9

times than with traditional treatment. The total number of complications in the control group was 16.1% of patients, and the lethality - 6.4% (2 patients). The use of individualized stage surgical tactics with preliminary decompression using endobiliary lavage significantly increased the effectiveness of treatment and promoted a favorable course of the disease. There were no lethal outcomes in the main group.

Conclusions. The developed individualized stage mini-invasive surgical tactic with the use of the method of endobiliary lavage and minilaparotomy access with mechanical jaundice is pathogenetically grounded, as it leads to an earlier arrest of clinico-laboratory manifestations of cholangitis and endogenous intoxication, accelerates the relief of multiple organ failure, promotes reduction of postoperative complications by 8% , reduction in the length of stay of patients in the hospital by 4.3 days and reduction of lethality 6.4%.

425

PRELIMINARY DECOMPRESSION WITH THE USE OF ENDOBILIARY LAVAGE IN CHOLEDOCHOLITHIASIS COMPLICATED BY JAUNDICE AND CHOLANGITIS

U. Usmonov

Andijan State Medical Institute, Andijan, Uzbekistan

Relevance. Cholangitis is one of the most unfavorable complications of cholelithiasis. Clinical significance of holatitis and mechanical jaundice is determined, first of all, by a high level of mortality, which reaches 28.5% and is caused by the rapid spread of the ascending infection into the intrahepatic ducts, the development of cholangiogenic liver abscesses and biliary sepsis.

Purpose of investigation. Improve the results of surgical treatment of patients with choledocholithiasis complicated by jaundice and cholangitis.

Material and methods of investigation. The results of examination and surgical treatment of 61 patients with choledocholithiasis complicated by jaundice and cholangitis, who were on inpatient treatment on the basis of the Department of Surgery and Urology of ASMI were analyzed. A comprehensive examination of the patients showed that the pathological process was localized not only in the gallbladder, but was often complicated together by choledocholithiasis with catarrhal (25%), fibrinous (23.5%) and purulent cholangitis (27.9%), as well as biliary pancreatitis (13.2%), parapuzyrnym infiltrate and abscess (7.4%), local peritonitis (3.0%). In 32 (52.4%) patients, preliminary decompression of the bile ducts with endobiliary lavage (EBL) was used, and in the second stage of surgical treatment minilaparotomy access was used according to the clinic technique. And in 29 patients (47.6%) traditional surgical treatment tactics were used.

Results of the researching. All 32 patients underwent endoscopic operations with diagnostic interventions at the first stage: endoscopic papillosfinkterotomy, endoscopic retrograde pancreato cholangiography with lithoextraction and nasobiliary drainage in 14 (43.7%) patients; endoscopic papillotomy, endoscopic retrograde pancreatocholangiography with lithoextraction and nasopharyngeal drainage - in 12 (37.5%) patients; endoscopic mechanical lithotripsy with lithoextraction and nasobiliary drainage - in 6 (18.5%) patients. The second stage of treatment tactics was performed by all patients of the main group: minilaparotomy, cholecystectomy in 31 (96.9%) patients, and 1 (3.1%) patient was operated using the open laparotomy method (upper-median laparotomy). Method of endobiliary lavage: All 32 patients of the main group after surgical interventions performed endobiliary lavage with application of 0.02% anti-septic Decasan in the treatment complex. Endobiliary lavage was carried out through the installed external drainage of choledochus or nasobiliary drainage by the drop method by 100 ml 3 times a day. Before using the drug, it was heated to body temperature and 0.5% solution of novocaine was added. The ratio of Novocain and Decasan solution is 1: 3. The course of treatment averaged 5-7 days. Further continuation of the course of treatment, increasing the frequency of lavage was carried out according to indications, was justified by the course of the disease, according to bacteriological studies of bile, the timing of elimination of cholangitis and jaundice. In the main group, the level of leukocytosis normalized already by 2-3 days after the operation by 29.6% relative to the initial data. In this group, the level of leukocyte intoxication index reached its normal values on days 4-5 after surgical interventions, which indicates that with this combination of complex therapy an earlier and pronounced clinical effect is observed. With traditional treatment, this dynamics was not so rapid and pronounced. The dynamics of the index level of endogenous intoxication convincingly shows that the use of endobiliary lavage and mini-access due to the impact on endogenous intoxication significantly increased the effectiveness of detoxification therapy.

Conclusions. Preliminary decompression with the use of endobiliary lavage and minilaparotomic access in the complex of treatment promoted effective correction of biochemical indices, endogenous intoxication indicators, thereby compensating for the general condition of patients and reducing the risk of surgical intervention, and also creates prerequisites for active postoperative recovery processes.

426

METABOLIC SYNDROME AS A RISK FACTOR OF IDIOPATIC DEEP VEIN THROMBOSIS OF THE LOWER LIMBS AND POST-THROMBOTIC SYNDROME

S. Usov, M. Voevoda, D. Rovenskih

Scientific Research Institute of Therapy and Preventive Medicine of The Siberian Branch of Russian Academy of Sciences, Russia

Actuality. The percentage of incident deep vein thrombosis events that are idiopathic thic ranges from 25 to 40 % (Heit JA et al., 2016).

The purpose of the study. To elucidate the role of metabolic syndrome (MS) as a risk factor of idiopathic deep vein thrombosis of the lower limbs (IDVT) and post-thrombotic syndrome (PTS).

Materials and methods: The study included 80 patients with IDVT. The control group was comprised of 580 healthy subjects. We estimated the prevalence of MS and its components according to the criteria of International Diabetes Federation (MS IDF) and Russian Scientific Cardiologists Society (MS RSCS). One year after the episode of IDVT the presence of PTS (according to Villalta score) was estimated. The odds ratio (OR) was calculated to estimate the risk of development of IDVT and relative risk (RR) to estimate the risk of development of PTS.

Results. Totally for MS IDF OR was 2.874; 95% confident interval (CI) 1.788 – 4.621, for MS RSCS OR 1.737; 95% CI 1.088 – 2.774; in women: MS IDF OR 3.023; 95% CI 1.535 – 5.952, MS RSCS OR 2.256; 95% CI 1.156 – 4.438; in men: $p > 0.05$ for MS IDF and MS RSCS. Hypertriglyceridemia was detected in 76.2% of the patients with IDVT compared with 22.2% in the control group ($p < 0.001$). The reduction of the high-density cholesterol level was documented in 43.7% of IDVT patients and in 10.0% of controls ($p < 0.05$). One year after the episode of the IDVT the risk for PTS was significantly higher in patients with MS: for MS IDF: RR – 2.165, 95% CI 1.194 – 3.927; for MS RSCS – RR 1.500, 95% CI 1.002 – 2.247.

Conclusion: MS is the risk factor of IDVT (especially in women) and subsequent PTS. In the first case dyslipidemia is a component of special value.

427

CRYODESTRUCTION OF MALIGNANT LIVER FORMATIONS: MRI MONITORING AT THE STAGES OF TREATMENT, PRELIMINARY RESULTS

V. Vdovenko, Y. Galchina, N. Karelskaya, G. Karmazanovsk, D. Ionkin, A. Chzhao

«A.V. Vishnevsky NMSC of surgery», Moscow, Russia

Relevance: The use of cryodestruction (CD) as an alternative

method for the treatment of focal liver lesions began in the 1970s. MRI is the preferred method for diagnosis postoperative changes in the CD zone.

Aim: To evaluate the completeness of CD and the probability of continued growth in the area of CD in patients with liver tumors at different stages of postoperative monitoring by MRI with DWI.

Materials and methods: During the period of 2012-2017 CD was performed in 58 patients with liver tumors. Dynamic postoperative MRI monitoring was carried out in 14 patients with malignant liver lesions (5 patients with primary liver tumors, 9 - with secondary liver lesions). All patients underwent MRI with ADC maps calculation before surgery and in the postoperative period on 1st day, 3 months, 6 months. Estimated "overlap" of the pathological focus by the area of edema 1 day after CD, the size of the lesion before surgery and in the late period after CD, changes of diffusion coefficient on DWI and ADC maps in the area of interest, the probability of continued growth in the area of CD.

Results: Criterion for the completeness of CD in focal lesions liver is the "overlap" of the lesion by the area of the swelling after CD on T2-weighted images and decrease of restriction in the tumor on ADC maps. In the long term (3, 6 months) the dynamics of tumor size and size of solid component limiting diffusion were evaluated. With the increase in the size of the tumor and the degree of diffusion restriction in solid component we concluded that the tumor continued growth. In the analysis of MRI results on the 1st day after CD of liver tumors: in 40% there was a complete "overlap" of the lesion by the edema area on T2-weighted images, the degree of diffusion restriction on DWI and ADC maps decreased. At a later date (6 months after CD) in these patients, with a positive result according to MRI data in the 1st day in 50% of cases, an increase in the size of the tumor and a solid component limiting diffusion according to DWI and ADC maps was not revealed. Incomplete "overlap" of the tumor with the edema zone in MRI on the 1st day after CD was revealed in 60% of cases, later in these patients an increase in the size of the tumor and a solid component limiting diffusion according to DWI and ADC maps was revealed. According to our preliminary results there was an increase in the size of the focus by 6.5% by the 6th month of the patients' observation, the value of the diffusion coefficient by the ADC increased by 20% by the 3rd month, by the 6th month it returned to its original values.

Conclusions: 1. MRI on the first day after CD in liver tumors allows to assess the completeness of destruction and to assess the probability of continued growth in the area of CD. 2. MRI with DWI / ADC is an informative method of assessing dynamic changes, postoperative monitoring during CD of liver tumors.

428

SCREENING COLONOSCOPY IN THE DIAGNOSIS OF COLON'S ADENOMATOUS NEOPLASIAS

V. Vereshchak¹, I. Karasev¹, S. Karaman¹, O. Malikhova^{1,2}

¹*Federal state budgetary institution "National medical research center of Oncology named N. N. Blokhin" of the Ministry of health of the Russian Federation, Moscow, Russia*

²*Department of Oncology of the Federal state budgetary educational institution of additional professional education of the Russian medical academy of continuous professional education of the Ministry of health of the Russian Federation, Moscow, Russia*

Urgency: Colon's adenomas (epithelial neoplasias) seem to be an attractive target for cancer screening, as they are one of the main substrates for the development of colorectal cancer. Colonoscopy using the newest technologies is a reliable method of screening.

Purpose of research: To carry out a comparative analysis of colonoscopy (CS) protocols, to determine the adenoma detection rate (ADR) and its tendency to growth.

Research methods and patients: Retrospective research was conducted in the "NMRC of Oncology named N. N. Blokhin" of the protocols of the CS, patients observed in our center over the last three years (period from may 2015 to may 2018).

Results: All studies were conducted by communicant of the department at the endoscopic racks Olympus EVIS EXERA II, III, devices CF Q-150I, CF Q-160ZL, Q-190L. For the period from 05.2015 to 05.2016 made 1376 CS, from 06.2016 to 05.2017-1402 CS, and from 06.2017 to 05.2018 - 1397. The frequency of detection of polyps was 424 cases (30.8%) in the first period, 501 cases (35.7%) was in the second, and 637 cases (45.5%) was in the third. The ADR is equal to the first period - 457 (33.2%), the second - 523 (37.3%), the third - 671 (48%). With the advent of the latest endoscopic equipment, detection of serrated adenomas increased from 10.5% to 18% of the total amount verified by adenomas.

Summary: This received obtained indicate an increase in the number of detected adenomatous neoplasias, which was a consequence of the expansion of the use of new imaging technologies and modern equipment. The results of the work and morphological characteristics indicate the need for continued and extended directional analysis of groups of patients.

429

BARRETT'S ESOPHAGUS IN MALES – POLICE OFFICERS OF YAKUTIA

E. Verchoturova, A. Golderova

Russia

Background. Gastroesophageal reflux disease (GERD) is the risk factor for the development of esophageal adenocarcinoma and its precursor, Barrett's esophagus (BE) (Michelon D., Faria A., 2017; Spechler SJ., Sharma P. et al, 2011). Yakutia remains an endemic region – there is a high incidence of esophageal cancer – more than 150 people per 100 thousand population (Ivanov P.M., Tichonov D.G., 2000; Kaibysheva V.O., 2012). A high prevalence of BE in males – police officers (39,7%) in Yakutia proves the actuality of our research and the necessity for in-depth study of the risk factors of this pathology.

Objective. The objective of the study is to estimate the risk factors in the formation of Barrett's esophagus in police-officers patients in Yakutia.

Materials and methods. We examined 78 males – police officers who were on examination at the Medical department of the Interior Ministry of the Republic of Sakha, in 2017-2018. The diagnosis was based on standard clinical, endoscopic and morphological methods of investigations. Barrett's esophagus was verified on detection of intestinal metaplasia of incomplete type on biopsy.

Results and discussion. The subjects were divided into 4 groups. Group «1» included 7 patients with unchanged mucous membrane (8,97%); group «2» - 19 patients with reactive changes of the squamous epithelium (24,35%); group «3» - 21 patients with squamous and intestinal metaplasia (26,92%); group «4» - 31 patients with dysplasia and Barrett's esophagus (39,7%). In our study, the ratio of the surveyed persons of the Mongoloid and Caucasoid race was 34:44, respectively, while the same ratio among patients with BE was 13:18, i.e. the white race was predominant, consistent with the literary data. Analysis of clinical and anamnestic data showed a statistically significant difference in the distribution of the surveyed persons according to the diagnosis, depending on the place of birth ($\chi^2 = 8.79$, $p = 0.032$). So in groups 3 and 4, the number of natives was significantly higher (4.25 and 1.85 times, respectively) than those who were born in Yakutia. Analysis of the distribution of patients depending on the work status revealed that 100% of the heads of departments have the lesions of the distal part of the esophagus, 48,4% were assigned to group «4». Hiatal hernia was established in 70,96% of all examined individuals. A significant relationship was established between hiatal hernia and erosive reflux ($\chi^2=8,79$; $p=0,032$). It should be noted that group «4» is consisted of patients with erosive reflux 80,6%.

Conclusion. Thus, the obtained data are indicated a high incidence of Barrett's esophagus among police officers with GERD (39,7%). In our study the significant risk factors for the

formation of Barrett's esophagus were belonging to the white race (Caucasians), leadership post, the natives of Yakutia, as well as the hiatal hernia and erosive gastroesophageal reflux.

430

DIFFICULT LAPAROSCOPIC CHOLECYSTECTOMY – RISK FACTORS AND ITS MANAGEMENT / STRATEGIES – OUR EXPERIENCE

Jain Vinamra, Jain Anupma

Amrita Hospital, Shahdol, India

Relevance: Laparoscopic Cholecystectomy is gold standard for gall bladder stone disease. Difficult cholecystectomy is associated with serious complications and a high conversion rate. Difficult laparoscopic cholecystectomy can be anticipated on certain preoperative and intraoperative factors like acute cholecystitis, male patient, biliary pancreatitis, previous abdominal surgeries, gallbladder perforation. We studied 100 cases of difficult Laparoscopic Cholecystectomy over a period of 7 years & evaluated predictors for difficult laparoscopic surgery, Intraoperative surgical techniques and Post-operative complications.

Objective: The aim of our paper is to evaluate the risk factors and strategies to manage case of difficult laparoscopic cholecystectomy.

Material & Methods: We operated 100 cases of difficult cholecystectomy in a period of 7 years from 2011 to 2017. Out of 100 cases study, 60% were of acute cholecystitis, 20% mucocele, 10% pyocele and rest 10% of difficult anatomy, biliary pancreatitis, morbid obesity and previous upper abdominal surgeries. Case selection criteria included – Right hypochondrium lump, severe tenderness, repeated attack of cholecystitis, USG findings included; Grossly distended gall bladder, Mucocele or Pyocele., Wall thickness > 5mm., Perforated Gall Bladder., Contracted small Gall Bladder.

Results: In a period of 7 years total 100 patients were operated which met the criteria of difficult laparoscopic cholecystectomy. Intraoperative difficulties encountered were port placement and pneumoperitoneum creation because of previous surgeries and adhesions. Bleeding due to gross adhesions from gallbladder wall due to acute cholecystitis, adhered duodenum and frozen calots. Complications observed were bleeding managed by cautery, gauze packing and abgel placement. In 2 patients duodenal injury recognized intraoperatively and repaired laparoscopically. CBD injury was 0.1% managed with ERCP. Conversion to open surgery 0%.

Conclusion: From our experience we conclude that surgery should be performed as early as possible because delay increases edema, incidence of adherence & bleeding thereby increases morbidity. Clear ligation, blunt dissection by cannula and pledget is safe and minimizes chances of

complications and ensures early recovery and discharge, a major goal of laparoscopic surgery.

431

PLACE OF ULTRASOUND CAVITATION AND VAC THERAPY IN THE TREATMENT OF INFINIATED RAS OF VARIOUS ETIOLOGY

A. Vorobev¹, I. Mironova¹, E. Brehov², V. Kalinnikov²

¹*FGBU "Clinical hospital No 1" Department of presidential Affairs, Moscow, Russia*

²*FGBU DPO "CGMA" the Department of presidential Affairs, the Department of surgery with the course of endoscopy, Moscow, Russia*

Relevance of the problem: patients with the presence of purulent and infected wounds of different etiology, are associated with the peculiarities of the wound process: infectious aggression, interstitial hypoxia, abundant and aggressive wound discharge, variability and polyresistance of the microflora, the risk of continued necrosis of soft tissues, low reparative activity, rigidity of the wound edges. All together leads to an increase in treatment time and additional material costs. The introduction of additional physical methods of treatment and treatment of wounds (ultrasonic cavitation and VAC therapy) in daily practice, against the background of timely adequate surgical rehabilitation of infected wounds, against the background of complex rational etiologic and pathogenetic therapy, allowed to improve the results and reduce the duration of treatment.

Objective: to optimize the conditions of the wound process in patients with purulent and infected wounds, through the integrated use of ultrasonic cavitation and VAC therapy.

Materials and methods: sample analysis of the results of treatment of 80 patients with purulent and infected soft tissue wounds of different etiology who are on hospital treatment in the Department of purulent surgery of the "Clinical hospital № 1", in the period from november 2013 to june 2018. The observation group included patients with extensive post-traumatic infected wound defects of different localization (17), patients with open management of post-operative stump, who underwent high amputation at the level of the hip, due to gangrene (13). Patients (35) with acute purulent-inflammatory diseases of soft tissues (abscesses, phlegmons of the body, limbs). Complex treatment of patients (15) with purulent-destructive changes in the distal lower extremities in patients with complicated course of neuroischemic form of diabetic foot syndrome. Local treatment of infected and purulent wounds of soft tissues, with a reorganization of the R-ramie antiseptics, ointments on polietilenglikoli basis, alginate dressings, superabsorbers interactive dressings for treatment of wounds in a wet environment, was supplemented with a step of physical treatment of wounds by the method of low

frequency ultrasound cavitation, with subsequent vacuum treatment conducted at 0-5th day after a primary surgical treatment of a purulent focus and/or after stage neurectomy areas continued secondary necrosis of soft tissues. A condition for the application of vacuum therapy has been the provision of stable hemostasis, as well as conduct additional decontamination by the preceding treatment of wounds by the method of ultrasonic cavitation. The vacuum therapy system was established for a period of 48 to 96 hours. Pressure mode from -90 to -125 mm water column, in constant and / or intermittent mode. Subsequently was performed the reinstallation of the system vacuum therapy with revision of surgical wounds and pre-stage treatment of the wound by the method of ultrasonic cavitation.

Results of treatment: reducing the frequency of secondary wound infection, reducing the time of cleaning the wound surface and the formation of granulation tissue, a progressive reduction in the volume of the wound cavity with an adaptive effect of the position of the wound edges. In earlier periods, signs of regression of the perifocal and General inflammatory reaction (decrease in the level of leukocytosis, normalization of body temperature), due to a decrease in local resorption of the wound exudate.

Conclusions: the stage-by-stage application of ultrasonic cavitation and vacuum therapy in the complex treatment of infected wounds of different etiology allowed to improve clinical results and to reduce the time of inpatient treatment of patients with purulent-surgical profile with "open" soft tissue wounds of different etiology.

432

DIFFICULTY SCORES OF LIVING DONOR LIVER TRANSPLANTATION

S. Voskanyan, A. Artemiev, K. Gubarev, I. Kolyshev, D. Zabezhinsky, E. Naydenov, V. Rudakov, M. Shabalin, V. Shcherbin, A. Voevodin, D. Svetlakova, A. Maltseva
State Research Center Burnazyan FMBC of the FMBA of Russia, Moscow, Russia

Relevance. Liver transplantation is the most effective and, often, the only radical method for treating patients with terminal stage of chronic diffuse liver diseases, fulminant liver failure, malignant and benign liver tumors and inoperable parasitic liver disease. Features of the donor vascular anatomy of the liver or portal and/or hepatic caval gate injury in Liver Alveococcosis contribute to complex reconstructions of portal venous inflow or outflow from the hepatic vein from liver graft.

Aim. The immediate and long-term results of the difficult liver transplantations at its terminal lesions because of the features of donors liver vascular anatomy or defeat portal and/or hepatic caval gates by Liver Alveococcosis have been studied.

Material and methods. 300 liver transplantations (LT) were performed in the Center for Surgery and Transplantology of the State Research Center Burnazyan FMBC of the FMBA of Russia in the period from June 2010 to June 2018. 231 living donor liver transplantation (LDLT) in the form «adult-to-adult» have been performed, 69 cadaveric liver transplantation have been performed (including adult split liver transplantation and retransplantations). 158 (68.3%) difficult LDLT have been performed because of the features of donors liver vascular anatomy or defeat portal and/or hepatic caval gates by Liver Alveococcosis. Complex reconstructions of portal venous inflow or outflow from the hepatic vein from liver graft have been required. Resections and reconstructions of the IVC and/or the right atrium by PTFE-conduits due to the parasitic lesions of the IVC have been performed. Isolated venous outflow from the 8 segment of the liver to middle hepatic vein, isolated venous outflow from the 6 segment of the liver and its diameters more than 5 mm were an indication for vascular reconstruction. Reconstruction and formation common embouchment of the portal vein via using autovenous Y-shaped portal conduit at «back table» was performed at trifurcation of the portal vein. Anastomosis between the portal vein of the recipient and autovenous portal conduit was formed for a short stump of the right portal vein of the transplant. Reconstruction of the portal vein at it complete fibrous obliteration was performed by autovenous prostheses. Saving the middle hepatic vein in the living donor's liver was a prerequisite. Linear prosthesis of the inferior vena cava and/or resections of the right atrium with atrium-caval prosthesis by the PTFE-conduits have been performed at their parasitic lesions, in this cases hepaticocaval anastomoses have been formed by type «vein-to-graft».

Results. Mortality among recipients was 2.5%. Morbidity was 38.0%. Vascular complications after LDLT were 1.9%. Frequency of the biliary complications (grade A, B (ISGLS, 2011) was 15.8%. Mortality among living donors was not. The morbidity among living donors was 10.7% and was mainly represented of the bile leakage (grade A, B (ISGLS)). Postoperative hospital stay for recipients was 27 (23-32) days.

Conclusion. Presented technologies allow achieving a good immediate and long term results of the liver transplantations, even in complex cases.

of Russia, Moscow, Russia

Relevance. Liver transplantation is the most effective and, often, the only radical method for treating patients with terminal stage of chronic diffuse liver diseases, fulminant liver failure, malignant and benign liver tumors and inoperable parasitic liver disease.

Aim. Study the immediate and long-term results of the liver transplantation (LT) at its terminal lesions.

Material and methods. 300 LT were performed in the Center for Surgery and Transplantology of the State Research Center Burnazyan FMBC of the FMBA of Russia in the period from June 2010 to June 2018. 231 living donor liver transplantation (LDLT) in the form «adult-to-adult» have been performed (group 1), 69 cadaveric liver transplantation (CLT) (group 2) have been performed (including adult split liver transplantation and retransplantations). Liver cirrhosis in the outcome of autoimmune hepatitis, primary sclerosing cholangitis, viral hepatitis, Wilson's disease, Budd-Chiari syndrome, primary and secondary biliary cirrhosis, alveolar liver disease, alimentary cirrhosis and cryptogenic cirrhosis have been indications for surgical treatment. 155 (67.1%) difficult LT at LDLT because of the features of donors liver vascular anatomy or defeat portal gates and/or hepatic confluence and/or inferior vena cava Echinococcus Alveolaris have been performed. Complex reconstructions of the portal venous inflow or outflow from the cava vein from liver graft have been required. Saving the middle hepatic vein in the living donor's liver was a prerequisite. Laparoscopic removal of the right lobe of the liver from a living related donor was performed in 1 case.

Results. Mortality among recipients was 3.4% (12 patients) at all LT. Mortality after LDLT was 3.0% (7 patients). Mortality after CLT was 7.2% (5 patients), 3 of these patients (60.0%) died after urgent liver retransplantations. Morbidity was 40.0% for all LT. Vascular complications among all recipients were 1.7%, in the 1 group – 1.7%, in the 2 group – 1.4%. Primary graft dysfunction was observed in 2 patients (0.7%) – 0.4% (1 case) after LDLT, 1.4% (1 case) after CLT. Frequency of the biliary complications (grade A, B (ISGLS, 2011) was 15.0% (30 patients) among all recipients, in the 1 group – 14.5% (24 patients), in the 2 – 17.6% (6 patients). The long-term survival in recipients was 1 year – 98.7%, 2 years – 97.3%, 3 years – 96.3%, 4 years – 91.7%, 5 years – 82.7%. Mortality among living donors was not. The morbidity among living donors was 11.3% and was mainly represented of bile leakage (grade A, B (ISGLS)). Postoperative hospital stay for recipients was 25.5 (21-29.5) days. Postoperative hospital stay for living donors was 12 (10-17) days.

Conclusion. Liver transplantation for patients with terminal stage of chronic diffuse liver diseases, fulminant liver failure, malignant and benign liver tumors and inoperable parasitic liver disease is an important option for treating patients with this pathology, which allows for good immediate and long-term treatment outcomes.

433

EXPERIENCE OF 300 LIVER TRANSPLANTATION IN STATE RESEARCH CENTER BURNAZYAN FMBC OF THE FMBA OF RUSSIA

S. Voskanyan, A. Artemiev, K. Gubarev, I. Kolyshev, D. Zabezinsky, E. Naydenov, V. Rudakov, M. Shabalin, V. Shcherbin, A. Voevodin, D. Svetlakova, A. Maltseva
State Research Center Burnazyan FMBC of the FMBA

434

EXPERIENCE OF HEPATECTOMIES WITH VASCULAR RESECTIONS

S. Voskanyan, A. Artemiev, I. Kolyshev, D. Zabezhinsky, E. Naydenov, V. Rudakov, M. Shabalin, V. Shcherbin
State Research Center Burnazyan FMBC of the FMBA of Russia, Moscow, Russia

Relevance. Hepatectomies is the main method of surgical treatment of focal liver formations. However, the variability and complexity of intrahepatic architectonics of vessels, the involvement of major vessels in the pathological process limit the possibilities of radical surgical treatment of focal liver formations.

Aim. To show the results of surgical treatment of liver focal neoplasms with invasion of the main vessels.

Material and methods. 359 patients with liver focal neoplasms with invasion of the main were operated in the Center for Surgery and Transplantology of the State Research Center Burnazyan FMBC of the FMBA of Russia between January 2009 and May 2018. Hepatocellular carcinoma developed on the background of liver cirrhosis (78 patients), hepatocellular carcinoma without liver cirrhosis (36 patients), Klatskin tumors (44 patients), cholangiocellular carcinoma (26 patients), colorectal liver metastases (63 patients), inferior vena cava sarcoma (2 patients), liver alveococcosis (110 patients) have been indications for surgical treatment. 106 liver transplantations (27 cadaveric liver transplantations, 75 living donor liver transplantations, 2 salvage-transplantations, 1 split liver transplantation for 2 adult recipients) have been performed at 78 patients with hepatocellular carcinoma developed on the background of liver cirrhosis, at 1 patient with hepatocellular carcinoma without liver cirrhosis, at 27 patients with liver alveococcosis. 56 extended liver resections with total vascular isolation of the liver (liver autotransplantations) (8 – in situ in vivo; 30 – normothermic autotransplantations ante situm (ex situ in vivo), 18 – hypothermic autotransplantations ex vivo (ex situ ex vivo)) have been performed at 12 patients with hepatocellular carcinoma without liver cirrhosis, at 5 patients with cholangiocellular carcinoma, at 14 patients with colorectal liver metastases, at 1 patient with inferior vena cava sarcoma, at 24 patients with liver alveococcosis. 197 extended liver resections with resection of the main vessels (24 – Inferior vena cava, 16 – hepatic veins, 89 – portal vein, 26 – hepatic artery, 42 – multivascular resections) have been performed at 23 patients with hepatocellular carcinoma without liver cirrhosis, at 44 patients with Klatskin tumors, at 21 patients with cholangiocellular carcinoma, at 49 patients with colorectal liver metastases, at 1 patient with inferior vena cava sarcoma, at 59 patients with liver alveococcosis. Plastics of the main vessels, including the inferior vena cava, when impossible performed their autoplasty and/or resection of the right atrium with atrium-caval prosthesis by the PTFE-conduits have been performed. R0-resections have

been performed in all cases.

Results. Resectability was 100%. The overall morbidity was 25.1%. The morbidity after liver transplantations was 28.8% (16.0% after CLT, 32% after LDLT). The morbidity after liver autotransplantations was 37.5%. The morbidity after liver hepatectomies with resections and plasty of the main vessels was 20.3%. Frequency of the biliary complications (grade A, B (ISGLS, 2011)) was 21.4%. Frequency of the post-operative liver failure (Grade A, B (ISGLS, 2011)) was 13.8%. The overall mortality was 4.4%. The mortality after liver transplantations was 5.7% (8.0% after LDLT). The mortality after liver autotransplantations was 10.7%. The mortality after liver hepatectomies with resections and plasty of the main vessels was 2.0 %.

Conclusion. The presented new technologies in surgical hepatology with resection and plasty of the main vessels are the only radical way to treat of liver focal neoplasms, can significantly increase the operability and resectability of these patients, and provide good immediate and long-term results of surgical treatment.

435

LIVER TRANSPLANTATION FOR HEPATOCELLULAR CANCER

S. Voskanyan, A. Artemiev, K. Gubarev, I. Kolyshev, D. Zabezhinsky, E. Naydenov, V. Rudakov, M. Shabalin, V. Shcherbin, D. Svetlakova, A. Maltseva
State Research Center Burnazyan FMBC of the FMBA of Russia, Moscow, Russia

Relevance. Liver transplantation is performed for hepatocellular carcinoma developed on the background of severe cirrhosis and the impossibility of performing a resection because of low functional liver reserves.

Aim. The immediate and long-term results of liver transplantation for hepatocellular carcinoma have been studied.

Material and methods. 78 liver transplantations for hepatocellular carcinoma (HCC) were performed by the State Research Center of the FMRC of the FMBA of Russia between June 2010 and June 2018. 76 patients with HCC developed on the background of liver cirrhosis have been operated (25 cadaveric liver transplantations (CLT), 49 liver donor liver transplantations (LDLT), 1 split-transplantation for 2 recipients have been performed) and 2 Salvage-transplantations have been performed patients with recurrent HCC (1 HCC without liver cirrhosis). The majority of patients (76 patients (97.5%)) came under the Milan criteria. Two patients (2.5%) went beyond the Milan criteria. "Dawn-staging" therapy, "bridging" therapy, which included stage transarterial chemoembolization, laparoscopic resections (2 patients), stereotaxic radiosurgery (Cyber-Knife) (2 patients) were performed in 13 patients.

Results. Mortality among recipients was 1.3% (1 patient) at

all transplantations. Mortality after LDLT was 2.0% (1 patient). Morbidity was 27.8% at all transplantations. Morbidity after LDLT was 30.0% and was mainly represented of the bile leakage (grade A, B (ISGLS)) – abdominal cavity bilomas, external biliary fistula, stenosis of biliary anastomosis, bile leakage. Morbidity after CLT was 35.0% - intra-abdominal bleeding, stenosis of biliary anastomosis. Morbidity for living donors was 12.0% (6 patients) - biliary complications (grade A, B (ISGLS, 2011)). Mortality among living donors was not. Postoperative hospital stay for recipients after LDLT was 25.5 (22-28) days. Postoperative hospital stay for recipients after CLT was 18 (15-25) days. Postoperative hospital stay for living donors was 13.5 (10.5-19) days. Long-term survival is 100%. Disease-free survival is 97.4%.

Conclusion. Liver transplantation for hepatocellular carcinoma is an important option for treating patients with this pathology, especially against the background of liver cirrhosis, which allows for good immediate and long-term treatment outcomes.

436

NEW TECHNOLOGIES OF RADICAL SURGICAL TREATMENT OF THE LIVER ALVEOCOCCOSIS

S. Voskanyan, A. Artemiev, E. Naydenov, D. Zabezhinsky, V. Rudakov, M. Shabalin, V. Shcherbin
State Research Center Burnazyan FMBC of the FMBA of Russia, Moscow, Russia

Relevance. Only surgical intervention is the only radical method for the treatment of liver alveococcosis at the present time, however, liver alveococcosis is more often diagnosed at later stages, when the possibility of radical liver resection is excluded.

Aim. Development of new technologies, assessment of technical possibilities of surgical treatment of the liver alveococcosis, including the invasion of the main vessels and the results of their application.

Material and methods. 137 patients with liver alveococcosis were operated from December 2011 to June 2018. More than 70% of patients had a history of non-radical surgical treatment. 53 patients (38.7%) had mechanical jaundice on admission to hospital. 88 patients (64.2%) had a parasitic invasion of neighboring structures and organs. Standard liver resections (anatomical resections, right or left hepatectomies) have been performed in 22 patients. 7 Associated Liver Partition and Portal vein ligation for Staged hepatectomy have been performed (3 resections and plastics of the portal vein, 1 resection and plastic of the portal vein and the left hepatic vein). 25 living donor liver transplantations have been performed, 2 liver transplantation from the cadaveric donor have been performed. 13 liver transplantations were performed with resection and plasty of the inferior vena

cava, 9 liver transplantations were performed with resection and plasty of the inferior vena cava and right atrium. 25 extended liver resections with total vascular isolation of the liver (liver autotransplantations) have been performed (21 – normothermic liver resection – ante situ (ex situ in vivo) autotransplantation, 2 – hypothermic liver resection – ex vivo (ex situ ex vivo) autotransplantation). 57 extended liver resections with resection and plasty of the main vessels (26 – Portal Vein, 8 – Inferior Vena Cava, 3 – Hepatic Veins, 5 – Hepatic Artery, 15 – Multivisceral Resections; 1 – celiac trunk) have been performed. Linear prosthesis of the inferior vena cava and/or resections of the right atrium with atrium-caval prosthesis by the PTFE-conduits have been performed. R0-resections have been performed in all cases. All patients were treated Albendazole for 6-12 months after surgery.

Results. Resectability was 100%. The overall morbidity was 33.6%. The morbidity after standard liver resections was 20.0%. The morbidity after liver transplantations was 36.0%. The morbidity after liver autotransplantations was 36.0%. The morbidity after liver hepatectomies with resections and plasty of the main vessels was 30.4%. The morbidity after ALPPS was 42.1%. Frequency of the biliary complications (grade A, B (ISGLS, 2011)) was 23,4%. Frequency of the postoperative liver failure (Grade A,B (ISGLS, 2011)) was 16,1%. The overall mortality was 3.6%. The postoperative hospital stay was 25 (21-41) days after liver transplantation, and 17 (13.5-44) days after liver autotransplantation. The mortality is 0% in the long term period after surgery. The maximum follow-up is 72 months. Survival median is 29 months. Disease-free survival is 97.6%. Disease-free survival median is 27 months.

Conclusion. The concept of inoperability of liver alveococcosis is now practically leveled due to the developed and introduced new technologies of surgical treatment of liver alveococcosis. The use of new technologies in liver surgery, with resection of the main vessels, including resection of the inferior vena cava and right atrium may be the only radical treatment for liver alveococcosis and provide satisfactory immediate and long-term results of the surgical treatment of these patients.

437

SURGICAL OUTCOMES OF DIFFERENT PANCREATIC STUMP CLOSURE TECHNIQUES DURING DISTAL PANCREATECTOMY

S. Voskanyan, E. Naydenov, I. Uteshev, A. Artemiev
State Research Center Burnazyan FMBC of the FMBA of Russia, Moscow, Russia

Relevance. The frequency of specific postoperative complications after distal pancreatectomies remains quite high and reaches 60% despite a decrease in postoperative mortality.

Aim. Effect of different pancreatic stump closure techniques to morbidity, severity of postoperative complications after distal pancreatectomy have been studied.

Material and methods. 126 patients were operated between June 2010 and December 2017. Distal pancreatectomies have been performed (isolated or in combination with operative interventions on adjacent organs of the abdominal cavity and retroperitoneal space). Patients have been divided into 4 groups depending on the pancreatic stump closure techniques. 1 (control) group – isolated suturing of the main pancreatic duct of the pancreatic stump with its omentization by gastrocolic omentum or local sealing its by hemostatic sponge (control group). 2 group – using a biological glue 2-octylcyanoacrylate. 3 group – using the Endoscopic Linear Cutter Echelon. 4 group – external transduodenal transnasal drainage of the enlarged main pancreatic duct. Morbidity, frequency and severity of the postoperative pancreatic fistula have been studied.

Results. The morbidity in the control group of patients was 45.8%. The morbidity in the 2 group of patients was 22.2%. The morbidity in the 3 group of patients was 12.9%. The morbidity in the 4 group of patients was 20.0%. Frequency of specific complications was increased (35.4%). A statistically significant decrease of the frequency of postoperative complications (Clavien-Dindo (2004)) in patients of 2, 3 and 4 groups were revealed in comparison with the control group of patients. The frequency of acute postoperative pancreatitis in the control group of patients was 45.8%. The frequency of acute postoperative pancreatitis in the 2 group of patients was 44.4%. The frequency of acute postoperative pancreatitis in the 3 group of patients was 9.7%. The frequency of acute postoperative pancreatitis in the 4 group of patients was 15.0%. The frequency of postoperative specific complications in the control group of patients was 35.4%, in 2 group – 11.1%, in 3 group – 6.4%, in 4 group – 5.0%. The frequency of postoperative pancreatic fistula in the control group of patients was – 29.2%, in 2 group – 7.4%, in 3 group – 6.4%, in 4 group – 5.0%. Postoperative hospital-stay in patients of the control group was 17 (13-22) days, in 2 group – 12 (10-15) days, in 3 group – 10 (8-13) days, in 4 group – 13 (10-16) days. Mortality was not. A statistically significant decrease of the morbidity, frequency and severity of postoperative complications, the frequency and severity of postoperative pancreatic fistula and decrease of the postoperative hospital-stay after the application of the proposed different pancreatic stump closure techniques were revealed in comparison with the control group of patients.

Conclusion. Distal pancreatectomy with "standard" pancreatic stump closure techniques accompanied by high frequency and severity of postoperative complications, as well as postoperative pancreatic fistulas. The use of the proposed pancreatic stump closure techniques after distal pancreatectomy contributed to decrease of the frequency and severity of postoperative complications, a decrease of the frequency and severity of postoperative pancreatic fistulas, and a decrease of the postoperative hospital-stay.

438

VASCULAR RESECTIONS IN PANCREATIC CANCER

S. Voskanyan, A. Artemiev, I. Kolyshev, D. Zabezhinsky, E. Naydenov, M. Shabalin

State Research Center Burnazyan FMBC of the FMBA of Russia, Moscow, Russia

Relevance. The incidence of pancreatic cancer with invasion of the main vessels does not tend to decrease, and the results of its treatment cannot be called satisfactory - the defeat of the main vessels due to local spread of the tumor is characterized by very low resectability.

Aim. Immediate and long-term results of combined treatment of locally advanced pancreatic cancer with tumor invasion of the main vessels of the abdominal cavity have been studied.

Material and methods. 359 patients with locally advanced pancreatic cancer with tumor invasion of the main vessels were operated in the Center for Surgery and Transplantology of the State Research Center Burnazyan FMBC of the FMBA of Russia between 2011 and 2018. Pancreaticoduodenectomies (PDE) or distal pancreatectomies (DP) with resection of the main vessels «en block» have been performed. Laparoscopic DP CAR has been performed in 1 case. The superior mesenteric vein, the portal vein, the splenic vein, the inferior vena cava, the left renal vein, the superior mesenteric artery, the common hepatic artery and own hepatic artery, the splenic artery, the celiac trunk were the main vessels affected by the tumor process and subjected to resection. Direct and the shortest autoplasty resected veins, reconstruction of the main trunks of the superior mesenteric vein (if there are several trunks) and restoring the blood flow for the splenic vein (if necessary resection of the splenic vein or portal vein confluence) were principled in all cases reconstruction. PTFE-conduits were used to reconstruction for the main veins after their resection and the impossibility of performing the terminal reconstruction of the vessels. The reconstruction of the arteries was performed by extraanatomical implantation in the aorta, the formation of end-to-end anastomoses, prosthetics with their autovenous or PTFE-conduit. All patients after the operation performed a constant oral intake of antiaggregants.

Results. The duration of PDE with resection of the main vessels was 490 (390-520) minutes. The duration of DP with resection of the main vessels was 170 (125-200) minutes. The intraoperative blood loss was 750 (450-1000) ml. Early thrombosis of conduits and reconstructed veins were not. Morbidity after PDE was 25.4%. Morbidity after DP was 18.4%. Mortality after PDE was 4.8%. Mortality after DP was not. Satisfactory PTFE-prosthesis patency and reconstructed veins patency was observed in the postoperative period. PTFE-conduits patency and reconstructed vein patency was 100% in all long-terms investigated periods postoperatively.

Conclusion. Using of the developed complex of surgical

technologies allows to achieve satisfactory immediate and long-term results of treatment of patients with locally advanced pancreatic cancer with extensive tumor invasion of the main vessels. PTFE-conduits are a universal plastic material in the reconstruction of the main veins of the mesenteric-portal system with the impossibility of their autoplasty.

439

IS THE PLUG AND PATCH HERNIA REPAIR A REAL ALTERNATIVE TO THE LICHTENSTEIN HERNIOPLASTY?

S. Voskanyan, M. Lashchik, M. Zabelin, E. Naydenov
State Research Center Burnazyan FMBC of the FMBA of Russia, Moscow, Russia

Relevance. Inguinal hernia is the most common of all hernias of the anterior abdominal wall, occurs in 70% of cases. The newest technologies, modern plastic and suture materials in the treatment of abdominal hernias allow to achieve good results of treatment. Development and introduction into surgical practice of more effective methods of treatment of inguinal hernia determine the urgency of this problem and its great social significance.

Aim. Compare the results of surgical treatment of inguinal hernias by methods of plug and patch hernia repair and Lichtenstein hernioplasty.

Material and methods. In the Center of Surgery and Transplantology of SRC-FMBC from 2007 to 2018, 532 patients were operated on the inguinal hernia. As for subjects of the observations, 514 (96.6%) were men, 18 (3.4%) were women. 320 patients (60.1%) were over 60 years old, with a significant concomitant pathology (IHD, hypertension, COPD, etc.) diagnosed in 241 (45.3%) patients. In 256 patients (group A), 267 surgical interventions were performed by the "plug and patch" method in the modification of Rutkov-Robbins (1993, 1999). At the same time, 245 patients (95.7%) were operated on the unilateral form of the hernia, and 11 (4.3%) were bilateral. During 260 interventions, two-component polypropylene systems AUTO SUTURE SURGIPRO HERNIA-MATE PLUG were used ("large" or "medium" variants were chosen intraoperatively according to the size of the hernial defect). The fixation of both components of the prosthesis, in analogy with the Lichtenstein one, was carried out with monofilament polypropylene sutures AUTO SUTURE SURGIPRO with a diameter from 0 to 2 \ 0 continuous and nodal sutures in all cases. In 7 observations polypropylene systems COVIDIEN PARIETEX PLUG and PATCH SYSTEM with a self-fixating mesh of the shuttlecock were implanted, which allows to slightly reduce the duration of the intervention.

Results. There were no intraoperative and general somatic complications. In the postoperative period, 3 (1.2%) patients were diagnosed with ischemic orchitis, which resulted in

testicular atrophy in 1 observation. In 1 observation (patient B. 63 years), in 16 days after surgery, formation of the fistula tract was observed in the region of the postoperative scar with a small amount of serous drainage, according to MRI data, outgoing from the projection of the internal opening of the inguinal canal - reoperated - after identification of the stroke, the shuttlecock with signs of insignificant adhesion to surrounding tissues was removed. The recurrence of the hernia was not noted in the course of further observation. In 276 patients (group B), standard Lichtenstein plastic surgery was performed on the back wall of the inguinal canal (AUTO SUTURE SPMM35-66, Lintex ESFIL endoprotheses) were used, 42 patients (15.2%) were operated on bilateral inguinal hernia - total 297 operative interventions. Also, there were no intraoperative and general somatic complications in this group. In 3 (1%) patients in the early postoperative period, diffuse bleeding from the veins of the pampiniform plexus of the spermatic cord with the formation of a hematoma of the postoperative wound was diagnosed - revision, evacuation of the hematoma was performed. In 6 (2%) patients, postoperative ischemic orchitis was diagnosed, completely stopped due to conservative therapy. Relapses were not observed during a selective outpatient examination and ultrasound examination of patients of both groups 6-12 months after the intervention, 4 years after the intervention, a recurrence of the disease in group A in 1 patient previously operated for a recurrent hernia was noted.

Conclusion. Thus, the use of various types of polypropylene mesh endoprotheses during the plasty of the posterior wall of the inguinal canal with various forms of inguinal hernia presupposes the achievement of the same type of recurrence-free results, and is not associated with a high risk of postoperative complications. The choice of the type of endoprosthesis may be determined by economic feasibility.

440

POSSIBILITIES OF MINIMALLY INVASIVE TREATMENT FOR ACUTE CALCULOUS CHOLECYSTITIS

S. Voskanyan, M. Lashchik, M. Zabelin, E. Naydenov
State Research Center Burnazyan FMBC of the FMBA of Russia, Moscow, Russia

Relevance. Analyzing the data of domestic and foreign literary sources devoted to the tactics of treating patients with acute calculous cholecystitis, we did not find a unified point of view of the authors in this pathology. It is known that acute forms of calculous cholecystitis average from 18.3 to 56% in the overall morbidity patterns of cholelithiasis, while the share of minimally invasive surgical techniques is rather low and varies from 12 to 68%.

Aim. Evaluate the possibilities of minimally invasive methods of surgical treatment of acute calculous cholecystitis.

Material and methods. We analyzed the results of the

surgical treatment of 112 patients operated from 2012 to 2018 in the surgical department of State Research Center Burnazyan FMBC of the FMBA of Russia in regard to various forms of acute calculous cholecystitis. As for subjects of the observations, 92 (82.1%) were women, 20 (17.9%) were men, while 81 patients (72.3%) were over 60 years old. 102 patients (91%) had severe comorbidity (COPD, CHD, etc.). All patients underwent preoperative standardized examination, including ultrasound of the abdominal cavity, EGDS, MRI cholangiography, and ERCP. Duration of the disease ranged from 2 to 18 days, while, according to the results of the examination, a perivesical infiltration was diagnosed in 79 patients (70.5%) at the preoperative stage.

Results. In all the observations, the surgical manual began with the laparoscopic stage and included the additional diagnostic component, and also puncture of the gallbladder with its emptying, as well as separation (attempting to separate) of the perivesical adhesive-infiltrative process. Conversion of access was required only in 5 cases (4.5%) - in 3 previously operated patients, the total adhesive process in the abdominal cavity was revealed intraoperatively, in 1 observation the previously undiagnosed Mirizzi's syndrome, in 1 case of colo-vesical fistula. According to the generally accepted algorithm for performing laparoscopic cholecystectomy, we did not make further attempts to isolate the elements of the hepatoduodenal ligament if it lasted more than 40 minutes and all the possibilities of the endoscopic procedure were exhausted. Drainage of the right subhepatic space was performed in 49 cases (43.7%). There was no mortality. Postoperative complications were noted only in the conversion group and were due to the development of seromas of the postoperative wound in 3 cases (2.6%).

Conclusion. Thus, the performance of laparoscopic cholecystectomy in acute forms of the gallstone disease is possible in patients with severe comorbidity, diagnosed with a pre-operational infiltrative process in the subhepatic space, and is also not associated with high rates of postoperative complications and mortality.

441

SINGLE-PORT LAPAROSCOPIC CHOLECYSTECTOMY: SINGLE-CENTER EXPERIENCE

S. Voskanyan, M. Lashchik, M. Zabelin, E. Naydenov
State Research Center Burnazyan FMBC of the FMBA of Russia, Moscow, Russia

Relevance. To date, laparoscopic cholecystectomy is the "gold standard" in the treatment of patients with benign gallbladder diseases, in whose structure the leading role is occupied by cholelithiasis. SILS technologies are an alternative to conventional multiport laparoscopy, give the best cosmetic effect with a low level of postoperative pain syndrome and comparable safety indices.

Aim. To evaluate the results of single-port cholecystectomy

in the treatment of cholelithiasis.

Material and Methods. In the Center for Surgery and Transplantology of SRC-FMBC, single-port laparoscopic cholecystectomies are performed from January 2012; during this period up to June 2018, 254 patients were treated, 18 (8.1%) patients have acute and subacute forms of calculous cholecystitis, chronic ones - 236 (92.9%), in 1 patient the intervention was simultaneous in nature - as for the concomitant chronic appendicitis, transumbilical appendectomy was performed. As for subjects of the observations, 218 (85.8%) were women, 36 (14.2%) were men, while 54 patients (21.2%) were over 60 years old, however, without significant concomitant pathology. All patients underwent a standardized examination at the preoperative stage, including ultrasound of the abdominal cavity organs, EGDS, as indicated by MRI cholangiography. In acute forms of calculous cholecystitis, the duration of the disease ranged from 3 to 5 days, while according to the results of the survey, a perivesical infiltrate was diagnosed in 5 cases at the preoperative stage. During the interventions a set of X-cone devices of Karl Storz Company with standard technology of transumbilical installation of the system, suturing and ligature fixation of the fundus of the gall bladder in 7-8 intercostal space were used. Intraoperative, during the intersection of the cystic duct and artery in 97 observations (38.2%) "clipless" technologies were used with the use of the "Liga Sure" generator of the firm "Valleylab" with an endo insert "Atlas" 5 mm, and in others 157 (61.8 %) standard clip with 8mm clips. The choice of the intersection of tubular structures was mainly determined by their diameter, degree of wall infiltration (especially in acute forms of cholecystitis), and length. Thus, we used only the clipping of the cystic duct, if its length did not exceed 7 mm and the thickness was from 5 mm. Because of a full intraoperative sanitation of the abdominal cavity, drainage of the right subhepatic space was not performed.

Results. The total duration of the intervention was 62 + 5 minutes. Intraoperatively, bleeding from the gallbladder bed and hepatoduodenal ligament was noted in 3 (1.2%) patients - it was stopped by suturing, which did not require the installation of additional equipment; in 2 cases, intensive intraabdominal bleeding was noted in the early postoperative period (in the first case, the source was coagulation damage to the posterior branch of the right hepatic artery during mobilization of the gallbladder neck, in the second - an additional branch of the cystic artery) - laparotomy was performed, bleeding was stopped. In 1 observation, on the 3rd day after the operation, the leak of the cystic duct remnant was diagnosed (the "clipless" technologies were used intraoperatively) - the endoscopic stenting of the common bile duct was performed above the level of the cystic duct, the drainage of the formed biloma under the ultrasound control. The patient was discharged on the 15th day after the operation in a satisfactory condition, the stent was removed on the 50th day after installation. It seems to us that the possible cause of bile leakage was intraoperative damage to the wall of the cystic duct by the endo-hood

during its mobilization below the level of the formation of the biological filling, and not the defect in the electrothermal treatment technology. Other patients (251) were discharged from the hospital on the 1-2 day after the operation. The need for conversion of single-puncture technology into a "traditional" 4-puncture laparoscopic intervention was noted in 7 cases (3 for chronic and 4 for acute calculous cholecystitis), and for "traditional" cholecystectomy in 1 observation (in connection with intraoperatively diagnosed colo-vesical fistula) and was caused by the technical inability to fully identify and mobilize elements of the hepatic-duodenal ligament. According to the results of a random examination of patients, 6 months after the operation, hernial defects were not noted, the postoperative scar, located intra-umbilically, visually indistinguishable from surrounding tissues. In 2 years after the intervention, relapses of hernia in the umbilical region were diagnosed in 2 patients (at the preoperative stage defects of the umbilical ring were determined).

Conclusion. In our opinion, single-puncture methods of operating patients with regard to various forms of the gallstone disease make it possible to achieve the optimal cosmetic result, a moderately pronounced postoperative pain syndrome, and rapid postoperative rehabilitation. However, the technological possibilities of their implementation are much lower in acute forms of calculous cholecystitis, involve greater risks of trauma to the elements of the hepatic-duodenal ligament than with "standard" laparoscopic interventions. The possibility of performing simultaneous interventions from a single transumbilical access in cases of concomitant surgical and / or gynecological pathology requires further study.

442

HYPERTHERMIC INTRAPERITONEAL CHEMOTHERAPY (HIPEC) IN COMBINATION WITH CYTOREDUCTIVE INTERVENTIONS FOR PERITONEAL CARCINOMATOSIS: SINGLE CENTER EXPERIENCE

S. Voskanyan, A. Kucheryavy, T. Sutor'ma

State Research Center Burnazyan FMBC of the FMBA of Russia, Moscow, Russia

The problem of peritoneal carcinomatosis remains one of the most topical in the treatment of ovarian and digestive cancer. The implementation of the hyperthermic intraperitoneal chemotherapy method (HIPEC) in combination with systemic chemotherapy has significantly increased the potential for cytoreductive treatment in ovarian cancer, gradually introducing this method in other cancer localiza-

tions. As a result of HIPEC – increased concentration of cytostatic drug in the abdominal cavity in 20-1400 times in comparison with the blood plasma. The following method is being used in 167 procedures among 136 patients since September 2010. There was also a case when patient with peritoneal mesothelioma, small and large intestinal carcinomatosis received surgery 3 times in 14 months. All the procedures are accomplishing the "Close Abdomen" technique with Performer HT using disposable sterile sets of RanD Hang & Go HT and chemotherapeutic agents (cisplatin, oxaliplatin, carboplatin, doxorubicin, and mitomycin). The temperature of the solution at the inlet drainage during the surgery that lasts 60-90 minutes is 44.5-45.0 ° C.

The patients' summary looks as following: • Patients with cancer of the ovarian - 102 (75%); • in 3 cases (2%) - cancer of the cervical uterine; • in 3 cases (2%) - cancer of the uterine corpus; • in 1 case (1%) - cancer of the uterine tube; • in 5 cases (4%) - granulosa cell of the tumor ovarian; • in 4 cases (3%) – cancer of the appendix; • in 1 case (1%) - pseudomyxoma; • in 3 cases (2%) - peritoneal mesothelioma; • in 7 cases (5%) - cancer of the colon; • in 1 case (1%) - cancer of the small bowel; • in 2 cases (2%) - cancer of the gastric; • in 3 cases (2%) - multiple cancer location - colon and ovaries. The age of the patients ranged from 27 to 83 years (mean age is 56.7 years). Out of 136 patients there were 132 (97%) women and 4 (3%) men. As a rule, the HIPEC procedure is the final stage of the surgical intervention, including the removal of the primary or recurrent tumor. In one case, HIPEC was combined with bifurcational aortoiliac and iliacaal prosthetics, in another case an intervention using cisplatin was performed to cure a female patient with a single kidney. Postsurgical lethality rate was 4.5% (6). The causes of death were • renal failure due to toxic effect of platinum based medication 0.75% (1); • peritonitis with progressive multiple organ failure and consequent: perforation of the small intestine 1.5% (2), ureter necrosis 0.75% (1), failure of colorectal anastomosis 0.75% (1); • cardiovascular insufficiency 0.75% (1). In one case (0.75%), during the procedure was noted a marked general hyperthermia of the patient, which required the use of local hypothermia without negative consequences in the long-term period. Optimal cytoreduction was achieved in 107 of 136 patients (78.7%). The long-term results evaluated in 118 of 136 patients (86.4%). All 118 patients have a survival from 1 to 70 months, no complications in the long-term period were noted. The cumulative percentage of survivors according to Kaplan-Meyer: 1 g. - 85%; 2 years - 67%; 3 years - 41%; 4 years - 38%; 5 years - 28%. The median was 15.6 months. The cumulative proportion without recurrent survivors according to Kaplan-Meyer: 1 g. - 90%; 2 years - 73%; 3 years - 46%; 4 years - 40%; 5 years - 27%. The median was 18 months. Some of the patients are scheduled to undergo a second program with a repeat HIPEC procedure("second look").

443

MUCOCELE AND MUCINOUS TUMOURS OF THE APPENDIX

Vozian Marin¹, Ghidirim Gheorghe¹, Mishin Igor¹, Rojnoveanu Gheorghe¹, Gutu Evghenii², Mishina Anna³, Danci Alexandr¹

¹Department of Surgery no.1 "Nicolae Anestiadi" and Laboratory of Hepato-Pancreato-Biliary Surgery

²Department of General Surgery and Semiology

³Department of Surgical Gynecology, Nicolae Testemitanu State University of Medicine and Pharmacy, Institute of Emergency Medicine, Kishinev, Moldova

Background: The mucocele of the appendix is a rare disease representing dilation of the appendix due to intraluminal mucin accumulation. It may exhibit benign or malignant features. The most severe complication of the appendiceal mucocele is development of pseudomyxoma peritonei – a life threatening situation characterized by excessive mucin accumulation in the peritoneal cavity as a result of mucocele perforation.

Introduction: To describe the cases of appendiceal mucocele and mucinous neoplasms (AM and AMN) and its complications treated in our unit.

Materials and methods: Review of 31 patients (22F/9 M; mean age 54.61 years) with AM, AMN and pseudomyxoma peritonei (PMP). The patients were divided into two groups: I (n=17, 54.84%) - simple mucocele and low-grade appendiceal mucinous neoplasm (LGAMN) and II (n=14, 45.16%) - with high-grade appendiceal mucinous neoplasm (HGAMN). The patients from the first group have undergone interventions: isolated appendectomy (n=13) or in conjoint with other surgeries(n=4). Three patients from the second group have had primary interventions (appendicectomy, hysterectomy+bilateral adnexectomy, bilateral adnexectomy) and repeated surgical procedures for pseudomyxoma peritonei: cytoreductive surgery with intra- and early postoperative hipertermic intraperitoneal chemotherapy (HIPEC and EPIC) (n=9), right hemicolectomy+HIPEC and EPIC (n=4), paracentesis+EPIC (n=1). The HIPEC and EPIC (SPOD) was performed with 5FU-750 mg/m².

Results: The post-operative follow-up: 71.76±12.32 months for the LGAMN group and 46.43±7.97 months for the HGAMN group. In the LGAMN group, one case of PMP developed vs 14 patients from the HGAMN group (5.88% vs 100%; p<0.0001). In the LGAMN group no deaths were recorded vs 5 patients who died in the HGAMN group (zero vs 35.71%; p=0.0118). The time range until PMP was diagnosed represented 1-168 (mean 34) months.

Conclusion: The obtained data confirm that PMP does not develop only from malignant forms of mucocele, and therefore, all the patients with appendiceal mucinous lesions have to be followed-up. There is a statistically significant difference between the survival duration and occurrence of PMP, depending on the histological type of

the appendiceal mucinous lesions which are more common in the HGAMN case.

444

INTESTINAL METAPLASIA AND ANASTOMOTIC RECURRENCE OF GASTRIC CARCINOMA

Elroy Patrick Weledji

University of Buea, Cameroon

Intestinal metaplasia (IM) of the stomach has been shown to increase the relative risk of gastric cancer. Endoscopic surveillance has been proposed and advocated for populations at risk. Those patients who had undergone surgery for gastric malignancy exhibited precancerous lesions such as atrophic gastritis and IM, and the possibility of anastomotic recurrence is higher than for the patients who had undergone benign gastric surgery. At present, there are no other recognized good markers of gastric dysplasia or cancer. The literature on IM of the stomach was reviewed to ascertain whether residual premalignant (type III) IM may predispose to anastomotic recurrence of gastric cancer.

445

THE EFFECT OF FORMALIZING PERIOPERATIVE ENHANCED RECOVERY PROTOCOL (ERAS) IN ESOPHAGEAL SURGERY

M. Yan, D. Ruchkin, M. Raevskaya, V. Sizov

A.V. Vishnevsky Institute of Surgery, Moscow, Russia

Actuality. ERAS protocol uses transdisciplinary approaches to reduce serious complications and accelerate recovery after surgery, it plays an important role to improve outcomes. Esophagectomy is a high-risk operation with the mortality rate of 8-15%, Esophagectomy is a high-risk operation (the mortality rate of 8-15%), carried out on patients with significant comorbidities. ERAS plays an important role in improving outcomes.

Aim. The objective of the study is to prove the impact of the protocol on the outcomes of esophagectomy.

Materials and methods. Between December 2012 and December 2016 150 patients with esophageal disease underwent esophagectomy with one-stage esophagoplasty. The transthoracic (McKeown) and transhiatal esophagectomy were used for 45,3% and 54,7% patients with the reconstruction: gastric tube (93,3%) and colon (6,7%). The median age was 58 years (47;66), females were significantly less predisposed than males (1:2), the prevalence of patients with ASA III-IV. The ERAS protocol included a consultation with ERAS team (anesthesiologist, resuscitator, therapist),

nutrition support, compensation comorbidities, maintenance of normothermia, rational use of vasopressors, immediate extubation, multimodal analgesia, early mobilization and feeding.

Results. 21 patients (14,0%) had postoperative complications. There was no anastomosis leakage, necrosis of transplant was diagnosed in 2,7% cases. Eventration was observed in 4 cases, hematoma of the pleural cavity and deep vein thrombosis in 2 cases, pneumonia-in 4 cases, hydro- and pneumothorax –in 2 cases. 3 patients had a paresis of the vocal cords, pneumonia and thereafter sepsis. 2 patients had a stroke and 1 patient – TIA. The postoperative mortality rate was 3,3% (5 patients), the causes were respiratory distress and haperorenal syndrome, pneumonia, stroke and disseminated intravascular coagulation. Median postoperative day (POD) and ICU were 8 (6;12) and 0,7 (1;3) days.

Conclusion. Application of the ERAS, the personalization of treatment has allowed reducing the incidence of postoperative complications and mortality after esophagectomy, reducing the number of failures in the operation and minimizing the risks for patients with ASA III-IV.

446

THE USING OF A «COMPROMISED» STOMACH IN ESOPHAGOPLASTY

M. Yan, D. Ruchkin

A.V. Vishnevsky Institute of Surgery, Moscow, Russia

Actuality. The using of compromised stomach (pathologically changed or previously operated stomach) is associated with the risk of circulatory disorders and deficiency of length of transplant.

Aim. The objective of the study is development of clear criteria for suitability to use a compromised stomach for esophagoplasty.

Materials and methods. 57 patients underwent esophagectomy with one-stage esophagoplasty at Institute between June 2011 and July 2016. Gastric tube was used in 39 cases, but in 18 cases it was considered which required using the colon. The reasons of refuse were previously operated stomach (6 patients), gastrostomy with injury of deep epigastric arcade (2 patients). Colon was used for esophagogastrectomy (10 patients), because there were esophageal tumor involving the stomach (6 patient) and synchronous esophageal and gastric pathology (2 patients).

Results. Intraoperative complications among patients with colonic esophagoplasty developed in 1 (1,8%) case in the form of disseminated intravascular coagulation. The patient died after 6 hours of hemorrhagic shock (V st. Clavien-Dindo). It was postoperative mortality rate. Anastomosis leakage occurred in 1 case (stage II Clavien-Dindo) with gastric tube. Thrombosis of transplant's vascular was diagnosed

only twice and led to necrosis of colon (stage IIIb). There were eventration (1), abscess pelvic and pneumonia (1), acute intestinal obstruction (1) and hematoma of posterior mediastinum (2) (stage IIIb).

Conclusion. In 2/3 of observations compromised stomach was suitable for reconstruction after esophagectomy. Criteria for suitability of stomach are: the anatomical integrity of all sections of the stomach; preservation of the vascular arcades more than 2/3 of the greater curvature.

447

LAPAROSCOPIC TOTAL GASTRECTOMY IN COMPLICATED STOMACH CANCER

P. Yartsev, S. Tarasov, M. Rogal, I. Kirsanov

N.V. Sklifosovsky Memorial Emergency Medicine Research Institute

Actuality. Laparoscopic surgery for gastric cancer is still not a standard procedure. Similar survival rate and complications have been demonstrated in open surgery vs laparoscopic surgery studies.

The aim. The world experience of minimally invasive oncosurgery is growing rapidly, however, there are still discussions about the advantages and disadvantages of laparoscopic access in the treatment of gastric cancer.

Materials and methods. Over the past 5 years, our team has performed 20 laparoscopic total gastrectomy in patines with complicated gastric cancer . All patients had GI bleeding. The operation was performed after hemostasis by endoscopic intervention. There were 9 women, 11 men, mean age – 62.6 ± 14.2 years. The tumor was cT2-cT3. All tumors without distant metastases. In 100% of cases there was a laparoscopic total gastrectomy, lymphadenectomy D2, R0. The average operation time was 448 ± 54 minutes (from 365 min to 570 min).

Results. The operations lasted for a long time due to technical difficulties in removing the large omentum a single block; separation of adhesions in 9 patients due to previous operations. Intraoperative blood loss averaged 120 ± 36,6 ml (from 50 to 200 ml). The length of stay in intensive care unit was 3 ± 1.1. Postoperative complications developed in 9 patients (45%). The average length of stay was 26.1 (from 10 to 53 days). The final diagnosis according to the classification of TNM (UICC 7-th) on the prevalence of cancer: IA – 4(20%), IB – 1(5%), IIA – 5(25%), IIB – 3(15%), IIIA – 1(5%), IIIB – 1 (5%), IV – 5-and (25%) patients. There were no postoperative deaths. In the remote period 3 patients died. The patient was 61 years old with stage IV cancer, a year after the operation revealed the progression of the oncological process, metastatic liver damage, mechanical jaundice, which led to death in 1.5 years from the date of operation. The patient did not receive chemotherapy. In a patient 86 years with stage III cancer death occurred on the back-

ground of a progressive cancer process in 1 year after surgery. The patient did not receive chemotherapy. One patient died 2 months after the operation, the cause of death was PE. In 16 patients (84,2%) of recurrence of the cancer process have not been identified.

Conclusion. Our experience with laparoscopic total gastrectomy in gastric cancer with bleeding has shown that these operations are technically feasible, while being radical. Laparoscopic access gives the benefits of mini-invasive surgery and provides better visualization and precision of lymphadenectomy.

448

ARE THE TRENDS IN THE PROFILE OF PAEDIATRIC SURGICAL CONDITIONS SEEN AT A TEACHING HOSPITAL IN GHANA CHANGING?

A. C. Yifieveh, B. Duduyemi, Y. Hardy

Komfo Anokye Teaching Hospital, Kumasi, Ghana

Actuality. In 2002, Abantanga and colleagues documented the common elective pediatric surgical cases seen at a tertiary facility. Ghana instituted a surgical residency program in 2004 to meet skill demands at tertiary and peripheral centers. Due to the increasing numbers of surgical trainees, we opined that trends in elective pediatric surgeries might have changed since 2002.

Aim. We set out to explore current trends in the indications for paediatric surgical procedures in a large teaching hospital in Ghana.

Materials and methods. A record review of the pediatric surgical register at Komfo Anokye Teaching Hospital theatre complex was carried out for January 2012 to December 2015. Data on age and sex, year of and type of surgery, diagnosis and procedure performed was collected. Only entries with complete and legible information were included.

Results. A total of 1062 entries out of 1086 were suitable for analysis. The ages ranged from 0-14years with a mean age of 1year and a male-female ratio of 2.5:1. The most common elective procedures were for Inguinal hernias/hydroceles (29%), Anorectal malformations-ARM (15.7%), Undescended testes (10.3%), Umbilical hernia (5.4%), Hirschsprung's disease (5.3%) and Corrosive esophageal strictures-CES (2.1%).

Conclusions. Compared to the study from 2002 (1,200 cases from 1997-2000), elective surgeries reduced by 10.9%. Though still most common, inguinal hernias reduced by 50%, possibly due to more trained personnel at the peripheries. There was a marked increase in ARM (224%) and CES (320%). These changing trends could be due to increased public awareness of the availability of trained specialists at our center capable of handling such cases.

449

MID-TERM OUTCOMES OF CORRECTIVE SURGERY FOR ANORECTAL

A. C. Yifieveh, B. Duduyemi, Y. Hardy

Komfo Anokye Teaching Hospital, Kumasi, Ghana

Relevance. Anorectal malformations (ARM) are a spectrum of congenital defects of the distal gastrointestinal tract. Although faecal continence and the absence of constipation are recognised measures of outcome of curative surgery for ARM, evaluation of these measures can be challenging particularly in resource-poor countries. The difficulty of long-term follow-up in such settings and the other plausible causes of faecal incontinence other than the surgical procedure performed are the usual reasons. The Krickenbeck score for faecal incontinence is one objective way of measuring the surgical outcome following the surgical correction of ARM.

Object. We present the medium-term outcomes of the patients who had ARM surgically corrected at our hospital.

Materials and methods. The folders of all patients who had curative surgery for ARM at our hospital (Komfo Anokye Teaching Hospital, Kumasi) from 2012-2016 were retrieved from the records department. Those who had had colostomy closure after curative surgery were identified. Data on age, sex, diagnosis and type of corrective surgery for these patients were documented. Telephone interviews of their mothers were then conducted and the incidence of faecal soiling and constipation recorded.

Results. A total of 46 interviews were concluded out of the 53 patients identified. The ages ranged from 8 – 107 months with an interquartile range of 9-24months (SD 16.93) and a male-female ratio of 1:1. Most patients (61%, n=28) had voluntary bowel movements without faecal soiling (Krickenbeck grade 1) and 1 had persistent constipation. Urinary disturbances were experienced by 4 patients (incontinence-3, straining at micturition-1).

Conclusions. Our study reveals acceptable medium-term outcomes for most patients who had corrective surgery for ARM at our centre. Long term follow-up and further evaluation of patients with faecal incontinence is necessary.

450

POLYSEGMENTARY CRYODESTRUCTION IN TREATMENT OF NON-SPECIFIC DIFFUSE LESIONS OF PARENCHYMA

V. Yudin¹, O. Brovkin¹, V. Osipov¹, M. Donichenko²

¹SBE RR "RCH", Ryazan, Russia

²SRR "Elatom device plant", Ryazan, Russia

Cryogenic methods are the most protective and efficient

medical techniques, including palliative and ambulance aid. Nowadays, cryosurgery is widely used in the world in various branches of clinical medicine, mainly, in oncology, gynecology, dermatology, urology, cardiosurgery, hepatology. Elaboration of cryosurgical device within this project was started in 1999, using the money of the "Fund of Supporting of Small Business in Scientific and Technological Sphere". The output of the project was a multifunctional cryosurgical and cryotherapeutical device KRIO-01, manufactured by SSR "Elatom device plant" in 2007. At present KRIO-01 is the only series home-made stationary cryoapparatus for numerous medical specialists, including abdominal, intraoperation and laparoscopic surgery. It took 10 years for clinical testing of cryodestructor (the experimental model "KRIO-01 Elamed" for different diseases: cutaneous benign formations (benign tumour skin scars, metastatic tumours of liver, tumours and chronic inflammations of the head of the pancreas, tumours of kidney, 300 patients were treated. On the basis of clinical investigations the patient was given a possibility to use a cryodestructor for treatment of keloid scars. Since 2010 we have been investigating the efficiency of cryogenic influence on liver tissue of patients with liver cirrhosis. The aim of investigation –improving of morphological condition of liver, achieving regress of intralobular sclerosis of liver. 18 patients took part in the clinical investigations: 15 males and 3 females. Average age was 42.9. Liver-cellular inefficiency was estimated according to Child-Pew scale. 4 patients were referred to class A-5-6 scores, 14 patients –to class B-7-9 scores. In 3 patients the cause of cirrhosis was viral hepatitis C, in 15 patients-toxic etiology. Operation was performed on, using endotracheal narcosis. In all cases laparoscopic access was used; via the umbilical port a troacar was introduced, then optics, an additional troacar in epigastral area for introduction of a cryoinstrument and additional a 5 mm troacar. During excretory laparoscopy a visual evaluation of liver condition (size, colour, form) was done. After that a biopsy material was taken, and cryodestruction of all accessible segments (5-7 points of influence) was done. In 3 cases laparoscopic cholecystectomy for cholelithiasis was performed on. Operation time was 1.5-2.5 hours. Follow-up was in 11 patients (1 year after operation-cryodestruction of liver). Subjectively: patient felt satisfactory, from time to time they experienced some pain in the right subcostal area. During physical examination: skin of usual colour. There was no ascitis there. USI: liver is not increased in size, is of a correct form, the contours are even, the structure is homogenous. Dopplerography of hepatic vessels: hemodynamic values are within the norms, spleen and portal veins are not dilated. In the biochemical blood test gradual (within a year) reduction of bilirubin level (11%), transaminase (23 %), thymol test (from 4 to 1.5 units), alkaline phosphatase (8.3%).

Conclusion: polysegmentary cryodestruction of liver in patients with cirrhosis of class A,B according to Child-Pew scale promotes stabilization of morphological parameters of liver and improves life quality of patients. After cryodestruction liver insufficiency is not increased, but reduction of cytolysis and inflammatory processes take place.

451

EXTRAORGAN GASTROINTESTINAL STROMAL TUMOR OF THE GREATER OMENTUM. CLINICAL CASE

V. Yugay, M. Nikulin, I. Stilidi

National medical research center of Oncology named after N. N. Blokhin, Moscow, Russia

Significance: Gastrointestinal stromal tumors (GIST) formed in the gastrointestinal tract (GIT) are the most common type of mesenchymal malignancies. About 10% of all gastrointestinal stromal tumors are GIST extractors developing outside the gastrointestinal tract. Included in the group are also GIST of the greater omentum constituting about 1%. In more than 80% of cases GIST contain mutations of C-kit and PDGFRA. We have described the case of successful combined treatment of a giant gastrointestinal stromal tumor of greater omentum with a mutation of the 11th exon of the C-KIT gene.

Purpose: The aim of this study is to describe and analyze the effect of combined treatment of a patient with a metastatic form of GIST of the greater omentum.

Materials and methods: The patient, 64 years old, was taken to the Department of abdominal Oncology in serious condition with complaints of shortness of breath and abdominal enlargement in volume. CT revealed a large tumor in the abdominal cavity with compression of the diaphragm and the left lung, the tumor size is 30x40 cm. The angiography showed that the source of blood supply was the gastro-omental vessels. With the presumable diagnosis of "retroperitoneal tumor", the patient was operated with left-sided thoracoabdominal access. It was found that the tumor comes from the greater omentum, while on the peritoneum of the lateral channel small metastases were revealed. Resection of the large omentum was performed. Immunohistochemical study showed the expression of CD117 (+++), CD34 (++) in tumor cells. The index of proliferation of tumor cells via the expression of Ki-67 reached 12-15%, 36 mf/10 HPF. The genetic study revealed a mutation in the 11th exon KIT –stromal tumor of the greater omentum (EGIST), spindle-cell variant of the structure, degree 3 of malignancy (according to the FNCLCC system). Treatment with imatinib 400 mg per day was prescribed.

Results: In 141 months the control examination amid the therapy with imatinib revealed a metastasis in the anterior abdominal wall with 3,5x3x2,5 cm in dimensions. On 09.11.17 the patient saw a removal of metastasis to the anterior abdominal wall. The immunohistochemical examination confirmed metastasis of GIST. The index of tumor proliferation activity was (Ki67) – 45%. In the postoperative period, the patient continued to take imatinib at the same dose of 400 mg per day. No signs of progression were revealed in the control examination 6 months after the operation.

Summary: We have demonstrated the case of successful treatment of gastrointestinal stromal tumor of the large

omentum with metastases on the peritoneum. The 12-year relapse free period with imatinib treatment is unique in our practice. Reserve with the progression in such patients is repeated surgical treatment and targeted therapy of the 2nd and 3rd lines.

452

LAPAROSCOPIC TOTAL PANCREATODUODENECTOMY: REPORT OF 10 CASES

Yunqiang Cai, Bing Peng

China

Background: Laparoscopic total pancreatectomy (LTP) is technical challenging and rarely reported in the literature. Herein, we introduced a safe and feasible technique to perform LTD basing on our own experience.

Methods and materials: Over the period of July 2015 to June 2018, 10 patients underwent LTP at our institution. Demographic characteristics, intraoperative and postoperative variables, and follow-up outcomes were prospectively collected.

Results: Four male and six female patients were included in this study. The median age of the patients was 51 years (range 29 years to 79 years). The post-operative pathological diagnosis included pancreatic ductal adenocarcinoma (six cases), intraductal pancreatic mucinous neoplasm (3 cases) and chronic pancreatitis (1 case). No patient required conversion to open surgery in our series. Two patients with superior mesenteric vein / portal vein involvement underwent LTP with venous resection and reconstruction. The median operative time was 355 min (range 300 min to 470 min). The median estimated blood loss was 200 ml (range 50 ml to 500 ml). Only one patient required blood transfusion. The median post-operative hospital stay was 17 days (range 12 days to 23 days). In terms of complication, one patient suffered from bile leakage and another patient suffered from delayed gastric emptying. Both patients cured with conservative therapy. There is no 90-days mortality in our series.

Conclusion: Laparoscopic total pancreatectomy can be safely and feasibly performed in well-selected patients.

453

PROSPECTIVE PHASE II TRIAL OF NEOADJUVANT CHEMOTHERAPY WITH GEMCITABINE AND S-1 (GS) FOR BORDERLINE RESECTABLE (BR)/ UNRESECTABLE (UR) PANCREATIC CANCER (CAP-003 STUDY)

Sato Yutaka¹, Yoshitomi Hideyuki¹, Takano Shigetsugu¹, Kagawa Shingo¹, Furukawa Katsunori¹, Takayashiki Tsukasa¹, Kuboki Satoshi¹, Miyazaki Masaru^{1,2}, Ohtsuka Masayuki¹

¹*Department of General Surgery, Chiba University, Graduate school of medicine, Chiba, Japan*

²*Department of General Surgery, International University of Health and Welfare, Mita Hospital, Tokyo, Japan*

Relevance: Surgical and complex treatment of pancreatic tumors. Complex treatment in pancreatic cancer: neoadjuvant chemotherapy, indications, modern principles, impact on long-term patient survival.

Object: Recently, neoadjuvant therapy for BR/UR pancreatic cancer is widely performed. However, no standard regimen has been established so far. Gemcitabine and S-1 (GS) showed favorable response rate in unresectable pancreatic cancer. We performed phase II study to estimate the safety and efficacy of GS as preoperative therapy for BR/UR pancreatic cancer.

Methods: Patients with BR or UR pancreatic cancer without distant metastasis were enrolled. Patients received GS (S-1 60/80/100mg/day based on BSA po, d1-14 plus GEM 1g/ m2, iv, d8, 15, q3w X 3). Thereafter, staging was re-estimated and patients underwent surgery, if possible. After surgery, patients received adjuvant therapy with S-1 (60/80/100mg/day based on BSA po, d1-14 q3 X8). Primary endpoint was R0 resection rate and secondary endpoints included R0+R1 resection rate, overall survival, and safety.

Results: Between April 2011 and October 2014, 46 patients were enrolled in this study. One patient was excluded due to the accompanied breast cancer which was found just after enrollment. GS therapy was discontinued in 3 patients due to adverse events (AE) in 2 and tumor progression in 1. Grade 3 or more hematologic AE was occurred in 21 patients (46.7%) and non-hematologic AE in 3 patients (6.7%). No treatment related death was occurred. Thirty six patients underwent surgical resection and R0 and R0+R1 resection was achieved in 17 (37.8%) and 33 patients (73.3%), respectively. Median overall survival and 2 year survival rate were 18.9m and 47.6%, respectively, with 18.7m of median observation period. Those of resected patients were 28.8m and 59.8%, respectively.

Conclusion: GS is well tolerated as neoadjuvant therapy. The favorable overall survival, especially for patients with resection, indicates the usefulness of this regimen for BR/UR locally advanced pancreatic cancer patients.

454

A RARE CASE OF MUCINOUS CYSTIC NEOPLASM OF THE LIVER CONSISTING OF MUCINOUS AND SEROUS CYSTS

Iwano Yusuke

Background. Mucinous cystic neoplasm of the liver (MCN-L) is a rare cyst-forming tumor, traditionally called biliary cystadenoma and cystadenocarcinoma. The cystic content and its wall are not well investigated.

Case Presentation. A 34-year-old woman consulted a physician with a chief complaint of epigastralgia. Ultrasonography (US) showed a liver cyst of 50 mm in diameter. 2 years later, US revealed the enlarged hepatic cyst measuring 130 mm in diameter. She was referred to our hospital for the further treatment. She had a fist-sized firm mass palpable in the epigastrium without tenderness. Laboratory data showed normal liver function tests and tumor markers including carcinoembryonic antigen (CEA) and carbohydrate antigen 19-9 (CA19-9) were within normal limits. Both hepatitis B virus antigen and anti-hepatitis C virus antibody tests were negative. Contrast abdominal computed tomography showed a multilocular cystic lesion of 139 x 100 x 80mm in size in the left lobe with multiple thick septal formations. Magnetic resonance imaging revealed a hypointense-cystic lesion on T1-weighted image and hyperintensity on T2-weighted image. Magnetic resonance cholangiopancreatography did not show a clear communication between the cyst and the biliary duct. As the preoperative diagnosis was MCN-L with epigastralgia, left hemihepatectomy was performed. Resected specimen had two types of the cysts. One was a mucinous cyst whose viscosity was high, and the other was a serous cyst whose viscosity was low. No mural nodules were found. While total bilirubin in the low-viscosity fluid was 0.2 mg/dL, the levels of CEA and CA19-9 in the serous fluid were 953.9 ng/dL and 25,625 U/mL, respectively. Microscopic findings revealed an ovarian-like stroma in both types of cystic lesions. The stromal cells were immunohistochemically positive for estrogen and progesterone receptors, leading to the final diagnosis of MCN-L. While mucinous goblets and columnar epitheliums, immunohistochemically strongly positive for MUC5AC, Periodic acid-Schiff, and Alcian Blue, were found in the mucinous cysts, they were hardly found in the serous cysts. **Conclusion.** We report a rare case of MCN-L consisting of mucinous and serous cysts; further investigations are necessary to clarify the biological features.

455

EXPERIENCE OF TRANSARTERIAL CHEMOEMBOLIZATION FOR UNRESECTABLE HEPATOCELLULAR CARCINOMA

V. Zagainov, A. Seregin, G. Gorochov, E. Zagainov, I. Tarasov, A. Chichkanova

Federal State-Funded Healthcare Institution «Volga District Medical Centre» of Federal Medical and Biological Agency, Nizhny Novgorod, Russia

Relevance. Hepatocellular carcinoma (HCC) take the 6th place of morbidity in the world with poor prognosis. Annually, 5-6 new cases are registered per 100 ths of the population. The average life expectancy without targeted treatment is 3-6 months.

AIM. Evaluate effectiveness of transarterial chemoembolization of the hepatic artery (TACE) in the treatment of unresectable HCC.

Materials And Methods. From 2009 to 2018 was performed 148 TACE for treatment unresectable HCC. Women/men was equal number. The average age was 57.8 ± 9.9 years (23 - 92). Hystology verification was in all cases. TACE was performed for unsuitable for surgery patients with liver cirrhosis B and C (Child-Pugh) or with advanced stages of disease without extrahepatic metastases. Milan criteria are the benchmark for selection of patients for liver transplantation. 465 courses of TACE were performed, numbers of procedure for one patient were from 1 to 13. Repeated TACE was provide after 1.5-2.5 months. After 1 courses treatment was stopped in 19 (13,3%) cases due to progression of disease, worse ECOG, liver dysfunction. For TACE used mostly doxorubicin or epirubicin with hepaspheres – 119 (81%) and lipiodol – 29 (19%) cases. Average post-operative days were 6,3+ 1,1 (4-7).

Results: The treatment effect was evaluated according to RECIST criteria. Response for treatment in 88 cases (59.46%). Total tumor necrosis, histology confirmed was in 38 patients (44.4%). Stabilization was in 41 cases (27.7%). The progression of the disease records in 19 (12.84%). Complication rate is 14 (3.0%) cases: pancreatitis in 8 (1.8%), liver abscess in 6 cases (1.2%). All liver abscesses were drained by ultrasound navi. Arterial bleeding from point with the formation of aneurysm was in 5 (1.2%) cases. Post-TACE syndrome was in all cases and manage by symptomatic treatment. Hospital mortality was in two cases (1.5%) due to liver dysfunction. Median survival 15 months.

Conclusions. TACE in treatment of unresectable HCC is effective method, wich can also used as down-staging procedure before radical treatment include hepatectomy and transplantation.

456

EXPERIENCE OF TRANSARTERIAL CHEMOEMBOLIZATION IN TREATMENT OF UNRESECTABLE CHOLANGIOCARCINOMA

V. Zagainov, A. Seregin, N. Kiselev, E. Zagainov, I. Tarasov, A. Chichkanova

Federal State-Funded Healthcare Institution «Volga District Medical Centre» of Federal Medical and Biological Agency, Nizhny Novgorod, Russia

Relevance. Cholangiocarcinoma (CCA) is one of the most aggressive cancers with very poor prognosis.

Aim. Evaluate the long-term results of transarterial chemoembolization (TACE) in treatment of unresectable cholangiocarcinoma.

Materials and methods. From 2008 to 2018 in «Volga district medical center» were treated by TACE 51 patients with unresectable CCA. Women/men – 27/24. The average age was 53 ± 7 years (43-78). A total number of interventions were 123. Patients underwent 1-8 courses of TACE. Number of courses depend on advance of disease, supply, somatic status and response to treatment. For TACE used Lipiodol with Gemcitabine (600 to 1000 mg per procedure). Histology verification was in all cases.

Results. Complications were in 2 cases: bleeding from the puncture point-1 (2.5%), dissection of the right hepatic artery-1 (2.5%). Response to treatment was assessed based on MRI or CT-scans by RESIST-criteria. Partial response was observed in 37 (72.5%) patients. Negative dynamics in 14 (27.5%) patients. The duration of follow-up was 2 to 36 months. 92% patients have a moderate post-TACE syndrome which stopped on 2-3 postoperative days by conservative treatment. In 3 cases, signs of mechanical jaundice appeared due to the progression of disease. These patients underwent bile duct decompression followed by antegrade stenting. One-year survival was 19 (37.2%) patients, two-year 5 (12.5%) patients, three-year 3 (7.5%) patients.

Conclusions. TACE in treatment of unresectable cholangiocarcinoma is effective method with a low incidence of complications.

Higher Education «Privolzhsky Research Medical University» of the Ministry of Health of the Russian Federation, Nizhny Novgorod, Russia

Relevance. Evaluation of the hepatic parenchyma as well as liver volume is a key strategy to determine the tactic of treatment in liver surgery. In addition, a preoperative evaluation of the hepatic parenchyma allows predicting the risk of postoperative complications, including posthepatectomy liver failure. At present, there are no reliable methods to determine the functional condition of the hepatic parenchyma. **Aim.** To assess the functional condition of the hepatic parenchyma by multiphoton FLIM microscopy.

Materials and methods. To determine the condition of the hepatic parenchyma we used multiphoton and fluorescence lifetime imaging microscopy. Two-photon excited fluorescence intensity and FLIM images of NAD(P)H and FAD/bile components were obtained by LSM 880 microscope (Carl Zeiss, Germany). NAD(P)H and FAD/bile components fluorescence was excited with a Ti:Sa femtosecond laser, using a pulse duration of 140 fs at wavelengths of 750 nm and 900 nm, respectively. FLIM images were processed in SPCImage software (Becker & Hickl GmbH). The experiments were performed on male Wistar rats. All animals were divided into 2 groups: control and experimental. Each group consisted of 5 rats. The experimental group included rats with cholestatic liver disease, induced by ligation of the common bile duct. Imaging was performed in 7 days after bile duct ligation. Fifteen images were collected for each rat liver from non-overlapping fields. A statistical analysis was performed by STATISTICA 64 software, version 10 (StatSoft Inc., USA).

Results. We analyzed the level, lifetime of fluorescence of intracellular cofactors and their contributions in normal and cholestatic liver. In healthy liver: hepatocyte cords with bright autofluorescence of NAD(P)H. Autofluorescence of FAD is not expressed in comparison with NAD(P)H. In diseased liver: injury of hepatocytes can be observed as reduced fluorescence of NAD(P)H in fluorescence image. Moreover, in the experimental group there are a decrease fluorescence lifetimes free and protein-bound forms of NAD(P)H and contribution protein-bound forms of NAD(P)H. These data show us the presence and degree of the pathological process in the liver.

Conclusion. We showed differences in the healthy and cholestatic liver based on the fluorescence of the metabolic co-factors NAD(P)H and FAD, their fluorescence lifetimes and the contributions by multiphoton FLIM microscopy. All presented methods do not need additional staining of samples or the incorporation of any markers to study different parameters, which have pronounced changes in hepatocytes and their microenvironment with common pathological diseases of the liver. This method of analysis can be translated into practical medicine, because there is an instrumental implementation of multiphoton microscopy for intraoperative examination of the organs and tissues of patients through the MPT Flex system.

457

IN VIVO MULTIPHOTON AND FLUORESCENCE LIFETIME IMAGING MICROSCOPY AS A TOOL TO ASSESS THE CONDITION OF HEPATIC PARENCHYMA

V. Zagainov^{1,2}, N. Bobrov^{1,2}, N. Kiselev^{1,2}, D. Kuznetsova², V. Dudenkova², E. Zagaynova²

¹Federal State-Funded Healthcare Institution «Volga District Medical Centre» of Federal Medical and Biological Agency, Nizhny Novgorod, Russia

²Federal State Budgetary Educational Institution of

458

THE FUTURE OF THE PATIENTS AFTER PELVIC EXENTERATION

Zarkov Kostadin¹, Petkov Christian¹, Bekir Sabrie¹, Assenov Assen¹, Mochurova Maya¹; Velinov Peter¹; Yusef Hani¹; Penev Lubomir¹, Grancharova Silvia²

¹First Surgical Department, Fifth General Hospital, Sofia, Bulgaria

²Clinique of Abdominal Surgery. Military Medical Academy, Sofia, Bulgaria

Background. Pelvic exenterations (PE) as combined and extended operations, open for discussion numerous problems and topics. The main paradigms concerning the management of extended pelvis tumors are: Pelvic exenteration or palliation? Quality of life or duration of life? Radical pelvic exenteration or palliative?

Aims. What is the future of patients after having PE? We assess this in terms of postoperative complications (early or late; related to gastrointestinal and urinary system, and pelvic floor; also regarding type of tumor – location, histopathology, primary or relapse); mortality; survival rates and quality of life. Is the PE a feasible procedure for treating extended pelvic tumor in regard of increase of survival rates?

Materials and methods. For the period 1992-2011 are analyzed 289 PE patients in our hospital - 88 total, 116 posterior and 85 anterior PE for advanced primary or relapse rectal (54), urological (12) and genital (223) carcinomas. Radical PE-197; palliative PE-92; palliations-47. Primary PE-107; secondary-for 124 relapse and 58 persisting tumors. Studied patients are distributed into two periods – I group for 1992-2008 (131) and II group for 2009 – 2011 (96). We compare the complications and survival rates in the two groups for radical PE vs palliative PE vs palliations.

Results. Patients are aged from 28 to 75. Intraoperative mortality – 0%. Postoperative mortality to 30th day – 6 patients. Complications. Early and late– gastrointestinal – I group 25% / II group 23%; urinary –I group 48% / II group 38%; pelvic floor – I group 44% / II group 24%. Survival - radical PE: for I group - 12 months–52%; 18 months –35%; 2 years –21%; 48 months –18%; 5 years –16%; for II group - 12 months –48%; 18 months –33%; 2 years –25%; 48 months –22%; 5 years –19,6%. For palliative PE –to 24 months. For palliations 2-6 months. Postoperative treatment, analyzed in: primary PE – RT–17; RT&CT–15; CT–23; without–10; secondary – RT–14; RT&CT–13; CT–46; without –26.

Discussion. The potential complications after pelvic exenteration are numerous. Almost every patient develops at least 1 complication, and approximately 40-50% experience a major complication requiring further diagnostic and therapeutic procedures. Complications are more often in the palliative pelvic exenteration cases. Reported 5-year survival rates after pelvic exenteration range from 23-61% (16% for our patients). All authors report for a decrease

in quality of life that is more apparent in total PE cases. Our patients have agreed with the worsened Quality of life following pelvic exenteration. They have accepted to live having the two stomas.

Conclusions. Although postoperative mortality is low in modern series, the major morbidity of pelvic exenteration still remains very high. Despite the high level of invalidism, pelvic exenteration is the only more radical method for treatment of advanced primary and relapse tumors in the pelvis, resulting in increased survival rates compared to palliation only. Postoperative results are poor when the tumor is too widely spread.

459

PROPHYLACTIC MEASURES AS AN OBLIGATORY COMPONENT OF PATIENTS WITH ACUTE ADHESIVE INTESTINAL OBSTRUCTION TREATMENT

V. Zemlyanov, B. Filenko, B. Sigua, P. Kotkov
Mechnikov North-West State Medical University, St. Petersburg, Russia

Actuality. Despite the high incidence of abdominal adhesions, the results of treatment remain unsatisfactory, because of the high disease recurrence rate. The necessity of further studies is explained by the lack of standardized approaches to the treatment of patients with acute adhesive intestinal obstruction.

The purpose of the study. Improvement of the acute adhesive intestinal obstruction treatment remote results.

Materials and methods: To complete the stated target, we developed the prophylactic algorithm. It was used in 105 patients of the main group. Of these, 43 (subgroup 1A), operated on an emergency basis and 62 (subgroup 1B) in the planned after elimination of the acute intestinal obstruction episode. 155 patients of the control group were treated by traditional methods: 83 operated, 72 - treated conservatively. In the main group endovideosurgery was chosen as an operative access, in the absence of contraindications. Intraoperative revision allowed to determine the kind of treatment (laparoscopic or conversion). All operations finished with the applying of certain prophylactic measures, which depended on the severity of adhesive process and kind of operative access. In case of local adhesive process operation completed with instillation of a resorbable gel of carboxymethylcellulose in the abdominal cavity. Defects of the peritoneum were replaced by collagen membrane "KolGara". In case of widespread fibrous-adhesive the principle of physiological enteroplication was realized by prolonged naso-intestinal intubation with preservation of the intestinal probe in the gut in the postoperative period from 11 to 14 days, in order to form a controlled adhesive process. To achieve the effect of hydroflotation, 4% solution of Icodextrin ("Adept") was introduced into the abdominal

cavity, which decreased the extent of adhesion process and reduced the risk of cicatricial complications.

Results. The results of treatment were investigated from 2 to 10 years. The best results were achieved in subgroup 1A after a planned operation: 29 (56%) patients had a stable remission, 27 (44%) had periodic pain attacks of varying severity, stool retention, mainly in the form of constipation. In 6 cases (10%) acute intestinal obstruction occurred, which required hospitalization. One patient (1.6%) was reoperated. In subgroup 1B 18 patients (41.8%) had a significant improvement, another 18 (41.8%) complained of non-recurring pains, irregular stools, diarrheal disorders. Relapses of intestinal obstruction were observed in 7 (16.4%), two (4%) were operated. Thus, the incidence of unsatisfactory results among patients in the main group was 12.4%. In control group good results were obtained in 9 patients (11%) - clinical remission of the disease. In 48 (58%) cases symptoms of intestinal passage disorder, which did not require in-patient treatment, occurred. Unsatisfactory results were obtained in 26 (31%) patients - 19 (23%) were reoperated.

Conclusion: Thus, patients with recurrent acute adhesive intestinal obstruction are advisable to be operated in a routine order, using endovideosurgical techniques and prophylactic measures, depending on the extent of adhesive process.

460

CHALLENGES IN DIAGNOSIS OF PANCREATIC CANCER

Lulu Zhang, Santosh Sanagapalli, Alina Stoita

Department of Gastroenterology, St. Vincent's Hospital Sydney, Darlinghurst 2010, NSW, Australia

Relevance. The motivation for this research is the dismal outcomes for pancreatic cancer that have failed to significantly improve; it is this that is the key problem to be solved. The main focus of this review is to describe the current state of play in pancreatic cancer diagnosis. Rapid and accurate diagnosis of a pancreatic mass is crucial for improving outcomes. After evaluating the evidence underpinning all of the widely used modalities for diagnosis, we intend to make a comparison of these modalities and provide an evidence-based algorithm for diagnosis.

Object. The main objective of this review was to evaluate and compare the suitability and accuracy of the current diagnostic modalities that exist for pancreatic cancer. We are currently lacking effective diagnostic and screening modalities to diagnose pancreatic cancer at an early, and therefore more likely curative stage. Therefore, it is valuable to have a thorough understanding of the currently available diagnostic technology, including its benefits and limitations, in order to provide direction for future research. Pitfalls and mimickers of pancreatic cancers, biomarkers and the current

screening programs in high risks individuals will also be discussed.

Materials and methods. A MEDLINE search was conducted using the following keywords and phrases: "pancreatic cancer, diagnosis, imaging, biomarkers, screening, endoscopic ultrasound, pitfalls", with a focus on more recently published research. In addition, we performed a manual review of the reference lists of the primary and review articles to ensure identification of all relevant articles. In particular, large scaled meta-analyses and systematic reviews were preferred.

Results. Diagnosis relies on imaging modalities such as computed tomography (CT), magnetic resonance imaging (MRI), positron emission tomography (PET) and endoscopic ultrasound (EUS) that are used along with tissue acquisition. Early detection is the only way of identifying small cancers and proceeding with curative surgery. We describe the different diagnostic modalities that currently exist, evidence underpinning their use and compare the benefits and disadvantages of each.

Conclusions. While the early diagnosis of pancreatic cancer remains challenging, improvements in diagnostic technology and methodologies in the last decade will hopefully translate into improved outcomes. Screening of high-risk individuals using EUS and/or MRI is recommended and shows promise in early detection. In patients with suspected pancreatic cancer we propose the use of CT or MRI as first-line investigations, with the choice between the two being determined by cost, availability and local expertise. Such cross-sectional imaging modalities remain the gold standard for staging, both of the primary lesion and detection of distal metastases. EUS has become a powerful diagnostic modality and should be used in adjunct, being superior in the detection of small lesions and having the ability to obtain a tissue diagnosis. While research is ongoing, at present there is no role for the use of any routine biomarker in the diagnosis of pancreatic cancer. Atypical cases can occur and differentiation of malignant from benign pancreatic lesions can be challenging; in these cases, opinion from a radiologist with pancreato-biliary expertise should be sought.

461

ENDOSCOPIC HEMOSTASE OF BLEEDING ESOPHAGEAL AND GASTRIC VARICES

S. Zhigalova, A. Shertsingher, G. Manukyan, E. Fandeyev

Federal State Budgetary Scientific Institution B. V. Petrovskiy National Research Center of Surgery, Moscow, Russia

Relevance. Annually, the urgent surgery and portal hypertension unit performs up to 500 endoscopic interventions (420 ± 12 endoscopic band ligation (EBL) and 38 ± 7 sclerotherapy (ES)).

Aim. To estimate the possibilities of EBL and ES procedures for the management of patients with esophageal and gastric varices (GOV I and GOV II by the Sarin S.K. classification).

Materials and methods. The analysis of treatment of 440 patients with esophageal and gastric bleeding varices was provided (367 patients with liver cirrhosis and 7 patients with extrahepatic portal vein obstruction). EBL of the esophageal varices was performed in 114 patients, the ES undergone 196 patients: EBL of GOV I, II – 62 patients; ES of GOV I, II – 44 patients. The effectiveness of EBL and ES was analyzed separately for the esophageal and gastro-esophageal (type I, II) varices.

Results. EBL was more effective than ES during the long-term follow-up. That was shown for haemostatic effect in acute variceal bleeding and for the recurrence of varices: both for esophageal and gastroesophageal varices. In esophageal varices, the haemostatic effect was 93.8% for EBL and 62.7% for ES during the 36-month follow-up. The recurrence of esophageal varices was 20.9% for EBL vs 70.2% for ES. The same result was shown for gastro-esophageal varices: haemostatic effect of 67.3% and 34.4% for EBL and ES, respectively; the recurrence of varices occurred in 42.3% (EBL) and in 70.0% (ES). Nevertheless, ES was more effective than EBL in acute variceal bleeding from esophageal and gastroesophageal varices. The effectiveness of ES was 72.2% in acute esophageal bleeding, compared with 29.4% for EBL. For bleeding gastric varices, ES was effective in 71.7% while EBL was impossible. The use of balloon tamponade in acute variceal bleeding improved the subsequent EBL and ES effectiveness and increased the stability of the haemostatic effect of these interventions. In ES, the increase from 58.3% to 72.1% was shown for esophageal varices, and from 30.0% to 77.8% for gastric varices. In EBL, the increase from 60.0% to 91.7% was demonstrated for esophageal varices, and from 0% to 92.9% for gastric varices. The complications analysis has shown that the overwhelming majority of the complications occurred in GOV II varices: both for EBL and ES. After the ES procedure, the complications occurred in 61.1% for GOV II and in 26.9% for GOV I ($p < 0.05$). After the EBL procedure the complications rate was 50% and 0% for GOV II and GOV I, respectively ($p < 0.05$).

Conclusion. The choice of management strategy in patients with bleeding esophageal and / or gastric varices should be carried out with regard to the topography and extension of varices. EBL has shown better results in the direct haemostatic effect and the recurrence of varices during the long-term follow-up. However, the feasibility of EBL was inferior to ES in case of acute variceal bleeding. Using the balloon tamponade in acute variceal bleeding can significantly improve the haemostatic effect for both techniques.

462

GIANT GASTRIC GIST OF INTRATHORACIC LOCATION THAT MIMICKING THE POSTERIOR MEDIASTINUM TUMOR

E. Zinchenko¹, V. Pischik^{1,2}

¹*Sokolov' Hospital No 122 of the Federal Medical and Biological Agency, St. Petersburg, Russia*

²*St. Petersburg State University, St. Petersburg, Russia*

Gastrointestinal stromal tumors (GIST) located in the mediastinum are very rare and often imitate the signs and symptoms of primary thoracic neoplasms. Most often, intrathoracic GIST are represented by the esophageal tumors. Only two cases of GIST from the stomach wall located in the posterior mediastinum are described previously (Machishi H. et al., 2002; Huijiao Chen et al., 2017). We present a case of successful surgical treatment of a patient with a giant gastric GIST prolapsing into the posterior mediastinum.

Clinical case. Male, 80 years old, with normosthenic constitution and comorbidity index (CCI) – 6, with no significant complaints on dysphagia. During X-ray examination a big mass in the left hemithorax was revealed. GI endoscopy showed no specific changes of the mucosa so the biopsy was inconclusive. The patient admitted to our clinic with a suspicion for pulmonary tumor in the left lower lobe. CT with intravenous and oral contrast was performed: a tumor in the area of this gastric-esophageal junction was revealed, which evenly accumulates a contrast substance given through the mouth, which flows around this tumor. Lateral left thoracotomy was done. The tumor without invasion into the surrounding tissues comes from the stomach, located in the posterior mediastinum in the form of a hernia; the upper edge of the mass is at the level of the lower pulmonary vein. The tumor was completely isolated and removed with the ultrasonic scalpel, the stomach defect was closed with the stapler, Belsey fundoplication was performed with the intraoperative endoscopic control. Histological examination: stomach tumor with a diameter of up to 11 cm, removed without damaging the pseudocapsule. In immunohistochemical study, the signs of GIST were detected: cells expressed Dog1, CD117, CD34 intensively. Postoperative period was uneventful, the patient was discharged at postoperative day 8. As the patient was identified as having a high risk the adjuvant targeted therapy was prescribed.

Conclusion. The presented clinical case shows the complexity of the differential diagnosis and unusual primary localization of GIST at the posterior mediastinum. The case was published to demonstrate the feasibility of surgery for the borderline sized tumor.

AUTHORS INDEX

A			
Aasawari Ambekar	S177	Aminova L.	S60, S61, S62
Abatov N.	S3, S187	Amiranashvili I.	S212
Abbassova E.	S11, S12	Amitabh Yadav	S204
Abbasy Mohamed	S56, S57	Amol Ingule	S177
Abdrashev Ye.	S17	Amorim Ricardo	S198
Abdulatipova Z.	S3, S13, S14, S96	Andoh D.	S45
Abgaryan M.	S203	Andrási L.	S164
Abha Nagral	S177	Andree E.	S5
Abhinav Humar	S72	Andreev A.	S45, S47
Ábrahám S.	S164	Andreev E.	S4
Abramov A.	S71	Andreytseva O.	S10
Abudeed Haytham	S93	Andrianov A.	S95
Abugaliev K.	S3	Andrienko I.	S15
Achaladze D.	S7	Angelo N.	S21, S22, S23
Achkasov E.	S201	Anghelici Gh.	S10, S11
Achmetshin R.	S156	Anipchenko A.	S8, S9
Adankwah E.	S45	Anipchenko S.	S9
Aditya Chowdary T.	S4	Ansari F.	S19
Afanasjeva E.	S152	Antinyan K.	S46
Agapov M.	S16, S62, S65 S134, S135	Antochi L.	S34
Agyemang D.	S45	Antonenko F.	S11, S12
Ahmetov A.	S131	Antupma Jain	S222
Ahmetzyanov F.	S51	Arabuli M.	S213
Ahrameev V.	S71	Arai Osamu	S182
Akaraviputh Thawatchai	S210	Apollonov A.	S47
Akhaladz D.	S5	Arablinskiy A.	S188
Akhaladze D.	S4	Arguchinskii I.	S132
Akhaladze G.	S71	Aralova M.	S67
Akhmetov A.	S5, S90	Artemiev A.	S205, S223, S224 S225, S226, S227
Akihiko Oshita	S149	Arun Malviye	S108
Akiko Watanabe	S120	Ashie Y.	S45
Akina Omura	S120	Assamidanov Y.	S187
Aksenova I.	S28	Assenov Assen	S167, S238
Aksenova T.	S85	Astakhov D.	S159, S160
Aktas Aydin	S72	Atanasov B.	S20
Al-Hazmi A.M.	S126	Atazan Judy Carissa M	S41
Al-Khyatt Waleed	S39, S40	Atroshchenko A.	S13, S14, S38, S96
Al-sayed abd-elsamee Mohamed	S56, S57	Avdeev A.	S160
Alborov A.	S115	Awapittaya Burin	S200
Aldo Jarimba	S141	Ayoup Eslam	S57
Alekseycev A.	S144	Azizov I.	S14
Alentev S.	S48	Azorliade R.	S45
Alentiev S.	S79, S114		
Alentyev S.	S79, S81, S115	B	
Aleshin D.	S55	Babajan A.A.	S54
Alexeyev V.	S153	Babak A.	S15
Ali M.	S194	Babenko E.	S46
Ali W.	S4	Babich A.	S110
Aliakbarian Mohsen	S182	Babkov O.	S142
Alibegov R.	S6, S7	Baburin K.	S15, S91, S92
Alikhanov R.	S7, S49, S53 S97, S123	Baconina I.	S208
Alimov V.	S60, S61, S62	Badyrov R.	S3
Alison P.	S23	Baichorov E.	S16
Allakhverdiev A.	S169	Baimakhanov A.	S17, S211
Allakhverdieva A.	S134	Baimakhanov B.	S87
Allakhverdyan A.	S8, S9	Baizhanov A.	S210
Allgöwer Chantal	S128	Bagatelia Z.	S188
Alsammahi A.A.	S126	Bagde Abhijet	S177
Amanova D.	S9, S14	Bahmetov T.	S172
		Balandina L.	S145
		Balalykin A.	S17, S18
		Balkar Pal Krishna	S108
		Baltazar Fátima	S198
		Bang Sup Shin	S127, S128
		Baranau Ya.	S173
		Baranov A.	S160
		Baranov G.	S172
		Barbado P.	S17, S18
		Barber P.	S22
		Barinov O.	S115, S116
		Bartlett A.	S21
		Baryshev A.	S130
		Basarab E.	S173
		Bashkov A.	S18
		Bassi Claudio	S159
		Baziyan-Kuhto N.	S30
		Baziyan-Kukhto N.	S29, S30
		Baychorov M.	S95
		Baydarova M.	S117, S217
		Bayramova T.	S121
		Bazikyan E.	S160
		Bazin I.	S164, S165
		Beburishvili A.	S151
		Bedin V.	S188
		Behera M.	S19
		Behram Sheikh	S108, S109
		Bekir Sabrie	S167, S238
		Belev N.	S19, S20
		Beliaev A.	S20, S21, S22, S23, S24
		Beliaev AM	S23
		Belik B.	S24, S25
		Belikova M.	S85
		Belousov A.	S25, S110, S153
		Belousova S.	S55
		Beltsevich D.	S52
		Benashvili L.	S212
		Benedetti Fabio	S76
		Berelavichus S.	S119
		Bergin C.	S21, S22, S23, S24
		Beslekoiev U.	S75
		Bespechniy M.	S57
		Besselink Marc	S159
		Bessonova Svetlana Alexandrovna	S180
		Bessonova E.	S207
		Bezaltinnih A.	S194
		Biktimirov R.	S26, S59, S102
		Biktimirov T.	S26, S134
		Billa Geeta	S177
		Bing Peng	S235
		Binogorov A.	S87
		Biryukov V.	S185
		Biscanin A.	S27
		Bitarov T.	S27, S189, S209, S215
		Blazevic N.	S27
		Boateng A.	S45
		Bobrakov M.	S28
		Bobrov N.	S237
		Bochkova A.	S28
		Boeva I.	S189, S194, S209, S215
		Bokarev M.	S29
		Bokova E.	S121
		Bondar L.	S97

ABSTRACTS

Bondarev V.	S93	Chkhikvadze V.	S71	Doshanov M.	S87
Booth M.	S20, S21, S22, S23	Cho Ei Rie	S129	Drobyazgo S.	S44
Borishva N.	S181	Cho Kyung-Ah	S181	Droc G.	S118
Borota A.	S29, S30	Choi Hwang	S84	Drozdov E.	S44
Borovik V.	S70	Choi Wonjae	S129	Duarte Marina	S141
Bosieva A.	S75	Choi Young Hoon	S127, S128, S181	Dudaev Z.	S165, S169
Botea F.	S118	Chormanov A.	S87	Dudenkova V.	S237
Bova F.	S31, S32	Chou Sai	S36	Dudina G.	S99
Boyarinov D.	S79	Chuang SC	S124	Duduyemi B.	S45, S233
Boyarinov V.	S155	Chukitu K.	S63	Duisebekov M.	S210, S211
Branco Cláudio	S197, S198	Chung Ik-Joo	S37, S82	Dunaev A.	S18
Braşoveanu V.	S118	Chunikhin A.	S160	Durleshter V.	S45, S46, S47, S57
Brehov E.	S223	Chzhao A.	S37, S58, S77	Dusek Tomas	S161
Breizat A. Al	S6		S117, S220	Dutta S.	S19
Brovkin O.	S233	Cicek Egemen	S72	Duvansky V.	S203
Bruns Doris-Henne	S128	Civil I.	S22	Dymkov I.	S166
Brytska N.	S132, S133	Confalonieri Dorotea	S76	Dymova Olga	S84, S131
Bugaev S.	S114	Crudu O.	S10, S11	Dynko V.	S57
Bugaev V.	S32	Cvetkov D.	S20	Dyuzheva T.	S66
Bukarev A.	S133			Dzhagraev K.	S155
Bulganina I.	S189	D		Dzidzava I.	S47, S48, S113
Bulynin D.	S178				S114, S115, S116
Bulynin V.	S178	Dadayan A.	S25	Dzhanbekov T.	S66
Bunchaliew Chairat	S176	Dalgatov K.	S186	Dzyadzko A.	S192
Burdyukov M.	S33	Danichenko M.	S38		
Burikov M.	S33	Danci Alexandr	S231	E	
Burmatova T.	S17	Danilov A.	S195		
Burmistrov D.S.	S54	Danilov M.	S13, S14, S38, S96	Efanov M.	S7, S49, S53
Burgutov M.	S189	Danu M.	S11		S97, S123, S143
Busch Olivier	S159	Das Subhashish	S204	Efanov S.	S24
Busirev Yu.	S60, S61, S65	Davtyan A.	S161	Efimov D.	S192
Busyrev Yu.	S62	Davydenko M.	S130, S207	Eftimie M.	S118
Butturini Giovanni	S159	Davydov M.	S169	Egorov V.	S49, S50, S51, S52
Buzadzhi D.	S135	De Pastena Matteo	S159	Egorova D.	S55
Bykov A.	S151	De Rosa Antonella	S39, S40	Eldesoky M.	S194
Bysirev Yu.	S135	Deeprasertvit A.	S42	Eliseev A.	S79
Bystrova T.	S185	Degtarev D.	S85	Elizarova N.	S49, S53
		Degtyareva N.	S149	Elshoubary M.	S194
C		Delfrate Nicholas Walter	S76	Enin E.	S87
		Delibashvili D.	S212	Ergenç Muhammer	S54
Cai Xiujun	S34	Delos Santos-Belen	S41	Erin S.	S60, S63
Cai Yunqiang	S235	Demini DB	S41	Ertugrul Ismail	S98
Carcano Giulio	S76	Demko A.	S142, S200	Esposito Alessandro	S159
Cernat M.	S34	Deshmukh Sharad	S177	Essenbaeva G.	S187
Chang Zhengyao	S36	Detochkin A.	S42		
Chaplygin S.	S160	Dhodi Deepti	S109	F	
Chaudhary Anuradha	S109	Di Carlo Isidoro	S43		
Chavkin P.	S145	Diakonova E.	S217	Fadeeva N.	S99
Chechetka D.	S44	Dibina T.	S44	Fahmy Karim	S207
Cheklecova E.	S66	Dibirov M.	S63	Fainshteinm I.	S112
Chen Chiung-Nien	S34	Dimova O.V.	S54	Falcão Joaquim	S196, S197, S198, S199
Chen Jiang	S34	Dionysio Lucas Monteiro	S153, S154	Fandeyev E.	S99, S136, S239
Chen JS	S124	Djarov G.	S19, S20	Fathy O.	S194
Chen Po-Da	S34, S35, S129, S130	Dmitrieva K.	S51	Fedaruk A.	S192
Cherkasov D.	S35	Dmitrochenko I.	S115, S116	Fedaruk D.	S192
Cherkasov M.	S35, S104, S105	Dobrovolskaya N.	S111	Fedun O.	S47, S48, S115
Chernaya N.	S49	Doklestić Krstina	S43	Ferreira Luis	S141
Chernichenko I.	S36	Dolgopyatov I.	S96	Ferri Enrico	S76
Chichkanova A.	S236, S237	Domenico Iovino	S76	Filenko B.	S238
Chikara Ogawa	S120	Domozhirova A.	S28	Filin A.	S144
Chinswangwatanakul Vitoon	S210	Donichenko M.	S233	Filin A.V.	S54
Chirkinyan G.	S24, S25	Donova L.	S156	Fomenko O.	S55
Chisa Aoyama	S150	Dorosulic Z.	S27	Fomenko Y.	S55

Frolov R.	S178	Grin A.	S160	J	
Fufaev E.	S115, S116	Grinberg L.	S78		
Funygin MS	S41	Grintsov A.	S71	Jaganmohan Reddy B.	S4
Furukawa Katsunori	S147, S235	Gubarev K.	S205, S223, S224, S225	Jeen Yoon Tae	S129
Fuyuhiko Motoi	S13	Gubkov I.	S195	Jekarl Dong-Wook	S127
G		Guchetl A.	S57	Jeong Young-Hoon	S82
		Gugnin A.	S188	Ji Jeong-Seon	S84, S127
Gabriel S.	S57	Guliaev V.	S156	Ji Tong	S34
Gad Emad Hamdy	S56, S57	Gulidov I.	S181	Ji Yoon Kim	S129
Gadlevskiy G.	S135	Gunay Yusuf	S72	Jiramarit W.	S42
Gafarova R.	S58	Gundogan Ersin	S72	Jirasiritham Jakrapan	S37
Galashokyan K.	S35	Guodong Zhao	S36	Jiro Kimura	S120
Galchina Y.	S58, S220	Gupta Bramhanand	S107, S108, S109	Jitpanu Wongyongsil	S84
Galimov R.	S87	Gutu Evghenii	S231	Joo Young-Eun	S37, S82
Galjan T.N.	S54	Gunyat R.	S115	Juchkova U.	S208
Galkin G.	S112	Gvozdik V.	S17	Jumataev D.	S17
Galkin I.	S175	Gweon Tae-Geun	S84	Juravel S.	S156
Galliamov E.	S59, S60, S61, S62, S63 S64, S65, S101, S134, S135	H		K	
Gallyamov E.	S59, S64, S65, S66 S101, S102	Han Sang-UK	S72	Kaabak Michael	S84
Galperin E.	S66	Hani Yusef	S167, S238	Kabanov M.	S85
Garina A.	S61	Hardy Y.	S233	Kagawa Shingo	S147, S235
Gautier S.	S66	Hayashi Hiroki	S13	Kagramanova A.	S99
Gehlot Singh Puspendra	S107, S108 S109	Hou Yu-Chen	S129	Kalashnik R.	S85
Gerashchenko Y.	S36	Hrabar D.	S27	Kalashnikova I.	S55
Giardino Alessandro	S159	Hrehoreţ D.	S118	Kaldarov A.	S119
Giparovich M.	S94	Huang Chiun-Sheng	S34	Kaliev D.	S93
Givotov V.	S214	Huang JW	S124	Kalinin D.	S52, S88
Gheorghe C.	S118	Huang Kai-Wen	S73	Kalinnikov V.	S223
Ghidirim Gheorghe	S231	Humberto Cristino	S196	Kamalov Y. R.	S54
Glück Philipp	S128	Hur Hoon	S72	Kambara Yuichi	S86
Gluhov E.	S165	Huseynov Amil	S74	Kamel Yasmin	S56, S57
Glukhov E.	S169	Hutiev C.	S75	Kan P.	S87
Glukhov A.	S67	Hutiev S.	S75	Kaniev S.	S87
Gluzman M.I.	S67	Hutieva N.	S75	Kanji Miyata	S86, S147, S154
Gogichashvili V.	S29	Hyun Shin Sang	S125	Kanzaki Masaki	S120
Gokler Cihan	S72	I		Kaoru Nagahori	S156
Golderova A.	S222	Iakova M.	S207	Kaoru Ogawa	S156
Gololobov G.	S59, S61, S101	letto Giuseppe	S76	Kapoor V K	S176
Golubenko E.	S62	Igamova S.	S189	Karaman S.	S221
Gonzalez Ayrton John Macedo	S153, S154	Il Jang Won	S96	Karagul Servet	S98
Goncharov S.	S71	Iliyasova B.	S87	Kaprin A.	S181
Gorbacova I.	S65	Ilynskaya O.	S146	Kaputovskij A.	S26
Gordiichuk M.	S68	Ionescu M.	S118	Karelskaya N.	S58, S77, S220
Gordiichuk P.	S68	Ionkin D.	S37, S38, S58 S77, S220	Karasev I.	S221
Gorgun A.	S87	Ioshiaki Yogi	S153, S154	Karayan A.	S98
Gorin D.	S119	Isakova M.	S33	Karmazanovsk G.	S220
Gorochov G.	S236	Iskhagi S.	S7	Karmazanovsk G.	S58, S88
Goulart André	S199	Ivanov N.	S5	Karpova R.	S91
Grachev N.	S4, S5	Ivanov P.	S202	Kaschenko V.	S131
Grancharova Silvia	S167, S238	Ivanov S.	S181	Kashchenko V.A.	S67
Granov D.	S69, S70, S114, S148	Ivanova N.	S4	Kashchenko V.	S5, S88, S89, S90
Grasu M.	S118	Ivachyov P.	S9	Kashkin D.	S114
Grebeniuk D.	S168	Ivanov Yu.	S159, S160	Kasumyan S.	S7
Grebtsov Y.	S70	Ivantsova M.	S78	Kato Manako	S120
Grebyonkin E.	S71	Ivanusa S.	S79, S80, S81, S115	Katsin M.	S192
Grekov D.	S188	Izrailov R.	S95, S153	Katsuhiko Uesaka	S157, S204
Grendal K.	S49			Kawai Naoyuki	S150
Greyasov V.	S16			Kayaalp Cuneyt	S72, S91, S98, S205
Grigorievsky M.	S50, S52			Kazakov I.	S7, S49, S53, S123
				Kazakova D.	S91
				Kazennov V.	S91

ABSTRACTS

Kazenov V.	S92	Kontzoglou Konstantinos	S103	Kudryavtsev P.	S160
Kchibekov E.	S42, S93	Kopeykin A.	S208	Kudryavtseva A.	S48
Kedrova A.	S159	Kornmann Marko	S128	Kuhto A.	S30
Khadzhieva E.	S36	Korobka R.	S104, S106	Kukeev I.	S10
Khalikov A.	S94	Korobka V.	S104, S105, S106	Kukhta A.	S169, S170
Khan Raheela	S39, S40	Korolev P.	S106	Kukhto A.	S29, S30
Khan Sh. L	S126	Koroleva A.	S49	Kulesneva J.	S157
Khan Shandana L	S93	Korolkov A.	S107	Kulezneva J.	S122, S143
Khanevich M.	S94	Korotkov S.	S192	Kulezneva Y.	S123
Khatkov I.	S13, S95, S96, S123	Korpraphong Pornpim	S210	Kulikov V.	S122
Khazov A.	S94	Korrel Maarten	S159	Kulikova N.	S123
Khetsuriani R.	S213	Korzeva I.	S188	Kumar Sepuri S.	S4
Khizroev K.	S66	Kosakevich E.	S99	Kumar Shaleen	S176
Khmylov L.M	S177	Koschel K.	S68	Kuo Kung-Kai	S124
Khokhlov A.	S80	Koshariya Mahim	S107, S108, S109	Kuo Ting-Chun	S129
Khrenova I.	S132, S133	Koshel A.	S44	Kurakevich I.	S115
Khrykov G.	S94	Koshelev D.	S186	Kurkov A.	S195
Khubezov D.	S185	Koshkin M.	S110	Kurskov A.	S186
Khubutiya M.	S156	Kosivtsov O.	S170	Kurushikina N.	S195
Kim E.	S144	Kosmacheva H.	S110	Kutay Saglam	S72
Kim Hyun-Soo	S82	Kostadinov R.	S207	Kutseva T.	S125
Kim E.F.	S54	Kostakis Ioannis D	S103	Kuzmichev D.	S136
Kim Edward	S84	Kostirev S.	S214	Kuzmicheva D.	S186
Kim Kyubo	S96	Kostyrykin M.	S104, S105	Kuzmina T.	S111
Kim Song Cheol	S125	Kostyuchenko L.	S111	Kuznetsov Y.	S47
Kim P.	S7, S49, S53	Kosyura S.	S111	Kuznetsova D.	S237
	S97, S123	Kotayev A.	S153	Kwon Ki Hwan	S129
Kim Taehyun	S129	Kotelnikov A.	S112, S113	Kwon Jaewoo	S125
Kim Yong-Tae	S127, S128, S181	Kotkov P.	S238	Kyohei Ariake	S13
Kim Yu-Hee	S181	Kotiv A.	S113	Kyoko Ando	S150
Kinyakin A.	S33	Kotiv B.	S47, S48, S114		
Kiprof K.	S87		S115, S116		
Kirakosyan V.	S161	Kouraklis Gregory	S103	L	
Kirillin A.	S62	Kovacevic M.	S218	Lakashia I.	S152
Kirichenko I.	S98	Koval V.	S168	Lalwani Shailendra	S183, S204
Kirmizi Serdar	S98	Kovalenko A.	S64	Landoni Luca	S159
Kirsanov A.	S176	Kovalenko Yu.	S116	Lashchik M.	S228, S229
Kirsanov I.	S232	Kovalev D.	S133	Latif Khan A.	S93, S126
Kirtanasov Y.	S45	Kovalevskii A.	S117	Lavrinenko A.	S9, S14
Kiselev N.	S121, S237	Kozlov I.	S117	Lavrov S.	S122
Kislitsin D.	S87	Kozlov M.	S118	Lázár G.	S164
Kit O.	S32	Kozlov V.	S55	Lazutkin M.	S79, S81, S115
Kita Hideyuki	S150	Kozlov Valentin Alexandrovich	S180	Le Trung Hieu	S126
Kitaev M.	S107	Kozobin A.	S196	Leão Pedro	S199
Kitsenko E.	S99, S136	Kraft A.	S118	Lebedev D.	S159
Kitzig Elle	S128	Krastev P.	S20	Lebezev V.	S99, S136
Klimov D.	S160	Kretz Anna-Laura	S128	Lee Beom Jae	S129
Knippschild Uwe	S128	Kriazhov V.	S146	Lee Jae Hoon	S125
Knyazev O.	S3, S99	Kruger A.	S112, S119	Lee Jae Woo	S128
Knyazev V.	S100	Krivosnogova T.	S170	Lee Jeong Rok	S84
Kochkin A.	S26, S64, S101, S102	Kruglov A.	S111	Lee Ji Ae	S129
Kochmashev I.	S102, S103	Kryanev A.	S11, S12	Lee KT	S124
Koh Yang-Seok	S162	Kryazhev D.	S29	Lee Po-Chu	S129
Kokosadze N.	S32	Krylov V.	S160	Lee Sang Hyub	S127, S128, S181
Kolarov Hr.	S19	Khytruk S.	S168	Lee Seung-Woo	S84
Kolesnikov R.	S71	Kryukova E.	S60	Lee Seungok	S127
Kolesnikov V.	S174, S175, S176	Kubo Atsushi	S120, S150	Lee Young-Joo	S125
Kolmachevsky K.	S87	Kuboki Satoshi	S147, S235	Lei Cing-Syuan	S129
Kolsanov A.	S160	Kubota Tadao	S120	Lemke J.	S128
Kolyshev I.	S223, S224	Kucheryavy A.	S230	Lemke Johannes	S128
	S225, S227	Kuchin D.	S121	Levanchuk A.	S168
Komorowski Andrzej Lech	S139	Kudashkin N.	S113, S165	Levchenko O.	S160
Kondo Hidetoshi	S150	Kudryavitsky Y.	S121	Levin L.	S174

Lewis C.	S23	Marikian A.	S169, S170	Miyazaki Masaru	S147, S235
Lezhneva E.	S185	Marino Marco Vito	S138, S139	Mizin A.	S87
Liakhovchenko N.	S168	Markarov A.	S29, S136, S139	Mizokami Ken	S120
Lida Jarahi	S182	Markov P.	S140	Mizuno Hironori	S147
Lim Yun Jeong	S129	Marshall R.	S22	Mochurova Maya	S167, S238
Lin Chih Hao	S130	Martínez Angel Flores-Huidobro	S140	Mohit Jain	S107, S108
Lin Hui	S34	Martins Sandra	S199	Moiseenko A.	S148
Lin Ming-Tsan	S34, S35, S129, S130	Martins Sandra Fernandes	S198	Moiseenko V.	S148
Linda Book	S140	Martins Sónia Fortuna	S141	Molchanov A.	S115
Lischenko A.	S130	Martynova G.	S142, S200	Molnár T.	S164
Lishchinskaya A.	S99	Martov A.	S26	Molokhoev E.	S161
Lishova E.	S131	Masahiro Morita	S120	Monahov A.	S61
Liu Rong	S208	Masamichi Mizuma	S13	Monakhov A.	S66
Livantsova E.	S111	Masashi Ishikawa	S77	Monier A.	S194
Lobakov A.	S149, S203	Masataka Okuno	S86	Moon Kyung Joo	S129
Lončar Zlatibor	S43	Masatoshi Mogaki	S156	Morokhotov V.	S203
Lodygin A.	S5, S90, S131	Maslov A.	S24	Morozov S.	S149
Lokhmatov M.	S217	Masui Hidenobu	S156	Mozhaeva E.	S15
Longatto-Filho Adhemar	S198	Matoshvili M.	S211, S212, S213	Mrugova T.	S131
Lopes Maria	S141	Matsugu Yasuhiro	S149	Mujkanovic Jasminka	S179
Lorenzo Latham	S76	Matsuyama Kazuo	S77	Muntyanu E.	S29
Lozhkin M.	S106	Matveev N.	S160	Murashkin N.	S217
Lubchenko L.	S32	Mavidi I.	S195	Muratovic Osman	S179
Lubianskii V.	S132	Mayorova E.	S143	Muravlyova L.	S55
Lugovoy A.	S70	Maystrenko D.	S70	Musatov A.	S143
Lukanova Ts.	S207	Maystrenko N.	S94	Musin R.	S136, S137, S138, S139
Lukianiuk P.	S200	McWilliams T.	S23	Mutsurov H.	S17
Lukyanchenko I.	S118, S132, S133	Medeubekov U.	S87	Muzharovskiy A.	S79, S81
Lulu Zhang	S239	Mehmedovic Zlatan	S40	Muzharovsky A.	S79, S114
Lupescu I.	S118	Mehrotra Siddharth	S204	Myrzin A.	S60
Lupu G.	S10, S11	Mehta Naimish	S183, S204	Myrzina A.	S61, S62
Lutsevich O.	S62, S65, S134, S135	Mekhdiev E.	S65		
Lutsyk K.	S156	Melekhina O.	S122, S123, S143	N	
Lychkova A.	S111	Melnik N.	S118		
Lyutov A.	S118, S132, S133	Melnychuk M.	S168	Nabieh Elghawalby A.	S194
		Mendoza Miguel C	S41	Nada Ali	S56, S57
M		Merencev S.	S68	Nadeen Babenko	S84
		Merkulov N.	S4, S5	Nagai Hidemasa	S86, S147, S154
Madhusudhan Ch.	S4	Mersaidova K.	S144	Naidenov E.	S18
Madyarov J.	S136	Meshechkin A.	S166	Nakagawa Kei	S13
Magomedov K.	S156	Metelin A.	S144	Namba Maiko	S149
Magomedov M.	S112, S164, S165	Metelin A.V.	S54	Namba Yosuke	S149
Mahgoob Nashwan Qahtan	S151	Meyers Rebecka	S140	Naoyuki Kawai	S90
Makhmudov Z.	S189	Midlenko V.	S145	Narimanov M.	S164, S165
Maksimov A.	S32	Mihaylov V.	S207	Natroshev I.	S151
Maksimova S.	S217	Mikhin I.	S151, S170	Navoian O.	S181
Malihova O.	S33	Mikhaylikov T.	S64	Naydenov E.	S223, S224, S225 S226, S227, S228, S229
Malikhova O.	S221	Mikhnevich M.	S95	Nechai I.	S152
Melikova S.	S35	Minaev I.	S169, S170	Nechipay A.	S33
Maltseva A.	S223, S224, S225	Mingzhe Cai	S146	Nechunaev A.	S160
Maltzev N.	S152	Minou A.	S192	Nechunayev A.	S159
Mamedli Z.	S136	Mironova I.	S223	Nedoluzhko I.	S195
Mamikin A.	S29	Mirza Darius	S177	Nesterov N.	S71
Mamishhev A.	S57	Mishin I.	S34	Nessi Chiara	S159
Manaev A.	S44	Mishin Igor	S231	Nigmatov M.	S25, S153
Manikandan	S123	Mishina Anna	S231	Nikoda V.	S131, S209
Mansurov J.	S102, S103	Mitrakov A.	S146	Nikolaev A.	S153
Mansurov Yu.	S172	Mitsinskaya A.	S5	Nikolic M.	S27
Manukyan G.	S99, S136, S137 S138, S239	Mitsinskii I.M.	S5	Nikolsky I.	S153
		Mittal K.	S19	Nikulin M.	S32, S203, S234
Manukyan V G.	S139	Mitsushige Shibatoge	S120, S150	Nilton Felix Valter	S153, S154
Marahotov V.	S149	Miyake Hideo	S86, S147, S154	Nishida Kazuhiro	S120
Mareev D.	S24, S25	Miyahara Yoji	S147		

ABSTRACTS

Nishisaka Takashi	S149	Pankiv K.	S168	Polynovskiy A.	S136
Nishnevich E.	S144, S209	Pankov A.	S161	Pongpaibul Ananya	S210
Nojima Hiroyuki	S147	Paral Jiri	S161	Popescu I.	S118
Nojiri Kazunori	S156	Parayno Krista Angeli	S41	Popov A.	S130
Nogueira Fernanda	S199	Parfenov A.	S99	Popov D.	S107
Nonni Afrodite	S103	Parfenov Igor' Pavlovich	S188	Popov M.	S18
Norihiro Yuasa	S86, S147, S154	Parise Cristiano	S76	Popov S.	S102, S148
Noritaka Nakamura	S150	Parihar Manish	S108	Popov Sh.	S20
Noskova K.	S99	Parmar Tushar	S177	Poprom Napaphat	S37
Novikov S.	S155	Pak E.	S104, S105	Porhanov V.	S130
Novikov V.	S155	Park Eun-Kyu	S162	Porshennikov I.	S171
Novruzbekov M.	S156	Park Jin-Woo	S162	Pozdnyakov S.	S13, S14, S38, S96
Nuengruetai Orannapalai	S176	Park Jong-Jae	S129	Prashanth K.	S4
Nundy Samiran	S204	Park Joo-Won	S181	Prakash Jai	S108
Nurlanbayev E.	S87	Parkhisenko Y.	S85	Prasunna M.	S4
Nurzhankyzy G.	S17	Parkhisenko Yu.	S178	Pratap Reddy R.	S4
		Parkhomenko R.	S11, S12	Prazdnikov E.	S172, S214
O		Pasechnik I.	S163	Presnov K.	S60, S65
O'Carroll M.	S23	Pašić F	S158	Prikhno N.	S172
Odisseeva E.	S207	Paszt A.	S164	Prohorenko K.	S64
Ogay V.	S3	Patsouris Efstratios	S103	Prohorov A.	S214
Ogneva A.	S157	Patrushev I.	S122	Prokhorenko T.	S6, S7
Ohgi Katsuhisa	S204	Patyutko Y.	S112, S113	Proskuryakov I.	S112, S113
Ohtsuka Hideo	S13	Patyutko Yu.	S164, S165	Prudkov M.	S15, S102, S103
Ohtsuka Masayuki	S147, S235	Pavic I.	S27		S144, S151, S172
Okhotina G.	S132	Pavlov P.	S87	Prusova A.	S131
Okamura Yukiyasu	S157, S204	Pavlovskij A.	S148	Puchinskaya M.	S173, S174
Okonskaya D.	S158	Pegov R.	S146	Puneet Dhar	S123
Oldakovskii V.	S217	Penev Lubomir	S167, S238	Pushkar Yu.	S47
Oleshkevich D.	S66	Penkov R.	S19, S20	Pyatakov S.	S118, S132, S133
Olisov O.	S156	Pereira Joaquim Costa	S199	Pykhteev V.	S47
Ömer Günal	S54	Pereira Ricardo	S196		
Omerovic M.	S218	Perfilyev I.	S121	R	
Omerović M	S158	Perlin D.	S166	Rabae G.	S5
Onishi Hiroaki	S150	Petershie B.	S45	Rabaev G.	S4
Onnicev I.	S79, S80	Petkov Christian	S167, S238	Rachmaev T.	S208
Onnitsev I.	S114	Petleshkov I.	S19, S20	Radoga Ia.	S168
Onnyceev I.	S79, S81	Petrosyan T.	S194, S215	Raevskaya M.	S231
Orazaliev G.	S17	Petrov A.	S114	Ragimov V.	S71
Orelkin V.	S145	Petrov E.	S217	Raimkhanov A.	S17
Örhalmi Julius	S161	Petrov L.	S181, S214	Rai A.	S109
Orjonikidze Z.	S211, S213	Petrov R.	S49, S50, S51, S52	Rajan Saxena	S176
Orlov I.	S26	Petrov S.	S195, S196	Rakhimov B.	S174, S175, S176
Orlova R.V.	S67	Petrovskiy A.	S130	Ramazan Eryilmaz	S74
Orlova Yu.	S3	Petrushenko V.	S168	Rameshwar More	S108
Osipov A.	S200	Petsuksiri Janjira	S210	Rapheephat Tanompetsanga	S176
Osipov V.	S233	Pirogov S.	S121	Raskovalov D.	S15
Oskanian M.	S24, S25	Pisarenco S.	S10, S11	Rastogi Neeraj	S176
Ostrovskaya A.	S172	Pischik V.	S240	Rasulov A.	S136
Ottlakán A.	S164	Pletner P.	S201	Rathore Ashay	S108
		Podluzhny D.	S112, S169	Ratnikova N.	S52
Q		Podluzhnyiy D.	S164, S165	Raut Vikram	S177
Quang Vu Van	S126	Podluzhnyj D.	S113	Raveglia Veronica	S76
		Podluznj D.	S165	Ravi Mohan T.	S4
P		Poduraev Yu.	S160	Ravich L.D.	S177
Peganova J.	S166	Pokshubinam A.	S134	Rawisak Chanwat	S84, S176
Pan Teresa Lucia	S159	Podolskiy E.	S169, S170	Ray Samrat	S204
Panchenkov D.	S159, S160, S217	Pokataev I.	S164, S165	Rayhan All	S178
Panchwagh Amaya	S177	Polehin A.	S69	Reddy D.	S23
Panici I.	S10	Polikarpov A.	S69, S70, S114, S148	Regentova O.	S12
		Poljakov A.	S165	Reznichenko A.	S179
		Poluektov Y.	S91	Riabov M.	S203
		Polyakov A.	S164, S165, S170		

Ribas Sónia	S199	Sarmanov N.	S210	Shestakov A.	S189, S194, S209, S215
Rifatbegović Z.	S158, S218	Sasaki Eiji	S185	Shestakov A.	S27
Rifatbegović Zijah	S179	Sasaki Keiko	S157	Shestopalova A.	S71
Risman B.	S81	Sato Yutaka	S235	Shevchenko T.	S117
Rodimov S.V	S179	Sauchenka A.	S192	Shevtsov S.	S114
Rodriguez-Davalos Manuel I.	S140	Savkin I.	S185	Shi Jiang	S34
Rogal M.	S155, S202	Sawant Amreen	S177	Shigetsugu Takano	S147, S235
	S216, S232	Sazonenkov M.	S122	Shin Ho-Jung	S72
Rojnoveanu Gheorghe	S231	Scaife Eric	S140	Shingo Sasamatsu	S120
Roman V.	S10, S11	Scherbenko O.	S11, S12	Shirakabe Katsudai	S120
Romashchenko P.	S94	Seisenbayev M.	S87	Shiro Fujita	S140
Rong Liu	S36	Selivanova I.	S27, S215	Shishin K	S195
Rovenskih D.	S220	Seliverstov D.	S185	Shkurin D.	S169, S170
Rowbotham D.	S21	Semash K.	S66	Shota Fukai	S120
Ruchkin D.	S158, S231, S232	Semenov N.	S186	Shpak E.	S17
Rudakov V.	S205, S223, S224	Semenova E.	S132	Shukakidze A.	S213
	S225, S226	Sementsov K.	S85	Shulgin O.	S33
Ruchkin Dmitry Valerievich	S180	Semenyakin I.	S63	Shulutko A.	S151
Rukhadze G.	S181	Semigolovski N.	S186	Shumkina L.	S195
Rummo O.	S192	Semigolovski S.	S186	Shumov K.	S98
Rusev P.	S20	Seregin A.	S236, S237	Shuplak S.	S47
Rutenburg G.	S196	Serdyukov M.	S93	Shusei Sano	S204
Ruzmatov P.	S184	Sergeev V.	S59, S64, S101	Shushanova A.	S55
Ruzibaev R.	S184	Serikuly E.	S87	Shutov V.	S169, S170
Ryabov K.	S121	Sergeev O.	S6, S7	Sidorov D.	S106
Ryaskov L.	S170	Seroshtanov V.	S132	Siddharth Mehrotra	S183
Rykov O.	S27, S215	Seto Yasuyuki	S187	Sigua B.	S195, S196, S238
Ryo Ashida	S157, S204	Sevastyanov L.	S187	Silantieva N.	S181
Ryu Ji Kon	S127, S128, S181	Sevryukov F.	S101	Silva Gabriel Previero Elias	S153, S154
Ryu Kyung-Ha	S181	Shabalin M.	S18, S223, S224	Silva Mateus Felipe Belo	S153, S154
Rzaeva A.	S48		S225, S226, S227	Silva Patrícia Araújo	S196, S197
		Shabat Galyna	S138		S198, S199
S		Shablovsky O.	S159	Sim Yu Ra	S129
Saakjan G.	S13, S14, S96	Shabunin A.	S188	Simonka Z.	S164
Saakyan G.	S38	Shahri Sara Saeidi	S182	Sintra Paulo	S141
Sadykov N.	S17, S210, S211	Shakbanov M.	S27	Siribumrungwong Boonying	S37
Safonov A.	S18	Shakhbanov M.	S189	Siripong Sirikurnpiboon	S200
Safronova V.	S32	Shaligin A.	S65	Sirota V.	S55
Sagaydak I.	S164, S165	Shamsiev A.	S189	Sisova A.	S214
Sahel S.	S126	Shamsiev J.	S189	Sivokon N.	S16
Said R.	S194	Shamsutdinov S.	S145	Sivolodsky E.	S47
Sakata Koichiro	S182	Shanaev I.	S190, S191	Sizonenko N.	S142, S200
Sakhno D.	S195	Shapiro Ron	S84	Sizov V.	S231
Salah T.	S194	Shapoval'yants S.	S151	Skakbayev A.	S87
Salam Daradkeh	S39	Shapovalov A.	S104, S106	Skazkin I.	S33
Salam Varun	S107, S108	Sharipov A.	S172	Skers S.	S173
Salemianov A.	S209	Sharma Agamy	S109	Slobina E.	S11, S12
Salienko A.	S156	Sharma Anurag	S108	Slobodyanik A.	S47, S48, S114
Salvatore Paiella	S159	Sharon Alex	S107, S109	Slugarev V.	S146
Salvia Roberto	S159	Shatveryan D.	S189	Smagulov A.	S17
Samir Delibegović	S40	Shcherba A.	S192	Smanev A.	S166
Samiran Nundy	S183	Shcherbin V.	S223, S224	Smorodsky A.	S47, S48, S113
Samrat Ray	S183		S225, S226		S114, S115
Samkharadze B.	S212	Shefer A.	S66	Sobolev Yu.A.	S41
Sander Silvia	S128	Shehta A.	S194	Sokolov A.	S80
Sandratskaya A.	S155	Sheikh Zh.	S18	Sokoolov P.	S181
Sanin D.	S181	Shelesko A.	S161	Soldatov S.	S47, S48, S114
Sansal Mufit	S72	Shelygin Y.	S55	Soldini Gabriele	S76
Santosh Sanagapalli	S239	Sheptunov Yu.	S193	Soliman Mohamed soliman	S207
Sanzharov A.	S59, S64, S101, S102	Shershen D.	S79	Solodov Yu.Yu	S41
Sapaev D.	S184	Sherstobitov V.	S102, S103	Solomka A.	S201
Saredi Giovanni	S76	Shertsingher A.	S239	Solonitsyn E.	S88, S89
		Sherzinger A.	S137	Soloviev I.	S85, S142, S200

Vozian Marin	S231	Yaprak Muhittin	S74	Zakaria Hazem	S56
Vnukov P.	S193	Yartsev P.	S155, S202, S216, S232	Zakaryan N.	S161
W					
Wahab M. Abdel	S194	Yastrebova E.	S113	Zakharov E.	S195
Wang Bo	S72	Yasyuchenya D.	S115, S116	Zamanov E.	S49
Wang SN	S124	Yawale Vijay	S177	Zani Elia	S76
Wang Fei	S208	Yeh Sung-Ling	S129	Zarkov Kostadin	S167, S238
Weledji Elroy Patrick	S231	Yokoi Yasuyo	S150	Zaykova M.	S28
Wilasrusmee Chumpon	S37	Yoo Hye-Jin	S127	Zelinskaya N.	S11, S12
Wongeeun Jung	S96	Yoshikawa Kentaro	S120	Zelter P.	S160
Woo So-Youn	S181	Yoshioka Yuichiro	S86, S147, S154	Zemlyanoy V.	S238
Woo Hyun Paik	S127, S128, S181	Yoshitomi Hideyuki	S147, S235	Zendejas Ivan	S140
Wook Hwang Dae	S125	You Min Su	S127, S128, S181	Zenin V.	S153
Wu Chao-Ying	S35	Yifieyeh A.	S45	Zhabina R.	S166
Wu Di	S34	Yifieyeh A.C.	S233	Zhantay A.	S210, S211
Wu Jin Ming	S130	Yudin V.	S185, S233	Zhao A.	S88, S116
Wu Yao-Ming	S35	Yugay V.	S234	Zharikov Yu.	S116
Y					
Yadav Amitabh	S183	Yurasov A.	S27, S194	Zhavoronkova O.	S77
Yakovleva D.	S85	Yurichev I.	S33	Zhelezinskaia V.	S173
Yakovleva E.	S155	Yuryev E.	S94	Zheludkova O.	S11, S12
Yakubov F.	S184	Yusuke Iwano	S236	Zhigalova S.	S139, S239
Yakyarova S.	S210, S211	Z			
Yamamoto Yusuke	S157, S204	Zabelin M.	S228, S229	Zhurina Ju.	S52
Yan M.	S231, S232	Zabezhinsky D.	S223, S224, S225	Zhvitiashvili I.	S6, S7
Yanishevskiy A.	S81	Zdasiuk S.	S226, S227	Zinchenko E.	S240
Yankovsky A.	S79, S80	Zagainov E.	S236, S237	Zinovsky M.	S160
Yanushevich O.	S160	Zagainov V.	S121, S236, S237	Zipunnikov V.	S166
Z					
Zhangxuan	S208	Zagaynov E.	S61, S66	Zivkovic M.	S27
Z					
Zakaria Hazem	S56	Zagaynova E.	S237	Zlobin A.	S159, S160
Zakaryan N.	S161	Zagaynova E.	S237	Zokoyev Allan	S84
Zakharov E.	S195	Zhangxuan	S208	Zubarev P.	S81
Zamanov E.	S49	Z			
Zani Elia	S76	Zhurina Ju.	S52	Zuev V.	S125
Zarkov Kostadin	S167, S238	Zhvitiashvili I.	S6, S7	Zugrav T.	S10, S11
Zaykova M.	S28	Zinchenko E.	S240	Zurnadzhlyants V.	S42
Zelinskaya N.	S11, S12	Zinovsky M.	S160	Zyul'korneeva S.	S24
Zelter P.	S160	Zipunnikov V.	S166		
Zemlyanoy V.	S238	Zivkovic M.	S27		
Zendejas Ivan	S140	Zlobin A.	S159, S160		
Zenin V.	S153	Zokoyev Allan	S84		
Zhabina R.	S166	Zubarev P.	S81		
Zhantay A.	S210, S211	Zuev V.	S125		
Zhao A.	S88, S116	Zugrav T.	S10, S11		
Zharikov Yu.	S116	Zurnadzhlyants V.	S42		
Zhavoronkova O.	S77	Zyul'korneeva S.	S24		
Zhelezinskaia V.	S173				
Zheludkova O.	S11, S12				
Zhigalova S.	S139, S239				
Zhurina Ju.	S52				
Zhvitiashvili I.	S6, S7				
Zinchenko E.	S240				
Zinovsky M.	S160				
Zipunnikov V.	S166				
Zivkovic M.	S27				
Zlobin A.	S159, S160				
Zokoyev Allan	S84				
Zubarev P.	S81				
Zuev V.	S125				
Zugrav T.	S10, S11				
Zurnadzhlyants V.	S42				
Zyul'korneeva S.	S24				