Online Journal of Health and Allied Sciences
Peer Reviewed, Open Access, Free Online Journal
Published Quarterly : Mangalore, South India : ISSN 0972-5997
Volume 19, Issue 4; Oct-Dec 2020

Case Report:

Extrasplenic Arterial Anastomosis – A Crucial Anatomical Variation

Authors:
Serghei Covantev, State University of Medicine and Pharmacy "N.Testemitanu", Chisinau, Republic of Moldova,
Kseniya Zabudskaya, N.N. Blokhin National Medical Research Center of Oncology, Moscow, Russian Federation
Olga Belic, State University of Medicine and Pharmacy "N.Testemitanu", Chisinau, Republic of Moldova.

Address for Correspondence
Serghei Covantev,
Department of Human Anatomy,
State University of Medicine and Pharmacy,
"Nicolae Testemitanu", Chisinau,
Republic of Moldova.
E-mail: Kovantsev.s.d@gmail.com.

Citation
Covantev S, Zabudskaya K, Belic O. Extrasplenic Arterial Anastomosis – A Crucial Anatomical Variation. *Online J Health Allied Scs.* 2020;19(4):8. Available at URL: https://www.ojhas.org/issue76/2020-4-8.html

Submitted: Dec 6, 2020; Accepted: Feb 27, 2021; Published: Mar 25, 2021

Abstract: Vascular anatomy of the spleen is constantly at special attention since there are various invasive and mini-invasive procedures that depend on precise knowledge of anatomy. Transcatheter partial splenic embolization is nowadays performed more often to treat a variety of conditions from patients with blunt splenic injury to interferon therapy in patients with chronic viral hepatitis. One of particularly important developmental variation is the presence of interarterial vascular anastomoses. Intrasplenic anastomosis are relatively common and are seen in 15.3%–43.3% of cases, while extrasplenic anastomoses are found less frequently in 4.9%–15.3%. We therefore present a case of an unusual splenic artery anastomosis in a 70-year-old male cadaver. The two splenic artery branches of the first order had an anastomosis thus forming a triangular arterial connection. Such anatomical variations allow surgical access and ligation, in order to achieve segmental dearterialization for hemostasis purposes and splenic preservation. They also provide a protection against ischemia in case of blockage.
Key Words: Spleen, Splenic artery, Extrasplenic anastomosis, Embolization

Introduction:
Vascular anatomy of the spleen is constantly at special attention since there are various invasive and mini-invasive procedures that depend on precise knowledge of anatomy. Wide introduction of endovascular embolization in clinical practice made it possible to manage difficult and sometimes unstable patients in a less invasive manner.
Transcatheter partial splenic embolization is nowadays performed more often to treat a variety of conditions from patients with blunt splenic injury to facilitating interferon therapy in patients with chronic viral hepatitis (1). Although, this is a widely accepted treatment option there are several difficulties which arise due to variations of arterial supply of the spleen. One of particularly important developmental variation is the presence of interarterial vascular anastomosis. Intrasplenic anastomosis are relatively common and are seen in 15.3%–43.3% of cases (1, 2). However, extrasplenic anastomoses are found less frequent in 4.9%–15.3%, which may also complicate the result and procedure of embolization (1-3). The presence of both intrasplenic and extrasplenic anastomosis is relatively rare and is found in 2.9% of cases (3). Nowadays, there is more interest toward the vascular variations and diseases of the spleen due to the increased incidence and prevalence of these conditions (4). We present an uncommon arterial anastomosis discovered during a routine anatomical dissection in a human cadaver.

Case Report
During a typical dissection of the organs of abdominal cavity in a 70-year-old male cadaver we encountered an unusual vascular variation of the spleen. The spleen measured 6.1X4.4 cm in length and width, respectively. The splenic artery branched from the celiac trunk and passed along the superior border of the pancreas. At the middle of the pancreatic body it divided into two arteries of the first order (Fig. 1). The two arteries had an anastomosis thus forming a triangle (Fig. 2). The superior artery of the first order gave off a superior polar artery and then branched into two vessels of the second order. The superior polar artery gave off two short gastric arteries. The inferior artery of the first order gave off a pancreatic tail artery, a short gastric artery and then divided into two vessels of the second order (Fig. 1). A schematic representation of the abovementioned branching pattern is present in figure 3. The splenic vein was formed by two veins of the first order which drained together at the level of the tail of the pancreas (Fig. 2). The vessel had two additional sources of drainage: a superior polar vein which accompanied the artery and a tail vein of the pancreas which accompanied the respective artery.

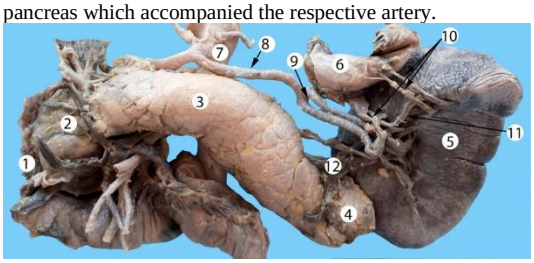

Figure 1. Overview of the anatomical specimen (a part of the stomach is removed). 1 – duodenum, 2 – pancreatic head, 3 – pancreatic body, 4 – pancreatic tail, 5 – spleen, 6 – part of the stomach, 7 – aorta, 8 – splenic artery, 9 – bifurcation of the splenic artery, 10 – short gastric arteries, 11 – superior polar artery, 12 – splenic vein.

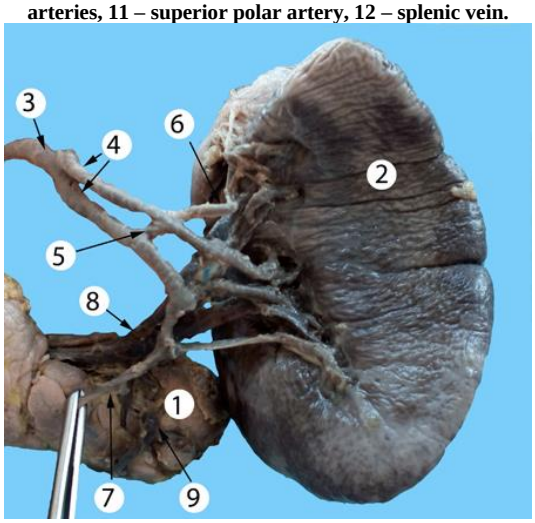

Figure 2. Arterial triangular anastomosis. 1 – pancreatic tail, 2 – spleen, 3 – splenic artery, 4 – splenic artery branches of the first order, 5 – arterial anastomosis, 6 – superior polar artery, 7 – artery to the tail of the pancreas, 8 – splenic vein, 9 – vein to the tail of the pancreas.

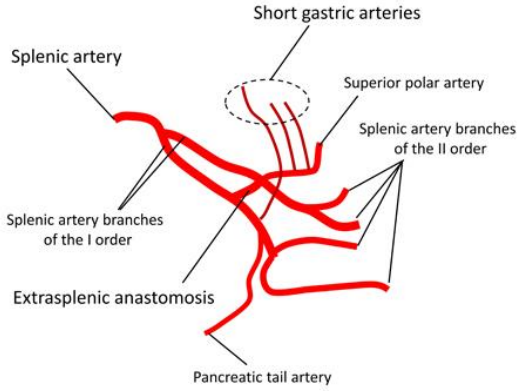

Figure 3. Schematic representation of the splenic artery and its branches.

Discussion

In the majority of cases the splenic artery divides into terminal branches in the fold of lienorenal ligament before entering into the hilum of the spleen. The number of terminal branches is two in 63.1% of cases, four branches in 18.8%, six branches in 9.7% and more than six branches in 18% of cadavers (2). The vascular supply of the spleen is complex, especially its intraorganic portion. Each lobe of the spleen is relatively independent, since there is often no anastomoses between (5). The spleen may, therefore, have two or three completely independent segments (6). However, in cases when there are anastomoses distal arterial splenic embolization can be achieved via collaterals (7).

Anatomical studies demonstrate that contrast solution can pass into neighboring compartments through vascular bridges. This is seen in 9.4% of cases when injecting into secondary branches, 22% when injecting into tertiary branches and 15.66% into fourth order branches (8). The current case illustrates that in some cases there are extraorganic anastomoses that are of clinical significance. From an endovascular standpoint it can be the reason for inadequate embolization or on the contrary a possibility to access the second vessel through the anastomosis. This is supported by the fact that the average length and caliber of these arteries allow surgical access and ligation, in order to achieve segmental dearterialization for hemostasis purposes and splenic preservation (9).

Splenic artery thrombosis is a relatively rare case usually happens in patients with some disorders that have potential of thromboembolism formation (10). However, the presence of interarterial anastomosis makes it possible for collateral circulation.

The present case demonstrates a rare extrasplenic anastomosis, which was formed by the branches of the splenic artery (Fig. 3). The anastomosis had a triangular shape and all of the vessels were of the same caliber therefore providing adequate circulation.

Conclusion

We present a case of an unusual splenic artery anastomosis. The two splenic artery branches of the first order had an anastomosis thus forming a triangle. Such anatomical variations allow surgical access and ligation, in order to achieve segmental dearterialization for hemostasis purposes and splenic preservation. They also provide a protection against ischemia in case of blockage. Although extrasplenic arterial anastomosis are relatively uncommon, they should be taken into account in vascular and endovascular surgery.

References

1. Guan Y-S, Hu Y. Clinical Application of Partial Splenic Embolization. *The Scientific World Journal.* 2014;2014:961345.
2. Pandey SK, Bhattacharya S, Mishra RN, Shukla VK. Anatomical variations of the splenic artery and its clinical implications. *Clinical Anatomy.* 2004;17(6):497-502.
3. Ignjatovic D, Stimec B, Duric B, Milicevic M. Anatomoclinical significance of splenic artery anastomotic bridges. *Acta chirurgica Iugoslavica.* 2000;47(1-2):113-8.
4. Covantev S, Mazuruc N, Ambarcumian M, Belic O. Splenic Artery Aneurysms: A Morphological Assessment. *Online J Health Allied Scs*. 2020;19(1):7.
5. Daisy Sahni A, Indar Jit B, Gupta CNM, Gupta DM, Harjeet E. Branches of the splenic artery and splenic arterial segments. *Clinical Anatomy.* 2003;16(5):371-7.
6. Gupta CD, Gupta SC, Arora AK, Singh PJ. Vascular segments in the human spleen. *Journal of Anatomy.* 1976 Jul;121(Pt 3):613-6.
7. Li X, Cwikiel W, Dasika N, Cho K. Distal Arterial Splenic Embolization via Collaterals: Report of Two Cases. *Acta Radiologica.* 2008;49(10):1119-23.
8. Garcia-Porrero JA, Lemes A. Arterial Segmentation and Subsegmentation in the Human Spleen. *Cells Tissues Organs.* 1988;131(4):276-83.
9. Ignjatovic D, Stimec B, Zivanovic V. The basis for splenic segmental dearterialization: a post-mortem study. *Surgical and Radiologic Anatomy.* 2005;27(1):15-8.
10. Cheng C-H, Bair M-J. Spontaneous Splenic Infarction as an Uncommon Cause of Fever in a Cirrhotic Patient. *International Journal of Gerontology.* 2017;11(2):121-4.