

E. Gudumac¹, S. Şciuca^{1,2}, R. Selevestru¹, L. Balaneţchi³

Pleuro-pulmonary complications in patients with chistic fibros

¹University of Medicine and Pharmacy «Nicolae Testemitanu», Chisinau, Republic of Moldova

²IMSP Mother and Child Institute, Clinic of Pneumology, Chisinau, Republic of Moldova

³Children Emergency Hospital, Cluj Napoca, Romania

PAEDIATRIC SURGERY.2017.4(57):28-34; doi 10.15574/PS.2017.57.28

Cystic fibrosis (CF) is an autosomal-recessive genetic disease characterized by a clinical triad: chronic pulmonary disease (chronic cough with purulent expectoration, dyspnoea, cyanosis, digital hippocratism), pancreatic insufficiency with maldigestion, malabsorption (fecal mass with lipid inclusions, fetide, bulky) weighting and increased content of chlorides in the sweat.

In the study are evaluated the clinic and imagistic sings of the lungs in 80 patients with CF by imagistic techniques. The main clinical manifestations in CF patients under study have been recorded in episodes of tremendous bronchial obstruction that is manifested by recurrent wheezing, persistent cough syndrome. The progressive evolution of the pulmonary pathological process was determined by resistant germs such as *Ps. aeruginosa*, *St. maltophilia*, *S. aureus*, *B. cepia* complex, which accelerated the destructive processes of the pulmonary parenchyma, and contributes to the spread of pulmonary fibrosis, bronchiectasis, emphysema, pulmonary destruction, focal or diffuse fibrosis, pleurisy, pneumothorax, all seen and diagnosed in imaging exams.

During the surveillance, the following complications were identified – pneumothorax, pleurisy (requiring toracocentesis), air bubbles, pulmonary empyema, pulmonary destruction, that developed in CF patients with exacerbations of *S. aureus*, *Ps. aeruginosa*, *B. cepacia* lung infections.

Synthesis of literature data and clinical experience has made it possible to optimize treatment programs for patients with CF to reduce the risk of progressive adverse evolutions, pleuro-pulmonary complications. Contemporary, long-term treatment in CF offers better quality of life, especially gene therapy.

Key words: cystic fibrosis, pleuro-pulmonary complications, children.

Легенево-плевральні ускладнення у пацієнтів із муковісцидозом

E. Gudumac¹, S. Şciuca^{1,2}, R. Selevestru¹, L. Balaneţchi³

¹University of Medicine and Pharmacy «Nicolae Testemitanu», Chisinau, Republic of Moldova

²IMSP Mother and Child Institute, Clinic of Pneumology, Chisinau, Republic of Moldova

³Children Emergency Hospital, Cluj Napoca, Romania

Муковісцидоз (МВ) є генетичним аутосомно-рецесивним захворюванням, характеризується клінічною тріадою: хронічні захворювання легень (хронічний кашель з гнійною мокротою, задишкою, ціанозом, симптомом барабаних паличок), недостатність підшлункової залози з мaldigestією, мальабсорбцією (фекальні маси з ліпідними включеннями, неприємним запахом, об'ємні), гіпотрофія та підвищений вміст хлоридів у поті.

У роботі представлений аналіз клініко-рентгенологічного дослідження легень у 80 пацієнтів із МВ за допомогою інструментальних методів діагностики. Серед основних клінічних проявів були зареєстровані епізоди бронхіальної обструкції з затяжним перебігом, що проявлялось задишкою, подовженим свистячим видихом «wheezing», синдромом хронічного кашлю. Прогресивний розвиток захворювання був обумовлений резистентними мікроорганізмами *Ps. aeruginosa*, *S. aureus*, *St. maltophilia*, *B. cepacia*, які прискорювали руйнівні процеси паренхіми легень, а також сприяли розвитку легеневого фіброзу, утворенню бронхоектазів, емфіземи, емфізематозних бул, деструктивним змінам легеневої тканини, плевриту, пневмотораксу та пневмомедіастинуму, що діагностувались рентгенологічними дослідженнями.

Під час спостереження були установлені наступні ускладнення – пневмоторакс, плеврит (що вимагало виконання торакоцентезу), бронхоектази, емпієма, деструктивні процеси легень, які розвивались у пацієнтів із МВ та резистентною легеневою інфекцією: *S. aureus*, *Ps. aeruginosa*, *B. cepacia*.

Синтез даних літератури та клінічний досвід дозволили оптимізувати ведення пацієнтів з МВ, щоб знизити ризик прогресування несприятливих плеврально-легеневих ускладнень. У світі комплексне сучасне лікування МВ, особливо генна терапія, забезпечує покращення якості життя цих дітей.

Ключові слова: муковісцидоз, легенево-плевральні ускладнення, діти.

Легочно-плевральные осложнения у пациентов с муковисцидозом

E. Gudumac¹, S. Şciuca^{1,2}, R. Selevestru¹, L. Balaneţchi³

¹University of Medicine and Pharmacy «Nicolae Testemitanu», Chisinau, Republic of Moldova

²IMSP Mother and Child Institute, Clinic of Pneumology, Chisinau, Republic of Moldova

³Children Emergency Hospital, Cluj Napoca, Romania

Муковисцидоз (МВ) является генетическим аутосомно-рецесивным заболеванием, характеризуется клинической триадой: хронические заболевания легких (хронический кашель с гнойной мокротой, одышкой, цианозом, симптомом барабанных палочек), недостаточностью

поджелудочной железы с мальдигестией, мальабсорбцией (фекальные массы с липидными включениями, неприятным запахом, объемистые), гипотрофия и повышенное содержание хлоридов в поте.

В работе представлен анализ клинико-рентгенологического исследования легких у 80 пациентов с МВ с помощью инструментальных методов диагностики. Среди основных клинических проявлений были зарегистрированы эпизоды бронхиальной обструкции с затяжным течением, что проявлялось одышкой, удлиненным свистящим выдохом «wheezing», синдромом хронического кашля. Прогрессивное развитие заболевания было обусловлено резистентными микроорганизмами *Ps. aeruginosa*, *S. aureus*, *St. maltophilia*, *B. ceracia*, которые ускоряли разрушительные процессы паренхимы легких, а также способствовали развитию легочного фиброза, образованию бронхоэктазов, эмфиземы, эмфизематозных булл, деструктивным изменениям легочной ткани, плеврита, пневмоторакса и пневмомедиастинума, диагностированные посредством рентгенологических исследований.

Во время наблюдения были установлены следующие осложнения – пневмоторакс, плеврит (что потребовало выполнения торакоцентеза), бронхоэктазы, эмпиема, деструктивные процессы легких, которые развивались у пациентов с МВ и резистентной легочной инфекцией: *S. aureus*, *Ps. aeruginosa*, *B. ceracia*.

Синтез данных литературы и клинический опыт позволили оптимизировать ведение пациентов с МВ, чтобы снизить риск прогрессирования неблагоприятных плеврально-легочных осложнений. В мире комплексное современное лечение МВ, особенно генная терапия, обеспечивает улучшение качества жизни этих детей.

Ключевые слова: муковисцидоз, легочно-плевральные осложнения, дети.

Introduction

Cystic fibrosis (CF) is a hereditary pathology with autosomal-recessive transmission characterized by the production of viscous secretions by the exocrine glands, manifested by obstructive chronic pneumopathy, malabsorption and malnutrition syndromes, with progressive chronic progression, and with varying prevalence: in Europe – 1 case in 1000-1800 newborns, in African countries – 1:17000, in the Asian population 1 out of 90000 live newborns. In the Republic of Moldova the frequency of cystic fibrosis is 1:2000-2500 newborns according to preliminary estimates [5,8].

Genetic researchers have discovered about 2000 mutations in the CFTR gene, and the most common mutation is F508del identified in 67-75% CF patients. The homozygous genotype of the F508del mutation is responsible for the most severe clinical forms with major risks of pleuro-pulmonary complications, with high fatal potential.

From the medical and social point of view, the importance of CF is determined by the reduction in the quality of life of the patient and a lower index of the average life, which in the developed countries was 14 years (in 1969), 28 years (1990), 31 years (1996) 30-32 years (2000), 47-50 years (2014). The high degree of childhood disability and the major fatal prognosis risks are conditioned by the early development of lung complications (bronchiectasis, pneumothorax, pleurisy, pneumofibrosis), digestive (pancreatic insufficiency, cirrhosis), nutritional (malnutrition, hypovitaminosis), cardiovascular (pulmonary cord) [5].

The onset of symptoms of bronchopulmonary damage in CF are premature – 80% in the first year of life with repeated bronchitis with severe obstructive syndrome, pneumonia with tremendous evolution with aggressive germs – *S. aureus*, *Ps. aeruginosa*, *H. influenzae*, development of pulmonary and extrapulmonary complications. The progressive evolution of the bronchopulmonary pathological process is determined by the selection of the multidrug-resistant germs, which accelerate

the destructive processes of the pulmonary parenchyma, contribute to the extension of the pulmonary fibrosis phenomena, the development of pulmonary complications (fibrosis, bronchiectasis, atelectasis, pneumothorax, emphysema, lung destructions, pulmonary abscesses, hemoptysis, lung calcifications, pulmonary hypertension, pulmonary cord), progressive respiratory insufficiency [10].

Aim. The purpose of the study is to present difficulties in diagnostic and treatment of pleuro-pulmonary complications in patients with cystic fibrosis, related to pulmonary infections, CFTR genotype and age-related.

Materials and methods

It is a study of 80 patients with CF, hospitalized and assessed clinical and paraclinical in the Cystic Fibrosis Center and in the Clinic of Pediatric Surgery, Orthopedics and Anesthesiology, for 20 years. The group had characteristics: mean age 8.79 ± 0.96 years, with age extremes 1 month – 38 years, distribution by sex 1:1, and average age of CF diagnosis – 3.61 ± 0.88 years, with variations in the neonatal period up to the age of 34 years.

The positive diagnosis of CF has been confirmed on the basis of anamnestic data, clinical examination of pulmonary disease, with frequent respiratory infections, repeated bronchitis, recurrent pneumonia, bronchiectasis, associated with maldigestion syndrome (steatorrhea, high-weight deficiency), paraclinical investigations (the sweat test using automated techniques with Macroduct System, USA; Exudose, France, molecular DNA research to determine CFTR mutations).

The imaging exam included echographic results, pulmonary radiography, computed tomography with angiography, pulmonary scintigraphy. The analysis of bronchial imaging data in patients with CF revealed lung hypertransparency, interstitial linear opacities, pulmonary cysts, pneumofibrosis, and in some patients were observed minor bronchopulmonary radiologic changes despite significant ventilator dysfunction.

Торакальна хірургія

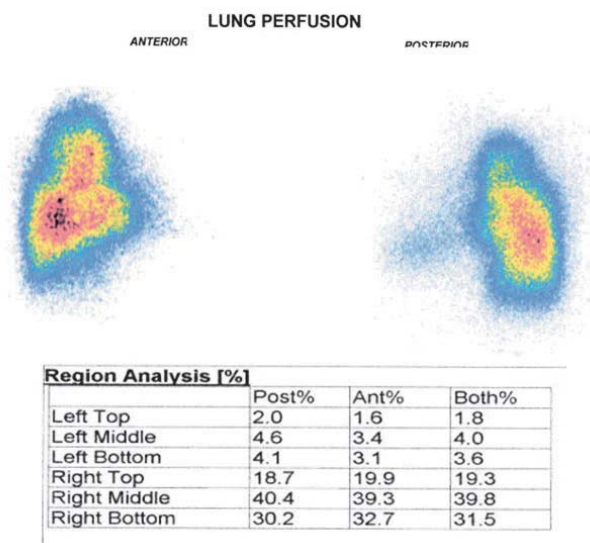


Fig.1. Pulmonary scintigraphy in the patient with CF – pulmonary perfusion disorders, deformed image with erased contour of the right lung. Reduced perfusion regions in S1-4.6. Absence of infusion in the left lung. In the projection of the left lung – unique fragments of radioactive substance accumulation. 8-year-old child with chronic pulmonary infection with *Ps. aeruginosa*, genotype delF508/X

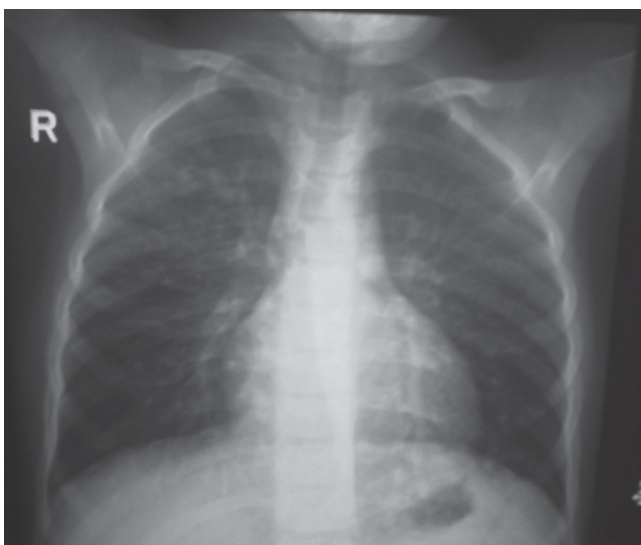

Fig.3. Thoracic chest radiography – hyperinflation, intensified pulmonary pattern, apical deformation and basal on the left, polymorphic, cystic deformations, S3 on the right, S5, S10 on the left. 7-year-old child with CF, chronic *Ps. aeruginosa* pulmonary infection, CFTR genotype delF508/W1282X

The research was carried out in accordance with the principles of the Helsinki Declaration. The study protocol was approved by the Local Ethics Committee (LEC) or National Bioethics Committee of all participating institution. The informed consent of the patient was obtained for conducting the studies.

The imaging evaluation of bronchopulmonary lesions was performed by thoracic HRCT (Aquilion 32, Toshiba, Japan). Pulmonary spiral computed tomography (CT)

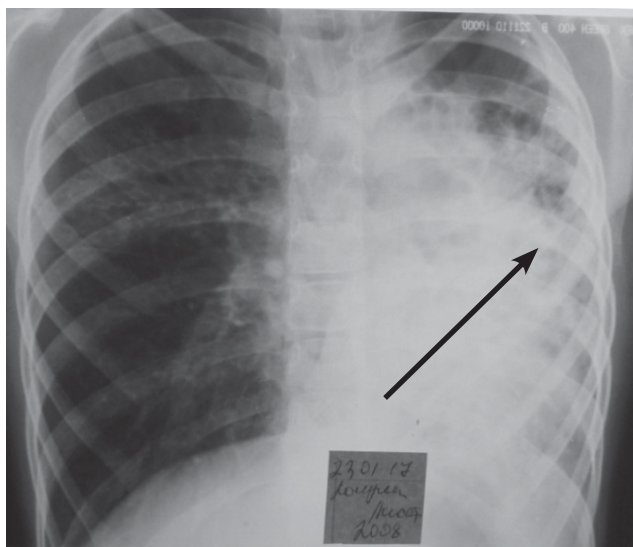


Fig.2. Thoracic chest radiography – left pulmonary atelectasis, total mediastinal displacement to the left, diffuse polymorphic cavity formations on the left. 8-year-old child with chronic lung infection with *Ps. aeruginosa*, genotype delF508/X, unfavorable evolution

with contrast is a necessary radiological exploratory exam, highly informative, and detects structural changes in the broncho-pulmonary system. Pulmonary CT provides high information in the assessment of the broncho-pulmonary substrate, thus advanced pulmonary emphysema, atelectasis, bronchiectasis, fibrosis, pulmonary sclerosis have been identified in CF.

The statistical processing of the material has been computerized (Microsoft Excel program).

Results and discussions

CF is a generalized exocrinopathy caused by the disruption of transepithelial transport of chlorine ions into tissues and organs, whereby the mucous glands produce very viscous secrets, and the serum glands eliminate the increased electrolyte content. The disordered transport of chlorine ions results in poor water transport, which does not ensure sufficient fluidity of secreted mucus. Accumulation of viscous and sticky mucus causes obstruction and inflammation in the glands and ducts followed by serious tissue damage [2].

The main clinical manifestations in CF patients, from this study, have been recorded in episodes of tremendous bronchial obstruction with wheezing, prolonged expulsion, persistent cough syndrome, night exacerbations, paroxysmal character, quintile, tiring. In 2/3 of cases, the clinical picture ranged to obstructive chronic broncho-pneumonia, which have evolved to diffuse irreversible changes with total pulmonary function loss, significant reduction in pulmonary perfusion (Figure 1), due to the progressive recurrent progression of pulmonary lesions in CF.

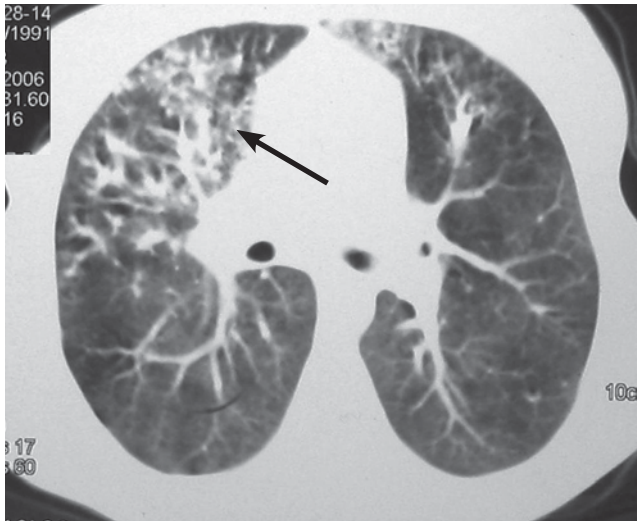


Fig.4. Pulmonary CT – «matte glass syndrome», fibrosis zones, varicose and sacciformes bronchiectasis, signs of bronchiolitis (in cortical areas, Y-type). 15-year-old child with CF, *S. aureus* chronic infection, CFTR genotype delF508/delF508

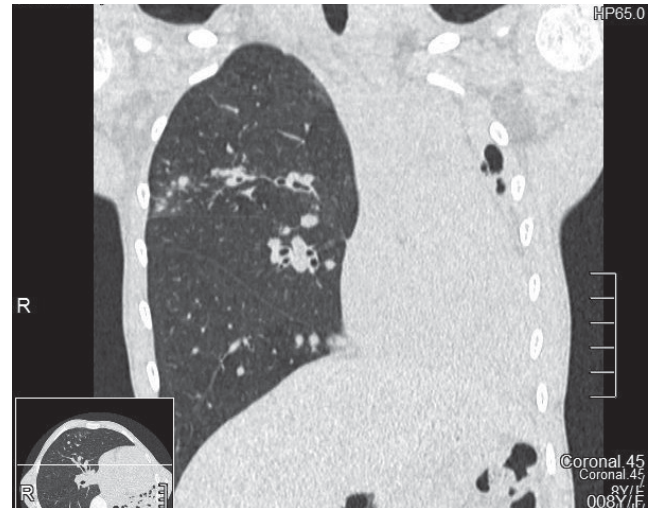


Fig.5. Pulmonary CT – Left lung fibroelectasis, decreased left hemithorax, mediastinal moving to the left. 8-year-old child, with CF, chronic pulmonary infection with 2 multidro-resistant strains of *Ps. aeruginosa*, CFTR genotype delF508/X

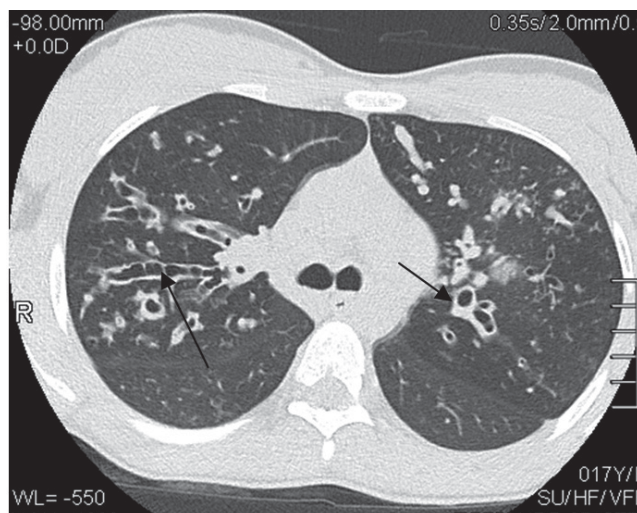


Fig.7. CT pulmonary – bilateral cylindrical and sacciformes bronchiectasis, with thickened walls, pneumosclerosis zones on the left. 18-year-old child, with CF, *Ps. aeruginosa* chronic pulmonary infection, CFTR genotype 4015delAC/4015delAC

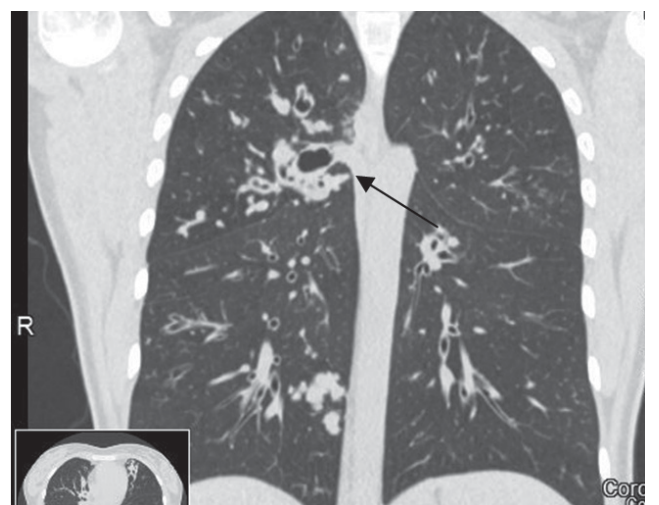
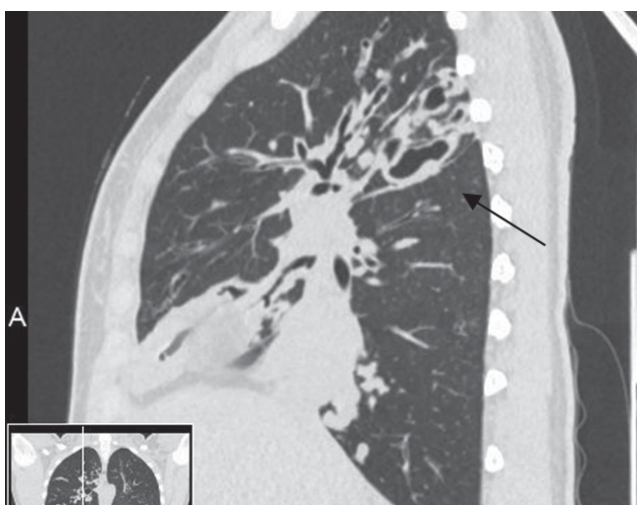
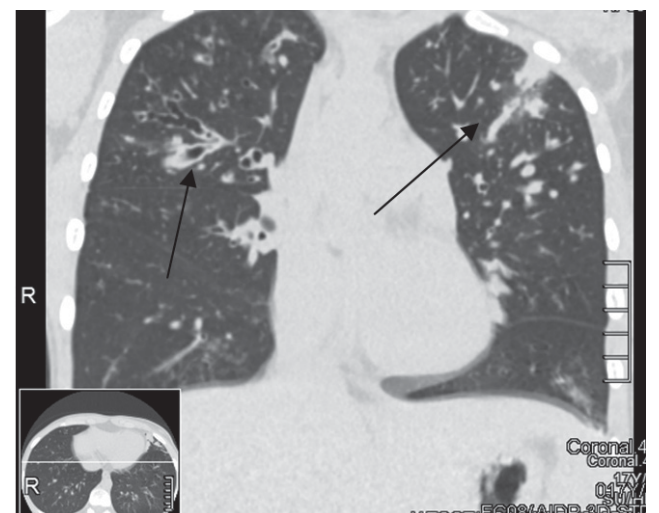


Fig.8. Pulmonary CT – Air cysts in the right pulmonary parenchyma with fibrous walls. 14-year-old child with FC, chronic *Ps. aeruginosa* pulmonary infection, CFTR genotype G542X/N1303K

Торакальна хірургія

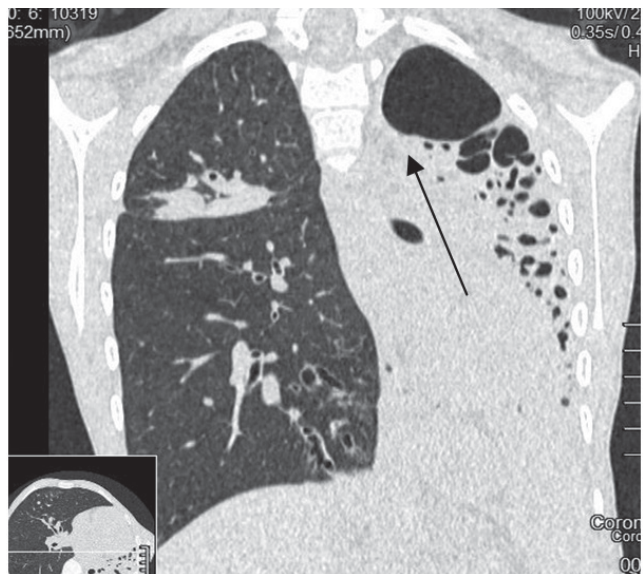
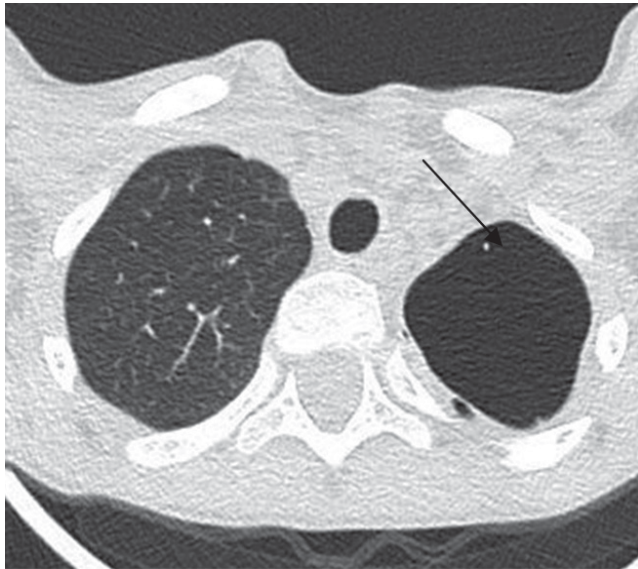
Fig. 9. Pulmonar CT – Left pulmonary fibroatelectasis, reduced left hemithorax, mediastinum moving to left, 3x3.4cm air bubble in the upper left lobe. 8-year-old child, with FC, chronic pulmonary infection with 2 multiresistant strains of *Ps. aeruginosa*, CFTR genotype delF508/X

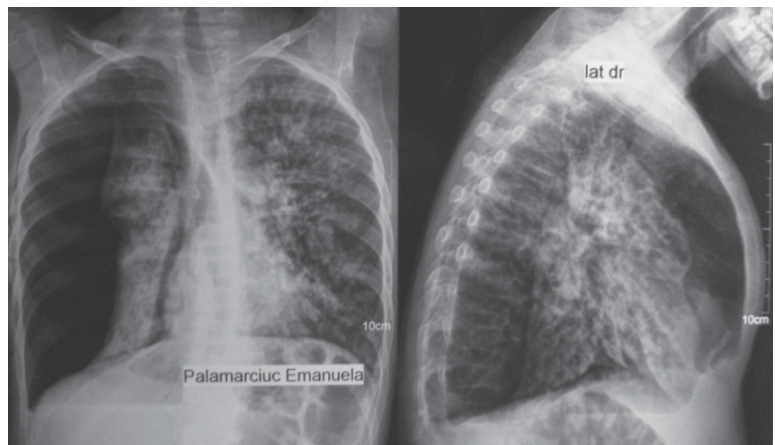
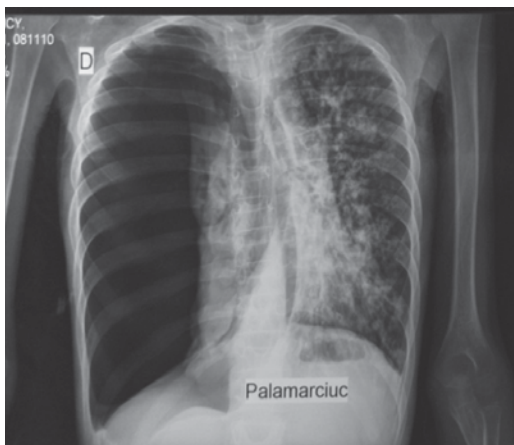


Fig.10. Pulmonary radiography – pneumothorax, the presence of free air in the pleural cavity, the right lung collapsed, the movement of the mediastinum to the left. Deceased child, 9 years, with CF, with *Ps. aeruginosa* chronic pulmonary infection, F508del/F508del genotype

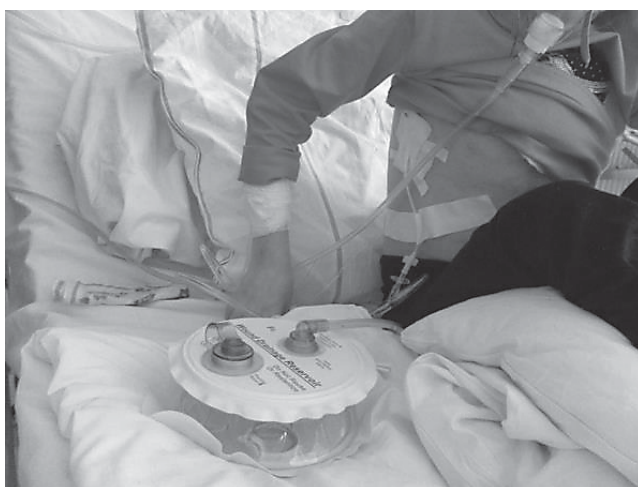

Fig.11. Surgical treatment of pneumothorax by applying a tube to the chest cavity and decompressive exudation. Deceased child, 9 years, with FC, with *Ps. aeruginosa* chronic pulmonary infection, F508del/F508del genotype

Respiratory manifestations in CF are varied depending on the degree of morphological changes of the bronchial tree, being presented by submucosal gland hypertrophy, caliciform cells hypertrophy, caliciform cell and ciliated epitheliocytes metaplasia, bronchial destruction, hypertrophy of bronchial epithelium. FC is characterized by the deregulation of mucociliary clearance with increased viscosity of bronchial secretions, which easily favors the compromise of local antiinfectious factors, colonization with aggressive microorganisms and the installation of bronchial hyperreactivity [2,3].

Thus, alveolar pulmonary damage from infectious episodes with aggressive germs causes bronchopulmonary chronicity. The progressive evolution of the pulmonary pathological process was determined by resistant germs such as *Ps. aeruginosa* (62.5%), *S. aureus* (55%), *St. maltophilia*, *B. cepia* complex, which accelerates the

destructive processes of the pulmonary parenchyma, and contributes to the spread of pulmonary fibrosis, bronchiectasis, emphysema, and pulmonary destruction.

The character of expectorations in children with CF is related to the bacteriological spectrum of lung infections: the piogenic germs cause abundant, purulent bronchial secretions, sometimes fetid sputum (20%). In advanced forms of pulmonary damage in 10% of patients, hemoptysis was present in infectious exacerbations. In 37.5% patients with CF, occurs chest deformity (emphysematous thorax, dorsal chifosis, thorax «in the hull»), which is a clinical expression of the severe bronchopulmonary pathological process. Pulmonary osteoarthropathy have a hypertrophic character and is responsible for thoracic jungle (17.5% patients), bone frailty with repeated fractures (12.5% patients), swelling. Over time, progressive respiratory failure develops, severe persistent chronic hypoxia causes the formation of digital hypokration in CF children (55% of patients).

Pulmonary radiological examinations (Figure 2, 3) in patients with CF showed signs of bronchitis, bronchoobstructive syndrome, emphysema with thoracic distension, pulmonary hypertransparency, more pronounced in apical areas, segmental opacities, confluent pulmonary condensation outbreaks, alveolar opacities, segmental and sub-segmental atelectasis «in the band», reticulo-nodular images, bronchial tree deformations, bronchiectasis in the «bunch» (more often affecting the upper right lobe), pneumofibrosis in the basal pulmonary segments.

A highly informative data of the bronchopulmonary changes in CF patients we obtain on computerized tomography (Figure 4, 5), which reveals signs of bronchopulmonary involvement, deformation of the pulmonary design involving the perivascular and peribronchial component. Bronchoobstructive syndrome in CF patients revealed pulmonary hyperinflation (72.5% cases), pulmonary emphysema (22.5%), non-uniform pneumatics with hyper- and hypoventilation zones, complicated with atelectasis in some cases (10%), diffuse foci of obturation pneumonia (15%). Broncho-obstructive phenomena are associated with persistent bronchial infections, leading to significant chronications, visualized at pulmonary CT with bronchial wall thickening (78.7%).

Characteristic for pulmonary involvement in CF is «matte glass syndrome» (Figure 4), which characterizes interstitial fibrosis phenomena, and fibrosis expressivity correlates with the disease stage, in advanced forms it complicates with areas of fibroatelectasis (Figure 5), bronchiectasis – at 62.5% patients. Bronchiectasis in CF patients was predominantly localized in upper lobes (50%) and predominant sacciforms bronchiectasis (47.5%), often with fluid levels (18.7%) (Figure 7).

Bronchiectasis is a diffuse or localized irreversible bronchial dilation, usually secondary to chronic infection, congenital anomalies or pulmonary fibrosis (traction bronchiectasis). Morphological criteria for fine-grained CT scan include: bronchial dilation versus to the adjacent pulmonary artery branch (the sign of the «sealing ring»). Bronchiectasis associates bronchial wall thickening, mucus plugs, signs of small airway damage (centripetal grouping nodules, air trapping) [4,11].

Pulmonary cyst (Figure 8) appears as a well-defined border of hypertransparency due to an epithelial or fibrous wall that presents a complication in infections. The content of lung cysts is usually aerobic, but occasionally cysts can contain liquid or solid material. Multiple cysts with thicker «honeycomb» walls characterize advanced pulmonary fibrosis [10,11].

The dilatation of the hills due to infectious adenopathy was determined in ¼ patients with CF, and the pulmonary trunk size increase in 18.7% of cases, which indicate the installation of pulmonary hypertension, pulmonary cord. Minor changes in the CT scan were seen in only 22.5% children with FC.

During surveillance, 25% CF patients with lung infections were diagnosed with pleurisy, which required thoracentesis in 8,7% of cases. Lung empyema was a serious complication in these patients, confirmed in 7.5% of cases. Pulmonary destructions (27.5% cases) developed in CF patients with exacerbations of *S. aureus* lung infections, rarely *Ps. aeruginosa*, *B. cepacia*.

The air bubble (pneumatocele) is a focal circumferential hypertrophic area or a low attenuation zone with a diameter of more than 1 cm and the thin wall (<1 mm). Bubbles in CF patients are located predominantly in the subpleural area in the central parenchymal lung area (Figure 9), which presents a risk of rupture in the context of coughing with installation of pneumothorax. Multiple bubbles are common, with signs of centrilobular or paraseptal pulmonary emphysema [9].

Pneumothorax is the accumulation of gas in the space between the lung and the chest wall, which occurs as a result of pulmonary tissue rupture, more commonly in patients with pneumatocele. More than 10% of CF patients develop pneumothorax, which is a serious complication with danger to the patient's life. The diagnosis is based on the brutal occurrence of dyspnea, violent chest pain, severe asphyxia, the abolition of vocal vibrations, hypersomnia and silence at auscultation. The onset of pneumothorax is usually brutal, even dramatic, in an effort, violent cough or apparent cause [12].

Pneumothorax is a major pleuro-pulmonary complication present in 17.5% CF patients, who in 11.2% had an unfavorable death rate at 10-22 years of age (Figure 10).

Торакальна хірургія

Genetic research of CFTR mutations confirmed the presence of the F508del genotype (15 cases – F508del/F508del, 4 cases – F508del/2789+5G> A, 3 cases – F508del/X) for 84.6% CF patients. Pneumothorax is a cause of mortality in patients with CF. Over 70% of patients develop recurrence after solving the first pneumothorax [6]. According to the European CF Registry, more than 7000 patients were able to demonstrate that the pneumothorax was among the factors associated with poor pulmonary function, as reflected by FEV1 > 10%.

The purpose of treatment in patients with CF (Figure 11) is the safe and effective resolution of pneumothorax with prevention of recurrence. Various therapeutic interventions are known: sclerosing agents, pleural abrasion, intercostal drainage, pleurectomy, and Heimlich flutter valve [1,7]. Most of these methods had different success rates and failures.

Synthesis of literature data and clinical experience has made possible to optimize treatment programs for patients with CF to reduce the risk of progressive adverse evolutions, pleuro-pulmonary complications. An important potential in CF patient is the implementation of the neonatal screening program, as well as a dual diagnosis program in the detecting of pathology at the early stages of the disease to prevent pleuro-pulmonary complications, improve prognosis, lifetime. Contemporan long-term treatment in CF offers better quality of life, especially gene therapy, but surgical treatment is more reserved.

Conclusion

1. Influence of the bronchopulmonary system in cystic fibrosis is clinically characterized by bronchoobstructive syndrome, chronic cough, and imagistic by fibrosis phenomena in the interstitial structures and the formation of extensive bronchiectasis.

2. Pulmonary syndromes in patients with cystic fibrosis evolve progressively, with the risk of death by severe pleuro-pulmonary complications, which are caused

by aggressive *Ps.aeruginosa* infections, by overdose infection with pulmonary alveolar affection, abscesses, atelectasis, pleurisy, pneumatosis.

3. On the personal case, early diagnosis, individualized conservative treatment, careful clinical-paraclinical assessment leads to a low rate of recurrence of bronchopulmonary complications and a higher life expectancy of CF patients.

4. The prognosis of CF with bronchopulmonary involvement is related to the degree of respiratory lesions, the character of pleuro-pulmonary complications, the presence of extrapulmonary syndromes, CFTR genotype F508del, and the degree of doctor-patient collaboration.

No conflict of interest was declared by the authors.

References

- Amin R., Noone PG, Ratjen F. Chemical pleurodesis versus surgical intervention for persistent and recurrent pneumothoraces in cystic fibrosis. *Cochrane Database Syst Rev.* 2009;(2):CD007481
- Bhalla V, Hallows KR. Mechanisms of ENaC regulation and clinical implications. *J Am Soc Nephrol* 2008;19:1845–54
- Debray D. et al. Best practice guidance for the diagnosis and management of cystic fibrosis-associated liver disease. *Journal of Cystic Fibrosis Volume 10 Suppl 2 (2011) S29-S36*
- Dodd J. et al. Imaging in cystic fibrosis and non-cystic fibrosis bronchiectasis. *Semin. Respir. Crit. Care Med.*, 2015; 36 (2): 194-206
- European Cystic Fibrosis Society Patient Registry. Annual data report (2014), 2016, p. 85
- Flume PA, Strange C, Ye X, et al. Pneumothorax in cystic fibrosis. *Chest* 2005;128:720-8
- Ioannis P. Kioumis, Konstantinos Zarogoulidis, Haidong Huang, et al.. Pneumothorax in cystic fibrosis. *J Thorac Dis.* 2014 Oct; 6(Suppl 4): S480–S487
- Southern K., et al. A survey of newborn screening for cystic fibrosis in Europe. *Journal of Cystic Fibrosis*, 2007, nr.6, p.57-65
- Wang J. et al. High-resolution computed tomography in assessment of patients with emphysema. *Respir. Care*, 2013; 58 (4): 614-22
- Wielpütz MO, Eichinger M, Biederer J et al. Imaging of Cystic Fibrosis Lung Disease and Clinical Interpretation. *Fortschr Röntgenstr* 2016; 188: 834–845
- Wormanns D., Hamer OW.. Glossary of Terms for Thoracic Imaging – German Version of the Fleischner Society Recommendations. *Fortschr Röntgenstr* 2015; 187(08): 638-661
- Yeow K.M., Risk factors of pneumothorax and bleeding: multivariate analysis of 660 CT-guided coaxial cutting needle lung biopsies. *Chest*, 126 (2004), pp. 748-754

Відомості про авторів:

Eva Gudumac – academician, university professor, dr.hab.med., University of Medicine and Pharmacy «Nicolae Testemitanu», Department of Pediatric Surgery, Orthopedics and Anesthesiology, Republic of Moldova, 2004, Chisinau, Stefan cel Mare, 165; tel. 373 69128177

Svetlana Şciuca – university professor, dr.hab.med., University of Medicine and Pharmacy «Nicolae Testemitanu», Department of Pediatrics Chisinau, Republic of Moldova, 2004, Chisinau, Stefan cel Mare, 165; IMSP Mother and Child Institute, Clinic of Pneumology, Chisinau, Republic of Moldova, st. Burebista, 93, tel. 373 22 552391, 373 79471374.

Rodica Selevestru – university assistant, dr.med., University of Medicine and Pharmacy «Nicolae Testemitanu», Department of Pediatrics, Republic of Moldova, 2004, Chisinau, Stefan cel Mare, 165, tel. 373 22 552391.

Ludmila Balaneţchi – resident physician Children Emergency Hospital, Department of Pediatric Surgery and Orthopedics, Cluj Napoca, Romania, tel. 373 79742858.

Стаття надійшла до редакції 18.04.2017 р.